

REVIEW ARTICLES

<https://doi.org/10.52418/moldovan-med-j.66-1.23.08>
UDC: 616.131-005.7-06



Post-pulmonary embolism syndrome: long-term complications of pulmonary embolism

¹Nadejda Diaconu, ^{1,2}Irina Civirjic, ²Galina Sorici, ¹Aurel Grosu

¹Scientific Clinical Laboratory on Cardiac Emergencies and Arrhythmias, Institute of Cardiology
²Doctoral School in Health Sciences, Nicolae Testemitanu State University of Medicine and Pharmacy,
Chisinau, the Republic of Moldova

Authors' ORCID iDs, academic degrees and contributions are available at the end of the article

*Corresponding author – Nadejda Diaconu, e-mail: nadeadiaconu@mail.com

Manuscript received November 17, 2022; revised manuscript February 17, 2023; published online March 10, 2023

Abstract

Background: People who survive an episode of pulmonary embolism (PE) have an increased risk of developing chronic complications even despite curative anticoagulant treatment. The association of dyspnea, low functional capacity, right heart failure, chronic thromboembolic pulmonary hypertension or chronic thromboembolic pulmonary disease is part of the notion of post-pulmonary embolic syndrome (PPES). Due to the fact that this syndrome is still not clearly described and mainly underdiagnosed, a poor awareness of the disease by patients and physicians leads to delaying specific treatment with unlikely improvement of quality of life for these patients. Chronic thromboembolic pulmonary hypertension is the most severe complication, which, if not diagnosed and not treated in time, can lead to fatal consequences. To improve the overall health outcomes of patients with acute PE, adequate measures to diagnose it and strategies to prevent long-term outcomes of pulmonary embolism are essential.

Conclusions: In this article, the data from the latest publications have been summarized to clarify the notion of PPES and its diagnostic algorithm.

Key words: thromboembolic pulmonary hypertension, post-pulmonary embolism syndrome, long-term outcomes.

Cite this article

Diaconu N, Civirjic I, Sorici G, Grosu A. Post-pulmonary embolism syndrome: long-term complications of pulmonary embolism. *Mold Med J.* 2023;66(1):44-51. <https://doi.org/10.52418/moldovan-med-j.66-1.23.08>.

Introduction

Following the researches carried out over the last 10 years, it has been demonstrated that less than half of the survivors of a pulmonary embolism do not return to their previous functional capacities. These patients in which persist right ventricle (RV) dysfunction continue to present with dyspnea, impaired functional status, diminished exercise capacity, becoming so limiting that they significantly reduce the quality of life (QoL) for many years ahead [1, 2]. The evolution of a patient with pulmonary embolism (PE) diagnosed and treated adequately, can be complicated by hemorrhages caused by anticoagulant treatment, recurrence of PE and long-term sequelae. People who survive an episode of pulmonary embolism are at increased risk of complications. In addition to the traditional complications (recurrent pulmonary embolism, anticoagulation-associated bleeding and cardiovascular events), the quality of life can be significantly affected by persistent dyspnea and sometimes disabling symptoms.

In this context, in order to systematize these patients,

the term post-pulmonary embolism syndrome (Post-PE syndrome or PPES) was proposed. Post-PE syndrome is defined by the presence at least 3 months after an acute episode, despite adequate anticoagulant treatment, of new or progressive dyspnea, a decrease in exercise tolerance and/or an unexplained impairment of functional or mental status, by the existence of other comorbidities [3]. The notion of PPES includes chronic thromboembolic pulmonary hypertension (CTEPH) and chronic thromboembolic pulmonary disease (CTEPD), post-PE cardiac dysfunction (heart failure with persistent right ventricular impairment), and post-PE decreased functional capacity (physical deconditioning) [4, 5]. Decreased functional capacity includes changes in the ability to care for oneself, to perform usual household or work activities, following physical, cognitive or intellectual impairments. Such a patient will be included in the diagnosis of post-pulmonary embolism syndrome [6]. Recently a consensus was developed that helps an early identification of patients with late outcomes of pulmonary embolism and aims to improve their prognosis [3, 7, 8].

Discussion

At the initial stage of diagnosis of the post-PE syndrome, it is important to exclude other comorbidities by performing early diagnostic functional tests, initiating their specific therapy in order to diminish the establishment of characteristic symptoms. The lack of clear guideline recommendations as well as inefficient application of diagnostic tests in clinical practice lead to a reported staggering diagnostic delay >1 year.

Chronic thromboembolic pulmonary hypertension is considered to be the most frequent and serious complication described in post-pulmonary embolism syndrome, which affects 2-4% of pulmonary embolism survivors [9]. An international CTEPH registry (Europe and Canada) indicated that 75% of patients with CTEPH had a documented antecedent history of acute pulmonary embolism [10]. The incidence of CTEPH after symptomatic acute pulmonary embolism is reported to range from 0.4% to 6.2% [11]. This complication, not treated in time, can even lead to death. To minimize the incidence of chronic complications after an episode of pulmonary embolism, it is important to identify and adequately treat patients with CTEPH as soon as possible. Chronic thromboembolic pulmonary hypertension is characterized by persistent obstruction of the pulmonary arteries by organized thromboembolic material associated with microvascular remodeling, which leads to an increased pulmonary vascular resistance, pulmonary hypertension (PH) and right heart failure [11]. Unilateral pulmonary artery obstruction represents a particular subset of CTEPH/CTEPD [12]. The mechanism of pulmonary hypertension in CTEPH is multifactorial. The most frequently discussed cause of pulmonary arterial hypertension is the persistence of the thrombus in the pulmonary arteries after an acute episode of pulmonary embolism. In a small subset of patients, a residual organized clot remains attached to pulmonary vessel walls. The complex pathophysiology of this entity primarily includes the failure of intra-arterial thrombus reabsorption, even in patients on adequate anticoagulant therapy, the pathophysiology of which remains not fully elucidated. Besides that, recent insights have revealed a small-vessel disease involved in CTEPH pathophysiology, including inflammation and infections that may be provocative for pulmonary hypertension (fig. 1).

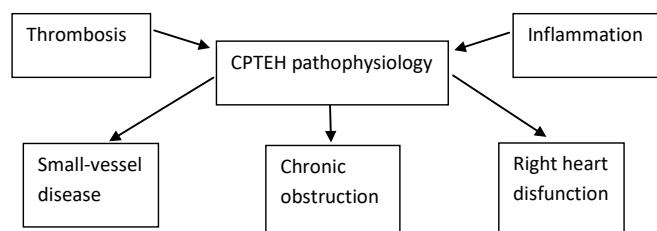


Fig. 1. Pathophysiology of chronic thromboembolic pulmonary hypertension (CTEPH) [13]

Lung ventilation/perfusion scintigraphy is the screening test of choice (fig. 2); a normal scan rules out CTEPH. For the diagnosis of CTEPH, a high-quality pulmonary angiogram is necessary to confirm and define the pulmonary vascular involvement. Prior making a treatment decision a right heart catheterization should be performed, in which a persistently pulmonary artery pressure greater than 20 mmHG presented over 3 months after an episode of pulmonary embolism, will establish the final diagnosis of CTEPH [11]. It is essential to diagnose chronic thromboembolic pulmonary hypertension in time to redirect them to a specific treatment. In addition to the medication widely used in patients with arterial hypertension, there is the possibility of performing invasive maneuvers: pulmonary endarterectomy with thrombus extraction or pulmonary balloon angioplasty, methods that have established a good long-term prognosis (improvement of hemodynamics and functional capacity) with an acceptable rate of complications in patients with CTEPH [14]. Interventional and medical treatment of CTEPH should be done in expert centres and aim to restore normal flow distribution within the pulmonary vasculature, unload the right ventricle and prevent or treat small-vessel disease.

Very similar to CTEPH, *chronic thromboembolic pulmonary disease (CTEPD)* involves similar vascular lesions without pulmonary hypertensive haemodynamics at rest (mPAP \leq 20 mm Hg or $20 < \text{mPAP} < 25$ mm Hg and pulmonary vascular resistance [PVR] < 240 dyn·s/cm⁵) [16]. Both entities are characterized by the persistence of thrombi in the pulmonary arteries, physical deconditioning and a modified cardiopulmonary test (fig. 3). These criteria were established by the International Society of Thrombosis and Haemostasis, including dyspnea according to NYHA scale and abnormal 6-minute walk distance (6MWD) [6].

For example, patients with complete unilateral obstruction may present with normal pulmonary haemodynamic parameters at rest despite symptomatic disease. These patients are classified as having chronic thromboembolic pulmonary disease. CTEPH or CTEPD are potentially curable by pulmonary endarterectomy (PEA) or by balloon pulmonary angioplasty (BPA). However, more than half of patients are not eligible for surgery, or experience persistent or recurrent PH after PEA. According to some studies, pulmonary endarterectomy could improve function class and hemodynamic in patients with CTEPD [17].

Another form of chronic post-pulmonary embolism complication is *heart failure* with a primary involvement of the right ventricle. Incomplete recovery of the right ventricle following adequate treatment of acute pulmonary embolism occurs between 4 and 25% of cases [6, 15] and is defined by:

- The presence of an intermediate or high probability of pulmonary hypertension according to the European Society of Cardiology (ESC) criteria on echocardiography (the EACVI imaging guide);
- Hypokinesis or dilatation of the right ventricle (RV);
- Exertional dyspnea corresponding to NYHA II-IV.

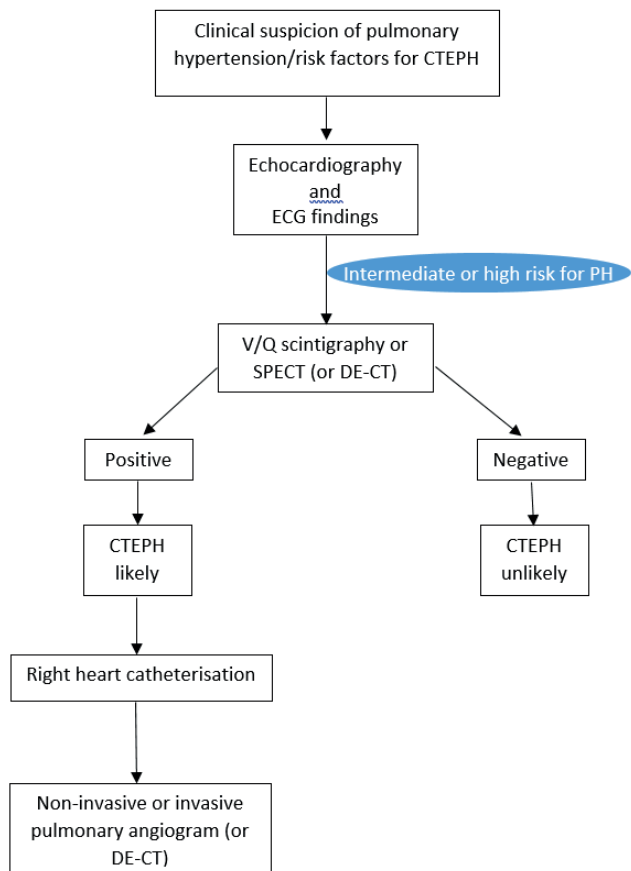


Fig. 2. Diagnostic imaging algorithm for CTEPH/CTEPD [12, 15].

ECG, electrocardiography; V/Q scintigraphy, ventilation/perfusion scintigraphy; SPECT, single-photon emission computerized tomography; DE-CT, dual energy computed tomography; CTEPH, chronic thromboembolic pulmonary hypertension.

Left diastolic dysfunction is the most common abnormality detected on echocardiography (tab. 1). Adaptive

remodelling mostly occurs with RV wall hypertrophy. However, the RV is not capable of sustaining the long-term progressively increased afterload, thereby remodelling becomes maladaptive. Right ventricular failure leads to further RV dilatation, worsening LV filling, decreased LV stroke volume, all leading to right ventricular dysfunction [15].

Table 1. Proposed echocardiography algorithm for the assessment of RV function [18]

1.	Recommended screening test for known/suspected RV dysfunction	
2.	Useful for serial assessment, response to therapy	
3.	Parameters assessed	
	Dimensions	RV size
		Right atrial size
	ASE recommended for assessment of RV function (at least one)	Fractional area change
		S' (PW TDI)
		TAPSE
	RV index of myocardial performance	dP/dT
		Isovolumic acceleration
		Diastolic function (E/A, E/E')
	RV/pulmonary hemodynamics	PASP
		Right atrial pressure estimate (from IVC dimensions)
	Consider	PADP
		Pulmonary vascular resistance
	Additional parameters	RV free wall
		Septal strain
		Pulmonary acceleration time

Diagnostic Criteria	CTEPH	CTEPD
Symptoms	Exercise and resting dyspnea	Exercise dyspnea, or no symptoms
RHC	mPAP ≥25 mm Hg, PAWP ≤15	mPAP <25 mm Hg (usually 21–24), PAWP ≤15
RHC at exercise	—	Pressure-flow slope >3 mm Hg/L/min
V/Q scan	Mismatched perfusion defects	Mismatched perfusion defects
Angiography (CTPA or DSA)	Ringlike stenoses, webs/slits, and chronic total occlusions (pouch lesions, or tapered lesions)	Ringlike stenoses, webs/slits, and chronic total occlusions (pouch lesions, or tapered lesions)
CPET	—	mPAP/CO slope >1 (correlated with dead-space ventilation) and ventilatory equivalents for carbon dioxide slope >20 ⁷⁵
TTE	Normal or enlarged RV and RA	Usually normal RV and (mildly enlarged) RA
Anticoagulation before diagnosis	At least 3 mo	At least 3 mo

Abbreviations: CO, cardiac output; CPET, cardio pulmonary exercise test; CTED, chronic thromboembolic pulmonary disease; CTEPH, chronic thromboembolic pulmonary hypertension; CTPA, computed tomography pulmonary angiography; DSA, digital subtraction angiography; mPAP, mean pulmonary artery pressure; PAWP, pulmonary artery wedge pressure; RA, right atrium; RHC, right heart catheterization; RV, right ventricle; TTE, transthoracic echocardiography; V/Q, ventilation/perfusion.

Fig. 3. CTEPH and CTEPD characteristics [12]

This dysfunction causes functional limitations. According to Dzikowska-Diduch O. et al., 34.2% of all symptomatic patients had echocardiographic confirmed diastolic dysfunction [19]. Studying a group of 845 survivors of an episode of pulmonary embolism, right ventricular dysfunction was determined in 17% of patients, which is comparable to the results of a meta-analysis performed by Sista A.K., where RV dysfunction was observed in 18% among patients [2]. If the electrocardiogram and NT-proBNP are within the normal limits, then the probability of relevant echocardiography abnormalities is low. The PEITHO trial, which included 219 survivors who were followed for 3 years after acute intermediate risk pulmonary embolism, demonstrated that 1 out of 7 patients develop chronic thromboembolic pulmonary hypertension or post-PE impairment (PPEI) [20]. Clinical and echocardiographic follow-up 6 months after acute phase may be useful for timely detection of late sequelae [20]. In another study, Stevinson et al. reported that echocardiography at 6 months detected right ventricular abnormalities, including dilatation and hypokinesia in approximately 25% (27/109) of patients, and functional limitation in nine of them [21]. Moreover, 41% of previously healthy patients had abnormal RV parameters on echocardiography or low functional capacity assessed by NYHA score or 6-minute walk test. PEITHO investigators suggested that lack of recovery or incomplete recovery of echocardiographic parameters of RV at 6 months may predict pulmonary hypertension [20]. A mechanism suggestive of subclinical and functional dysfunction of the RV may be right ventricle overload during acute pulmonary embolism [18]. Czurzynski M. et al. found that survivors showed persistent abnormalities of RV function and morphology on echocardiography >1 year after PE, despite normalization of pulmonary artery systolic pressure [22].

The decrease in functional capacity is a complication that has as result the substantial impact on the reduction of the quality of life. In addition to the entities described above, such as dyspnea in chronic thromboembolic pulmonary hypertension and post-pulmonary embolism heart failure, other factors that lead to decreased functional capacity may be considered: anxiety, chest pain, post-thrombotic panic syndrome, and/or depression leading to decreased QoL in post-PE syndrome and general deconditioning [23, 24]. Deconditioning is defined as a loss of physical fitness due to failure to maintain an optimal level of activity or training [25]. Inactivity of any origin can lead to deconditioning, and in the patient with pulmonary embolism, the decrease in functional capacity is obtained by the vicious circle, represented by pain, anxiety, depression, dyspnea, together generating the lack of physical activity [23]. In the prospective ELOPE study, it was suggested for the first time that the deconditioning that occurs after acute pulmonary embolism appears to be the most likely explanation for the limitation of physical activity, mostly impaired circulatory or ventilatory function [1]. Exercise

limitation on 1-month cardiopulmonary exercise test was predictive of worse functional outcome during follow-up, suggesting that identifying exercise-limited patients early after pulmonary embolism is of prognostic value, and that exercise rehabilitation interventions early after pulmonary embolism may have potential to improve long-term functional outcomes [1]. The role of inactivity was also highlighted in a cohort of intermediate- and high-risk pulmonary embolism patients, in which no significant association was found between patient-reported symptoms, pulmonary function, right ventricular dysfunction, and changes from cardiopulmonary testing [26]. Thus, the authors suggest that functional impairment appears to be attributable to general deconditioning rather than intrinsic cardiopulmonary limitation, and rehabilitation plays an important role for improving patient outcomes and quality of life. Other studies have also demonstrated clinical improvement after exercise training, further emphasizing the contribution of deconditioning in post-pulmonary embolism syndrome [27-30].

Mental health problems, such as depression, anxiety and panic syndrome that are related to venous thromboembolism are not negligible, contributing to functional deterioration after pulmonary embolism [23, 31, 32]. Such disorders as anxiety associated with pain could lead to less physical activity, with deconditioning and psychogenic functional limitation [33]. Identifying patients who require psychological counselling and treatment for depression or panic disorders, appears to have an incremental benefit for patients with pulmonary embolism [34].

Evaluation of patients with post-pulmonary embolism syndrome

For the evaluation of patients' symptoms with post-pulmonary embolism syndrome, such as dyspnea, fatigue, pain, decreased quality of life, a series of questionnaires and scores are available, summarized in table 2 [6]. There are two specific questionnaires available for patients with thromboembolic disease, but any available validated score can be used. The PVFS – Post-VTE Functional Status score [35, 36] can be used to assess dyspnea and the PEmb-QoL score (the validated Pulmonary Embolism Quality in Life) can be used to assess quality of life [37].

The PVSF scale is the most used questionnaire for scaling dyspnea in patients with post-PE syndrome. This scale is ordinal, has 6 steps ranging from 0 (no symptoms) to 5 (death, D), and covers the entire range of functional outcomes by focusing on limitations in usual duties/activities either at home or at work/study, as well as changes in lifestyle. The scale grades are intuitive and can easily be grasped by both clinicians and patients.

The post-VTE functional status is intended to be assessed: (1) at the time of discharge after a VTE diagnosis, (2) after 3 months, and (3) optionally after 12 and/or 24 months following a VTE diagnosis to check for recovery and degree of persisting disability. The 3-month follow-up

Table 2. Validated scores and questionnaires for the assessment of subjective data and quality of life in patients with post-pulmonary embolism syndrome

Questionnaire	Parameter
PVFS – Post-VTE Functional Status	Dyspnea
Medical Research Council dyspnea Scale, original or modified (mMRC)	Dyspnea
PROMIS Short Form Dyspnea Severity	Dyspnea
The modified Borg Dyspnea Scale	Dyspnea
the World Health Organization Functional Class	Dyspnea
PEmb-QoL (the validated Pulmonary Embolism Quality in Life)	QoL
QoL PROMs	QoL
PROMIS Short Forms for pain	Pain
The Checklist Individual Strength with fatigue severity	Fatigue
Patient Health Questionnaire– 9	Depression
Generalized Anxiety Disorder-7	Anxiety
Hospital Anxiety and Depression Scale	Depression, anxiety

corresponds to a routine visit performed by the treating physician for determination of the duration of anticoagulant treatment. The last time point is chosen as the functional status is expected to be stabilized in most patients and because it is the optimal moment for considering the presence of severe VTE complications, such as chronic thromboembolic pulmonary hypertension (CTEPH). The persistence of symptoms or an incomplete functional recovery after acute pulmonary embolism should trigger diagnostic tests to rule out CTEPH.

The second questionnaire, the PEmb-QoL (the validated Pulmonary Embolism Quality in Life) score, regards the quality of life of post-PE patients [1, 38]. It was proposed in 2009 and initially it was written in Danish, later translated into English. There are countries that have validated it, such as: China, Germany, France, and their experiences with it have been already published in PubMed. It contains nine subsections with various questions to which the patient must answer [38].

If the patient presents with symptoms and impaired functional status which can be included in the post-PE syndrome, it is a priority to rule out thromboembolic chronic pulmonary hypertension, because its early diagnosis and treatment leads to an improvement in the quality of life and further prognosis [4, 39].

The target population requiring diagnosis for chronic thromboembolic pulmonary hypertension comprises three groups [40-44]:

- Patients with pulmonary embolism and new-onset or progressive dyspnea, exertional dyspnea, oedema, palpitations, syncope, or chest pain;
- Those with a high pretest probability for CTEPH;

➤ Patients with signs of chronic embolism or RV overload on pulmonary angiography at the time of diagnosis of acute pulmonary embolism.

A non-invasive screening algorithm is shown in fig. 4.

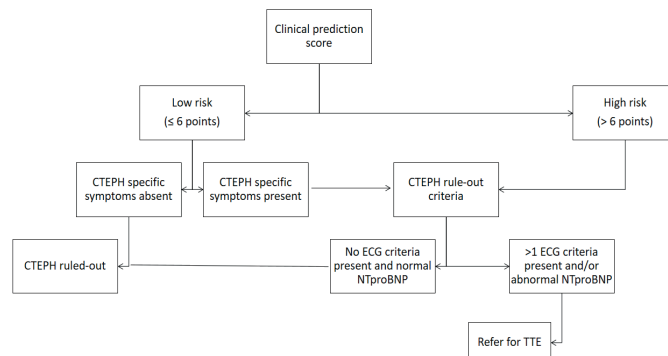


Fig. 4. Non-invasive early exclusion of chronic thromboembolic pulmonary hypertension after acute pulmonary embolism: the InShape II algorithm [6, 45, 46].

CTEPH, chronic thromboembolic pulmonary hypertension, ECG, electrocardiogram, NT-proBNP, N-terminal-prohormone of brain natriuretic peptide, TTE, transthoracic echocardiogram.

The clinical prediction score of chronic pulmonary hypertension after pulmonary embolism identifies patients with a higher risk of developing chronic thromboembolic pulmonary hypertension and was proposed by Klok FA et al. in 2016 [47]. It includes:

- Unprovoked pulmonary embolism +6 points;
- Known hypothyroidism +3 points;
- Onset of symptoms >2 weeks before of pulmonary embolism diagnosed +3 points;
- Right ventricular dysfunction on CT or echocardiography +2 points;
- Known diabetes -3 points;
- Thrombolytic treatment or embolectomy -3 points.

Exclusion criteria (roll-out) of chronic thromboembolic pulmonary hypertension include assessment of NTproBNP and ECG criteria of right ventricular overload. ECG criteria are considered:

- Paternal rSR' or rSr' in V1 derivation;
- R/S>1 in V1 with R wave > 0.5 mV;
- QRS axis > 90°.

If both parameters are normal, chronic thromboembolic pulmonary hypertension is considered excluded [6]. In retrospective studies applying the exclusion criteria of chronic thromboembolic pulmonary hypertension without any additional tests were considered to be safe [48, 49]. If chronic thromboembolic pulmonary hypertension is excluded, the subsequent diagnostic algorithm will be established individually. Diagnostic tests, such as transthoracic echocardiography (if not performed in the previous step), cardiopulmonary stress test, and imaging tests will be performed to assess the presence of persistent perfusion defects and residual clots (fig. 5) [6].

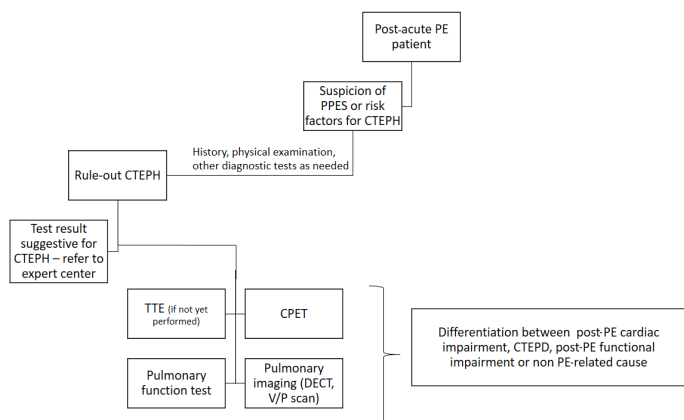


Fig. 5. Flow chart for follow-up 3 months after an acute PE for the detection of PPES

CPET, cardiopulmonary exercise test; CTEPD, chronic thromboembolic pulmonary disease; CTEPH, chronic thromboembolic pulmonary hypertension; DECT, dual-energy computed tomography; PE, pulmonary embolism; PPES, post-pulmonary embolism syndrome; TTE, transthoracic echocardiogram; V/Q, ventilation/perfusion.

Echocardiography can provide us with a series of useful information for the evaluation of patients with dyspnea in post-thrombotic syndrome, first of all, the exclusion of pre-existing causes of dyspnea, such as left ventricular dysfunction established before acute pulmonary embolism event, congenital cardiac anomalies, valvulopathies, etc. In the 2022 ESC guidelines for the diagnosis and management of pulmonary hypertension, a series of echocardiographic parameters are proposed to be used in order to quantify patients with suspected pulmonary hypertension [50]. In addition to conventional echocardiography techniques, the new echocardiographic techniques, such as speckle tracking echocardiography and 3D techniques were proposed. The estimation of pulmonary pressure during exercise can be evaluated, but in most cases an increased pulmonary pressure may be present during exercise as a sign of left ventricle dysfunction. Echocardiographic parameters that can be used in the evaluation of the patient with probable PH [18, 51-53]:

- Increase in LV diameter (RVOT prox) in PLAX >35 mm;
- Dilatation of the right ventricle, VD/LV ratio >1 in apical 4 C;
- D shape of VD PSAX
- Distension of the inferior vena cava >21 mm and reduction of its collapse on inspiration (<50%) – subcostal window;
- Acceleration of RVOT time at the level of the pulmonary valve, >105 msec, PSAX;
- Reduction of LV fractional area <35% – Apical 4 chambers;
- Decrease TAPSE < 17 mm – M mode;
- Decreased velocity of the tricuspid ring (S' <9.5 cm/sec), tissue doppler;
- Increase in AD area > 18 cm² – apical 4 chambers;

- Increasing the maximum velocity of tricuspid regurgitation >2.8 m/s – continuous doppler;
- Estimated sPAP (>28 mmHg) – continuous doppler;
- Severe tricuspid regurgitation – apical 4C;
- VD dyssynchrony >25 msec – speckle tracking echo;
- Decrease in the deformation of the VD free wall <20% – speckle tracking echo;
- Decrease of the RV ejection fraction <45% – 3D echocardiography;
- Pericardial effusion in any sections.

If the echocardiography does not show signs of pulmonary hypertension, the cardiopulmonary exercise test is the next diagnostic step to quantify exercise limitation, but also with the aim of differentiating mechanisms of functional limitation.

If necessary, lung perfusion imaging is performed next. Patients with suspected chronic thromboembolic pulmonary hypertension or chronic thromboembolic disease should be referred to expert centers for specific imaging tests and right heart catheterization. Anemia, cancer and interstitial lung diseases, obstructive lung pathologies or other comorbidities that could cause dyspnea, not being related to the pulmonary embolism episode, should be excluded, and where appropriate, targeted treatment should be indicated [9]. Gleditsch et al. studied 26 survivors of pulmonary embolism evaluated by magnetic resonance imaging (MRI) before and after rehabilitation. In those whose dyspnea improved significantly, no important changes in cardiac parameters were detected on MRI. This fact could suggest the presence of functional dyspnea in some patients with post-pulmonary embolism syndrome [54].

In addition to all of the above, we should not ignore the screening tools for depression and anxiety, which are indicated in selected patients in the post-pulmonary embolism evaluation scheme. If the cause of the physical alteration in a patient after an episode of pulmonary embolism has not been detected, redirection to specialized centers for cardiopulmonary rehabilitation may be useful. Early rehabilitation through physical effort on individual programs would contribute positively to the functional recovery of patients with post-PE syndrome.

Conclusions

After an episode of pulmonary embolism, a large number of patients remain with functional limitations and persistent symptoms. Multiple studies and meta-analyses demonstrated that it is essential to diagnose post-PE syndrome earlier in order to have better long-term outcomes. There are algorithms proposed to objectify the symptoms after an episode of pulmonary embolism and to contribute to the correct and timely selection of patients with post-embolic pulmonary syndrome who require additional evaluations and specialized treatment. Since chronic thromboembolic pulmonary hypertension represents the most severe post-pulmonary embolism complication, earlier detection and treatment of this entity remains a priority.

References

- Kahn SR, Akaberi A, Granton JT, et al. Quality of life, dyspnea, and functional exercise capacity following a first episode of pulmonary embolism: results of the ELOPE cohort study. *Am J Med*. 2017;130(8):990.e9-990.e21. doi: 10.1016/j.amjmed.2017.03.033.
- Sista AK, Miller LE, Kahn SR, Kline JA. Persistent right ventricular dysfunction, functional capacity limitation, exercise intolerance, and quality of life impairment following pulmonary embolism: Systematic review with meta-analysis. *Vasc Med*. 2017;22(1):37-43. doi: 10.1177/1358863X16670250.
- Klok FA, Ageno W, Ay C, Bäck M, Barco S, Bertoletti L, et al. Optimal follow-up after acute pulmonary embolism: a position paper of the European Society of Cardiology Working Group on Pulmonary Circulation and Right Ventricular Function, in collaboration with the European Society of Cardiology Working Group on Atherosclerosis and Vascular Biology, endorsed by the European Respiratory Society. *Eur Heart J*. 2022;43(3):183-189. doi: 10.1093/eurheartj/ehab816.
- Boon GJAM, Huisman MV, Klok FA. Determinants and management of the post-pulmonary embolism syndrome. *Semin Respir Crit Care Med*. 2021;42(2):299-307. doi: 10.1055/S-0041-1722964.
- Le Gal G, Carrier M, Castellucci LA, et al. Development and implementation of common data elements for venous thromboembolism research: on behalf of SSC Subcommittee on official Communication from the SSC of the ISTH. *J Thromb Haemost*. 2021;19(1):297-303. doi: 10.1111/JTH.15138.
- Luijten D, de Jong CMM, Ninaber MK, et al. Post-pulmonary embolism syndrome and functional outcomes after acute pulmonary embolism. *Semin Thromb Hemost*. 2022. doi: 10.1055/s-0042-1749659.
- Klok FA, van der Hulle T, den Exter PL, Lankeit M, Huisman MV, Konstantinides S. The post-PE syndrome: a new concept for chronic complications of pulmonary embolism. *Blood Rev*. 2014;28(6):221-226. doi: 10.1016/J.BLRE.2014.07.003.
- Sista AK, Klok FA. Late outcomes of pulmonary embolism: the post-PE syndrome. *Thromb Res*. 2018;164:157-162. doi: 10.1016/j.thromres.2017.06.017.
- Klok FA, Coutraud F, Delcroix M, Humbert M. Diagnosis of chronic thromboembolic pulmonary hypertension after acute pulmonary embolism. *Eur Respir J*. 2020;55(6):2000189. doi: 10.1183/13993003.00189-2020.
- Pepke-Zaba J, Delcroix M, Lang I, et al. Chronic Thromboembolic Pulmonary Hypertension (CTEPH) : results from an international prospective registry. *Circulation*. 2011;124(18):1973-81. doi: 10.1161/circulationaha.110.015008.
- Kim NH, Delcroix M, Jais X, et al. Chronic thromboembolic pulmonary hypertension. *Eur Respir J*. 2019;53(1):1801915. doi: 10.1183/13993003.01915-2018.
- Lang IM, Campean IA, Sadushi-Kolici R, Badr-Eslam R, Gerages C, Skoro-Sajer N. Chronic thromboembolic disease and chronic thromboembolic pulmonary hypertension. *Clin Chest Med*. 2021;42(1):81-90. doi: 10.1016/J.CCM.2020.11.014.
- Simonneau G, Torbicki A, Dorfmueller P, Kim N. The pathophysiology of chronic thromboembolic pulmonary hypertension. *Eur Respir Rev*. 2017;26(143):160112. doi: 10.1183/16000617.0112-2016.
- Aoki T, Sugimura K, Tatebe S, et al. Comprehensive evaluation of the effectiveness and safety of balloon pulmonary angioplasty for inoperable chronic thrombo-embolic pulmonary hypertension: long-term effects and procedure-related complications. *Eur Heart J*. 2017;38(42):3152-9. doi: 10.1093/eurheartj/ehx530.
- Bryce YC, Perez-Johnston R, Bryce EB, Homayoon B, Santos-Martin EG. Pathophysiology of right ventricular failure in acute pulmonary embolism and chronic thromboembolic pulmonary hypertension: a pictorial essay for the interventional radiologist. *Insights Imaging*. 2019;10(1):1-13. doi: 10.1186/S13244-019-0695-9.
- Remy-Jardin M, Hutt A, Remy J. Chronic thromboembolic pulmonary disease and chronic thromboembolic pulmonary hypertension. *Semin Respir Crit Care Med*. 2022;43(6):936-45. doi: 10.1055/S-0042-1755570.
- Rashidi F, Parvizi R, Bilejani E, Mahmoudian B, Koohi A. Outcome of surgery for chronic thromboembolic pulmonary disease without pulmonary hypertension. *Thorac Cardiovasc Surg*. 2022;70(8):658-62. doi: 10.1055/S-0041-1740560.
- Brittain EL, Hemnes AR, Keebler M, Lawson M, Byrd BF, Disalvo T. Right ventricular plasticity and functional imaging. *Pulm Circ*. 2012;2(3):309-26. doi: 10.4103/2045-8932.101407.
- Dzikowska-Diduch O, Kostrubiec M, Kurnicka K, et al. The post-pulmonary syndrome – results of echocardiographic driven follow-up after acute pulmonary embolism. *Thromb Res*. 2020;186:30-35. doi: 10.1016/j.thromres.2019.12.008.
- Barco S, Russo M, Vicaut E, et al. Incomplete echocardiographic recovery at 6 months predicts long-term sequelae after intermediate-risk pulmonary embolism. A post-hoc analysis of the Pulmonary Embolism Thrombolysis (PEITHO) trial. *Clin Res Cardiol*. 2019;108(7):772-8. doi: 10.1007/S00392-018-1405-1/TABLES/3.
- Stevinson BG, Hernandez-Nino J, Rose G, Kline JA. Echocardiographic and functional cardiopulmonary problems 6 months after first-time pulmonary embolism in previously healthy patients. *Eur Heart J*. 2007;28(20):2517-24. doi: 10.1093/eurheartj/ehm295.
- Ciurzyński M, Kurzyna M, Bochowicz A, et al. Long-term effects of acute pulmonary embolism on echocardiographic doppler indices and functional capacity. *Clin Cardiol*. 2004;27(12):693-7. doi: 10.1002/CLC.4960271207.
- Tavoly M, Wik HS, Sirnes PA, et al. The impact of post-pulmonary embolism syndrome and its possible determinants. *Thromb Res*. 2018;171:84-91. doi: 10.1016/j.thromres.2018.09.048.
- Tavoly M, Asady E, Wik HS, Ghanima W. Measuring quality of life after venous thromboembolism: who, when, and how? *Semin Thromb Hemost*. 2022. doi: 10.1055/S-0042-1754390/ID/JR03011-33.
- The Free Dictionary [Internet]. “deconditioning”. Medical Dictionary, Farlex and Partners, 2009 [cited 2022 Nov 13]. Available from: <https://medical-dictionary.thefreedictionary.com/deconditioning>.
- Albaghdadi MS, Dudzinski DM, Giordano N, et al. Cardiopulmonary exercise testing in patients following massive and submassive pulmonary embolism. *J Am Heart Assoc*. 2018;7(5):e006841. doi: 10.1161/JAHA.117.006841.
- Nopp S, Klok FA, Moik F, et al. Outpatient pulmonary rehabilitation in patients with persisting symptoms after pulmonary embolism. *J Clin Med*. 2020;9(6):1811. doi: 10.3390/JCM9061811.
- Noack F, Schmidt B, Amoury M, et al. Feasibility and safety of rehabilitation after venous thromboembolism. *Vasc Health Risk Manag*. 2015;11:397-401. doi: 10.2147/VHRM.S81411.
- Amoury M, Noack F, Kleeberg K, et al. Prognosis of patients with pulmonary embolism after rehabilitation. *Vasc Health Risk Manag*. 2018;14:183-187. doi: 10.2147/VHRM.S158815.
- Lakoski SG, Savage PD, Berkman AM, et al. The safety and efficacy of early-initiation exercise training after acute venous thromboembolism: a randomized clinical trial. *J Thromb Haemost*. 2015;13(7):1238-44. doi: 10.1111/JTH.12989.
- Kirchberger I, Ruile S, Linseisen J, Haberl S, Meisinger C, Berghaus TM. The lived experience with pulmonary embolism: a qualitative study using focus groups. *Respir Med*. 2020;167:105978. doi: 10.1016/j.rmed.2020.105978.
- Hunter R, Noble S, Lewis S, Bennett P. Long-term psychosocial impact of venous thromboembolism: a qualitative study in the community. *BMJ Open*. 2019;9(2):e024805. doi: 10.1136/BMJOPEN-2018-024805.
- Rolving N, Brocki BC, Andreasen J. Coping with everyday life and physical activity in the aftermath of an acute pulmonary embolism: a qualitative study exploring patients’ perceptions and coping strategies. *Thromb Res*. 2019;182:185-191. doi: 10.1016/j.thromres.2019.06.007.
- Hunter R, Lewis S, Noble S, Rance J, Bennett PD. “Post-thrombotic panic syndrome”: a thematic analysis of the experience of venous thromboembolism. *Br J Health Psychol*. 2017;22(1):8-25. doi: 10.1111/BJHP.12213.
- Klok FA, Barco S, Siegerink B. Measuring functional limitations after venous thromboembolism: a call to action. *Thromb Res*. 2019;178:59-62. doi: 10.1016/j.thromres.2019.04.003.
- Boon GJAM, Barco S, Bertoletti L, et al. Measuring functional limitations after venous thromboembolism: optimization of the Post-VTE Functional Status (PVFS) Scale. *Thromb Res*. 2020;190:45-51. doi: 10.1016/j.thromres.2020.03.020.

37. Cohn DM, Nelis EA, Busweiler LA, Kaptein AA, Middeldorp S. Quality of life after pulmonary embolism: the development of the PEmb-QoL questionnaire. *J Thromb Haemost.* 2009;7(6):1044-6. doi: 10.1111/j.1538-7836.2009.03341.x.
38. Klok FA, Cohn DM, Middeldorp S, et al. Quality of life after pulmonary embolism: validation of the PEmb-QoL Questionnaire. *J Thromb Haemost.* 2010;8(3):523-32. doi: 10.1111/j.1538-7836.2009.03726.x.
39. Boon GJAM, van den Hout WB, Barco S, et al. A model for estimating the health economic impact of earlier diagnosis of chronic thromboembolic pulmonary hypertension. *ERJ Open Res.* 2021;7(3):00719. doi: 10.1183/23120541.00719-2020.
40. Bonderman D, Wilkens H, Wakounig S, et al. Risk factors for chronic thromboembolic pulmonary hypertension. *Eur Respir J.* 2009;33(2):325-31. doi: 10.1183/09031936.00087608.
41. Lang IM, Pesavento R, Bonderman D, Yuan JXJ. Risk factors and basic mechanisms of chronic thromboembolic pulmonary hypertension: a current understanding. *Eur Respir J.* 2013;41(2):462-8. doi: 10.1183/09031936.00049312.
42. Guérin L, Couturaud F, Parent F, et al. Prevalence of chronic thromboembolic pulmonary hypertension after acute pulmonary embolism. *Thromb Haemost.* 2014;112(3):598-605. doi: 10.1160/TH13-07-0538/ID/JR0538-3.
43. Ende-Verhaar YM, Meijboom LJ, Kroft LJM, et al. Usefulness of standard computed tomography pulmonary angiography performed for acute pulmonary embolism for identification of chronic thromboembolic pulmonary hypertension: results of the InShape III study. *J Heart Lung Transplant.* 2019;38(7):731-8. doi: 10.1016/j.healun.2019.03.003.
44. Lachant D, Bach C, Wilson B, et al. Clinical and imaging outcomes after intermediate- or high-risk pulmonary embolus. *Pulm Circ.* 2020;10(3):1-9. doi: 10.1177/2045894020952019.
45. Ende-Verhaar YM, Ruigrok D, Bogaard HJ, et al. Sensitivity of a simple non-invasive screening algorithm for chronic thromboembolic pulmonary hypertension after acute pulmonary embolism. *TH Open.* 2018;2(1):e89-e95. doi: 10.1055/S-0038-1636537.
46. Boon GJAM, Ende-Verhaar YM, Bavalia R, et al. Non-invasive early exclusion of chronic thromboembolic pulmonary hypertension after acute pulmonary embolism: the InShape II study. *Thorax.* 2021;76(10):1002-1009. doi: 10.1136/thoraxjnl-2020-216324.
47. Klok FA, Dzikowska-Diduch O, Kostrubiec M, et al. Derivation of a clinical prediction score for chronic thromboembolic pulmonary hypertension after acute pulmonary embolism. *J Thromb Haemost.* 2016;14(1):121-8. doi: 10.1111/jth.13175.
48. Klok FA, Surie S, Kempf T, et al. A simple non-invasive diagnostic algorithm for ruling out chronic thromboembolic pulmonary hypertension in patients after acute pulmonary embolism. *Thromb Res.* 2011;128(1):21-6. doi: 10.1016/j.thromres.2011.03.004.
49. Klok FA, Tesche C, Rappold L, et al. External validation of a simple non-invasive algorithm to rule out chronic thromboembolic pulmonary hypertension after acute pulmonary embolism. *Thromb Res.* 2015;135(5):796-801. doi: 10.1016/j.thromres.2014.12.009.
50. Humbert M, Kovacs G, Hoeper MM, et al. 2022 ESC/ERS Guidelines for the diagnosis and treatment of pulmonary hypertension. *Eur Heart J.* 2022;43(38):3618-3731. doi: 10.1093/eurheartj/ehac237.
51. Galderisi M, Cosyns B, Edvardsen T, et al. Standardization of adult transthoracic echocardiography reporting in agreement with recent chamber quantification, diastolic function, and heart valve disease recommendations: an expert consensus document of the European Association of Cardiovascular Imaging. *Eur Heart J Cardiovasc Imaging.* 2017;18(12):1301-10. doi: 10.1093/ehjci/jex244.
52. Konstantinides SV, Meyer G, Becattini C, et al. 2019 ESC Guidelines for the diagnosis and management of acute pulmonary embolism developed in collaboration with the European Respiratory Society (ERS). *Eur Respir J.* 2019;54(3):1901647. doi: 10.1183/13993003.01647-2019.
53. Mitchell C, Rahko PS, Blauwet LA, et al. Guidelines for performing a comprehensive transthoracic echocardiographic examination in adults: recommendations from the American Society of Echocardiography. *J Am Soc Echocardiogr.* 2019;32(1):1-64. doi: 10.1016/j.echo.2018.06.004.
54. Gleditsch J, Jervan O, Haukeland-Parker S, et al. Effects of pulmonary rehabilitation on cardiac magnetic resonance parameters in patients with persistent dyspnea following pulmonary embolism. *Int J Cardiol Heart Vasc.* 2022;40:100995. doi: 10.1016/j.ijcha.2022.100995.

Authors' ORCID iDs and academic degrees

Nadejda Diaconu, MD, PhD, Associate Professor – <https://orcid.org/0000-0002-6477-3729>

Irina Civirjic, MD, PhD Applicant – <https://orcid.org/0000-0001-5973-1869>

Galina Sorici, MD, PhD Applicant – <https://orcid.org/0000-0002-1662-1384>

Aurel Grosu, MD, PhD, Professor – <https://orcid.org/0000-0002-2824-2306>

Authors' contributions

ND conceptualized the idea, IC and GS conducted literature review and wrote the manuscript, AG revised critically the manuscript. All the authors approved the final version of the manuscript.

Funding

This research was part of the project No 20.80009.8007.28 "Strategic approach to pulmonary embolism in the pre- and post-hospitalization period in the Republic of Moldova", within the State Program of the Republic of Moldova (2020-2023).

Ethics approval and consent to participate

No approval was required for this study.

Conflict of interests

The authors have no conflict of interests to declare.