

Short Article

A Compound Heterozygous *HPD* Mutation in an Iranian Patient with Hypertyrosinemia Type III

Fatemeh Sarkargar Ph.D., Seyed Ali Madani Manshadi M.Sc., Ehsan Zare Mehrjardi Ph.D., Hosein Khodaei Ph.D., Seyed Mehdi Kalantar Ph.D., Seyed Ahmad Mohamamdi * Ph.D.

Meybod Genetic Research Center, Meybod, Yazd, Iran

ABSTRACT

Article history

Received: 9 Apr 2022

Accepted: 13 Dec 2022

Available online: 31 Dec 2022

Keywords

Hypertyrosinemia

Mutation

Whole exome sequencing

Background and Aims: Hypertyrosinemia type 3 (HT3) is an inherited error in tyrosine metabolism caused by a mutation in the *4-hydroxyphenylpyruvate dioxygenase (HPD)* gene. Here we report a one and half-year-old girl infant who was diagnosed based on increased serum tyrosine levels and increased urinary excretion of p-hydroxyphenyl derivatives.

Materials and Methods: The proband was one and half-year-old Iranian girl who was diagnosed based on increased serum tyrosine levels and increased urinary excretion of p-hydroxyphenyl derivatives. In this study, we used Whole-Exome Sequencing to identify the genetic reason for the disease and the funded mutation confirmed by Sanger sequencing.

Results and Conclusion: Through whole-exome sequencing screening of heterozygotes c.413C>T (p.T138M) and c.75G.A (p.W25Ter) in the *HPD* gene and genetically confirmed by Sanger sequencing. There were heterozygous conditions c.413C>T (p.T138M) and c.75G.A (p.W25Ter) in father and mother respectively. This mutation in her parents was also confirmed by Sanger sequencing.

Introduction

L-Tyrosine is an aromatic amino acid that is required for the protein synthesis of thyroid hormones, catecholamines, and melanin. Tyrosine is only synthesized in plants and microorganisms. Tyrosine in plants as precursor specialized metabolites have various physiological roles as electron carriers, antioxidants, defense compounds, and adsorbents. The biosynthetic and catabolic pathways of L-Tyrosine to animals have been extensively studied. Disorders of tyrosine catabolism cause several acquired and genetic disorders with increasing plasma tyrosine concentrations. Tyrosine degradation occurs in the hepatic and proximal kidney cells, which contain sufficient amounts of all the enzymes required for tyrosine catabolism and produce acetoacetate in a set of five enzymatic reactions [1].

Tyrosinemia is prevalent around the world at a rate of about 1 per 100,000 people, but in some areas, such as the Scandinavian region of the province of Quebec, the prevalence is comparable, which seems to be due to the founding effect. Elevated levels of new blood tyrosine occur in a variety of cases, including transient tyrosinemia neonatal, hereditary neonatal tyrosinemia (Tyrosinemia I), Richner-Honhart syndrome (Tyrosinemia II), and tyrosinemia III. Type I tyrosinemia is the most severe type of the disorder and shows its signs and symptoms in the first few months of life.

Type I tyrosinemia can lead to liver and kidney failure and softening and weakening of

the bones. Children with type I tyrosinemia will not survive more than 10 years [2].

In type II, symptoms often begin in early childhood. Symptoms include pain and redness of the eyes, abnormal sensitivity to light, and thick soles of the feet. Type II tyrosinemia can also affect mental development [3].

The rarest type of tyrosinemia is type III. Symptoms of this type include mental retardation, seizures, and periodic loss of balance and coordination (intermittent ataxia). However, about 10% of newborns have a temporary increase in tyrosine levels (transient tyrosinemia). In these cases, it is not a genetic cause and may be due to a lack of vitamin C or immature liver enzymes due to premature birth [1, 4]. Symptoms of type III tyrosinemia have not been well identified and no correlation has been identified between serum tyrosine levels, clinical phenotype, and type of mutation. As reported in various articles, many patients have neurodevelopmental manifestations, including mental retardation, learning disabilities, attention deficit hyperactivity disorder, behavioral disorder, ataxia, microcephaly, hypotension, and seizures, but the classical phenotype is not described [5].

Materials and Methods

A one and half year-old girl infant presented neonatal hepatitis at birth from a non-consanguineous marriage. This patient has neither mental development nor neurological abnormalities. Liver and kidney function was

normal and without eye and skin lesions. Blood tyrosine levels were measured for the first time in 25 days and its rate was 709 micromoles per liter at 4 months this rate was reported to be 455 micromoles per liter (normal range 88-204 μmol/l). No abnormalities were observed on physical examination. With the informed consent of the parents, the whole exome of the patient was sequenced and genetically confirmed as type 3 hyperthyroidism.

Ten ml of peripheral blood was collected in tubes containing ethylenediaminetetraacetic acid. DNA was isolated from peripheral blood samples using by DNA extraction kit from Qiagen. After DNA extraction, DNA quality and quantity were assessed by UV-spectrophotometry (260 nm and 280 nm) and agarose gel electrophoresis.

Whole exome sequencing was utilized to identify the genetic reason for this disease The whole exome sequencing (WES) was been analyzed and determined of mutation. To aim for re-confirmation, the patient's DNA from the blood sample was extracted along with the parents' blood samples and then amplified with the designed primers shown in Table 1. The product was reciprocated with the same primers. Sequencing was determined and analyzed by the Sanger sequencing method.

Results and Discussion

Using WES in this patient, we identified two mutations c.75G> A p.W25Ter, in exon 3 which is a pathogenic mutation and caused to tryptophan becomes the final code and the protein chain ends. Another mutation was c.413C>T, p.T138M, in exon 7 which is a likely pathogenic and threonine come to methionine, in the *4-hydroxyphenylpyruvate dioxygenase (HPD)* gene (ENST00000289004.8). Those mutations are heterozygous and correspond to the patient's clinical symptoms. Both mutations have autosomal recessive inheritance and were confirmed by Sanger sequencing in the patient and his parents. The pedigree and the results of Sanger sequencing in the patient and her parents are shown in Figure 1.

Hereditary tyrosinemia type III (OMIM 276710) is a rare inherent error in tyrosine metabolism caused by a deficiency of *HPD* as an autosomal recessive inheritance. In general, to date, about 18 cases of the patients have been reported in the literature, and the most common long-term complication in these reports is a mental disorder, which is seen in 75% of patients. A report by Endo et al. identified mild hyperthyroidism in a child and his mother that was accompanied by mild retardation [6].

Table 1. *HPD* gene primers

Gene	Target	Sequence 5'-3'	Tm	Product size
<i>HPD</i>	Exon 3	CTAAGTTCCTGTGGTTGAGGCTG	51.0	343
		AGATAACTTTCCCGCTGGTG	51.0	
	Exon 7	CAAGGGTTCTGGAAGGCTC	51.1	441
		GCTCGTGTGGGAAGTATG	50.9	

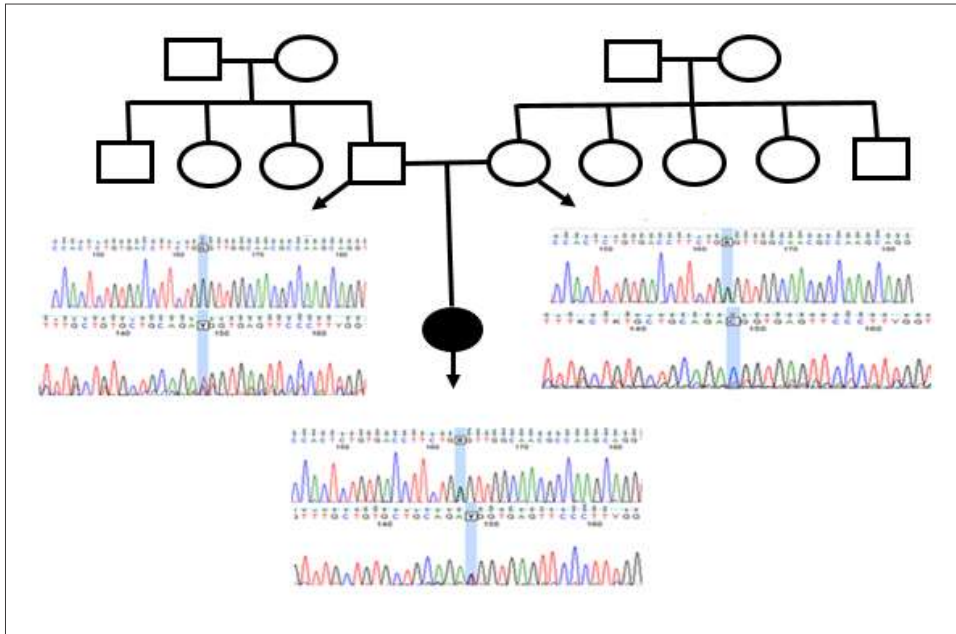


Fig. 1. The patient's pedigree and the results of sanger sequencing in the patient and his parents. The patient's father is normal for variant c.75G> A and shows G, and for variant c.413C> T is heterozygous and her mother for variant c.75G> A is heterozygous and for variant c.413C> T is normal and C have given. The patient inherited both heterozygous alleles from the parents.

Ellaway et al. in 2001 studied 9 patients with tyrosinemia III, which was the most common long-term complication of mental disorder in most patients. Psychomotor retardation and neurological abnormalities were diagnosed in some patients. In all patients, liver and kidney function was normal and no abnormalities were seen in the skin or eyes [7].

In a study by Rüetschi et al. 4-four pathogenic mutations in the *HPD* gene were reported in three unrelated families and one case was compound heterozygous while the rest were homozygous [4].

According to research, 4-HPD is an enzyme that is highly expressed by neutrophils and neurons and participates in the intracellular secretion of nitric oxide (NO) in *Pseudomonas aeruginosa* in a 2009 study by Patrizia D'Eufemia et al. NO was analyzed by

neutrophils in a 30-year-old woman with type III tyrosinemia. It was shown that neutrophils isolated from our patient release much more NO than controls, and given the high expression of the HPD enzyme in neurons, it can be said that they release too much NO and could be a reason for nervous involvement described in patients with type III tyrosinemia [8].

In 2012, Heylen and colleagues report a case of a boy with type III tyrosinemia diagnosed using neonatal screening, which is homozygous for the IVS11 + 1G> A splint mutant in intron 11 of the *HPD* gene. At 30 months of age, was characterized by mild protein restriction with normal growth and psychomotor development [9].

A 2015 report by Szymanska et al. Found that high tyrosine concentrations did not directly

contribute to the neurological damage described in patients with tyrosinemia type III. They are an asymptomatic 11-year-old girl with normal mental development who reported increased urinary excretion of p-hydroxyphenyl derivatives through metabolic screening for HT3 by increasing serum tyrosine levels from 425 to 535 $\mu\text{mol/L}$. Genetically confirmed by altering c.479A> G (p.Tyr160Cys) homozygosity in *HPD* gene. Was referred due to only recurrent proteinuria of unknown cause, and restricted diets with phenylalanine and tyrosine had never been used [10].

In 2021 in a study by Vakili et al., The clinical, biochemical, and molecular characteristics of an Iranian female patient with type III tyrosinemia were investigated and followed up for 7 years. A new type of mutation (c.759+1G>A) was detected in *HPD* (609695) in the homozygous pattern. The patient continued to have normal neuropsychological development, and the recommended diet has not been followed the effect of a low tyrosine diet in this patient which is negligible [11].

Barroso et al. identified a case in 2020 by screening infants for endocrine metabolic disorders and immediately began a low-protein diet with a steady decline in tyrosine levels. By age seven, he has improved slightly in behavior and attention span, and despite maintaining acceptable tyrosine levels, he has

slightly lower cognitive function than his peers. The child's sister, like him, had a history of attention-deficit hyperactivity disorder and was diagnosed with hypertyrosinemia type III after family screening at the age of eight [5].

Najafi and his colleagues (2018) examined a child who was hospitalized at 4 months due to recurrent seizures. Two months later, he was hospitalized again with epilepsy and increase in blood tyrosine levels. He was treated with a diet containing tyrosine. Phenylalanine and the anamix formula led to rapid growth and symptoms improved. Plasma tyrosine levels were reduced to normal values and in this case, the diagnosis of type III tyrosinemia was considered [12].

Conclusion

Considering the existence of two heterozygous alleles in the patient, in which one of the parents has one of the alleles as heterozygous, it seems that the cause of hyperthyroidism in the child is the inheritance of both alleles and compound heterozygous.

Conflict of Interest

The authors declare no potential conflict of interest concerning the research, authorship, and publication of this report.

Acknowledgment

We thank Meybod Genetic charity for supporting the investigation.

References

- [1]. Russo PA, Mitchell GA, Tanguay RM. Tyrosinemia: a review. *Pediatric Develop Pathol.* 2001; 4(3): 212-21.
- [2]. Chinsky JM, Singh R, Ficicioglu C, Van Karnebeek CD, Grompe M, Mitchell G, et al. Diagnosis and treatment of tyrosinemia type I: a US and Canadian consensus group review and

- recommendations. *Genetics in Medicine* 2017; 19(12): 1380-388.
- [3]. Locatelli F, Puzeat E, Arnoux JB, Blanc D, Aubin F. Richner-Hanhart syndrome (tyrosinemia type II). *Cutis* 2017; 100(6): 20-2.
- [4]. Rüetschi U, Cerone R, Pérez-Cerda C, Schiaffino MC, Standing S, Ugarte M, et al. Mutations in the 4-hydroxyphenylpyruvate dioxygenase gene (HPD) in patients with tyrosinemia type III. *Hum genet.* 2000; 106(6): 654-62.
- [5]. Barroso F, Correia J, Bandeira A, Carmona C, Vilarinho L, Almeida M, et al. Tyrosinemia type iii: a case report of siblings and literature review. *Revista Paulista de Pediatria.* 2020; 38.
- [6]. Endo F, Kitano A, Uehara I, Nagata N, Matsuda I, Shinka T, et al. Four-hydroxyphenylpyruvic acid oxidase deficiency with normal fumarylacetoacetase: a new variant form of hereditary hypertyrosinemia. *Pediatr Res.* 1983; 17(2): 92-6.
- [7]. Ellaway C, Holme E, Standing S, Preece M, Green A, Ploechl E, et al. Outcome of tyrosinaemia type III. *J Inherited Metabolic Dis.* 2001; 24(8): 824-32.
- [8]. D'Eufemia P, Finocchiaro R, Celli M, Raccio I, Properzi E, Zicari A. Increased nitric oxide release by neutrophils of a patient with tyrosinemia type III. *Biomedicine Pharmacotherapy* 2009; 63(5): 359-61.
- [9]. Heylen E, Scherer G, Vincent MF, Marie S, Fischer J, Nassogne MC. Tyrosinemia Type III detected via neonatal screening: management and outcome. *Mol Genet Metabol.* 2012; 107(3): 605-607.
- [10]. Szymanska E, Sredzinska M, Ciara E, Piekutowska-Abramczuk D, Ploski R, Rokicki D, et al. Tyrosinemia type III in an asymptomatic girl. *Mol Genet Metabol Rep.* 2015; 5: 48-50.
- [11]. Vakili S, Emami M, Mobini M, Vakili R. Tyrosinemia Type III: A case report with a seven years follow-up. *Int J Pediatr.* 2021; 9(6): 13853-3857.
- [12]. Najafi R, Mostofizadeh N, Hashemipour M. A case of tyrosinemia type III with status epilepticus and mental retardation. *Advanced Biomedical Research* 2018; 7(1): 7.