



doi: 10.4103/2221-6189.374316

jadweb.org

Post–COVID recurrent dyspnoea: A case report

Kiran A. Balani, Tushar R. Sahasrabudhe[✉], M. S. Barthwal*Department of Respiratory Medicine, Dr. D.Y. Patil Medical College, Hospital and Research Center, Dr. D.Y. Patil Vidyapeeth, Pimpri, Pune, India*

ABSTRACT

Rationale: Post-COVID symptoms need aggressive evaluation.

Patient's Concern: A 29-year-old male patient who had suffered from COVID-19 eight weeks earlier, presented with an acute onset of breathlessness and right-sided chest pain due to pneumothorax. Emergency tube thoracostomy was performed. However, it failed to improve hypoxia.

Diagnosis: High-resolution computed tomography of the thorax with computed tomography pulmonary angiography revealed pulmonary arterial thrombosis, ground-glass opacities, and bilateral pneumatoceles.

Interventions: Hospital admission and treatment with low molecular weight heparin at a dose of 1.5 mg/kg every 24 h.

Outcomes: The large pneumatocele showed significant resolution after three months of follow-ups.

Lessons: Being increasingly reported after having a SARS-CoV-2 infection, pneumatocele formation, due to post-COVID lung scarring and late vascular thrombotic events, is a peculiar sequela and can present as acute dyspnoea. Long-term preventive anticoagulants after recovery from COVID-19 are necessary. Breathing exercises during recovery should be done with caution.

KEYWORDS: COVID-19; Pneumothorax; Pneumatocele; Thrombosis; Embolism

1. Introduction

Lung fibrosis is a common sequela of COVID-19[1]. One-way valve-like obstruction of terminal airways due to lung fibrosis can result in pneumatoceles. Large pneumatoceles can rupture resulting in a pneumothorax. Pulmonary thromboembolism frequently complicates COVID-19 due to a hypercoagulable state[2]. Delayed thromboembolism after recovery is however rare. Pulmonary edema due to viral cardiomyopathy or myocardial ischemia is common after

COVID-19 and may cause acute dyspnoea. Secondary bacterial, mycobacterial, or fungal infection is not uncommon after recovery from COVID-19 and can present as an acute illness.

In view of COVID-19-specific sequelae such as late thrombosis, pneumatoceles, pneumothorax, cardiac events, secondary infections, and rare recurrence of COVID-19, evaluating and treating post-COVID acute dyspnoea poses a challenge to clinicians. Hence we report a case of peculiar sequelae of COVID-19 and discuss our intervention methods.

2. Case report

An informed consent was obtained from the patient. A 29-year-old male patient presented with residual post-COVID breathlessness that was worsening for 5 days and a new onset of cough and chest pain. He suffered from a real-time polymerase chain reaction confirmed COVID-19 eight weeks prior and was managed in an intensive care unit with non-invasive ventilation, remdesivir, enoxaparin, and one dose of tocilizumab. His computed tomography (CT) scan during the acute COVID-19 showed bilateral extensive ground-glass opacities and consolidations with a CT severity score of 15/25 (Figure 1). His COVID-19 treatment lasted for three weeks and he was discharged with persistent mild dyspnoea.

[✉]To whom correspondence may be addressed. E-mail: tushar.sahasrabudhe@dpu.edu.in, dr_tushar_s@yahoo.co.in

This is an open access journal, and articles are distributed under the terms of the Creative Commons Attribution-NonCommercial-ShareAlike 4.0 License, which allows others to remix, tweak, and build upon the work non-commercially, as long as appropriate credit is given and the new creations are licensed under the identical terms. For reprints contact: reprints@medknow.com

©2022 Journal of Acute Disease Produced by Wolters Kluwer- Medknow.

How to cite this article: Balani KA, Sahasrabudhe TR, Barthwal MS. Post-COVID recurrent dyspnoea: A case report. J Acute Dis 2023; 12(2): 83–86.

Article history: Received 7 October 2021; Revision 10 March 2022; Accepted 18 April 2022; Available online 26 April 2023

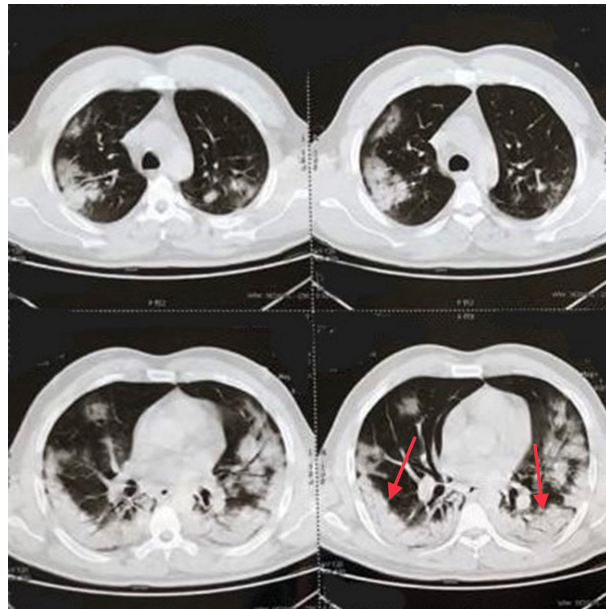


Figure 1. Thoracic CT scan of a 25-year-old male patient during his COVID-19 showing bilateral extensive ground-glass opacities (red arrows).

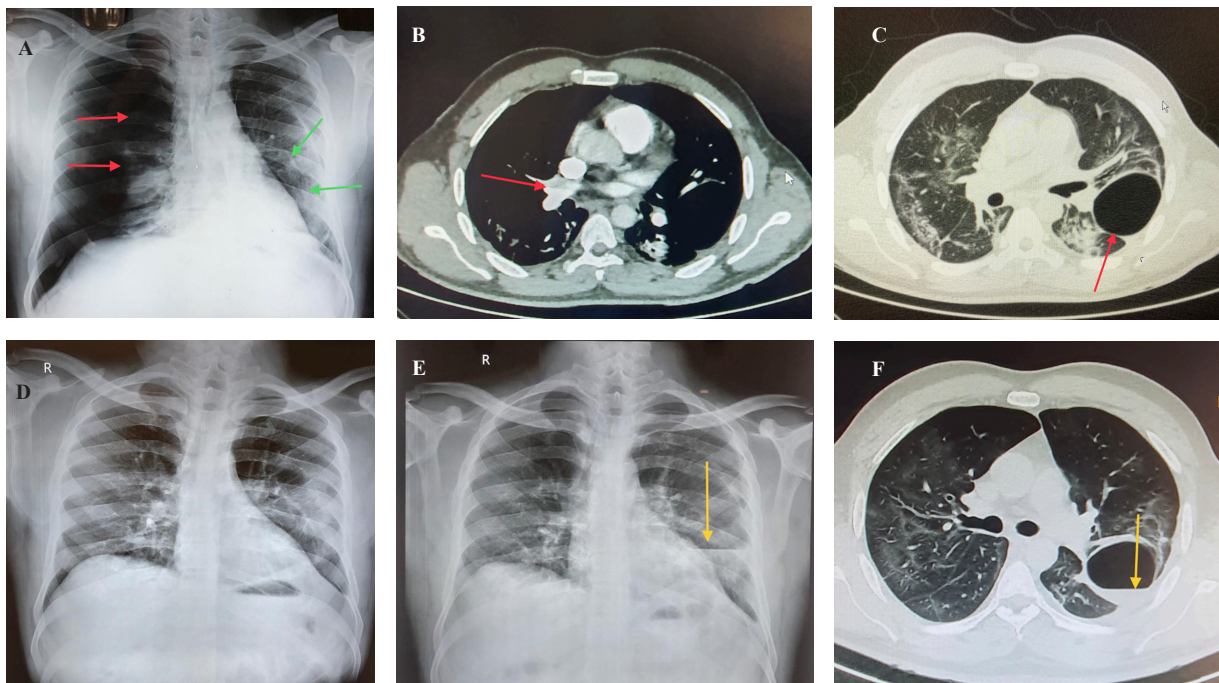


Figure 2. Chest X-ray showing a right-sided pneumothorax (red arrows showing collapsed lung border) and a large left-sided pneumatocele (green arrows showing pneumatocele borders) (A). CT pulmonary angiography done on first hospitalization with us (8 weeks post-COVID) showing thrombus in the right upper lobar pulmonary artery (red arrow) and the segmental arteries of an apical-posterior segment of the right upper lobe (B). High-resolution CT thorax done on first hospitalization with us (8 weeks post-COVID) showing diffuse resolving ground-glass opacities with interlobular septal thickening in both lungs and a large pneumatocele in the left lower lobe (red arrow) (C). Chest X-ray after intercostal tube drainage removal showing complete lung expansion and successful resolution of the pneumothorax (D). Chest X-ray (E) and high-resolution CT thorax showing a left-sided infected pneumatocele with a fluid level at the time of re-hospitalization (yellow arrows) (F).

On examination after the patient was presented to us, his respiratory rate was 32 breaths/min (normal: 12-16 breaths/min), blood pressure was normal (normal: systolic 90-140 and diastolic below 85), SpO₂ was 78% (normal: 98%) and heart rate was 124 beats/min (normal: 60-100 beats/min). Breath sounds were diminished on the right side. Other systemic examination was normal. Some urgent investigations including an electrocardiogram, troponin I test, arterial blood gas analysis, and chest X-ray (Figure 2A) were carried out in an emergency room. Electrocardiogram showed sinus tachycardia without any ischaemic changes, the troponin I test was negative, and arterial blood gas analysis showed acute hypoxemic respiratory failure. Chest X-ray revealed a right-sided pneumothorax and a large left-sided pneumatocele. A tube thoracostomy was done on an emergency basis.

The patient was then shifted to the ward for further management. Routine blood investigations were normal except for a mildly raised D-dimer level (560.22 ng/mL, normal: below 500 ng/mL). With the insertion of an intercostal tube drainage (ICD), the patient's lung expanded almost completely with no bronchopleural fistula. Pleural fluid analysis showed exudative pleural effusion. However, only partial clinical improvement was observed in dyspnoea and hypoxia and he still required oxygen support. Further testing was therefore ordered. Bilateral lower limb venous Doppler examination was normal. Two-dimensional echocardiography showed normal valves, wall motion, and ejection fraction. High-resolution CT thorax with CT pulmonary angiography showed thrombosis in the right upper lobar pulmonary artery and the segmental arteries of posterior segment of the right upper lobe (Figure 2B), diffuse ground-glass opacities with interlobular septal thickening in both lungs, large pneumatocele in the left lower lobe, multiple small pneumatoceles in the right lung and resolving pneumothorax with ICD *in situ* (Figure 2C).

He was treated with enoxaparin 60 mg twice daily and was later switched to oral anticoagulants (rivaroxaban). He was strongly discouraged from doing deep breathing exercises and incentive spirometry that he was doing since his recovery from COVID-19, which could have triggered the rupture of one of the pneumatoceles. He responded well to the treatment over the next 10 days. Oxygen requirement gradually dropped and oxygen support was no longer required at the time of discharge. ICD was removed after complete lung expansion (Figure 2D) and he was discharged on rivaroxaban. Regular follow-ups found that the left pneumatocele was gradually getting absorbed.

One month after the discharge, the patient developed acute breathlessness along with high-grade fever and cough. He was hospitalized again. His repeat high-resolution CT thorax showed significant resolution of lower lobe fibrosis. However, the left lung bulla now showed a fluid level suggesting a secondary infection with a communicating bronchus (Figures 2E and 2F). He was given intravenous antibiotics as per the culture sensitivity pattern and after ruling out the presence of any fungal elements as the cases of

mucormycosis were a rising trend in the country then. He responded well and was discharged after one week. On further follow-up, he was recovering well with no symptoms.

3. Discussion

COVID-19 is known to cause damages to the lungs, heart, and vascular endothelium[3] and complications may emerge even a few months after recovery. Delayed vascular events are also being increasingly reported and therefore the trend of continuing anticoagulants for a longer duration after recovery from COVID-19 is on the rise[4]. Post-COVID lung fibrosis cripples patients and antifibrotics are also being prescribed with variable responses[5]. As the management of COVID-19 is getting standardized, focus is gradually shifting to post-COVID sequelae as the cumulative number of COVID-19 survivors rises all over the world. Pneumatocele formation and pneumothorax are two of the sequelae of COVID-19 and the interest of this report will be discussed in the following section.

Pneumatoceles are air-filled lung cysts that occur when bronchial injury or inflammation creates a check-valve mechanism for air to enter the lung parenchyma. Common causes include pneumonia, blunt thoracic trauma, chronic obstructive pulmonary disease, and aspiration[6]. Pneumatoceles can complicate the course of the disease by rupture, tension, or infection, which may present acutely and require prompt management.

Pneumothorax is more common in patients requiring high-flow nasal oxygen, non-invasive ventilation, or invasive ventilation. Pneumothorax after recovery from COVID-19 is uncommon but is being reported and the most mentioned cause is the rupture of pneumatoceles. There is an increasing trend to start deep breathing exercises and pranayama, a yogic practice that focuses on breathing, during COVID-19 recovery. This is usually started with the intention of early rehabilitation. In our observation, patients are doing breathing exercises while their lungs are still inflamed and weak with scars, predisposing them to barotrauma and pneumothorax. Further studies are warranted to decide the appropriate time for pulmonary rehabilitation. Patients who are at higher risk of pneumothorax should be identified and should be discouraged from doing aggressive breathing exercises.

There is a high reliance on D-dimer levels for determining the presence of intravascular thrombi. However, a high index of suspicion is more important[2,7]. As endothelial injury in COVID-19 may not heal completely for a few weeks, the risk of thromboembolism persists for a much longer time. Duration of prophylactic blood thinners needs to be established. The risk of secondary infection in post-COVID fibrotic lungs is always a concern and should be considered if the patient develops acute dyspnoea, fever, or a new radiological shadow[8-10].

In conclusion, pneumatoceles secondary to lung fibrosis is a

potential risk factor for pneumothorax. Such patients should avoid deep breathing exercises. Late onset of pulmonary arterial thrombosis is uncommon after having COVID-19, but the duration of prophylactic oral anticoagulants needs to be established. Post-COVID secondary infections should be suspected early.

Conflict of interest statement

The authors report no conflict of interest.

Funding

This study received no extramural funding.

Authors' contributions

KAB and TRS performed literature search, conducted the study, prepared and edited the manuscript. All authors developed the concept, designed, and defined the intellectual content of the study, as well as acquired data and reviewed the manuscript.

References

- [1] Udhwadia ZF, Pokhariyal PK, Tripathi AK, Kohli A. Fibrotic interstitial lung disease occurring as sequelae of COVID-19 pneumonia despite concomitant steroids. *Lung India* 2021; **38**: S61-S63.
- [2] Ooi MW, Rajai A, Patel R, Gerova N, Godhamgaonkar V, Liang SY. Pulmonary thromboembolic disease in COVID-19 patients on CT pulmonary

angiography-Prevalence, pattern of disease and relationship to D-dimer. *Eur J Radiol* 2020; **132**: 109336.

- [3] Madjid M, Safavi-Naeini P, Solomon SD, Vardeny O. Potential effects of coronaviruses on the cardiovascular system: A review. *JAMA Cardiol* 2020; **5**(7): 831-840.
- [4] Chandra A, Chakraborty U, Ghosh S, Dasgupta S. Anticoagulation in COVID-19: Current concepts and controversies. *Postgrad Med J* 2022; **98**(1159): 395-402.
- [5] George PM, Wells AU, Jenkins RG. Pulmonary fibrosis and COVID-19: The potential role for antifibrotic therapy. *Lancet Respir Med* 2020; **8**(8): 807-815.
- [6] Batubara EA, Amanda C, Sinambela P, Triweda R, Setiawan JI. COVID-19 patient associated with rare pneumatocele finding: CT features and case report. *Asian J Case Rep Med Health* 2020; **4**(1): 1-5.
- [7] Mouhat B, Besutti M, Bouiller K, Grillet F, Monnin C, Ecarnot F, et al. Elevated D-dimers and lack of anticoagulation predict PE in severe COVID-19 patients. *Eur Respir J* 2020; **56**(4): 2001811.
- [8] Chennamchetty VK, Adimulapu S, Kola BP, Padua MD, Ambika C, Verma MK, Rao MV. Post-COVID pulmonary mucormycosis- A case report. *IP Indian J Immunol Respir Med* 2021; **6**(1): 62-66.
- [9] Zahid A, Iqbal N, Moeen S, Irfan M. Post COVID-19 tuberculosis: An emerging threat of pandemic. *Monaldi Arch Chest Dis* 2021; **91**(3). doi: 10.4081/monaldi.2021.1749.
- [10] Kakamad FH, Mahmood SO, Rahim HM, Abdulla BA, Abdullah HO, Othman S, et al. Post COVID-19 invasive pulmonary aspergillosis: A case report. *Int J Surg Case Rep* 2021; **82**: 105865.

Publisher's note

The Publisher of the *Journal* remains neutral with regard to jurisdictional claims in published maps and institutional affiliations.