



# Incidental Appendiceal Neuroendocrine Tumors (NETs): A Case Report and Review Of Literature

Peerawitch Petchmak MD<sup>1\*</sup>

Punnawat Chandrachamnong MD<sup>2</sup>

<sup>1</sup> Department of Surgery, Nakhon Nayok Hospital, Nakhon Nayok, Thailand

<sup>2</sup> Colorectal Surgery Unit, Department of Surgery, Faculty of Medicine Vajira Hospital, Navamindradhiraj University, Bangkok, Thailand

\* Corresponding author, e-mail address: peet\_154@hotmail.com

Vajira Med J. 2022; 66(3): 229-36

<http://dx.doi.org/10.14456/vmj.2022.23>

## Abstract

Incidental appendiceal neuroendocrine tumors (NETs) are rare and mostly asymptomatic or come with clinically suspected appendicitis. Although, there is a various review of literatures and consensus guidelines, there has been controversy in the management of tumor size 1-2 cm or grading G2 – G3 according to mitotic count (mitoses/10 HPF) or Ki-67. A 20-year-old female presented to the emergency department with acute right lower quadrant abdominal pain with an onset of 2 hours. The presumed clinical diagnosis was acute appendicitis. She underwent an open appendectomy and the histopathologic result of the specimen showed a neuroendocrine tumor of the appendix. It was a controversial decision since it was a well-differentiated tumor of <1 cm as well as G2 at the distal half of the appendix, which made it a challenging surgery. The patient was informed and computer tomography (CT) scan and colonoscopy was done for further evaluation. Discussion of whether a right-hemicolectomy or single appendectomy was proposed to the patient, finally a right hemicolectomy was performed. However, more studies should be conducted to determine the optimal management and follow-up strategy for situations like this.

**Keywords:** appendix, appendicitis, appendiceal neuroendocrine tumors, carcinoid tumors, NET G2



# กรณีศึกษามะเร็งของไส้ติ่งชนิดต่อมไร้ท่อ หรือ Neuroendocrine Tumors และทบทวนวรรณกรรม

พีรวิชญ์ เพ็ชรมาก พ.บ.<sup>1\*</sup>

ปณวัฒน์ จันทรวงศ์ พ.บ.<sup>2</sup>

<sup>1</sup> กลุ่มงานศัลยกรรม โรงพยาบาลนครนายก นครนายก ประเทศไทย

<sup>2</sup> ศัลยศาสตร์ลำไส้ใหญ่และทวารหนัก ภาควิชาศัลยกรรม คณะแพทยศาสตร์วชิรพยาบาล มหาวิทยาลัยนวมินทราธิราช กรุงเทพมหานคร ประเทศไทย

\* ผู้ติดต่อ, อีเมล: peet\_154@hotmail.com

Vajira Med J. 2022; 66(3): 229-36

<http://dx.doi.org/10.14456/vmj.2022.23>

## บทคัดย่อ

อุบัติการณ์โรคมะเร็งไส้ติ่งชนิดต่อมไร้ท่อหรือ Neuroendocrine Tumors (NETs) พบได้ยาก และส่วนใหญ่ มักไม่มีอาการหรือมาห้องฉุกเฉินด้วยอาการสงสัยภาวะไส้ติ่งอักเสบ ถึงแม้ว่าจะมีทบทวนวรรณกรรม หรือแนวทางการรักษาหลากหลาย แต่ยังคงมีข้อถกเถียงเรื่องการรักษามะเร็ง NETs ที่มีขนาด 1 – 2 เซนติเมตร หรือการเจริญของเซลล์ (Mitotic count และ Ki-67) ระยะ 2 – 3 กรณีศึกษาเป็นผู้ป่วยหญิงอายุ 20 ปี มาห้องฉุกเฉินด้วยอาการปวดท้อง ข้างขวาล่าง 2 ชั่วโมงก่อนมาโรงพยาบาล หลังจากการซักประวัติและตรวจร่างกายได้รับการวินิจฉัยเป็นไส้ติ่งอักเสบ ผู้ป่วยจึงได้เข้ารับการผ่าตัดไส้ติ่ง และผลชิ้นเนื้อเป็นมะเร็งไส้ติ่งชนิด NETs ที่มีขนาดน้อยกว่า 1 เซนติเมตร ระยะการเจริญของเซลล์ระยะ 2 และอยู่ส่วนปลายของไส้ติ่ง ทำให้การตัดสินใจเป็นไปได้หลายทาง โดยยังไม่มีแนวทางการรักษา มาตรฐานกำหนด ผู้ป่วยได้รับการเอกซเรย์คอมพิวเตอร์และส่องกล้องลำไส้ใหญ่ หลังจากปรึกษาข้อดีข้อเสีย ของการรักษา ผู้ป่วยได้รับการผ่าตัดชนิดลำไส้ใหญ่ฝั่งขวา (right hemicolectomy) อย่างไรก็ตามต้องอาศัย หลายการศึกษาเพื่อกำหนดแนวทางในการรักษาในปัจจุบันที่มีข้อถกเถียงต่อไป

**คำสำคัญ:** ไส้ติ่ง ไส้ติ่งอักเสบ มะเร็งไส้ติ่งชนิดต่อมไร้ท่อ มะเร็งต่อมไร้ท่อ มะเร็งต่อมไร้ท่อเกรด 2

## Introduction

Neoplasms of the appendix present in appendectomy specimens in less than 1%<sup>1</sup> and an incidence rate of approximately 0.15 per 100,000 per year in the SEER database<sup>2</sup>. Appendiceal carcinoid tumors and appendiceal adenomas are the most common lesions identified. The term “carcinoid” was first described in 1907 to describe the small benign carcinomas of the small intestine<sup>4</sup>. The term carcinoid was later replaced by neuroendocrine tumors. Appendiceal Neuroendocrine tumors (NETs) are neoplasms of the appendiceal sub-epithelial neuroendocrine cells<sup>4</sup>; the majority of which are benign and rarely metastasize. NET comprises the most common neoplasm of the appendix<sup>5</sup>. Within the gastrointestinal tract, most NETs occurred in the small intestine (41.8%), rectum (27.4%), and stomach (8.7%). For all sites, age-adjusted incidence rates were highest in black males (4.48 per 100,000 population per year). Associated non-NETs were frequent in conjunction with small intestinal (29.0%), gastric (20.5%), colonic (20.0%), and appendiceal (18.2%) NETs<sup>4</sup>.

The clinical presentation of appendiceal neuro-endocrine tumor lesions is often similar to that of acute appendicitis, or the tumors are asymptomatic<sup>5</sup>. The NETs are commonly found incidentally during the histopathological examination of the resected appendix following appendectomy or other abdominal procedures. Appendiceal NETs usually behave as benign tumors and appendectomy alone is sufficient treatment in the majority of the cases, while for larger lesions, right hemi-colectomy should be performed. The prognosis of the majority of the appendiceal NETs is excellent in the series that report outcomes on limited tumor stages with the 5-year survival rate of 100% or close to this<sup>6-7</sup>.

European Neuroendocrine Tumor Society (ENETS) Consensus Guidelines for the management of patients with neuroendocrine neoplasms from the jejunum-ileum and the appendix including goblet cell carcinomas<sup>8</sup> concluded that an appendiceal

NETs with a size of  $\leq 1$  cm, with invasion up to the subserosa or mesoappendiceal invasion up to 3 mm, and clear surgical margins, poses no further risk of recurrence after appendectomy. Most tumors (70%) are located at the tip of the appendix. However, tumors at the base of the appendix, tumors  $> 2$  cm, deep mesoappendiceal invasion, or margin invasion, confer a relevant risk of recurrence<sup>8</sup>. Therefore, further surgical procedures are warranted, although no data have proven a survival benefit of more aggressive surgery.

Another criterion to define a surgical approach in patients with tumors between 1 and 2 cm is Ki-67. When Ki-67  $> 3\%$ , there is indication for right hemicolectomy. There is insufficient evidence to demonstrate that Ki-67 is a prognostic factor in well differentiated NETs. It is also equally important to evaluate the mitotic index in the histopathological evaluation of tumors included in this group<sup>9</sup>.

Additional ENETS Consensus stated that right hemicolectomy is justified only in appendiceal NETs 1–2 cm but with positive or unclear margins or with deep mesoappendiceal invasion (ENETS T2), higher proliferation rate (G2) and/or angioinvasion. The challenge here is well-differentiated tumors of 1–2 cm and R0 resection since there is no sufficient data for a clear-cut decision.

## Presentation of case

A 20-year-old female patient presented to our emergency department with a chief complaint of acute right lower quadrant abdominal (RLQ) pain with 2 hours of evolution. She was anorexic and presented with epigastric abdominal pain migrating to the right lower quadrant. She had no nausea, chills, fever or gynecologic symptoms. She had no other significantly relevant past medical history.

She was agitated with a body temperature of 36 celsius, hemodynamically stable, and showed no sign of respiratory distress during physical examination. Abdominal examination revealed tenderness in the RLQ without rebound tenderness.

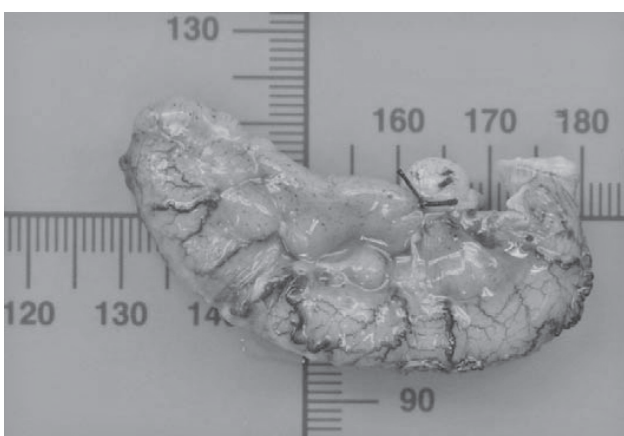Laboratory tests were performed, yielding the following results: hemoglobin level 11.2 g/dL, hematocrit level 35%, white blood cell count 11,940 cells/ $\mu$ L, neutrophil proportion 75.2%, lymphocyte 18%, platelet count 429,000 cells/ $\mu$ L, normal electrolytes, and creatinine of 0.65 mg/dL.

Clinical history, physical examination, and Alvarado score of 7 points for acute appendicitis, concluded the findings consistent with appendicitis. In World Society of Emergency Surgery (WSES) Jerusalem guidelines<sup>10,11</sup>, if the patient's clinical presentation is consistent with appendicitis, there is no need for further investigation by ultrasound or computerized tomography scan. The patient underwent open appendectomy. Intraoperatively, an acute inflammatory appendicitis of retrocecal type was diagnosed. The resection of the appendix was completed. The patient completed antibiotics for 24 hours and was discharged 1 day after without any complications.

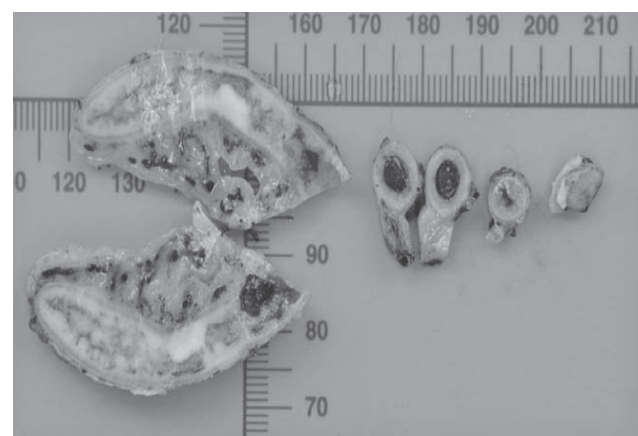
The histopathological examination of the specimen (figure 1, 2) showed consists of a vermiform appendix, measuring 6.7 cm in length and 0.8-1.2 cm in diameter. The serosa is congested and partially covered with exudate. The mucosa is light brown and shows a rubbery ill-defined yellow area of 0.9x0.5x0.5 cm, located 2.7 cm from

the resection margin. The lumen contains dark brown material. Histology showed well-differentiated neuroendocrine tumor, G2 at distal half of appendix invading muscularis propria without involved resection margin and lymphovascular invasion with acute suppurative appendicitis. Tumor was 9 mm in size and mitotic figures 0.68 per 2 square millimeters. The Ki67 index 3.2% (G2). The patient was doing well on routine follow-up in the out-patient department.

A multidisciplinary team with radiology, oncology, and general surgery, using teleconference program, reviewed this case and decided for further treatment. The patient went for computer tomography (CT) scan of whole abdomen with contrast and revealed (figure 3) circumferential wall thickening at ascending colon and cecum with focal fat stranding at pelvic cavity, possibly inflammation and without any metastasis of the lesion. The patient was informed and decided to complete colonoscopy after CT scan. The patient underwent colonoscopy (figure 4) and it revealed mucosal swelling at the ascending colon but other parts of the colon and rectum were normal. The tissue was biopsied and sent to pathology, which reported active colitis without granuloma and malignancy consistent with the clinical finding.



**Figure 1:** Gross pathology of appendix of these patient



**Figure 2:** Gross pathology of appendix of these patient (Cross section)

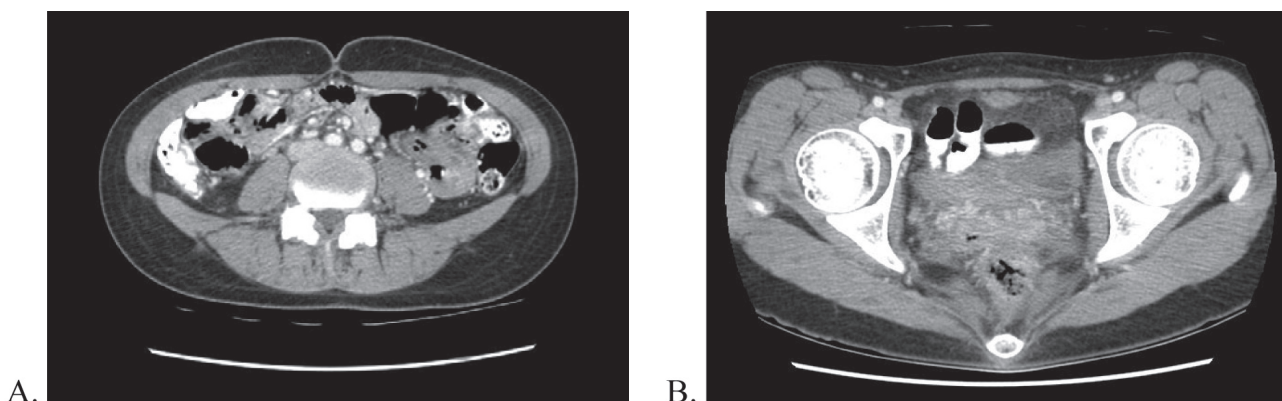


Figure 3: CT scan shown (A) circumferential wall thickening at ascending colon and cecum with (B) focal fat stranding at pelvis cavity

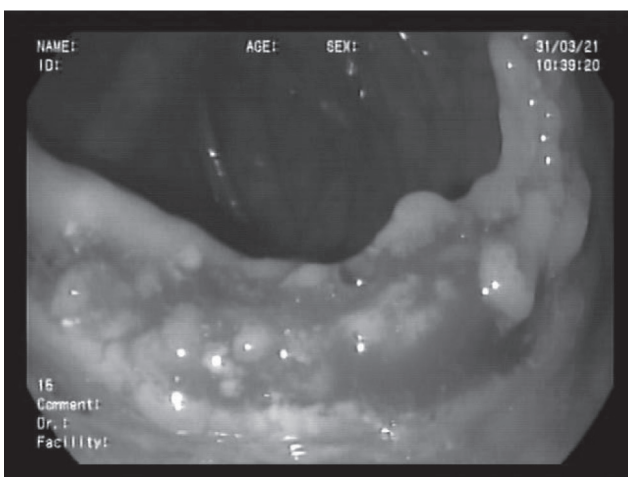
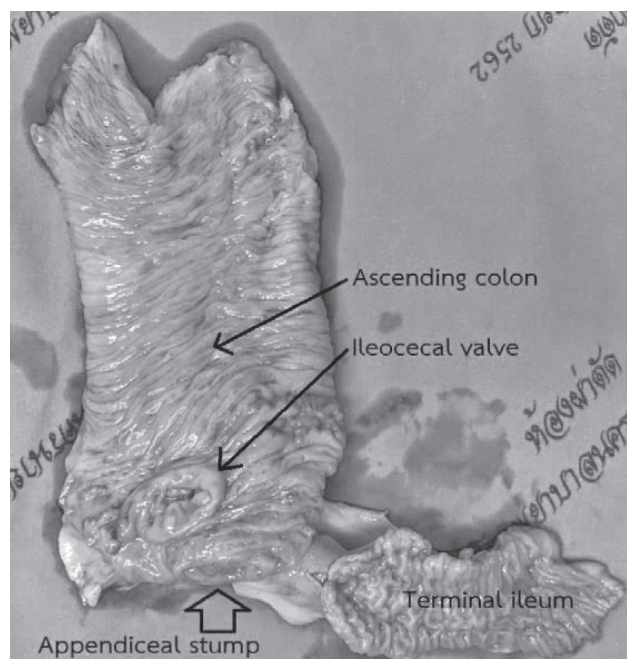


Figure 4: colonoscopy of ascending colon of the patient

ulceration of the cecum and necrotizing granulomatous lymphadenitis, 12 out of 38 regional lymph nodes. Special stains for fungi and acid-fast bacilli were negative. The ileum, appendiceal stump, and ascending colon were unremarkable. Real-time PCR for Mycobacterium tuberculosis complex was performed from paraffin-embedded blocks and revealed negative result.

The patient was informed of all the data including the risk of metastasis or recurrence rate. The patient decided to go on with right hemicolectomy. Therefore, the patient was scheduled for an elective right hemicolectomy. Intraoperatively (figure 5), normal right-side colon with good appendiceal-stump without any gross mass or metastatic lesion was diagnosed. The patient completed observation for postoperative complications, given pain killers, and was discharged after 6 days without any complications.



The histopathological examination of the specimen revealed necrotizing granulomatous inflammation with focal mucosal necrosis and

Figure 5: Gross-specimen of right hemi-colectomy of these patient

## Discussion

Our patient came in complaining of a typical presentation of appendicitis and an uneventful open appendectomy, where an incidental G2, well-differentiated NET was discovered on histopathological examination. There were no classical symptoms specifically attributed to appendiceal NETs. The most common presentation of these neoplasms is acute appendicitis (54%), which can result from obstruction of the appendiceal lumen by the tumor (25%)<sup>12</sup>. Infrequently, appendiceal NETs can present as a vague abdominal pain located in the right lower quadrant as a result of incomplete or periodic obstruction of the lumen<sup>13-15</sup>. Carcinoid syndrome is a much rarer consequence of appendiceal NETs, which appears after distant metastasis have developed, similar to the other gastrointestinal NETs cases.

After the histopathological diagnosis of an appendiceal neuroendocrine tumor, many parameters have to be taken into account for the

distinction of tumors with a mild clinical course from those with a more aggressive potential carrying a higher risk for locoregional relapse and distant metastasis. These include the tumor size and its exact location, as well as the extent of infiltration of the appendix wall or possible vascular invasion (table 1)<sup>12</sup>.

Currently there are two classifications, the one presented by ENETS<sup>12</sup> and the one by the American Joint Committee on Cancer (AJCC). Surgery is the only curative treatment for neuroendocrine tumors, being incurable when there is unresectable metastatic disease<sup>9</sup>.

In this clinical case, the tumor was located at distal half of the appendix, size < 1 cm in diameter (T1a according to UICC/AJCC according to ENETS) and 3-20% of Ki-67 labeling index defined as G2 according to the WHO criteria. If there is histologic grade of G2, lymphovascular invasion and/or mesoappendiceal infiltration > 3 mm, it is recommended to discuss right-hemicolectomy with patients particularly<sup>16-18</sup>.

**Table 1:**

Prognostic factors of appendiceal neuroendocrine neoplasms<sup>12</sup>

Factor	Comments
1 Size	
< 1 cm	Most common; 100% survival post-appendectomy.
1 – 2 cm	5-25% of appendiceal NETs; rarely accompanied with lymph node metastasis, especially if >1.5 cm
2 cm	<10% of appendiceal NETs. Up to 40% risk for systematic dissemination
2 Location	
Tip of the appendix	Most common location (60-75%)
Body of the appendix	Frequency 5-20%
Base of the appendix	Frequency <10%. Associated with higher risk for R1 or R2 tumor resection
3 Mesoappendiceal invasion >3 mm	Higher risk of vascular or lymphatic invasion. More aggressive neoplasm
4 Proliferative rate Ki-67 index >2%	Higher metastatic potential; increased risk for lymph node disease and for vascular or perineural infiltration

According to ENET consensus guidelines<sup>10</sup>, cross-sectional imaging using CT or MRI with modern protocols should be used to rule out locoregional or distant metastasis. Endoscopy is rarely helpful unless the tumor is locally advanced and infiltrates the caecum, which is a very rare situation, and therefore routine colonoscopy for tumor detection is not recommended. In the context of the potentially increased incidence of secondary neoplasms, general recommendations regarding colorectal cancer screening should be followed. ENETS Consensus Guidelines concluded no clear data for well-differentiated tumors of 1 to 2 cm and R0 resection, but a single CT or MRI of the abdomen to rule out lymph node or distant involvement is justified.

## Conclusion

We present the case of a 20-year-old female that complained about clinical diagnosis of appendicitis. The histopathology examination reveals a 9-mm well-differentiated neuroendocrine tumor, histologic grade G2 at distal half of the appendix. The tumor invades the muscularis propria, but is uninvolved in the resection margin. The management of appendiceal NETs is still controversial; especially tumor size is less than 2 cm. In addition, tumors with prognostic factors depend on histopathologic examination. This case presents dilemma management for appendiceal NETs, including surgical management, follow-up surveillance, and recurrence rate.

## Conflict of interest

The authors declare no competing interests.

## Acknowledgments

The authors thank Miss Nikita Dubey for her manuscript English editing and the staff of the Colorectal Surgery Unit, Department of surgery, Faculty of Medicine Vajira Hospital, Navamindradhiraj University for their support.

## References

1. Liang MK, Andersson RE, Jaffe BM, Berger DH. The Appendix. In: Brunicaardi F, Andersen DK, Billiar TR, Dunn DL, Hunter JG, Matthews JB, Pollock RE, editors. *Schwartz's Principles of Surgery*. 10<sup>th</sup> ed. McGraw Hill; 2015. P 1257-9.
2. Yao JC, Hassan M, Phan A, Dagohoy C, Leary C, Mares JE, et al. One hundred years after "carcinoid": epidemiology of and prognostic factors for neuroendocrine tumors in 35,825 cases in the United States. *J Clin Oncol* 2008;26(18): 3063-72.
3. Griniatsos J, Michail O. Appendiceal neuroendocrine tumors: recent insights and clinical implications. *World J Gastrointest Oncol* 2010;2(4):192-6.
4. Modlin IM, Lye KD, Kidd M. A 5-decade analysis of 13,715 carcinoid tumors. *Cancer* 2003;97(4): 934-59.
5. Gu Y, Wang N, Xu H. Carcinoid tumor of the appendix: A case report. *Oncol Lett* 2015;9(5): 2401-3.
6. Quaedvlieg PF, Visser O, Lamers CB, Janssen-Heijen ML, Taal BG. Epidemiology and survival in patients with carcinoid disease in The Netherlands. An epidemiological study with 2391 patients. *Ann Oncol* 2001;12(9):1295-300.
7. Garcia-Carbonero R, Capdevila J, Crespo-Herrero G, Díaz-Pérez JA, Martínez Del Prado MP, Alonso Orduña V, et al. Incidence, patterns of care and prognostic factors for outcome of gastroenteropancreatic neuroendocrine tumors (GEP-NETs): results from the National Cancer Registry of Spain (RGETNE). *Ann Oncol* 2010; 21(9):1794-803.
8. Pape UF, Niederle B, Costa F, Gross D, Kelestimur F, Kianmanesh R, et al. ENETS Consensus Guidelines for Neuroendocrine Neoplasms of the Appendix (Excluding Goblet Cell Carcinomas). *Neuroendocrinology* 2016;103(2): 144-52.
9. Rui Pedro Neto da Silva Abreu. Appendiceal neuroendocrine tumors: approach and treatment. *j coloproctol (rio j)* 2018;38(4):337-42.

10. Royal College of Surgeons of Thailand. Clinical Practice Guideline in Surgery: Appendicitis [internet]. [cited 2021 Sep 01]. Available from: <https://www.rcst.or.th/web-upload/filecenter/CPG/Appendicitis.html>.
11. Di Saverio S, Podda M, De Simone B, Ceresoli M, Augustin G, Gori A, et al. Diagnosis and treatment of acute appendicitis: 2020 update of the WSES Jerusalem guidelines. *World J Emerg Surg* 2020;15:27. doi: 10.1186/s13017-020-00306-3.
12. Moris D, Tsilimigras DI, Vagios S, Ntanasis-Stathopoulos I, Karachaliou GS, Papalampros A, et al. Neuroendocrine Neoplasms of the Appendix: A Review of the Literature. *Anticancer Res* 2018 ;38(2):601-11.
13. Prommegger R, Obrist P, Ensinger C, Profanter C, Mittermair R, Hager J. Retrospective evaluation of carcinoid tumors of the appendix in children. *World J Surg* 2002;26(12):1489-92.
14. O'Donnell ME, Carson J, Garstin WI. Surgical treatment of malignant carcinoid tumours of the appendix. *Int J Clin Pract* 2007;61(3):431-7.
15. Doede T, Foss HD, Waldschmidt J. Carcinoid tumors of the appendix in children—epidemiology, clinical aspects and procedure. *Eur J Pediatr Surg* 2000;10(6):372-7.
16. Morais C, Silva E, Brandão PN, Correia R, Foreid S, Valente V. Neuroendocrine tumor of the appendix—a case report and review of the literature. *J Surg Case Rep* 2019;2019(3):rjz086.doi:10.1093/jscr/rjz086
17. Elkbuli A, Sanchez C, McKenney M, Boneva D. Incidental neuro-endocrine tumor of the appendix: Case report and literature review. *Ann Med Surg (Lond)* 2019;43:44-7.
18. Sana L, Saber M. Incidental neuroendocrine tumor of the appendiceal base less than 20 mm in diameter: is appendectomy enough? *Pan Afr Med J* 2015;22:102. doi: 10.11604/pamj.2015.22.102.6548.