

## Original Study

# Separation of An Endodontic Instruments – An Endodontic Fear

Yesh Sharma

Assistant Professor  
Dept of Conservative Dentistry & Endodontics  
Pacific Dental College & Hospital  
Udaipur

The separation of an endodontic instrument within the root canal system can be one of the most stressful and unpleasant situations with which the clinician can be confronted. These fractures often occur due to incorrect use of instruments. The clinician is confronted with a few options when considering this situation. These options can include leaving the fragment where the fracture occurred and incorporating the fragment to form part of the final obturation or removal from the root canal. When a file fractures during root canal treatment there are several treatment options available to the clinician. The definitive management should be based on a thorough knowledge of the success rates of each treatment option, balanced against potential risks of removal or file retention.

These fractures often occur due to incorrect use of instruments. Operators can utilize incorrect movements during cleaning and shaping or use deformed instruments, pushing them beyond their ability to absorb the workload (Gross man, 1969; Parashos, et al., 2004). Once an instrument fractures, a detailed approach should be followed to assess the possibility of removal. The clinician should be thoroughly aware of the complicating factors when attempting the removal.

**These factors may include the following:**

- The unique anatomy of the root canal system.
- The availability of materials, instruments, and devices to dislodge and remove separated instruments.

- The clinician's experience and ability.
- The location, size, position, and diameter of the fractured portion.

### What Dental Clinician Can Do?

When an instrument fractures in the root canal system a decision has to be made to leave, bypass or remove the fragment, the choice being based on an assessment of the potential benefit of removal compared with the risk of complication.

### What Other Factors Influence Clinical Decision-making?

#### Periodontal & Restorative Status of Tooth

Periodontally compromised teeth do not make good candidates for instrument removal, although it can be considered if the patient's periodontal condition is stable and they are informed of the risks of removal. In cases where teeth are unrestorable or are likely to become unrestorable subsequent to instrument removal, extraction should be considered, as there is no virtue in spending further resources (patient or dentist) treating a tooth with a hopeless prognosis.

#### Patient Factors

Fractured instrument removal generally involves a prolonged period in the dental chair, therefore, general dental issues such as patient

Access This Article Online

Website:  
[www.healtalk.in](http://www.healtalk.in)

Quick Response Code:



DOI: <https://doi.org/10.5281/zenodo.11000702>

apprehension and time constraints become more pertinent. Health issues may also alter the balance in favour of instrument removal if extraction is best avoided. Conditions such as severe bleeding disorders or patients receiving intra- venous bisphosphonate medication are at increased risk of postoperative complications subsequent to dental extractions.<sup>24</sup> Finally, cost to the patient may be an influencing factor as removal of fractured files is a technically challenging procedure, often requiring the assistance of a specialist. Patients may decide that removal of the fragment is not worth the additional financial outlay compared to extraction or observation.

### How Successful are Clinicians at Removing Instruments and What Influences that Success?

These factors can be broadly grouped as (1) the location, length and type of fractured instrument, (2) the tooth/canal involved, and (3) the clinician's skill and available armamentarium.

#### 1) Location, length, type and material of fractured instrument

**Location** – With the introduction of the operating microscope into clinical dentistry, instruments in the straight portion of the canal can now generally be removed, while fractured instruments that lie partially in the canal curvature – although more challenging – can also be removed. When fragments are localised apical to the canal curvature, removal is compromised, often impossible and generally ill advised.

**Length** -Hulsmann and Schinkel<sup>5</sup> pro- posed that longer fragments would be easier to remove than short fragments, explaining that fragments (>5 mm) were likely to engage dentine at their tips, creating space coronally to allow loosening of the fragment,

**Type** -More recent research investigating a broad spectrum of instruments, including hand and rotary files of various designs and taper, concluded that instrument type did not have any effect on success of removal.

**Material** -Stainless steel (SS) files are considered to be easier to remove than nickel-titanium (NiTi) instruments, which have a higher propensity to fracture further during the removal process, perhaps due to accumulation of heat from direct ultrasonic vibration.

Removing rotary NiTi instruments include the fact that they effectively engage or 'lock' into the canal during rotation and tend to fragment into smaller pieces often at or around the curves of narrow canals.

#### 2) Tooth/canal involved

Root anatomy such as the diameter, length, canal curvature and thickness of the root dentine has been reported to affect the potential to safely remove a fractured instrument. P

There is general agreement that curved canals (particularly buccal canals of maxillary molars and mesial canals of mandibular molars) present a significantly higher risk of instrument fracture than straight canals.

Some investigators reported significantly decreased removal rates as the severity of curvature increases, suggesting that as the angle of root curvature increases, it becomes technically more difficult to create a 'staging platform' and trephine around the coronal aspect of the fragment,

#### 3) Clinician's skill and available armamentarium

The clinician's experience, competence and attitudes regarding the impact of a fractured file on prognosis are important factors in the management of a fractured instrument. In modern endodontic practice fractured instruments can be removed more predictably, which has been credited to technological advances including the use of the dental operating microscope, ultrasonics and microtube extraction devices. However, other factors may account for these differing success rates, including the lack of modern ultrasonic 'tips' and use of different removal systems.

### Latest Techniques For Removal of Intracanal Separated Instruments

Braiding technique of endodontic files H or K files can be inserted into root canal to engage the fragment and then withdraw it when the fragment is positioned deeply in the canal and not visible and the clinician is relying on tactile sense, or the fragment is loose but cannot be retrieved by using other means.

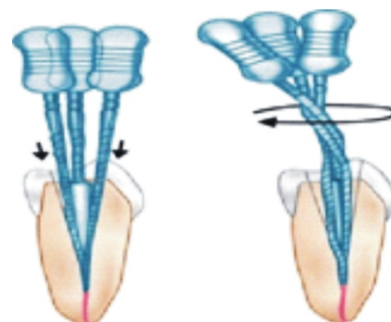
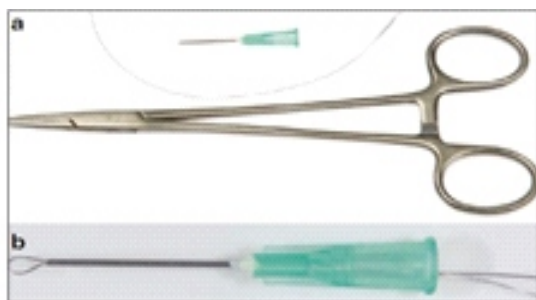


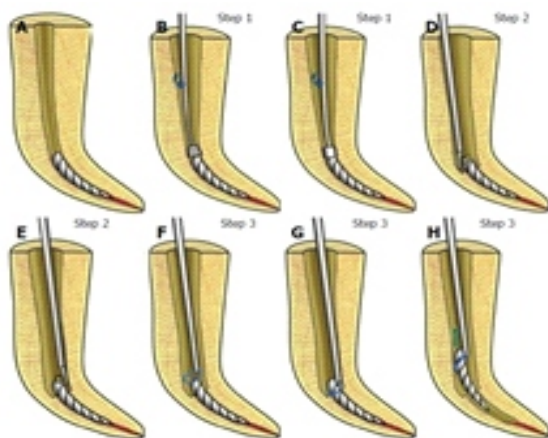
Figure 1. Braiding Technique

**Wire Loop Method** - A wire loop can be formed by passing the 2 free ends of a 0.14-mm wire through a 25-gauge injection needle from the open end until they slide out of the hub end . By using a small haemostat, the wire loop is tightened around the upper free part of the fragment, and then whole assembly can be withdrawn from the root canal . The loop can be either small circular or long elliptical in shape, according to canal size and the location of the fragment. This technique can be used to retrieve objects that are not tightly bound in the root canal.




**Figure 2.** Wire loop technique includes a cut disposable needle, an orthodontic wire, and small hemostatic forceps a loop formed

**File Retrieval System:** The Terauchi File Retrieval Kit [26] (TFRK, Dental Care, Santa Barbara, California, USA) was introduced in 2006. Two types of low-speed cutting burs with 28-mm lengths are used. Ultrasonic tip (30mm long and 0.2 mm diameter) is used to prepare a groove around the separated fragment (at least 0.7 mm deep). This usually loosens the fragment or even removes it or else step 3 is carried out. A loop device with a NiTi wire (0.08 mm) is used to mechanically engage the peripherally exposed (by at least 0.7 mm) fragment and retrieve it.



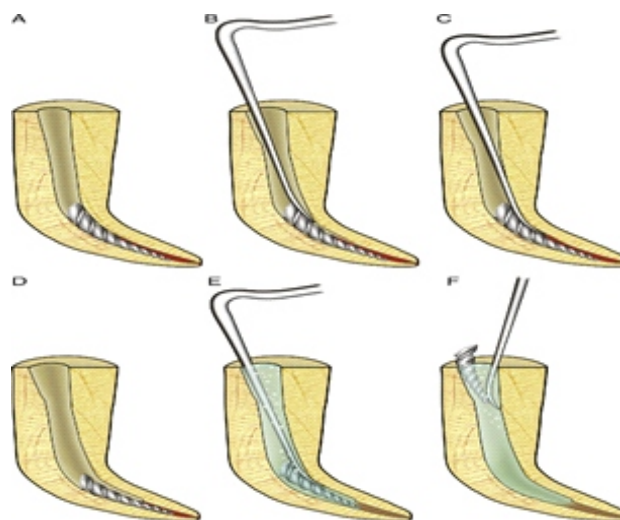
**Figure 3.** Steps In File Retrieval System

**Instrument Removal System-** It contains 3 extractors. The black extractor/ microtube has an outside diameter of 1 mm and is used in the coronal one third of larger root canals. The red and yellow microtubes (0.80 and 0.60 mm, respectively) are used in narrower canals (Fig. 7a).<sup>9</sup>, The screw wedge has knurled metal handle and is inserted into corresponding microtube which has a rubber handle (Fig. 7b) [17] Microtube is beveled at 45 degree to scoop out the separated instrument with a side window for efficient engaging (Fig. 7c)



**Figure 4.** Color coded microtubes with corresponding screw wedges inserted

**Ultrasonics** - Ultrasonic instruments have a contra-angled design with alloy tips of different lengths and sizes to enable use in different parts of the root canal . A staging platform is prepared around the most coronal aspect of the fragment by using modified Gates Glidden burs (no. 2-4) . Gates Glidden bur is modified by grinding the bur perpendicular to its long axis at its maximum cross-sectional diameter .



**Figure 5.** Ultrasonic Procedure



The ultrasonic tip is activated at lower power settings, so it trephines dentin and the vibration being transmitted to the fragment, makes latter to loosen and then "jumps" out of the root canal. Other root canal orifices in the tooth, when present, should be blocked with cotton pellets to prevent the entry of loose fragment.

The ability of a fluid to lubricate the fractured

instrument in the root canal space and flush it away with the aid ultrasonic- generated acoustic streaming and cavitation generated is mainly dependent on the fluid characteristics, including lubricity, viscosity and surface tension. Generally, fluids with high viscosity and surface tension reduce both acoustic streaming and cavitation, but increase lubricity, and vice versa.

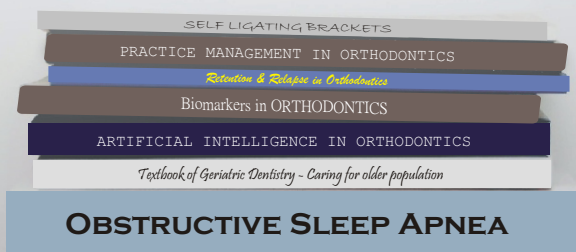### How To Prevent File Separation During Root Canal Procedure

- Avoid subjecting Ni Ti rotary instrument to excessive stress
- Use instruments that are less prone to fracture
- Follow an instrument use protocol
- Assess root canal curvatures radiographically and instrument them carefully
- Ensure that the endodontic access preparation is adequate
- Open orifices before negotiating canals
- Enlarge root canals with fine hand hard instruments
- Set rotational speed and torque at low levels
- Use the crown-down technique
- Irrigate and lubricate rootcanals during preparation
- Manipulate rotary instruments with a pecking or pimping motion
- If inexperienced, engage in preclinical training in the use of rotary instruments.

### References:

1. Crump M C, Natkin E. Relationship of a brokenroot canal instrument to endodontic case prognosis: a clinical investigation. J Am Dent 1970;80: 1341–1347.
2. Fox J, Moodnik R M, Greenfield E, Atkinson J S. Filling root canals with files: radiographic evaluation of 304 cases. N Y State Dent J 1972;38: 154–157.
3. Sjögren U, Hagglund B, Sunqvist G, Wing K. Factors affecting the long-term results of endodontic treat-ment. J Endod1990; 16: 498–504.
4. Machtou P, Reit C. Non-surgical retreatment. In Bergenholtz G, Hørsted-Bindslev P, Reit C (eds). Textbook of endodontology, 1st ed. pp 300–310. Oxford: Blackwell Munksgaard, 2003.
5. Hülsmann M, Schinkel I. Influence of several factors on the success or failure of removal of fractured instruments from the root canal. Endod Dent

## INVESTING IN BOOK PUBLICATIONS



*elevates your expertise,  
providing a lasting contribution  
to your field & accumulating  
essential points in  
academic evaluations.*

updentpublication@gmail.com

Published 1000+ Titles