

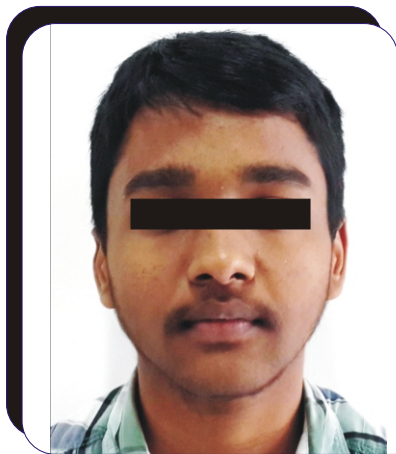## Case 1: Class II Div 2 Case

Dr. Devinder Preet Singh

DOI: <https://doi.org/10.5281/zenodo.10369366>

A fifteen year old male patient reported to the dental clinic with a chief complaint of irregular upper front teeth. Intraorally the patient had Class II molar and canine relationship, division 2 incisors with deep overbite. The patient was skeletal Class II with deficient mandible. The patient was treated with comprehensive fixed mechanotherapy with self ligating metal brackets having 0.022" slot. After leveling and alignment of the teeth which took about 9 months, the patient was given Forsus Fixed Functional Appliance, to stimulate the growth of the mandible, for 6 months to correct the skeletal Class II. The total treatment took about 1.5 years with the achievement of Class I molar and skeletal relationship and ideal overjet and overbite. Permanent lower bonded retention from canine to canine was given with upper removable anterior inclined plane to retain the Class II correction.

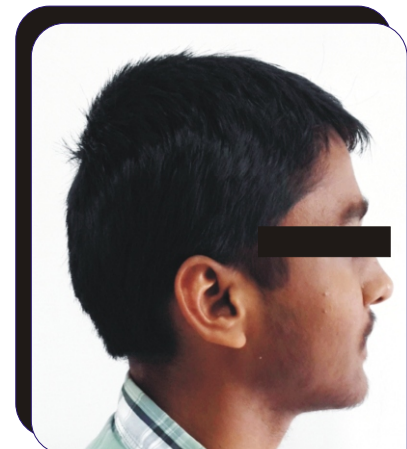### Extra-oral Photographs (Pre-Treatment)



Frontal View

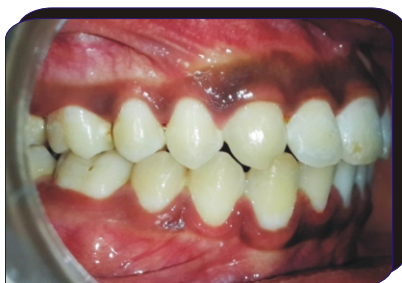


Smiling View

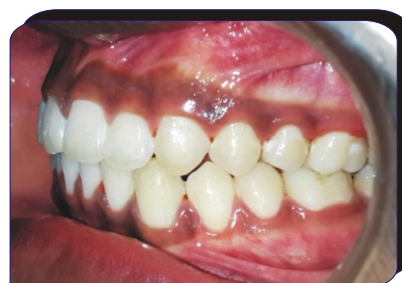

Profile View

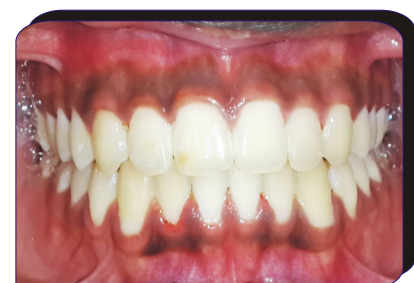### Intra-oral Photographs (Pre-Treatment)



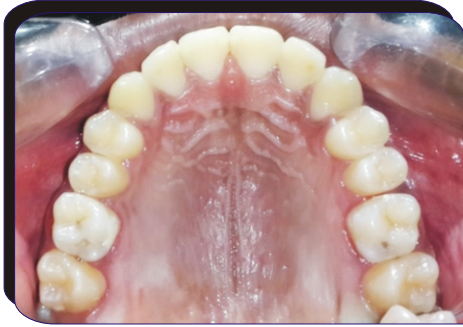Right Lateral



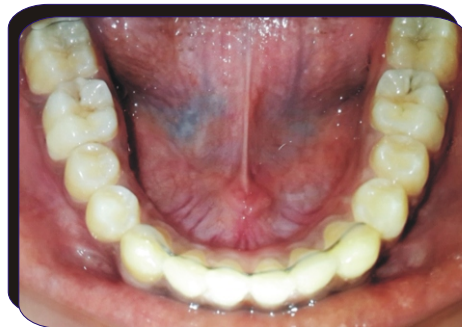Left Lateral



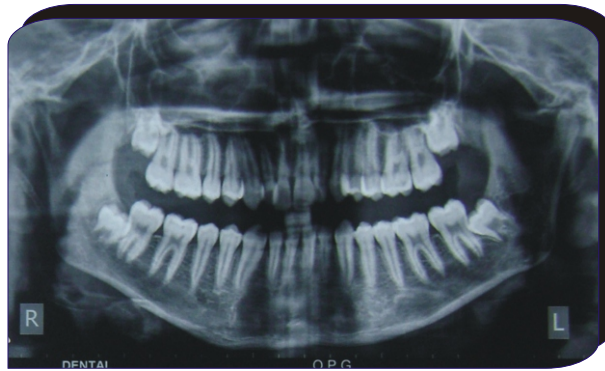
Frontal View



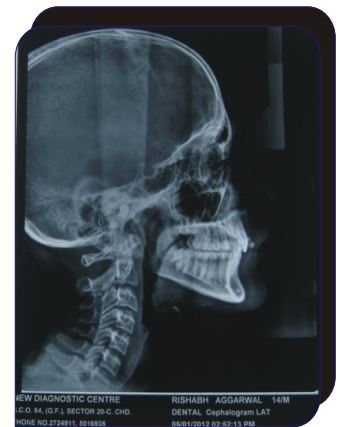**Maxillary Occlusal**



**Mandibular Occlusal**

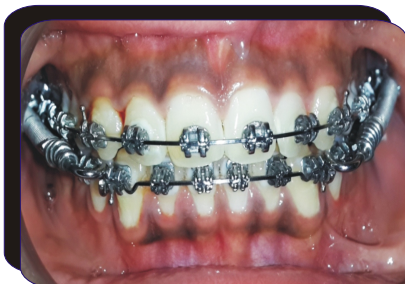

**OPG (Orthopantomogram)**

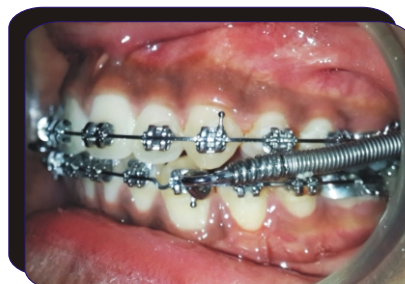

**Lateral Cephalogram**

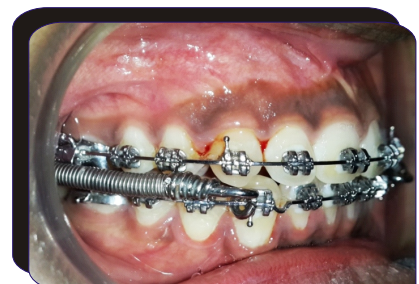
**Intra-Oral Photographs (Forsus Appliance)**



**Frontal View**



**Left Lateral**



**Right Lateral**

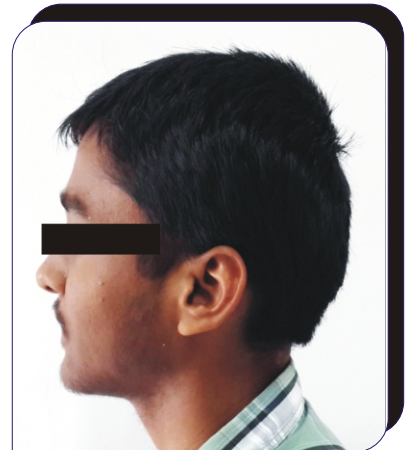**Extra-oral Photographs (Post-Treatment)**



**Frontal View**



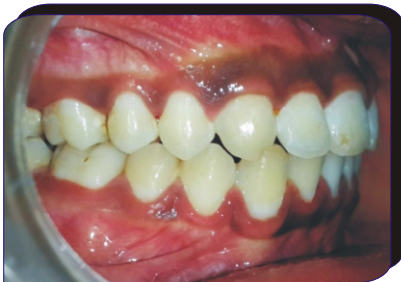**Smiling View**



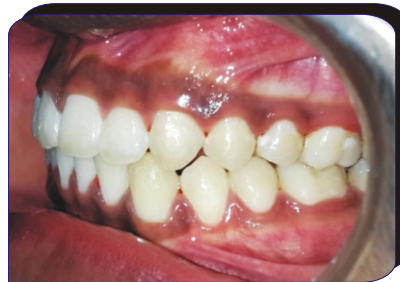**Profile View**

---

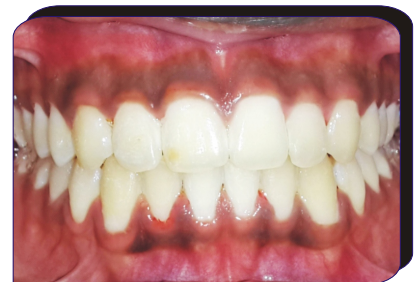**Intra-oral Photographs (Post-Treatment)**



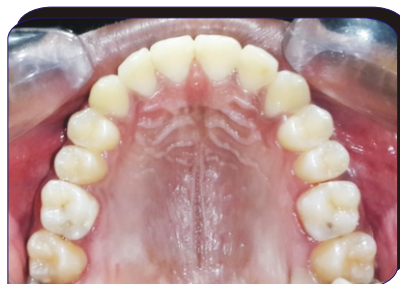**Right Lateral**



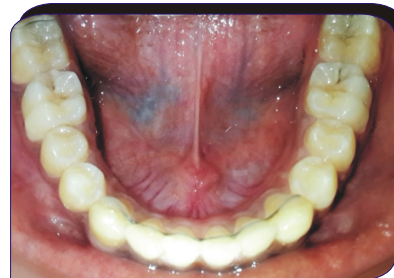**Left Lateral**



**Frontal View**

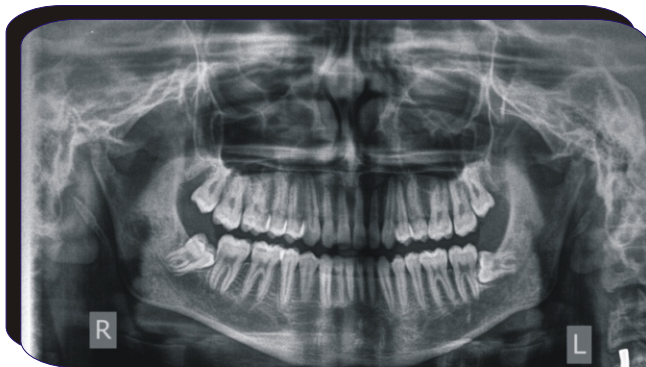

**Maxillary Occlusal**

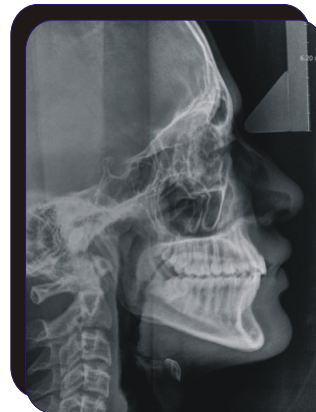

**Mandibular Occlusal**





**OPG (Orthopantomogram)**



**Lateral Cephalogram**

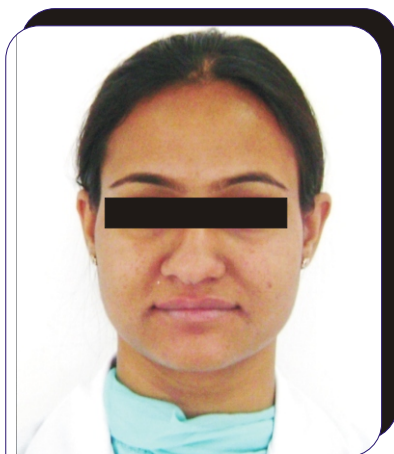---

## **Case 2 Anterior Crossbite**

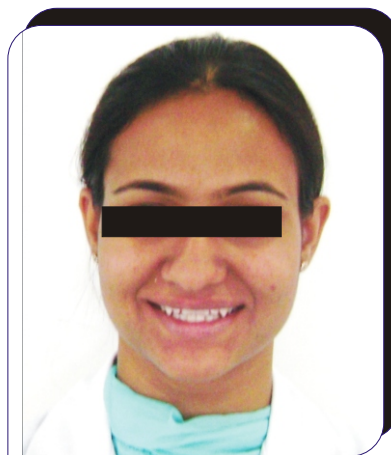A twenty two year old female patient reported to the dental clinic with a chief complaint of irregular upper front teeth. Intraorally the patient had Class I molar and canine relationship with anterior crossbite irt. 11-41, 21-31 and rotated 12,22, 32,42. The patient was skeletal Class I with horizontal growth pattern. The patient was treated with comprehensive fixed mechanotherapy with conventional metal brackets having 0.022” slot. The leveling and alignment of the teeth took about 9 months with the correction of anterior cross bite.. The total treatment took about 1.2 years with the achievement of Class I incisor relationship and ideal overjet and overbite. Permanent lower bonded lingual retention from canine to canine was given with upper Hawley’s retainer.

---

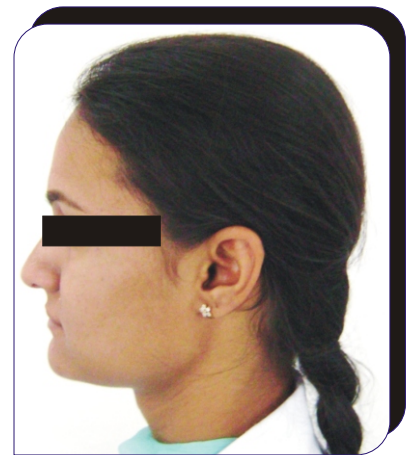### **Extra-oral Photographs (Pre-Treatment)**



**Frontal View**

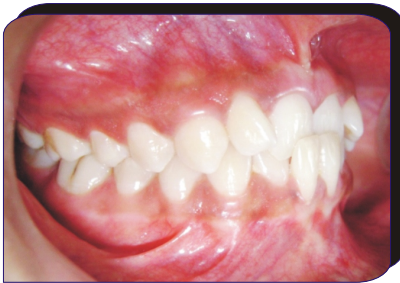

**Smiling View**

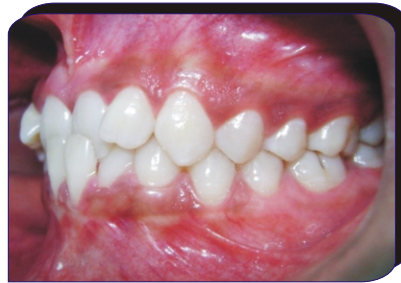

**Profile View**

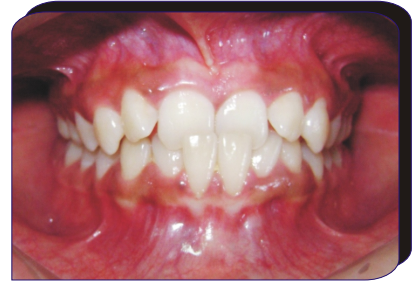**Intra-oral Photographs (Pre-Treatment)**



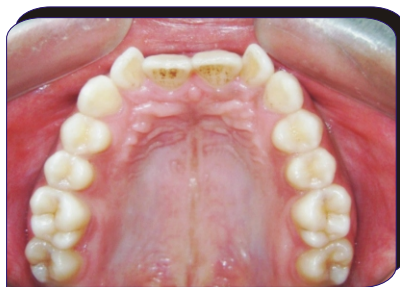**Right Lateral**



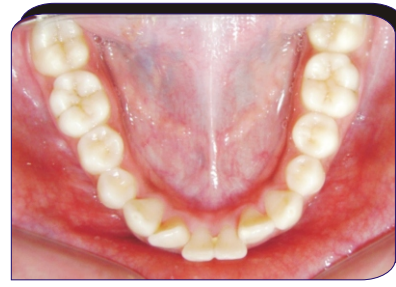**Left Lateral**



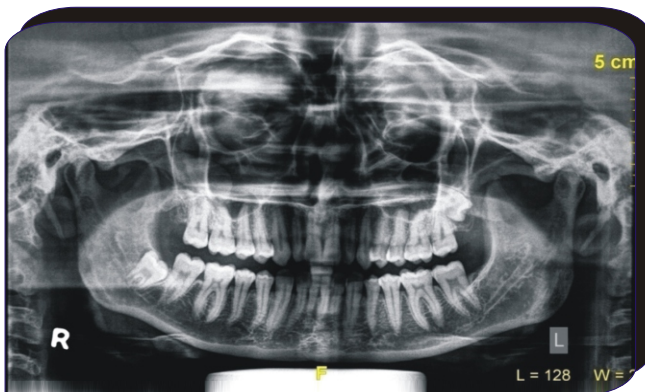
**Frontal View**



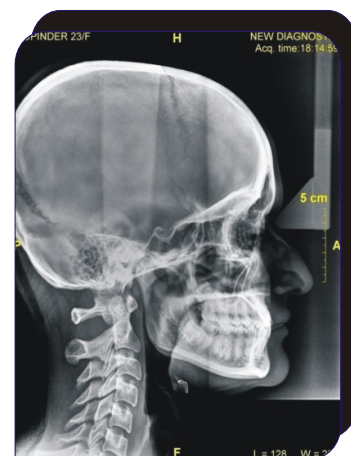**Maxillary Occlusal**



**Mandibular Occlusal**

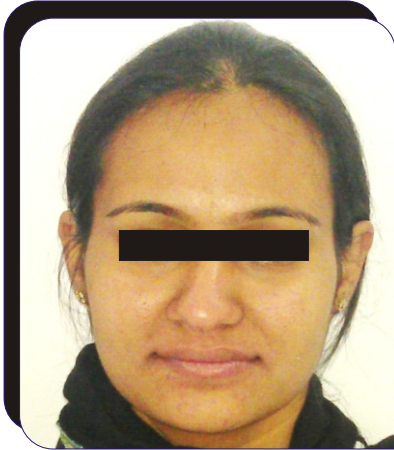

**OPG (Orthopantomogram)**



**Lateral Cephalogram**

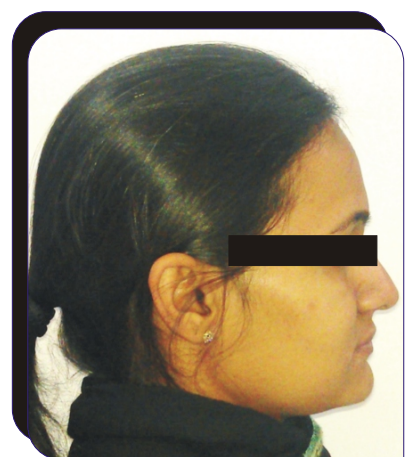**Extra-oral Photographs (Post-Treatment)**



**Frontal View**



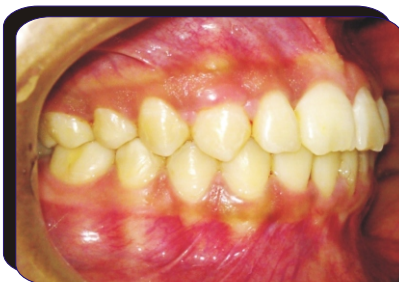**Smiling View**



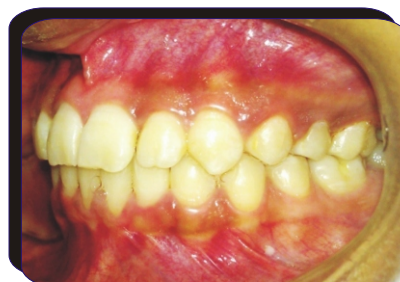**Profile View**

---

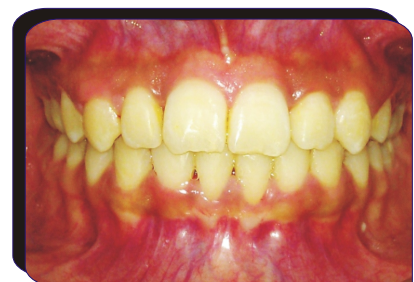**Intra-oral Photographs (Post-Treatment)**



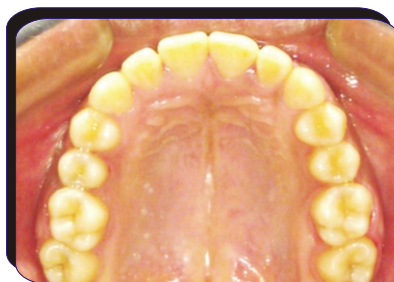
**Right Lateral**



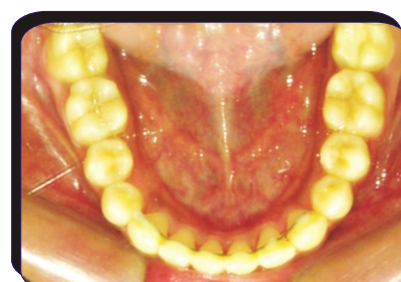
**Left Lateral**



**Frontal View**

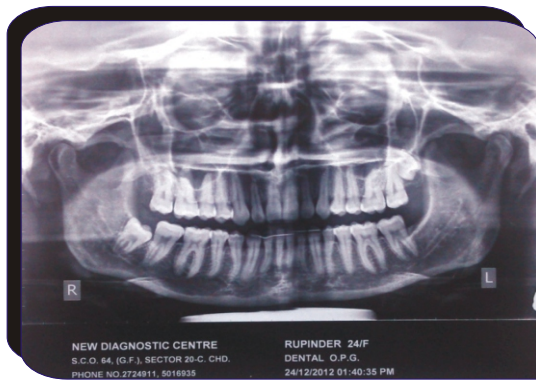

**Maxillary Occlusal**

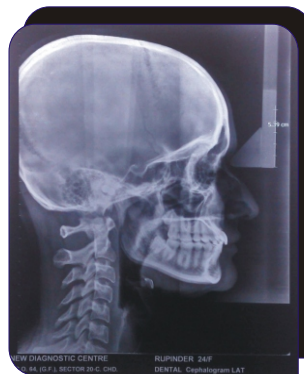

**Mandibular Occlusal**





**OPG (Orthopantomogram)**



**Lateral Cephalogram**

Exponent International New Delhi  
22 to 24 December 2023

54<sup>th</sup> Kerala State Dental Conferences  
5-6-7 January 2024  
Saptha Resorts & Spa, Wayanad

74<sup>th</sup> IDC Kolkata 2024  
2-3-4 February 2024  
Biswa Bangla Convention Centre Kolkata

UAE International Dental Conference  
Dubai AEEDC-DUBAI  
6-7-8 February 2024  
Dubai World Trade Centre

Dental South China International Expo  
3-4-5-6 March 2024  
Guangzhou City, China

Exponent Chennai  
16-17 March 2024

International Conference of Digital  
Dentistry Digitize 2.0  
5-7 April 2024  
Le Meridian New Delhi

Exponent Kolkata  
6-7 April 2024

IDEM Singapore 2024  
19 20 21 April 2024

Exponent Lucknow  
20-21 April 2024

IDEX Istanbul 2024  
8-9-10-11 May 2024



Expo Dental Meeting Rimini, Italy  
16-17-18 May 2024

SIDEX 2024 Seoul, South Korea  
7-8-9 June 2024

China Dental Show  
11 12 13 September 2024  
Shanghai National Convention & Exhibition  
Centre, Shanghai, China

World Dental Show  
26-27 October 2024 Mumbai

6<sup>th</sup> Global American Academy of Implant  
Dentistry & World Congress for Oral  
Implantology Conference 2024  
8<sup>th</sup> - 10<sup>th</sup> November 2024  
The Leela Ambience Convention Hotel, New Delhi

Global Summit on Pediatrics Dentistry  
30-31st December at Bangalore

IDS Germany Cologne  
25 26 27 28 29 March 2025

# Event Talk