

Rehabilitation of Severely Attrited Teeth Using Full Crown, Onlay, Endocrown & Buccal Half Crown

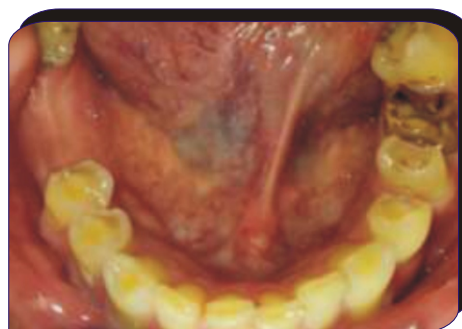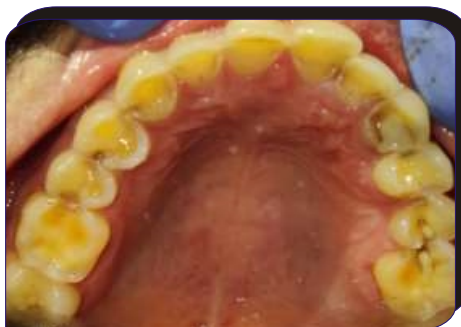Dr. Manisha Khanna, Dr. Shefali Singla, Dr. Rajni jain, Dr. Monika

DOI: <https://doi.org/10.5281/zenodo.10071119>

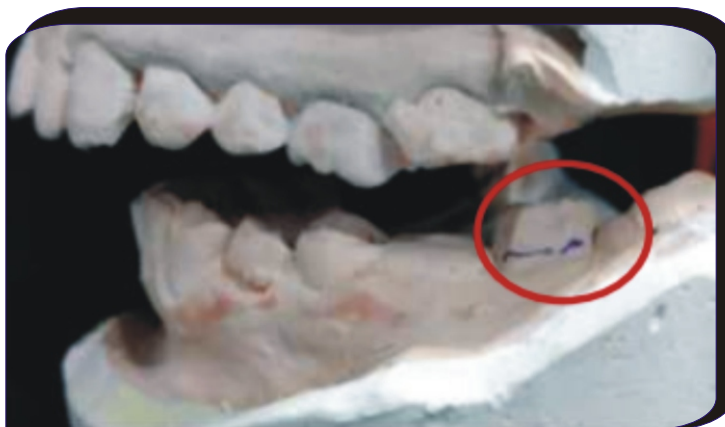Dr Harvansh Singh Judge Institute of Dental Sciences and Hospital, Chandigarh

A 37 year old male patient came to the department with chief complaint of rapid wear of his dentition and sensitivity in #16. Intra-oral and radiographic examination revealed generalised attrition of teeth with freeway space no more than 2mm; Root canal treated #35, #36, #37. Missing #46, #47

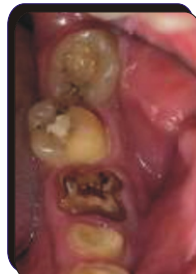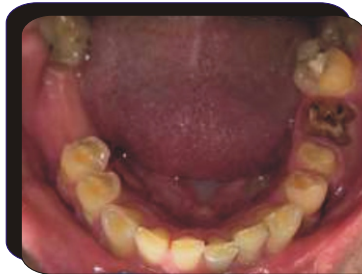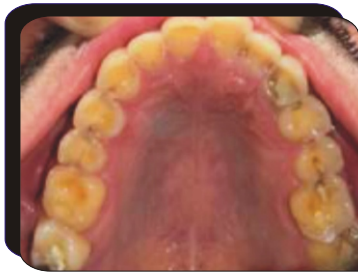Treatment plan - fabrication of vertical stops in the form of various indirect restorations and RPD fabrication wrt #46, #47 followed by soft splint fabrication



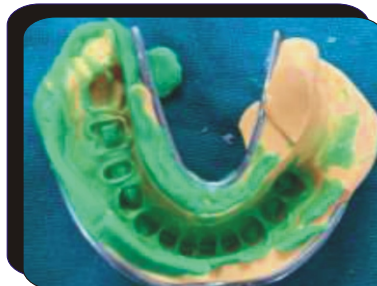
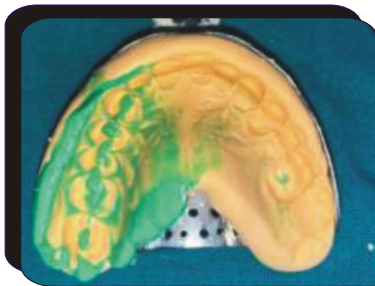
Pre-operative intra-oral photographs



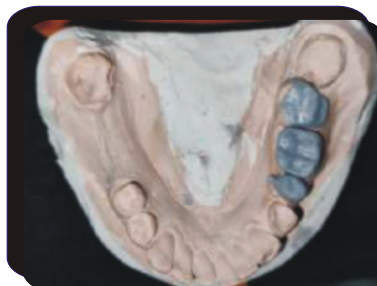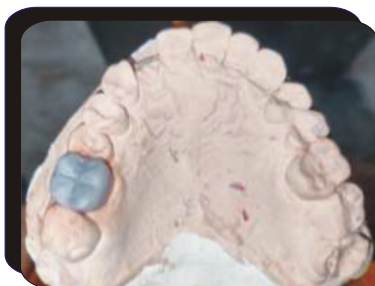
Extra-oral left lateral view presenting absence of positive occlusal contact for #17 and severely attrited buccal surface of #37




**Tooth Preparation
WRT**
#16- Onlay
#35- For pfm full
veneer crown
#36- Endo crown
#37- Buccal half
preparation



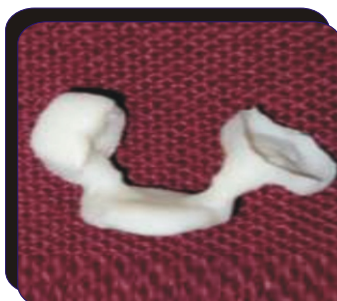**2 Stage dual consistency
impression of maxillary &
mandibular arch**



**Full contour wax up #16,
#36
Wax up for metal coping
wrt #35, #37 (with step
created for occlusal stop
buccally wrt #37)**

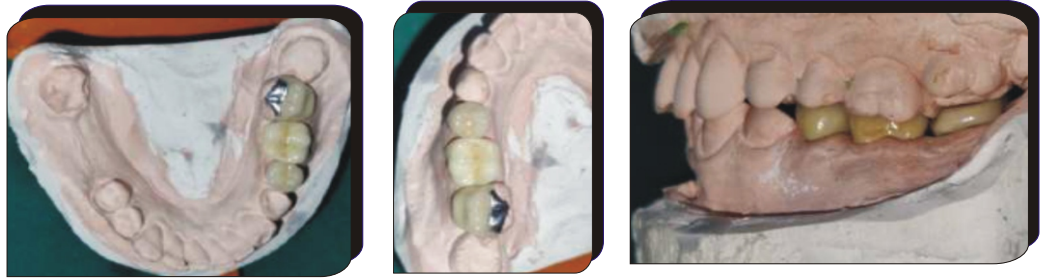


Crowns retrieved from investment material

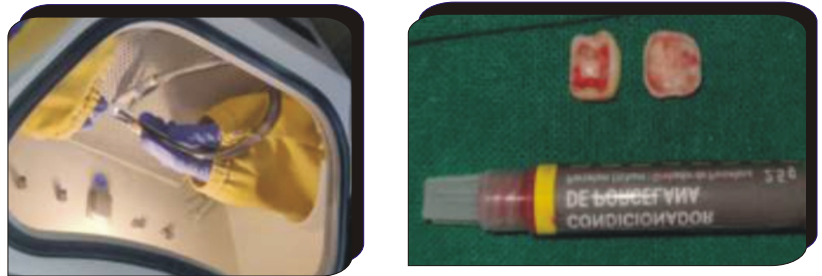


Ceramic layering wrt #35, #37

Polished crowns on the cast



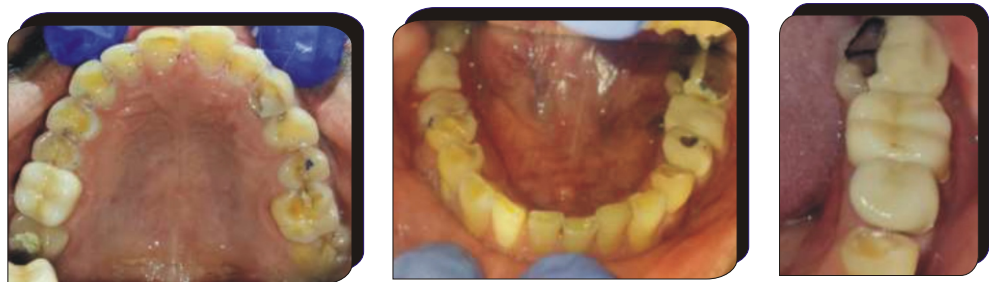Ceramic crowns conditioning: sandblasting followed by '9% HF' etchant and silane application



Tooth conditioning using H_3PO_4 etchant and bonding agent application followed by cementation using dual cure resin cement



Post-operative intra-oral photograph



In present case report, further wear of teeth was prevented by creating vertical stops bilaterally in the form of various indirect restoration. Full coverage metal ceramic crown was planned for #35, All ceramic endocrown for #36 because of inadequate inter-occlusal space (supra-erupted 26) and less crown height wrt #36. #37 was excessively lingually tilted and required RCT for full crown. A conservative buccal half crown was given instead of full coverage crown because of which we were able to avoid the root canal treatment. Onlay was planned for #16 which acted as vertical stop as well as protected the tooth from sensitivity.