

# A Case Report

## Submandibular Sialolithiasis – A Case Report

Aparna Mishra, Rajendragouda Patil, Vaibhav Seth, Himani Singh

PGT<sup>1</sup>  
Department of Oral Medicine and Radiology  
Kothiwal Dental College and Research Centre  
Moradabad, UP

Professor & HOD<sup>2</sup>  
Department of Oral Medicine and Radiology  
Kothiwal Dental College and Research Centre  
Moradabad, UP

Reader<sup>3</sup>  
Department of Oral Medicine and Radiology  
Kothiwal Dental College and Research Centre  
Moradabad, UP

Senior Lecturer<sup>4</sup>  
Department of Oral Medicine and Radiology  
Kothiwal Dental College and Research Centre  
Moradabad, UP

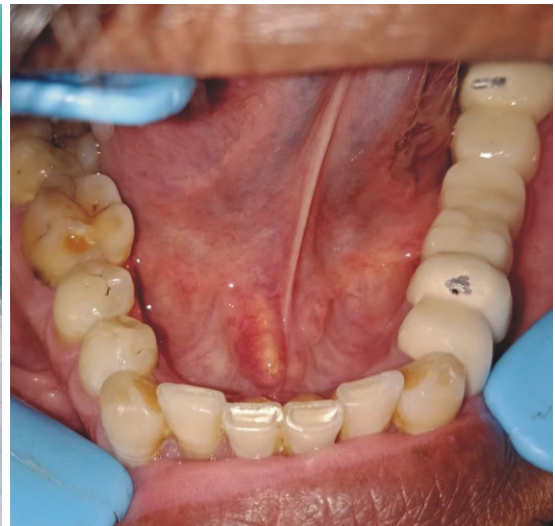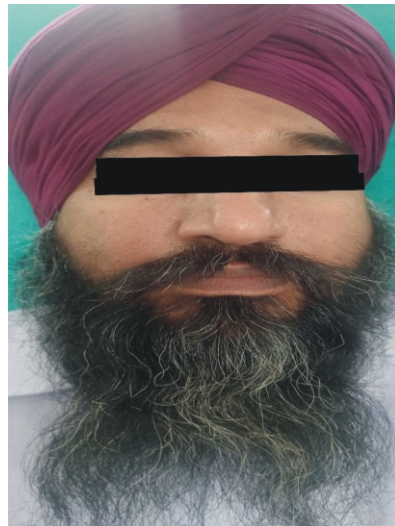A 45 years old male patient reported to the Department of Oral Medicine and Radiology, Kothiwal Dental College and Research Centre with a chief complaint of swelling below the tongue since 3 months. The swelling caused pain and discomfort during eating food. The pain was dull and intermittent in nature which aggravated on eating food, especially sour food. He also complaint about dryness of mouth since 3 months.

On clinical examination, no obvious swelling was seen extra orally. On intra oral examination a small, well defined swelling of size approx. 1cm X 0.5cm was present below the tongue, on right side to the frenulum attachment on the floor of the mouth. The mass was firm,

slightly tender and bimanually palpable. The submandibular and submental salivary glands were non tender. The salivary flow from the submandibular gland was checked by milking the submandibular gland area and lesser secretion from the right submandibular gland was observed. All other vital signs of the patient were found to be in the normal range.

On the basis of history and clinical findings a provisional diagnosis of submandibular sialolithiasis on the right side was made. However, the following differential diagnosis can be considered-

1. Bacterial/ Viral sialadenitis
2. Mucous extravasation cyst
3. Dystrophic calcification of lymph node



Access This Article Online

Website:  
[www.healtalk.in](http://www.healtalk.in)

Quick Response Code:




### Investigation -

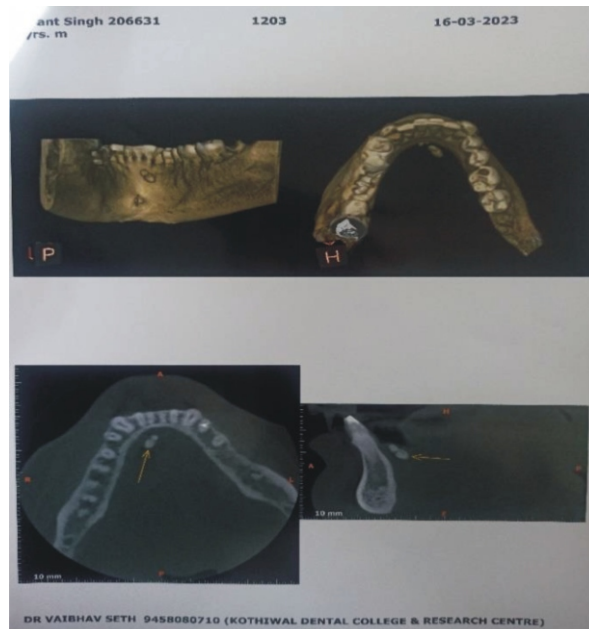
**CBCT** – CBCT shows oval shaped, localized, well demarcated radio dense masses along the lingual aspect of symphysis i.r.t 41-43 region, corresponding to the region of Wharton's duct.

**How to cite this article:** Mishra A et al.: Submandibular Sialolithiasis – A Case Report, *HTAJOCD* 2023;Sep-Oct(1):73-75

The anteriorly located mass appeared smaller in size measuring 3mmX3.3mm, with irregular periphery. The posteriorly located mass measured 5.5mmX 3.6mm. It showed an oval shape with concentric structures and

irregular margins. The centre appeared more opaque than the periphery. Based on the radiographic findings, a radiographic impression of **sialolith i.r.t lingual aspect of 41, 42, 43** was made.

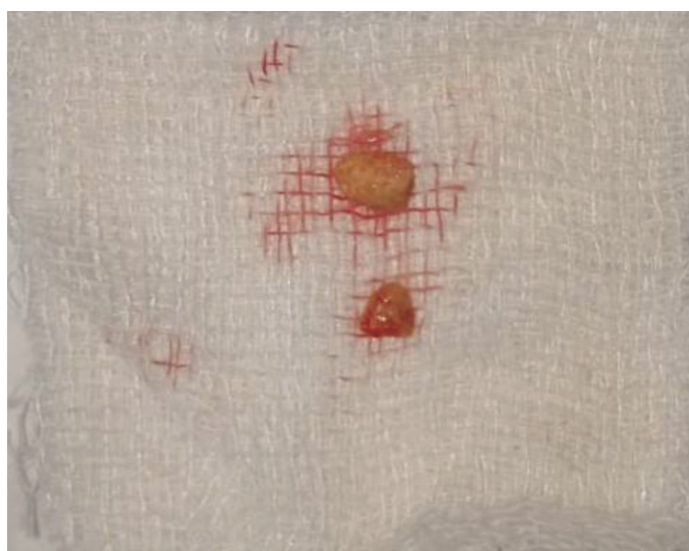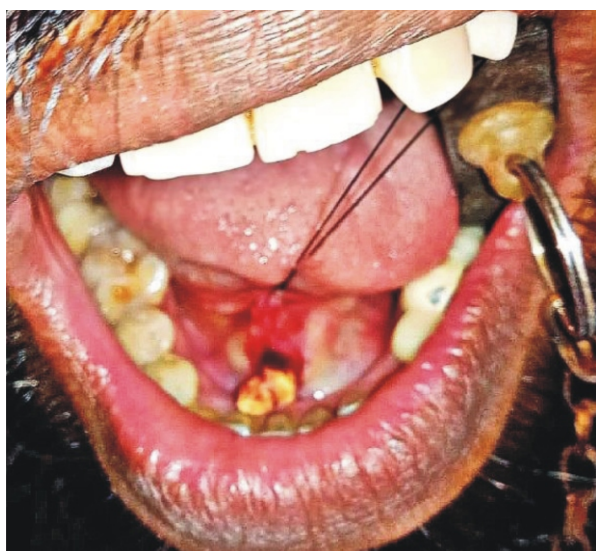DEPARTMENT OF ORAL MEDICINE AND RADIOLOGY KOTHIWAL DENTAL COLLEGE AND RESEARCH CENTRE			
16/03/2023			
Patients Name	JASVANT SINGH	Case paper ID	206631
Age	48yrs	Gender	MALE
Referred By	ORAL MEDICINE		
Clinical impression	EVALUATION OF IMPLANT SITE		
Radiograph	CBCT MANDIBLE		
Cone-beam computed tomographic examination of mandible has been performed with F.O.V of 5 X 5 cm. The image volume was reviewed and reformatted cross-sectional & 3D volumetric images were generated.			
<b>Images Provided:</b>			
1. Reformatted cross sectional image Cross sections images were generated through the mandible using 1 mm slice thicknesses.			
2. 3D image.			
<b>CBCT Shows</b>			
Localized, well demarcated, radiodense masses along the lingual aspect of the symphysis i.r.t. 41-43 region. The region corresponds to the submandibular gland duct or wharton's duct. The anteriorly located mass is smaller in size 3.0mm x 3.3mm and shows irregular periphery. Comparatively larger posterior mass measures 5.5mm x 3.6mm. It shows an oval shape with concentric structure and irregular margins. The centre appears more opaque than the periphery of the mass.			
<b>Radiographic impression:</b>			
• Sialolith i.r.t lingual aspect of 41, 42, 43 region.			
 Dr. Vaibhav Seth Oral and Maxillofacial Radiologist Dept. of OMR Kothiwai dental College		Dr. Rajendra gouda patil Prof. and Head Dept. of OMR Kothiwai Dental College	
Note: All radiographic impressions need to be correlated with clinical findings.			



### Management –

The sialolith was surgically excised under local anaesthesia by making an incision longitudinally over the swelling, causing minimal invasion to surrounding structures.

On gross examination, two bits were observed, the largest measuring 0.4x0.5x0.3 cm and the smallest measuring 0.2x0.2x0.1 cm, whitish in colour and irregular in shape with hard, stony and brittle in consistency.



Post operatively, antibiotic and analgesic coverage was given to the patient for 5 days. Medications prescribed were –

- ⊗ Amoxicillin 500mg + Clavulanic acid 125mg (BD)
- ⊗ Paracetamol 325mg + Aceclofenac 125mg + Seratio-

- peptidase 15mg (BD)
- ⊗ Pantoprazole 20mg (OD)
- ⊗ Post operative follow-ups were maintained and it was noted that there was no sign of recurrence or discomfort to the patient.

### Discussion-

Sialolithiasis is a frequent salivary gland condition in which calcifications or calculi form inside salivary glands or in their ductal system<sup>1</sup>. It is estimated to occur in 1.2% of the adult population with a slight male predominance<sup>2,3</sup>. Sialoliths are usually unilateral and localized within the duct more frequently than inside the gland<sup>4,5</sup>.

The submandibular gland is the most involved site because of its retrograde anatomical location and tortuous duct combined with the secretion of mucous and alkaline saliva<sup>6,7</sup>.

The diagnosis of sialolithiasis can be made on the basis of its history, clinical presentation and careful examination. It often presents as recurrent bouts of pain and swelling of the affected salivary gland, usually during mealtimes or in response to other salivary stimuli. Bimanual palpation of the floor of the mouth may reveal a palpable stone in most cases. A uniformly firm and hard gland also suggests a hypofunctional or nonfunctional gland<sup>3</sup>.

### References-

1. Salivary gland diseases: infections, sialolithiasis and mucoceles. Delli K, Spijkervet FK, Vissink A. *Monogr Oral Sci.* 2014;24:135–148.
2. Painless giant submandibular gland sialolith: a case report. Thong HK, Othman IA, Ramli R, Sabir Husin Athar PP. *Cureus.* 2021;13:0.
3. Multiple sialoliths and a sialolith of unusual size in the submandibular duct: a case report. Leung AK, Choi MC, Wagner GA. *Oral Surg Oral Med Oral Pathol Oral Radiol Endod.* 1999;87:331–333.
4. Unusually large sialolith of Wharton's duct. Iqbal A, Gupta AK, Natu SS, Gupta AK. *Ann Maxillofac Surg.* 2012;2:70–73.
5. Sialolithiasis of the submandibular gland in an 8-year-old child. Steiner M, Gould AR, Kushner GM, Weber R, Pesto A. *Oral Surg Oral Med Oral Pathol Oral Radiol Endod.* 1997;83:188.
6. Giant sialoliths of Wharton duct: report of two rare cases and review of literature. Shahoon H, Farhadi S, Hamed R. *Dent Res J (Isfahan)* 2015;12:494–497.
7. Management of anterior submandibular sialolithiasis. Duong LT, Kakiche T, Ferré F, Nawrocki L, Bouattour A. *J Oral Med Oral Surg.* 2019;25:16.