

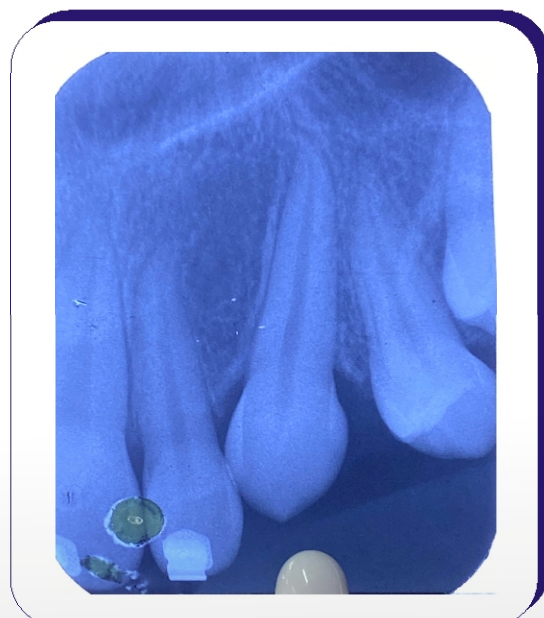
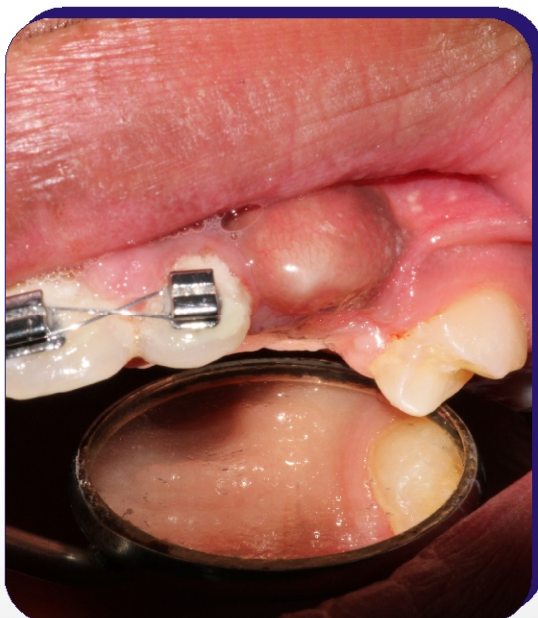
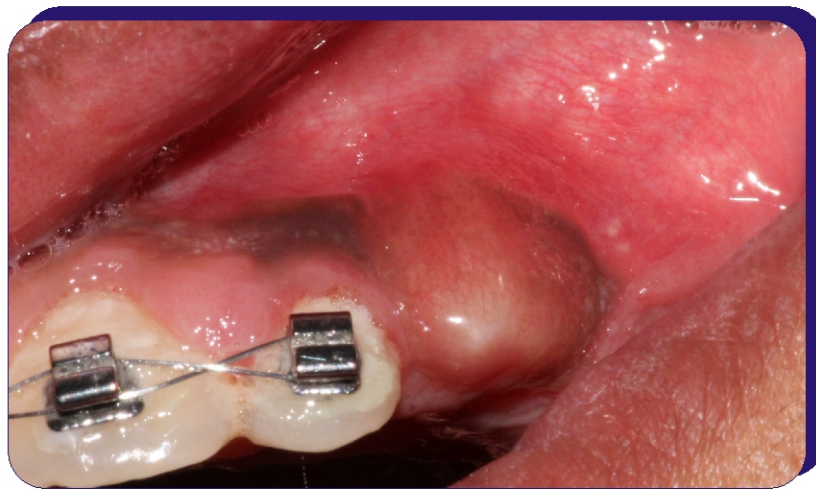
## Canine Exposure

Dr. Rohan Khare

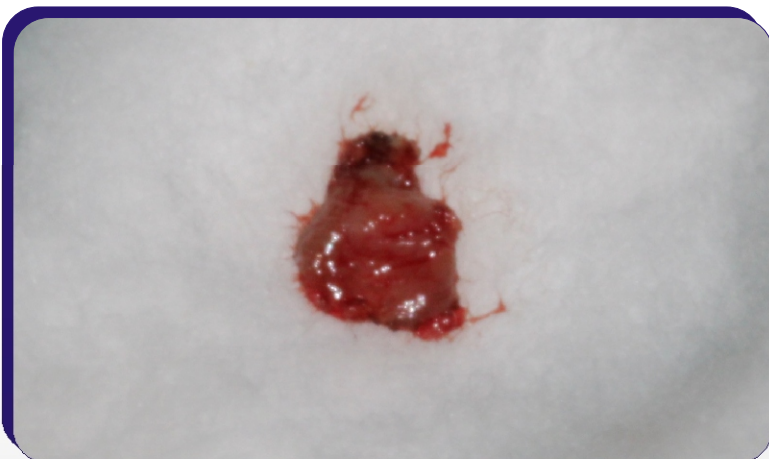
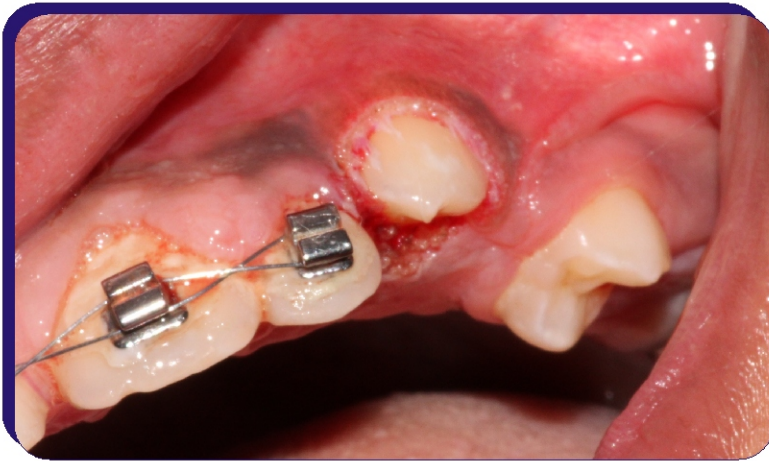
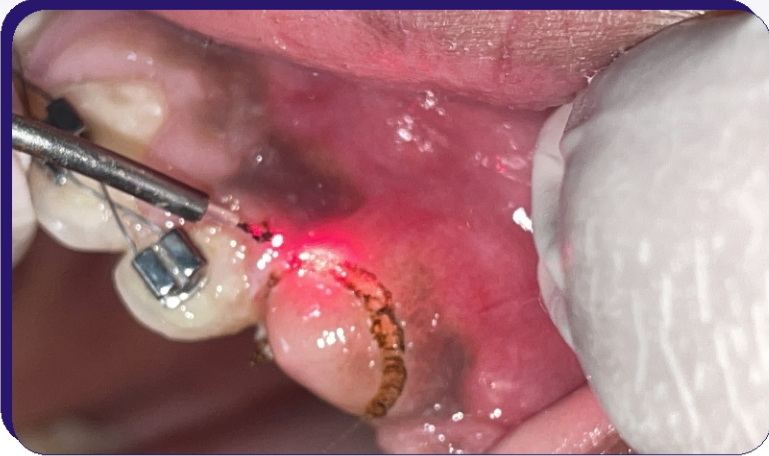DOI: <https://doi.org/10.5281/zenodo.8362065>

**A** 14 year old male patient reported to the dept with an impacted canine. On examination, canine exposure using LASER was decided. Soft tissue diode laser was set to gingivectomy mode (0.8 W setting) at continuous pulsation mode. The tissue was excised and COE Pak was given. Patient was recalled after 10 days. On examination, the healing was proper and further orthodontic treatment was initiated.

### Pre Operative



## Intra Operative



## Post Operative

