

# A Case Report

## Prosthetic Rehabilitation of an Unemployed Mandibular Ridge in Completely Edentulous Patient Using Neutral Zone Technique: A Case Report

Manu Rathee<sup>1</sup>, Surbhi Mittal<sup>2</sup>, Maqbul Alam<sup>3</sup>, Sarthak Singh Tomar<sup>4</sup>, Kritika Diwan<sup>5</sup>

Senior Professor and Head<sup>1</sup>  
Department of Prosthodontics,  
Post Graduate Institute of Dental Sciences,  
Pt. B.D. Sharma University of Health Sciences,  
Rohtak, Haryana, India

Post Graduate Student<sup>2</sup>  
Department of Prosthodontics,  
Post Graduate Institute of Dental Sciences,  
Rohtak, Haryana, India.

Senior Resident<sup>3</sup>  
Department of Prosthodontics,  
Post Graduate Institute of Dental Sciences,  
Pt. B.D Sharma University of Health Sciences,  
Rohtak, Haryana, India.

Post Graduate Student<sup>4</sup>  
Department of Prosthodontics,  
Post Graduate Institute of Dental Sciences,  
Rohtak, Haryana, India.

Post Graduate Student<sup>5</sup>  
Department of Prosthodontics,  
Post Graduate Institute of Dental Sciences,  
Rohtak, Haryana, India.

### 1) Introduction

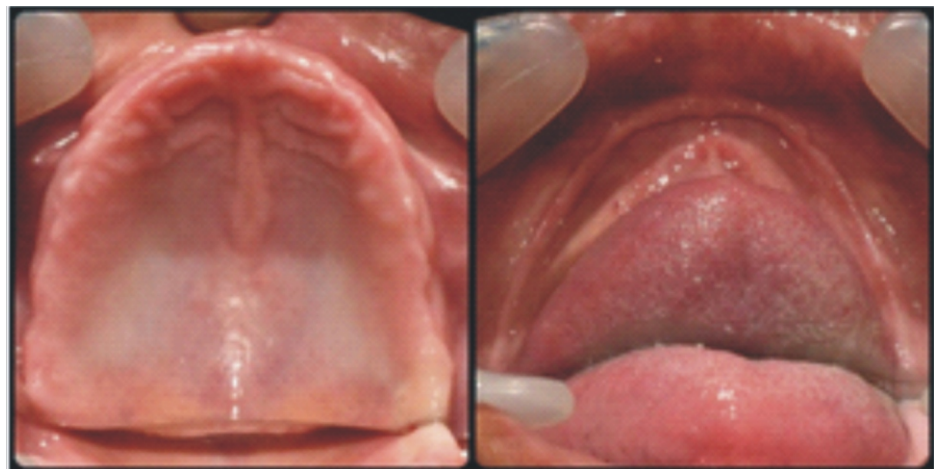
The neutral zone technique is a method used in the fabrication of dentures where there is a highly atrophic ridge, neuromuscular in coordination, and a history of denture instability. The neutral zone is the potential denture space where the outward forces exerted by the tongue are neutralized by the inward forces of the cheeks and lips. Various materials such as impression compounds, tissue conditioners, waxes, and impression plaster have been used for recording the neutral zone. This case report describes in detail the steps in the fabrication of a mandibular denture using the low-fusing impression compound to record the neutral zone to improve the retention and stability of the lower denture.

### 2) Procedure

- Pre-rehabilitative maxillary and mandibular occlusal view
- Primary Impression
- Border molding and Secondary Impression
- Recording Neutral zone
- Teeth arrangement
- Denture try-in and insertion
- Pre-rehabilitative and Post-rehabilitative view

#### 2.a Pre-rehabilitative maxillary and mandibular occlusal view

The maxillary ridge was rounded and well-formed, whereas the mandibular residual ridge was unfavorable due to a high degree of resorption.



Access this article online

Website:  
[www.healtalk.in](http://www.healtalk.in)

Quick Response Code:

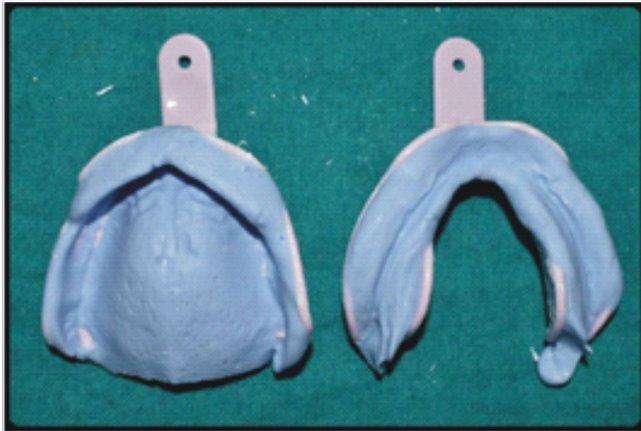


DOI: <https://doi.org/10.5281/zenodo.8351311>

### 2.b Primary Impression

The preliminary impression was made using irreversible hydrocolloid in a perforated edentulous tray and the primary cast was poured in dental plaster.

**How to cite this article:** Rathee M et al.: Prosthetic Rehabilitation of an Unemployed Mandibular Ridge in Completely Edentulous Patient Using Neutral Zone Technique: A Case Report, *HTAJ OCD* 2023; July-Aug(6):38-40



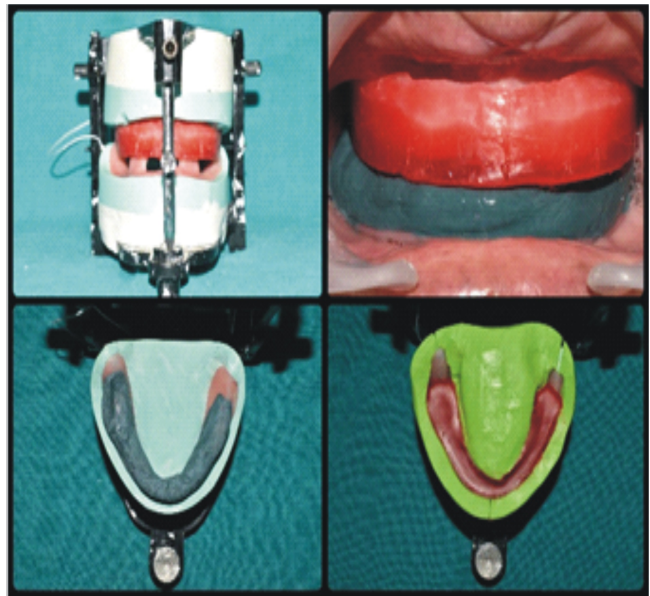
### 2.c Border molding and Secondary Impression

The border molding was done conventionally for the maxillary arch and using all green technique for the mandibular arch followed by the secondary impression with zinc oxide eugenol impression paste. Master casts were fabricated and tentative jaw relation was recorded.



### 2.d Recording Neutral Zone

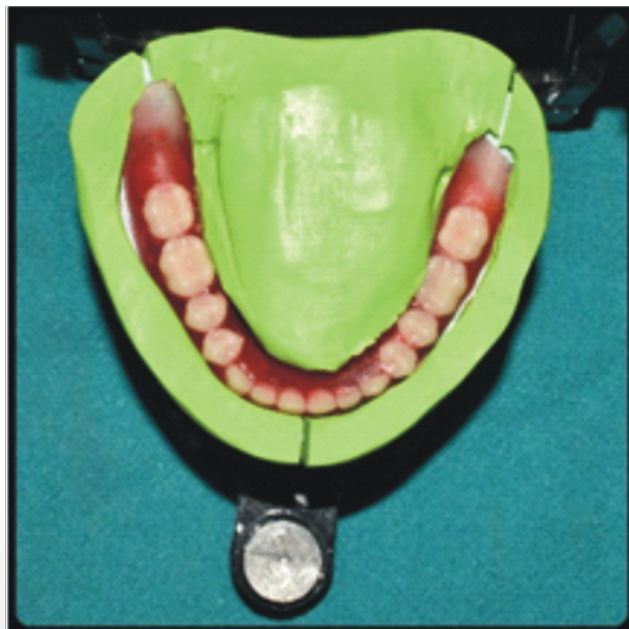The lower occlusal rim was removed and two acrylic pillars were made in the area of the first molars. The neutral zone was recorded using the low fusing compound by asking the patient to talk, swallow, lick, and purse his lips, and drink some water several times so that the lingual and buccal surfaces of the impression were molded correctly. The silicone index of the recorded neutral zone was prepared and the green stick compound was replaced with wax.



### 2.e Teeth arrangement

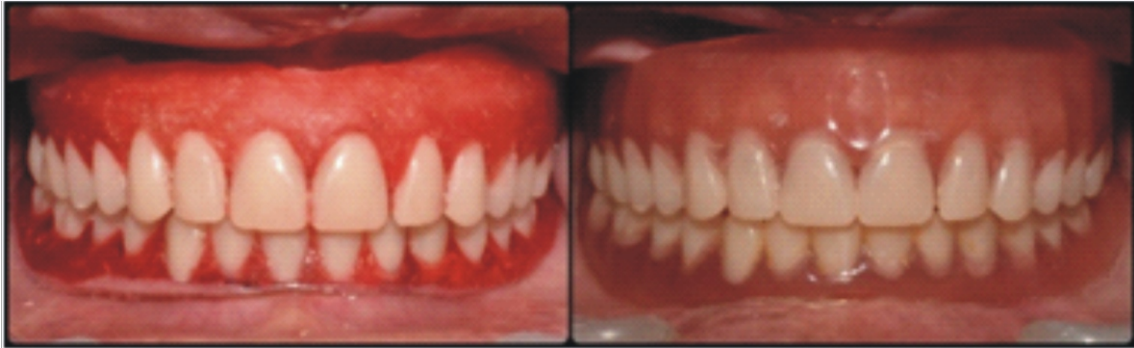Lower teeth arrangement was done first in the

recorded neutral zone. The upper teeth arrangement was done in accordance with the lower teeth.



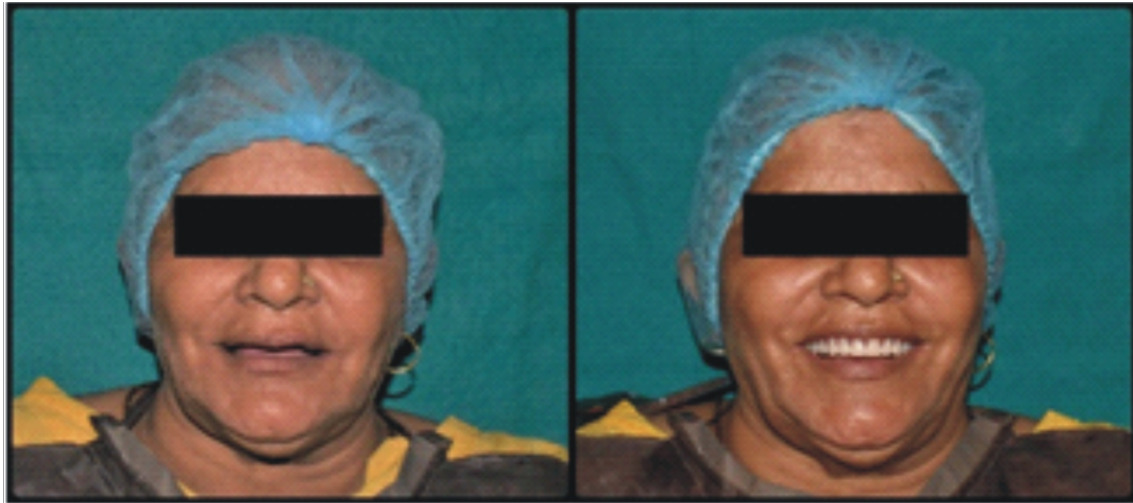## 2.f Denture try-in and insertion

A denture try-in was performed. The denture insertion was done and verified for occlusion, retention, and stability.



## 2.g Pre-rehabilitative and Post-rehabilitative view

The patient was satisfied with the prosthesis.



## 3) References

1. **Rathee M, Alam M, Malik S, Divakar S, Chahal S.** Management of severely resorbed mandibular ridge using neutral zone technique: A case report. *AJOAD* 2022;11(01):32-34.
2. **Agrawal KK, Singh SV, Vero N, Alvi HA, Chand P, Singh K, Goel P.** Novel registration technique to register neutral zone. *J Oral BiolCraniofac Res.* 2012 Sep-Dec;2(3):198-202.
3. **Lynch CD, Allen PF.** Overcoming the unstable mandibular complete denture: the neutral zone impression technique. *Dent Update.* 2006 Jan-Feb;33(1):21-2, 24-6.