

# Subcutaneous Injection of Allogeneic Adipose-Derived Mesenchymal Stromal Cells in Psoriasis Plaques: Clinical Trial Phase I

Amir Bajouri, M.D.<sup>1#</sup>, Dorsa Dayani, M.D.<sup>1#</sup>, Anoushe Taj Sharghi, M.Sc.<sup>1#</sup>, Shahedeh Karimi, M.D.<sup>1</sup>, Maryam Niknejadi, M.D.<sup>2</sup>, Kasra Moeinabadi Bidgoli, M.D.<sup>1</sup>, Hoda Madani, M.D.<sup>1</sup>, Fatemeh Abbasi Kakroodi, M.Sc.<sup>1</sup>, Tina Blourieh, M.Sc.<sup>1</sup>, Sura Mardpour, Ph.D.<sup>1</sup>, Neda Jaroughi, M.Sc.<sup>1</sup>, Nasser Aghdami, M.D., Ph.D.<sup>1\*</sup>, Leila Ataie-Fashtami, M.D.<sup>1</sup>, Saeid Shafiyani, M.D.<sup>1</sup>, Massoud Vosough, M.D., Ph.D.<sup>1\*</sup>

1. Department of Regenerative Medicine, Cell Science Research Center, Royan Institute for Stem Cell Biology, ACECR, Tehran, Iran  
2. Department of Reproductive Imaging, Reproductive Biomedicine Research Center, Royan Institute for Reproductive Biomedicine, ACECR, Tehran, Iran

## Abstract

**Objective:** Mesenchymal stromal cells (MSCs) play immunomodulatory role in various autoimmune diseases. Previous pre-clinical and clinical studies have shown that MSCs could be a therapeutic modality for psoriasis. However, the mechanisms of treatment and its possible side effects are under investigation. In this study, the safety and probable efficacy of injecting allogeneic adipose-derived mesenchymal stromal cells (ADSCs) in psoriatic patients were evaluated.

**Materials and Methods:** In this phase I clinical study with six months of follow-up, total number of  $1 \times 10^6$  or  $3 \times 10^6$  cells/cm<sup>2</sup> of ADSCs were injected into the subcutaneous tissue of each plaque as a single dose in three males and two females (3M/2F) with a mean age of  $32.8 \pm 8.18$ . The primary outcome was safety. Changes in clinical and histological indexes, the number of B and T lymphocytes in local and peripheral blood, and serum levels of inflammatory cytokines were assessed. Paired t test was used to compare variables at two time points (baseline and six months after injection) and repeated measures ANOVA test was utilized for variables at three time points in follow-up visits.

**Results:** No major adverse effects such as burning, pain, itching, or any systemic side effects were observed following ADSCs injection, and the lesions showed slight to considerable improvement after injection. The mRNA expression levels of pro-inflammatory factors were reduced in the dermis of the patients after injection. The increased expression level of Foxp3 transcription factor in the patient blood samples suggested modulation of inflammation after ADMSCs administration. Six months after the intervention, no major side effects were reported, but skin thickness, erythema, and scaling of the plaques, as well as the PASI score, were decreased in majority of patients.

**Conclusion:** Our study suggested that ADSC injection could be considered as a safe and effective therapeutic approach for psoriatic plaques (registration number: IRCT20080728001031N24).

**Keywords:** Adipose-Derived Mesenchymal Stromal Cells, Cell Therapy, Psoriasis, Regenerative Medicine

**Citation:** Bajouri A, Dayani D, Taj Sharghi A, Karimi Sh, Niknejadi M, Moeinabadi Bidgoli K, Madani H, Abbasi Kakroodi F, Blourieh T, Mardpour S, Jaroughi N, Aghdami N, Ataie-Fashtami L, Shafiyani S, Vosough M. Subcutaneous injection of allogeneic adipose-derived mesenchymal stromal cells in psoriasis plaques: clinical trial phase I. Cell J. 2023; 25(6): 363-371. doi: 10.22074/CELLJ.2023.1973793.1167

This open-access article has been published under the terms of the Creative Commons Attribution Non-Commercial 3.0 (CC BY-NC 3.0).

## Introduction

Psoriasis is a chronic, immune-mediated, inflammatory dermatologic disease, which can involve other organs such as joints. The disease prevalence is 2% of the world population and 0.2-0.7% of Asian people (1). Erythematous scaling plaques are the characteristic involvement of skin in this disease. Psoriasis may be accompanied by diseases such as uveitis, Crohn's disease, celiac disease, non-alcoholic fatty liver disease (NAFLD), and metabolic syndrome, which can also result in cardiovascular disease and depression (2-5). The molecular and cellular pathogenesis of the disease have not been well understood, but it is proposed that autoimmunity of T-cells, particularly Th17 cells, leads to

increased production of interleukin-17 (IL-17) and IL-22 (5, 6-8). These cytokines induce keratinocyte proliferation, tumor necrosis factor- $\alpha$  (TNF- $\alpha$ ) and interferon- $\gamma$  (IFN- $\gamma$ ) production, and consequent inflammation (9). In addition, IL-17, IL-23, and IL-27 are detected in the serum, skin lesions, and peripheral blood of psoriatic patients. As these cytokines are in association with the pathogenesis of the disease (10).

The treatment of choice for mild to moderate psoriasis is a combination of glucocorticoids, vitamin D analogs, and phototherapy, which are used topically. Moderate to severe psoriasis often requires systemic treatment. Numerous case reports and case series have suggested

Received: 19/November/2022, Revised: 27/February/2023, Accepted: 05/April/2023

#These authors contributed equally in this study.

\*Corresponding Address: Department of Regenerative Medicine, Cell Science Research Center, Royan Institute for Stem Cell Biology, ACECR, Tehran, Iran

Emails: [nasser.aghdami@royaninstitute.org](mailto:nasser.aghdami@royaninstitute.org), [masvos@royaninstitute.org](mailto:masvos@royaninstitute.org)



Royan Institute  
Cell Journal (Yakhteh)

that tonsillectomy has a therapeutic effect on patients with guttate psoriasis and plaque psoriasis (11).

In recent years, the development of various psoriasis treatments has accelerated and resulted in using advanced drugs like methotrexate (MTX), cyclosporine A, and retinoids, which are traditionally considered as systemic medications (11). However, these purported drugs are not ideal and have some limitations, such as decreased potency over time, potentially serious side effects, and poor clinical response in some patients. Also, many patients with psoriasis do not respond to a systemic therapy. Therefore, there is a need for innovative methods to treat severe psoriasis (12).

Applying weighted gene co-expression network analysis (WGCNA) on RNA-seq data from psoriasis patients has identified several networks of coding and non-coding genes associated with psoriasis and biological drug treatments, including networks enriched for short-chain fatty acid metabolism and olfactory receptor activity. It is likely that non-coding genes play critical roles in the regulation of pathways involved in the pathogenesis of psoriasis (13).

Mesenchymal stromal cells (MSCs) are multipotent stem cells found in tissues such as bone marrow, peripheral blood, adipose tissue, synovia, placenta, umbilical cord blood, Wharton's jelly, decidua basalis, ligamentum flavum, amniotic fluid, dental pulp, and breast milk. MSCs are characterized according to minimal criteria announced by the International Society for Cellular Therapy (ISCT) (14). MSCs have an immunomodulatory effects on T cells, dendritic cells, B cells, natural killer (NK) cells, and macrophages (15, 16). Moreover, MSCs can modulate neutrophil inflammatory activity by reducing neutrophilic apoptosis (17).

Recently, much attention is paid to MSCs' therapeutic potentials, considering their immunomodulatory and regenerative capabilities. Therefore, many studies have proposed MSCs as a treatment choice for different autoimmune diseases, e.g. psoriasis (18-22). In a study conducted by De Jesus et al. (18), autologous MSCs were infused intravenously at a dose of 0.5-3.1 million cells/kg in two patients with psoriasis. Both patients demonstrated a decrease in PASI after MSC infusion and neither one showed serious adverse outcomes. Sah et al. (21) reported that subcutaneous injection of allogeneic SOD3-transduced MSCs significantly prevented psoriasis development in IMQ-induced mouse models. Furthermore, in a phase I/IIa single-arm study conducted by Cheng et al. (23), seventeen psoriatic patients underwent  $1.5 \times 10^6$ /kg infusion of human umbilical cord-derived MSCs (UMSCs) four times. They concluded that allogeneic UMST is safe and partially effective in psoriasis patients, and the number of Tregs may be used as a potential biomarker to predict the clinical efficacy of UMST.

In this study, we aimed to evaluate the safety and probable efficacy of subcutaneous transplantation of ADSCs for treating skin lesions in patients with psoriasis plaques.

## Materials and Methods

### Patients and study design

This study was a phase I, open-label clinical trial designed to evaluate the safety and potential efficacy of allogeneic ADSCs in patients with psoriasis plaque.

Three males and two females with a mean age of  $32.8 \pm 8.18$  with persistent psoriatic plaques for more than six months and resistance to conventional treatments were enrolled in this study. Other eligibility criteria were age  $>18$ , and psoriasis area and severity index (PASI) score  $<12$ . Patients with recent lesions or any increase in the size of previous lesions during the last six months, severe chronic diseases, uncontrolled diabetes or hypertension, history of any types of cancer, human immunodeficiency virus (HIV), hepatitis B virus (HBV) or hepatitis C virus (HCV) positive tests, active local or systemic infection, immunosuppressive treatments in the past four weeks or topical agents except emollients in the past two weeks, and pregnant or lactating women were not eligible.

Two patients received  $1 \times 10^6$  cells/cm<sup>2</sup> and three patients underwent subcutaneous injections of  $3 \times 10^6$  cells/cm<sup>2</sup> of allogeneic ADSCs in their psoriasis plaques using a 28 gauge needle. In both groups, after the first patients received the cells, they were monitored for any adverse events (AEs) for up to six months. If severe AEs did not occur, the next participants in each group received ADSCs and were followed for six months according to the safety protocol. The participants were asked not to apply topical steroids and tacrolimus, vitamin D derivatives or any other topical treatments except emollients.

All participants signed an informed consent before participation in this trial. The study was approved by the Ethics Committee of the Iran University of Medical Sciences (IR.ACECR.ROYAN.REC.1394.1) and is registered at [www.irct.ir](http://www.irct.ir) with registration number IRCT20080728001031N24.

### Adipose-derived stromal cells' isolation, cultivation, and identification

The adipose tissues were obtained from healthy male donors who had consented to use their cells in this study. Donors aged 20 years or above with a body mass index of 25 to 29.9 kg/m<sup>2</sup>. Prior to collecting the adipose tissue, the donors were screened for hepatitis B and C viruses, human immunodeficiency virus, human T-cell lymphotropic virus 1 and 2, Epstein-Barr virus, cytomegalovirus, and parvovirus B19. Donors underwent medical examinations and tests to confirm their health status. Allogeneic adipose-derived MSCs (Ad-MSCs) isolation, characterization, differentiation potential, and preparation methods are provided as supplementary data.

### Adipose tissue-derived stromal cells injection

As mentioned above,  $1 \times 10^6$  and  $3 \times 10^6$  ADSCs/cm<sup>2</sup> diluted in 3-5 ml normal saline was injected subcutaneously into the

psoriatic lesions of two and three patients, respectively.

### Safety and tolerability assessment

The primary observation of our study was patients' safety. We recorded all local AEs such as burning, pain, itching, or any systemic side effects including fever, rash, and loss of consciousness during follow-up visits based on Common Terminology Criteria for AEs (CTCAE) (24). Patients were visited every week during the first month, and then 3, and six months after injection.

### Clinical assessments

PASI score and the size of the injected psoriatic lesions were measured before and six months after ADSCs injection. Skin (epidermal and dermal) thickness was also measured by ultrasonography at the same time points (Samsung WS80A, Linear array transducer, 9-16 KHz). The severity of the disease from both the patient's and physician's perspectives were documented at the beginning of the study and six months after cell injection. Interestingly, patients and our physicians reported improvements in thickness, erythema, crust, and surface appearance at 1, 3, and six months after the injections.

### Histopathological assessments

The formalin-fixed skin specimens were paraffin-embedded and related slides were prepared and stained by hematoxylin and eosin (H&E). Staining of the T-cell subsets was performed using the following polyclonal primary antibodies: anti-CD3 antibody (ab5690, dilution 1:100, Abcam, Cambridge, UK), anti-IL-17 antibody (sc-7927, dilution 1:50, Santa Cruz, California, USA) and anti-Foxp3 antibody (ab4728, dilution 1:100, Abcam, Cambridge, UK).

### Local and peripheral blood B and T lymphocytes

#### Sample collection and storage of peripheral blood mononuclear cells

Blood samples (3 ml) were acquired from the median antecubital vein of each patient. Peripheral blood mononuclear cells (PBMCs) were isolated using the Ficoll density gradient centrifugation method from heparinized blood. The viability of isolated PBMCs was assessed via trypan blue exclusion assay. PBMCs were frozen in liquid nitrogen and stored for six months.

### Flow cytometry

The number of lymphocyte subsets was determined by flow cytometry analysis. Cells were washed and resuspended in phosphate-buffered saline (PBS). A total number of  $1 \times 10^5$  to  $1 \times 10^6$  cells were added to each test tube. Cells were first incubated with purified anti-CD3 (eBioscience, San Diego, CA, USA), Allophycocyanin (APC)-conjugated anti-CD4 (BD Pharmingen, San Diego, CA, USA), Phycoerythrin (PE)-conjugated anti-CD8 (Cyto Matin Gene, Isfahan, Iran), and PE-conjugated anti-CD19 (eBioscience, San Diego, CA, USA) antibodies.

Alexa Fluor 488 anti-human IgG conjugated was added as a secondary antibody (Invitrogen, Carlsbad, CA, USA). Live lymphocyte cells were gated, and the percentages of CD3<sup>+</sup>CD4<sup>+</sup>, CD3<sup>+</sup>CD8<sup>+</sup>, and CD19<sup>+</sup> cells were measured. Appropriate matched conjugated immunoglobulin G antibodies were used as isotype controls. Three-color flow cytometric analyses were acquired using FACS Calibur and FlowJo version 7 software (Tree Star, Ashland, OR, USA).

### Assessment of inflammatory cytokines

A punch biopsy of the skin lesions (2 mm) was collected from each patient before and after the treatment. Total mRNA and DNA were extracted simultaneously from the skin lesions using AllPrep DNA/RNA Mini Kit (Qiagen, USA). The mRNA expression level of cytokines including TNF- $\alpha$ , IL-10, IL-17, IL-22, IL-23, and Foxp3 was evaluated by quantitative real time polymerase chain reaction (qRT-PCR). The  $2^{-\Delta\Delta Ct}$  method was used to determine relative gene expression levels. Primer sequences are available in the supplementary file.

### Statistical analysis

Data are presented as means  $\pm$  standard deviation (SD). Paired t test was used to compare variables at two time points (baseline and six months after cell injection) and the repeated measures ANOVA test for variables at three time points in follow up visits. A  $P < 0.05$  was considered statistically significant. We used SPSS version 24 (IBM, US) for statistical analysis.

## Results

### Characteristics of the patients

Five patients including three males and two females with a mean age of  $32.8 \pm 8.18$  with psoriatic plaques enrolled from 2018 to 2020. Two patients received  $1 \times 10^6$  cells/cm<sup>2</sup> and three were treated with  $3 \times 10^6$  cells/cm<sup>2</sup> of ADSCs.

All patients were complying and came back for follow-up visits and none of them dropped out of the study. The basic demographic and clinical characteristics of the patients are listed in Table 1.

Patient No. 1 was a 25-year-old male with psoriasis for 19 years. The knees and elbows were the first involved sites in his body. He had lesions on his scalp, face, ear, elbows, hands, trunk, knees, legs, and ankles. No nail or joint involvements were observed. He was not taking any medications when entering the study, but he mentioned using MTX and psoralen and long-wave ultraviolet radiation (PUVA) therapy in the past. No family members were diagnosed with psoriasis. Diabetes mellitus type 2 was reported in his father, uncle, and grandfather. His grandfather also had a brain tumor, which the patient did not have much information about. His right elbow lesion, measured  $2 \times 4$  cm<sup>2</sup>, was chosen for injection using  $1 \times 10^6$  cells/cm<sup>2</sup>.

**Table 1:** Baseline characteristics of the patients

Patient number	1	2	3	4	5
Age (Y)	25	26	36	26	33
Sex	M	F	M	F	M
BMI (kg/m <sup>2</sup> )	32.65	19.77	25.24	17.41	22.7
BSA (%)	14	6	8	1	6
PASI	8.9	4.7	5.2	0.7	2.4
Nail involvement	-	-	Mild	-	-
Arthritis	-	-	Mild	-	-
Other AD	-	-	-	-	-
FH of psoriasis	-	+	+	+	-
FH of AD	+	-	-	+	-
Previous medications	-	Betamethasone, Clobetasol	-	-	-
Treatment site	Elbow	Back	Hand	Retro auricular	Wrist
Duration (Y)	19	14	27	8	15
Primary lesion size (cm <sup>2</sup> )	8	4	20	12	25
Number of cells/cm <sup>2</sup>	1×10 <sup>6</sup>	1×10 <sup>6</sup>	3×10 <sup>6</sup>	3×10 <sup>6</sup>	3×10 <sup>6</sup>

M; Male, F; Female, BMI; Body mass index, BSA; Body surface area, PASI; Psoriasis area and severity index, AD; Autoimmune disease, and FH; Family history.

Patient No. 2 was a 26-year-old female with 14 years of history of psoriasis, which started with scalp lesions as its first presentation. She had forehead, ear, and posterior auricular, abdomen, back, and leg lesions. She had no nail, joint, or eye involvement and was under treatment with betamethasone and clobetasol. Her sister was also diagnosed with psoriasis. Her back lesion (2×2 cm<sup>2</sup>) was selected as an injection site with 1×10<sup>6</sup> cells/cm<sup>2</sup>.

Patient No. 3 was a 36-year-old man with psoriasis for 27 years. He had constant limb involvement: both hands and wrists, and both feet and ankles during the past 10 years. Mild arthritis in the toes and mild nail involvement were observed. He had only used emollients for the past two years but he mentioned using various treatments such as vitamin D derivatives, topical corticosteroids, methotrexate, cyclosporine, acitretin, etanercept, and neotigazon prior to using emollients. A total number of 3×10<sup>6</sup> cells/cm<sup>2</sup> was injected into the dorsal side of his right hand in one session. His lesion size was 2×3 cm<sup>2</sup>.

Patient No. 4 was a 26-year-old female with 8 years history of psoriasis. Her father was suffering from the same disease, and she mentioned a history of vitiligo in her grandmother. Her involved areas were both posterior auricular sites. She had no nail or joint involvement and was not using any medications. She had been under treatment with corticosteroids for four years before entering the study. Injection of 3×10<sup>6</sup> cells/cm<sup>2</sup> MSCs was performed in her left post-auricular lesion measuring 2×6 cm<sup>2</sup>.

Patient No. 5 was a 33-year-old male with 15 years

history of the disease. His palms, thighs, and soles were involved and a history of using topical corticosteroids was recorded before entering the study. He received 3×10<sup>6</sup> cells/cm<sup>2</sup> ADSCs in his left wrist lesion measured about 2.5×4 cm<sup>2</sup>.

### Safety and tolerability profile

AEs following ADSC injections are summarized in Table 2. No severe AEs during the main course of the study and the follow-up visits were reported. Patient No. 1 mentioned mild burning on the day of injection, which improved the day after. Patient No. 2 did not report any AEs or discomfort after the injection. Patient No. 3 reported mild pain on the first day of injection, which improved over several days. Patients No. 4 and 5 did not mention any burning, pruritis, or any other AEs after ADSC injection.

### Clinical findings

The clinical outcomes of the study are mentioned in Table 2. In summary, patient No. 1 reported mild improvement in lesion erythema, scaling, and a decrease in skin thickness. No changes in pruritis were reported. Six months following the injection, PASI score decreased from 8.9 to 7.3. From the patient and physician's points of view, there were mild improvements in lesion severity. Using ultrasonography, the skin thickness of the elbow was changed from 8 mm to 5 mm in patient No. 1 (Fig.1A, B).

Table 2: Safety and efficacy outcomes

Patient number	PASI		Skin thickness (mm)		Lesion severity (0-4)		Severity change (physician) (-2 to +2)	Severity change (patient) (-2 to +2)	Adverse events	
	Before	After 6 m	Before	After 6 m	Before	After 6 m			Type	Severity
1	8.9	7.3	8	5	3	3	-1	-1	Burning	Mild
2	4.7	4.3	2.3	2.4	2	2	0	0	-	-
3	4.7	4.3	2.1	1.7	3	2	-1	-1	Pain	Mild
4	0.7	0.4	1.8	1.5	2	1	-1	-2	-	-
5	2.4	1.8	3.3	2.6	3	2	-1	-1	-	-

PASI; Psoriasis area and severity index.

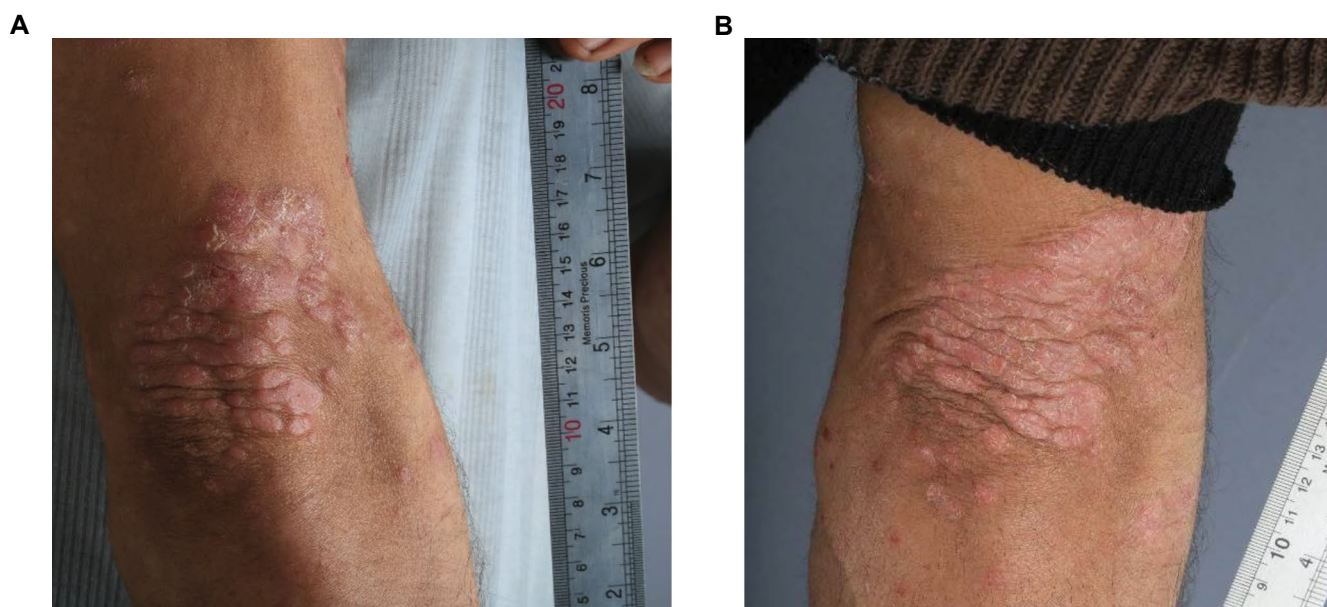

Fig.1: Photographs of the right elbow of patient no.1 before and after cell therapy. **A.** Patient No. 1 with psoriatic plaques on his right elbow on the day of adipose-derived mesenchymal stromal cell (ADSC) injection with treatment dosage of  $1 \times 10^6$  cells/cm<sup>2</sup>. **B.** Patient No. 1 six months after ADSC injection in right elbow, decreased erythema and scaling were observed.

Patient No. 2 did not have any noticeable changes in the characteristics of the lesions. Skin thickness was measured at 2.3 mm and 2.4 mm, before and six months after injection, respectively. The PASI score for patient No. 3 was changed from 4.7 to 4.3 after cell injection. Six months following cell transfer, erythema, scaling, and thickness of the injected sites were significantly decreased. Skin thickness was decreased from 2.1 mm to 1.7 mm, which was similar to the healthy part of his hand. This patient reported better quality of life. (Fig.2A, B).

Patient No. 4 reported an obvious reduction in lesion scaling, thickness, and erythema. She did not report any reactions after cell injection. Skin thickness lessening was confirmed by ultrasonogram (1.8 mm to 1.5 mm). Our physician reported one-point improvement in lesion severity after six months. Her PASI scores were 0.7 before and 0.4 six months after the injection.

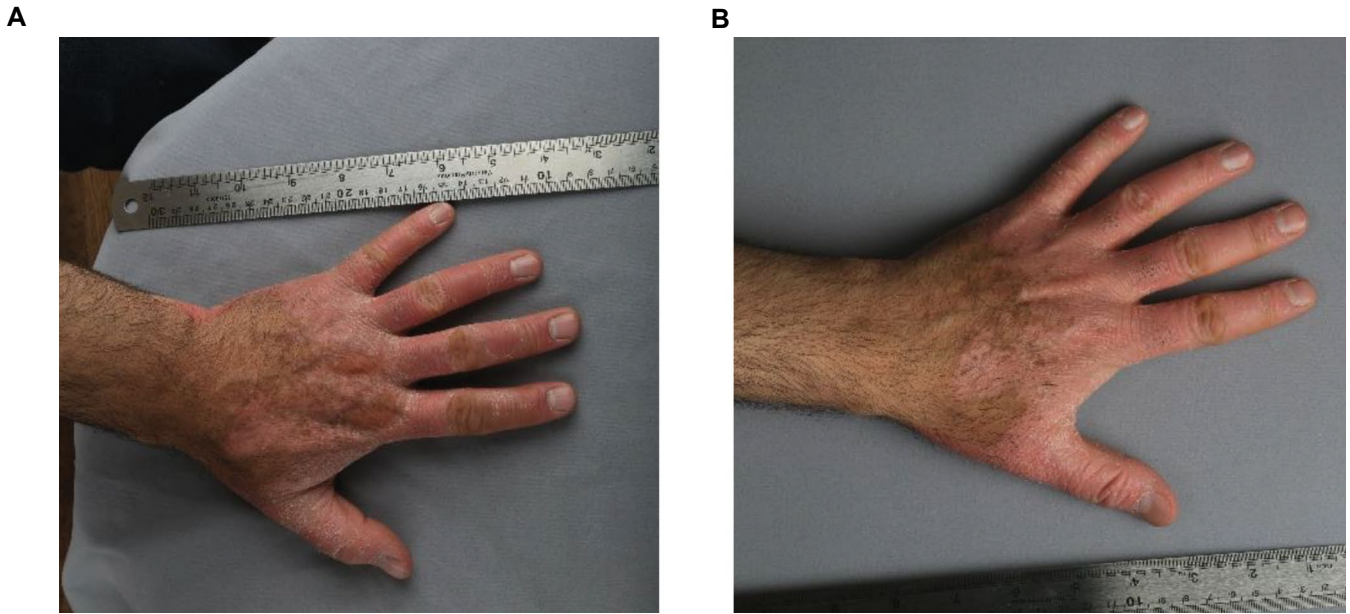
Patient No. 5 received  $3 \times 10^6$  cells/cm<sup>2</sup> ADSCs in his wrist lesion and the PASI score was reduced from 2.4 to 1.8. Skin thickness noticeably decreased from 3.3 mm to

2.6 mm. This patient and the physician reported a one-point improvement in lesion severity.

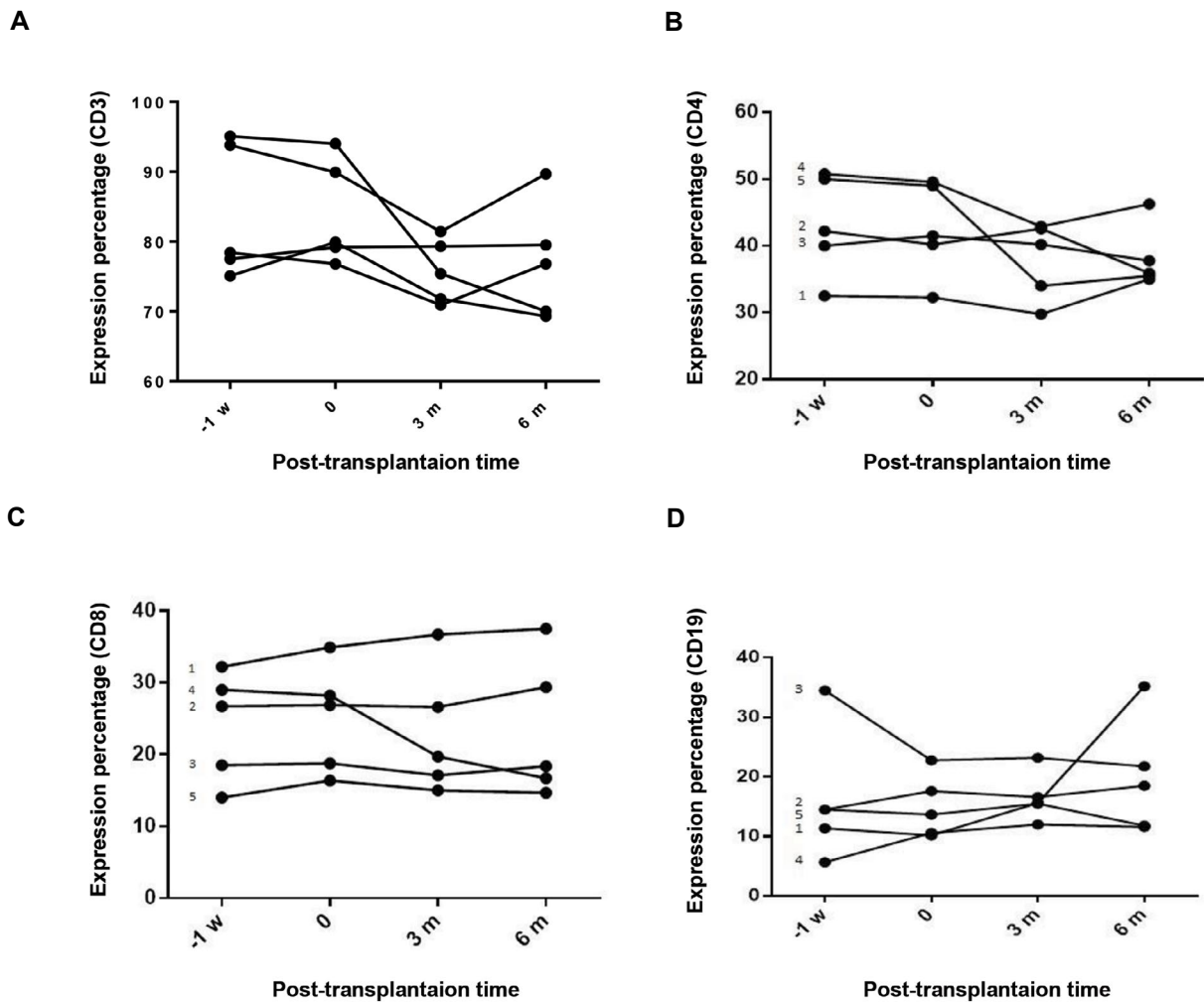
All three patients who underwent  $3 \times 10^6$  cells/cm<sup>2</sup> ADSCs injection showed a remarkable decrease in disease severity six months after the injections, which was confirmed by the physician. Moreover, these patients reported better quality of life after the treatment. No notable changes in disease severity were observed in the two patients who received  $1 \times 10^6$  cells/cm<sup>2</sup>. Comparing these two groups, a higher number of injected cells resulted in a better improvement in the disease course.

### Population of B and T lymphocytes

Any changes in the populations of T and B lymphocytes after the administration of ADSCs were measured in blood samples. Flow cytometry analysis showed that the number of B and T lymphocytes were not significantly different before and after the injections (Fig.3).



**Fig.2:** Photographs of the left hand of patient No.3 before and after cell therapy. **A.** Patient No. 3 on the day of adipose-derived mesenchymal stromal cell (ADSC) injection with dosage of  $3 \times 10^6$  cell/cm<sup>2</sup> in the dorsal side of left hand. **B.** Patient No. 3 after ADSC injection in the left hand, decreased erythema and scaling were observed.



**Fig.3:** Changes in population of T and B lymphocytes in blood of patients after ADSCs injection. **A.** Representative the frequency of T cell population, **B.** The frequency of T helper cell population, **C.** The frequency of T cytotoxic cell population, and **D.** The frequency of B cell population within lymphocytes. Data are analyzed using repeated measure ANOVA and represented as mean  $\pm$  SD ( $P < 0.05$ ). ADSCs; Adipose-derived mesenchymal stromal cells, w; Week, and m; Month.

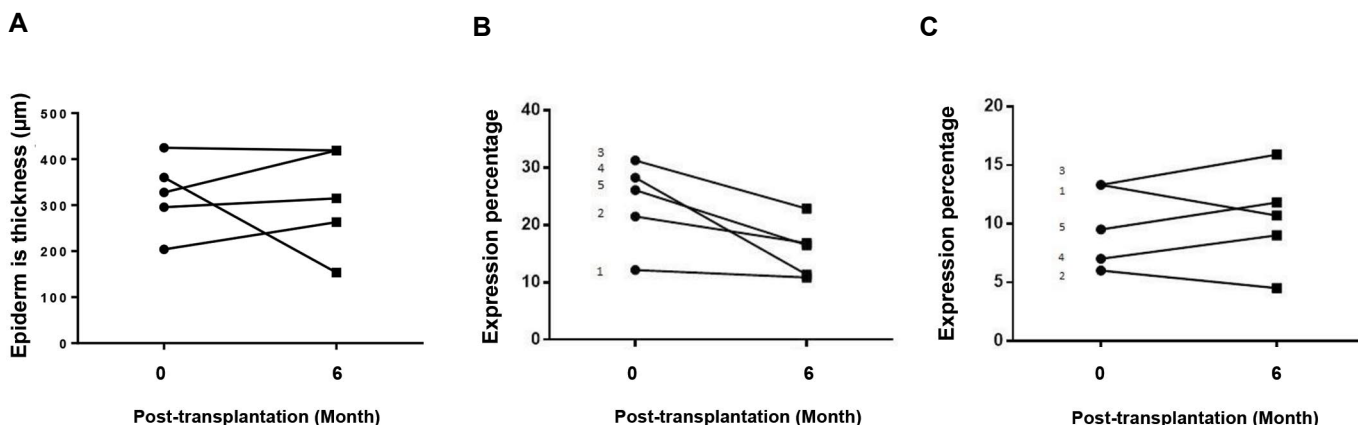
### Histological findings

Measurements of epidermal thickness showed significant differences in some patients before and six months into the study. However, skin immunohistochemistry for IL-17 showed that the inflammation in the dermis decreased following the injection and the number of FOXP3<sup>+</sup> cells in the second

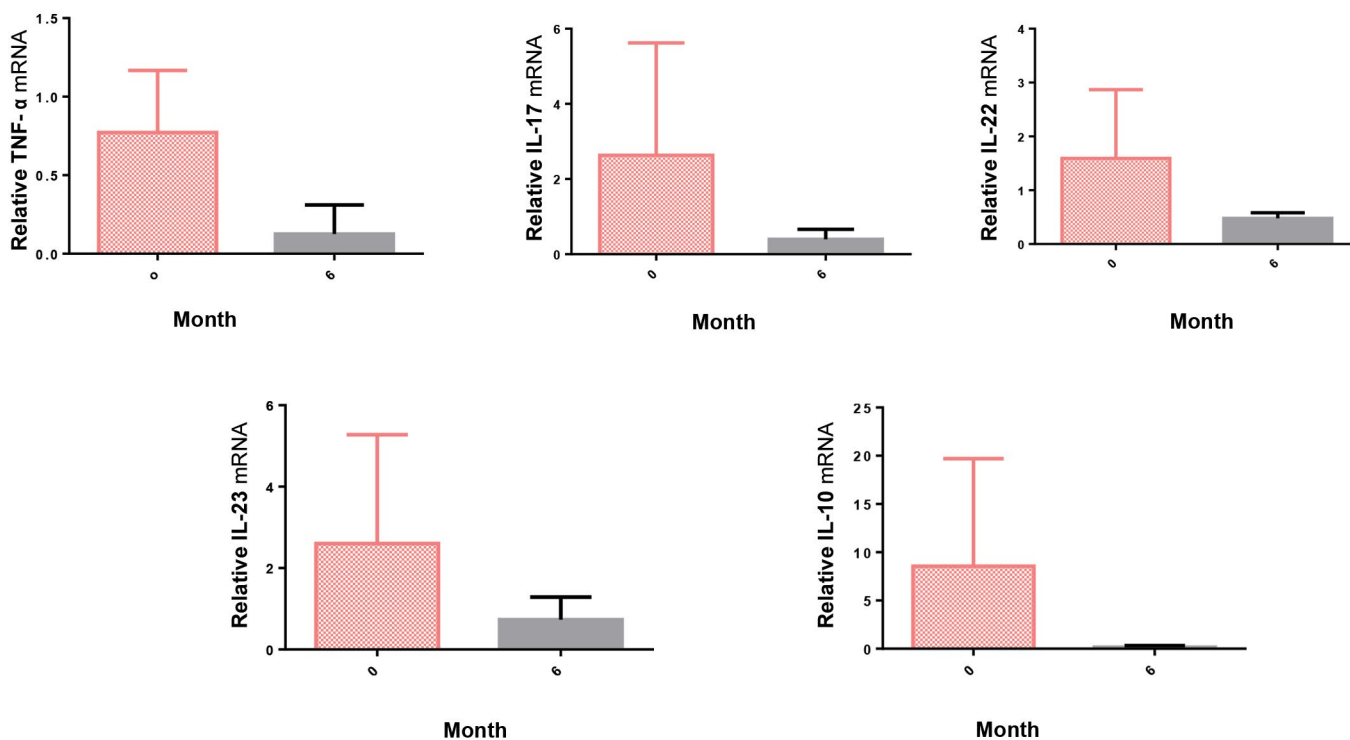
group of patients increased, indicating the modulation of inflammation after cell injections (Fig.4).

### Inflammatory cytokines profile

Quantification of mRNA expression of pro-inflammatory factors in the dermis of the patients after injection showed a decreasing trend in all cytokines (Fig.5).



**Fig.4:** Changes in expression of immune cell markers in psoriatic lesions after AMSCs injection. **A.** Measurement of mean epidermal thickness, **B.** Evaluation of T helper17 cells, and **C.** Treg cells from biopsy specimens. Data are analyzed using paired t test and represented as mean ± SD [P<0.05 (before treatment vs. after 6 months in all cases)]. AMSCs; Adipose-Mesenchymal stromal cells.



**Fig.5:** Changes in messenger RNA expression of inflammatory cytokines in psoriatic lesions after adipose-derived mesenchymal stromal cells (ADSCs) injection. Total RNA was isolated from the skin biopsy at baseline and 6 months after transplantation and quantitative real-time polymerase chain reaction (PCR) was performed to evaluate inflammatory cytokines. Statistical significance is displayed for all the samples, error bar indicates SD [P<0.05 (before treatment vs. after 6 months in all cases)]. Paired t test was used for analyzing the data.

## Discussion

The treatment strategy for psoriasis is adjusted based on the severity of the disease. Topical calcineurin inhibitors such as tacrolimus, topical corticosteroids, topical keratolytics, vitamin D3 analogs, and phototherapy are usually considered as the treatment of choice for mild psoriasis. These medications seem to have slight effects on moderate-to-severe psoriasis and have concomitant side effects after long-term application. Biologic agents such as anti-TNF- $\alpha$ , IL-17, IL-23, and oral systemic medications such as acitretin, cyclosporine, and methotrexate, which are the most common cytotoxic drugs used in psoriasis, are mainly prescribed for moderate to severe psoriasis. These drugs come along with side effects like teratogenicity, leukopenia, and hepatotoxicity (24, 25). New monoclonal antibodies are expensive and not completely safe, as the risk of opportunistic infections is considerable following their administration (26). Moreover, these conventional therapies are used to control symptoms and do not instate long-term and effective treatment for psoriasis. Therefore, it is crucial to find safe and effective alternative therapies.

Chen et al. (27) studied MSC injection on imiquimod-induced psoriatic lesions in mice. Before injection, they observed up-regulation of proinflammatory cytokines (IL-1 $\beta$ , IL-6, IL-17, and IL-23) in psoriasis, whereas the anti-inflammatory cytokine, IL-10, was decreased. MSC injection into the psoriatic plaques corrected this imbalance. The expression of proinflammatory cytokines was decreased and IL-10 was significantly increased in MSC-treated mice compared to the control group. Furthermore, IL-17, IL-23, and IFN- $\gamma$  were notably diminished.

In an experimental study by Lee et al. (19), human umbilical cord blood-derived MSCs (UMSCs) were injected subcutaneously in psoriatic lesions induced by topical imiquimod or IL-23 injection in mouse models. The results showed a decrease in Th17. It was concluded that MSC injection inhibits CD4<sup>+</sup> T cell activation both directly and indirectly by regulating activation of dendritic cells.

In a study conducted in 2020, 3 $\times$ 10<sup>6</sup>/kg allogeneic gingival tissue-derived MSC were injected into a psoriasis plaque in five sessions in a young male with severe psoriasis. The patient had not responded to other previous treatments, but after five consecutive injections, he was psoriasis-free for three years (28).

In a study by Cheng et al. (23), UMSCs were intravenously injected into 17 psoriasis patients in two different stages. In the first stage, 18 patients received a single dose of 1.5 $\times$ 10<sup>6</sup>/kg cells every two weeks for a total of four times, where 17 patients completed the first stage. In the second stage, 12 of the 13 enrolled patients were divided into four groups of escalating doses (1.5, 2.0, 2.5, 3.0 $\times$ 10<sup>6</sup>/kg). Groups under 1.5 and 2 $\times$ 10<sup>6</sup>/kg received injections every two weeks,

and the remaining were infused every 30 days, four times. The outcomes of the study were evaluated by PASI and Physician Global Assessment (PGA) scores. Eight out of 17 patients (41.7%) under this two-staged treatment showed at least 40% improvement. A significant decrease was observed in the number of CD4<sup>+</sup> TCM (central memory) cells, Treg cells, and Treg/Th17 ratio in the response group, compared to the no-response group. Also, the levels of Treg cells were significantly increased after UMSC injection. Based on these results, besides the considerable post-injection decrease in the number of CD4<sup>+</sup> naive T cells and Th17 cells, Cheng et al. (23) suggest that MSCs play their immunomodulatory role by inducing the differentiation of naive T cells to effector and memory T cells. Furthermore, no severe AEs were reported following the cell injections.

In our study, local injections of MSCs were safe in all patients. Four out of five patients slightly responded to MSC therapy regarding the PASI scoring assessment. Measurement of proinflammatory cytokines such as IL-17, IL-22, IL-23, and TNF- $\alpha$  6 months after MSC injections, showed down regulation of the cytokines, which was in accordance with previous studies. No significant changes in the number of blood B and T cells were detected. Biopsies of psoriatic plaques before and after the trial did not show a decline in the T cell population; however, Th-17 reduction was observed after treatment. Also, the Treg cell population increased six months after MSC injection, while we observed a reduced mRNA expression level of *Foxp3*, a master marker of Tregs. Considering all the changes during the study, it seems that MSC therapy modified the pathogenesis of the disease. Injection of higher numbers of MSCs resulted in noticeable changes in patients.

## Conclusion

The injection of MSCs into psoriasis lesions is potentially a safe and efficient therapy for patients with psoriasis. Further studies with larger sample sizes will need to be conducted to find the best dosage, method, and injection frequency and detect probable adverse reactions. Evaluation of the efficacy outcome after multiple injections is highly recommended.

## Acknowledgements

We would like to express our gratitude to our colleagues in Regenerative Medicine Department at Royan Institute. This study was supported by Royan Institute by the grant number 91000209. The authors declare no conflicts of interest.

## Authors' Contributions

A.B., D.D., A.T.S.; Data collection, analysis, drafting, and editing the manuscript. S.K., M.N., K.M.B., H.M.; Data collection and analysis. F.A.K., T.B., S.M., N.J.; Data collection, cell preparation, administration, and data



analysis. N.A., L.A.-F., S.S., M.V.; Supervising project, data analysis, study design, reviewing the manuscript, and final approval. All authors read and approved the final manuscript.

## References

1. Christophers E. Psoriasis--epidemiology and clinical spectrum. *Clin Exp Dermatol.* 2001; 26(4): 314-320.
2. Birkenfeld S, Dreither J, Weitzman D, Cohen AD. Coeliac disease associated with psoriasis. *Br J Dermatol.* 2009; 161(6): 1331-1334.
3. Gelfand JM, Troxel AB, Lewis JD, Kurd SK, Shin DB, Wang X, et al. The risk of mortality in patients with psoriasis: results from a population-based study. *Arch Dermatol.* 2007; 143(12): 1493-1499.
4. Gisondi P, Targher G, Zoppini G, Girolomoni G. Non-alcoholic fatty liver disease in patients with chronic plaque psoriasis. *J Hepatol.* 2009; 51(4): 758-764.
5. Oliveira Mde F, Rocha Bde O, Duarte GV. Psoriasis: classical and emerging comorbidities. *An Bras Dermatol.* 2015; 90(1): 9-20.
6. Boyman O, Hefti HP, Conrad C, Nickoloff BJ, Suter M, Nestle FO. Spontaneous development of psoriasis in a new animal model shows an essential role for resident T cells and tumor necrosis factor-alpha. *J Exp Med.* 2004; 199(5): 731-736.
7. Cheuk S, Wikén M, Blomqvist L, Nylén S, Talme T, Stähle M, et al. Epidermal Th22 and Tc17 cells form a localized disease memory in clinically healed psoriasis. *J Immunol.* 2014; 192(7): 3111-3120.
8. Conrad C, Boyman O, Tonel G, Tun-Kyi A, Laggner U, de Fougères A, et al. Alpha1beta1 integrin is crucial for accumulation of epidermal T cells and the development of psoriasis. *Nat Med.* 2007; 13(7): 836-842.
9. Conrad C, Meller S, Gilliet M. Plasmacytoid dendritic cells in the skin: to sense or not to sense nucleic acids. *Semin Immunol.* 2009; 21(3): 101-109.
10. Kim J, Krueger JG. The immunopathogenesis of psoriasis. *Dermatol Clin.* 2015; 33(1): 13-23.
11. Rendon A, Schäkel K. Psoriasis pathogenesis and treatment. *Int J Mol Sci.* 2019; 20(6): 1475.
12. Naik PP. Stem cell therapy as a potential treatment option for psoriasis. *An Bras Dermatol.* 2022; 97(4): 471-477.
13. Ahn R, Gupta R, Lai K, Chopra N, Arron ST, Liao W. Network analysis of psoriasis reveals biological pathways and roles for coding and long non-coding RNAs. *BMC Genomics.* 2016; 17(1): 841.
14. Samsonraj RM, Raghunath M, Nurcombe V, Hui JH, van Wijnen AJ, Cool SM. Concise review: multifaceted characterization of human mesenchymal stem cells for use in regenerative medicine. *Stem Cells Transl Med.* 2017; 6(12): 2173-2185.
15. Singer NG, Caplan AI. Mesenchymal stem cells: mechanisms of inflammation. *Annu Rev Pathol.* 2011; 6: 457-478.
16. Zhao Q, Ren H, Han Z. Mesenchymal stem cells: immunomodulatory capability and clinical potential in immune diseases. *J Cell Immunother.* 2016; 2(1): 3-20.
17. Hsu SC, Wang LT, Yao CL, Lai HY, Chan KY, Liu BS, et al. Mesenchymal stem cells promote neutrophil activation by inducing IL-17 production in CD4+ CD45RO+ T cells. *Immunobiology.* 2013; 218(1): 90-95.
18. De Jesus MM, Santiago JS, Trinidad CV, See ME, Semon KR, Fernandez MO Jr, et al. Autologous adipose-derived mesenchymal stromal cells for the treatment of psoriasis vulgaris and psoriatic arthritis: a case report. *Cell Transplant.* 2016; 25(11): 2063-2069.
19. Lee YS, Sah SK, Lee JH, Seo KW, Kang KS, Kim TY. Human umbilical cord blood-derived mesenchymal stem cells ameliorate psoriasis-like skin inflammation in mice. *Biochem Biophys Res.* 2016; 9: 281-288.
20. Owczarczyk-Saczonek A, Krajewska-Włodarczyk M, Kruszewska A, Placek W, Maksymowicz W, Wojtkiewicz J. Stem cells as potential candidates for psoriasis cell-replacement therapy. *Int J Mol Sci.* 2017; 18(10): 2182.
21. Sah SK, Park KH, Yun CO, Kang KS, Kim TY. Effects of human mesenchymal stem cells transduced with superoxide dismutase on imiquimod-induced psoriasis-like skin inflammation in mice. *Antioxid Redox Signal.* 2016; 24(5): 233-248.
22. Shin TH, Kim HS, Choi SW, Kang KS. Mesenchymal stem cell therapy for inflammatory skin diseases: clinical potential and mode of action. *Int J Mol Sci.* 2017; 18(2): 244.
23. Cheng L, Wang S, Peng C, Zou X, Yang C, Mei H, et al. Human umbilical cord mesenchymal stem cells for psoriasis: a phase 1/2a, single-arm study. *Signal Transduct Target Ther.* 2022; 7(1): 263.
24. Armstrong AW, Read C. Pathophysiology, clinical presentation, and treatment of psoriasis: a review. *JAMA.* 2020; 323(19): 1945-1960.
25. Zachariae H. Methotrexate side-effects. *Br J Dermatol.* 1990; 122 Suppl 36: 127-133.
26. Kalb RE, Fiorentino DF, Lebwohl MG, Toole J, Poulin Y, Cohen AD, et al. Risk of serious infection with biologic and systemic treatment of psoriasis: results from the psoriasis longitudinal assessment and registry (PSOLAR). *JAMA Dermatol.* 2015; 151(9): 961-969.
27. Chen M, Peng J, Xie Q, Xiao N, Su X, Mei H, et al. Mesenchymal stem cells alleviate moderate-to-severe psoriasis by reducing the production of type I interferon (IFN-I) by plasmacytoid dendritic cells (pDCs). *Stem Cells Int.* 2019; 2019: 6961052.
28. Wang SG, Hsu NC, Wang SM, Wang FN. Successful treatment of plaque psoriasis with allogeneic gingival mesenchymal stem cells: a case study. *Case Rep Dermatol Med.* 2020; 2020: 4617520.