

<https://doi.org/10.52418/moldovan-med-j.65-1.22.06>
UDC: 617.553-006-073



Comparative analysis of imaging investigations in the diagnosis of retroperitoneal tumors

*Victor Schiopu, Corina Scerbatiuc-Condur, Nicolae Ghidirim

Department of Oncology

Nicolae Testemitanu State University of Medicine and Pharmacy, Chisinau, the Republic of Moldova

Authors' ORCID iDs, academic degrees and contributions are available at the end of the article

*Corresponding author – Victor Schiopu, e-mail: victor.schiopu@usmf.md

Manuscript received May 09, 2022; revised manuscript June 17, 2022; published online August 29, 2022

Abstract

Background: Primary retroperitoneal tumors (PRT) are a group of extremely heterogeneous soft tissue tumors that grow in the retroperitoneal space and have no organic affiliation. Tumors usually become symptomatically late and cause secondary symptoms or become palpable once they have become significantly large. Preoperative diagnosis of PRT is essential for assessing subsequent treatment tactics, planning the approach and volume of surgery, by detecting the structural component, relationships with adjacent anatomical structures and the degree of invasion.

Material and methods: Complex prospective and retrospective analysis of clinical, anamnestic and imaging data of 118 patients with primary and non-primary retroperitoneal tumors, investigated and treated at the Institute of Oncology of the Republic of Moldova during 2015-2020.

Results: To determine the primary PRT diagnosis for the clinician, it is primordial to rule out the organic or secondary nature of the tumor. Thus, the patients were examined by: abdominal USG – 118 patients (100%), abdominal and small pelvic contrast-enhanced CT – 118 patients (100%), MRI – 3 patients (2.5%), videoesogastroduodenoscopy – 32 patients (27.1%), videocolonoscopy – 31 patients (26.3%), irigography – 4 patients (3.4%), urography – 29 patients (24.6%).

Conclusions: Contrast-enhanced CT provides more accurate data than USG. The image obtained at the USG examination is flat, therefore the dimensional measurements of the tumor are not always performed on the longest tumor axis, especially in the case of polylobulated or giant tumors, while the tomographic examination techniques allow the three-dimensional reconstruction of the tumor with more accurate assessment of the tumor size.

Key words: primary retroperitoneal tumors, diagnostic, sonography, computerized tomography.

Cite this article

Schiopu V, Scerbatiuc-Condur C, Ghidirim N. Comparative analysis of imaging investigations in the diagnosis of retroperitoneal tumors. *Mold Med J.* 2022;65(1):36-39. <https://doi.org/10.52418/moldovan-med-j.65-1.22.06>.

Introduction

Primary retroperitoneal tumors (PRT) are a commonly used term which defines a group of tumors developed from mesenchymal, neuronal, or vestigial tissue in the retroperitoneal space. They develop themselves in the space bounded by the posterior parietal peritoneum and the endoabdominal fascia, including extraorganic structures of fatty, connective, fascial, vascular, nervous tissues, muscle bundles, vessels and lymph nodes or embryonic vestiges, more frequently derived from urogenital tract [1-5]. Analyzing the data available in the literature, PRT are tumors with an incidence constituting 0.01-1.0% of all neoplasms of the human body [6-9]. In about 8% of cases they are malignant [10].

Preoperative diagnosis, especially in the case of small tumors, is a challenge, does not present a specific clinical picture and is frequently detected incidentally. The symptoms become clinically important as a result of compression, displacement or invasion of adjacent organs, being determined by the specific properties of the developmental

sites. Clinical syndromes occur depending on the affected organelles and vital structures [11-12].

The most common symptom of TRP is pain, which can be localized in the tumor area or diffuse, radiating throughout the abdominal cavity, loins or lower limbs. Abdominal pain or low back pain, according to the literature, occurs in 44–75% of patients later diagnosed with PRT. The nature of the pain may be permanent or intermittent, acute or insidious. Despite the fact that the pain manifests itself depending on the location of the tumor, it is difficult to determine its exact location. The main mechanism of pain is the direct compression by the tumor of the retroperitoneal or intraperitoneal anatomical structures.

Dyspeptic syndrome, with complex gastrointestinal symptoms, is often known in these patients. Meteorism and abdominal distension may occur in 4-35% of patients, and in some cases, intestinal occlusion may develop through compression or extrinsic invasion of the intestines.

Cachexia, weight loss, general weakness, and fatigue occur in 40–50% of patients with advanced retroperitoneal

malignancies, compared with only 3% of those with early-stage disease.

Pelvis-invading retroperitoneal tumors can compress or can grow in the sacral or lumbar plexus, causing back pain with irradiation in the lower limbs uni- or bilaterally. The edema of the lower limbs appears after compression of the pelvic veins and lymph ducts.

Fever, which is present in about 10% of patients with PRT, is due to necrosis and destruction of tumor tissue or urinary tract infections as a result of urostasis.

Occasionally, retroperitoneal tumors are found on physical or instrumental examination of patients due to bloating, early satiety, and abdominal discomfort. Only about 30.0% of patients with retroperitoneal tumors initially have asymptomatic abdominal mass, most of which are addressed when the tumor becomes palpable and is characterized by "secondary" symptoms. Abdominal tumor can be detected on physical examination in more than 90%. Considering that the frequent clinical picture is secondary, the diagnosis of PRT begins with laboratory analyzes and methods of paraclinical investigations useful for the differential diagnosis with a potential pathology of the manifest clinical organ.

The aim of the study. Evaluation of the usefulness of imaging tools: the degree of informativeness and accuracy for preoperative diagnosis of PRT.

Material and methods

Complex prospective and retrospective analysis of clinical, anamnestic and imaging data of 118 patients with primary and non-primary retroperitoneal tumors investigated and treated at the Institute of Oncology of the Republic of Moldova, during 2015-2020. The group of patients with PRT included in the study consisted of 48 women (57.1% (95% CI 46.5, 67.3)) and 36 men (42.9% (95% CI 32.7, 53.5)). The mean age of patients with PRT in the research group is 57 years ($\sigma = 12.0$), $Me = 59$, $Q1 = 51$, $Q3 = 67$.

Results

To determine the primary PRT diagnosis for the clinician, it is primordial to rule out the organic or secondary nature of the tumor. Thus, the patients were examined by: abdominal USG – 118 patients (100%), abdominal and small pelvic contrast-enhanced CT – 118 patients (100%), MRI – 3 patients (2.5%), videosogastroduodenoscopy – 32 patients (27.1%), videocolonoscopy – 31 patients (26.3%), irigography – 4 patients (3.4%), urography – 29 patients (24.6%).

Ultrasonography (USG) of the peritoneal cavity and retroperitoneal space is a first intention, cheap and highly informative imaging method. The main intention in applying this diagnostic method is to establish the presence of supracentimetric tumors. USG's ability to assess the origin and benign or malignant nature of retroperitoneal tumors is limited. The sensitivity of USG, according to the data presented in the literature is 84.6%. USG provides indirect information that may be useful in assessing the

retroperitoneal location of the neoplastic process. The use of the DOPPLER regime may highlight the presence of feeding vessels. The malignancy of the tumor formation has several criteria: irregular character, mixed structure and abundant vascularity.

The method of investigation CT with intravenous contrast or CT angiography offers a detailed and appropriate image of the PRT and the relationship it has with the anatomical structures or adjacent organs. This method of investigation provides sufficient information that may suggest the benign or malignant nature of the tumor, having a key role in planning the treatment strategy. [13]. Although it offers the possibility of a complex differential diagnosis and has a high degree of certainty in diagnosing a retroperitoneal tumor, CT examination is not able to differentiate between the 50 histological subtypes of retroperitoneal sarcoma [14].

Ultrasound examination and intravenous contrast CT of the abdominal cavity and retroperitoneal space were the main imaging methods applied in the study, in order to provide the necessary information for planning the surgery, used in all 118 patients (100%) included in the study and have provided information on: the size of the tumor, the location, the uni- or multicentric structure of the tumor, the character of the edges and the relationship of proximity with adjacent organs.

Both diagnostic investigations, USG and intravenous contrast CT, provide feasible data regarding TRP dimensions, but CT provides dimensional information with greater accuracy. The partial correlation between the dimensions of the operating part and the dimensions estimated at USG is 0.540 (95% CI 0.295, 0.737, $p < 0.001$), which represents a high positive correlation, as well as in the case of the dimensional values offered by CT 0.789 (95% CI 0.693, 0.873, $p < 0.001$), there is a significant positive correlation. Since the value of $p = 0.001$, this means that in both cases the partial correlations between the actual size of the tumor and the size provided by the diagnostic tests performed, USG and CT with intravenous contrast are statistically significant.

Regarding the determination of the uni- or multicentric character of the tumor, the CT showed an integrative value of sensitivity and specificity of 0.733 (95% CI 0.527, 0.939, $p < 0.001$), while the USG – a value of 0.644 (95% CI 0.415, 0.873, $p < 0.001$). Comparing the average quality of the USG vs CT model in detecting multifocal tumors, CT is more valuable (fig 1).

Contrast-enhanced CT, as a diagnostic test to identify the character of tumor margins, showed the integrative value of sensitivity and specificity of 0.617 (95% CI 0.490, 0.745, $p < 0.001$), which indicates that contrast-enhanced CT has a significantly better ability compared to an occasional diagnostic test. The USG-based method also showed a higher absolute value of AUC 0.720 (95% CI 0.601, 0.838, $p < 0.001$, interpretations being similar to CT), the average quality of the USG model being higher compared to the CT with intravenous contrast (fig. 2).

The assessment of the anatomical site is essential for

scheduling the type and volume of surgery. The diagnostic test used to determine the intra- or retroperitoneal location of the tumor based on intravenous contrast CT showed the integrative value of sensitivity and specificity at 0.620 (95% CI 0.496, 0.743, $p < 0.001$), while the test based on USG demonstrated the same integrative sensitivity and specificity values of 0.641 (95% CI 0.541, 0.740, $p < 0.001$), indicating that both CT and USG indicate good diagnostic accuracy. Analyzing the average quality of diagnostic models, USG is insignificantly higher compared to CT (fig. 3).

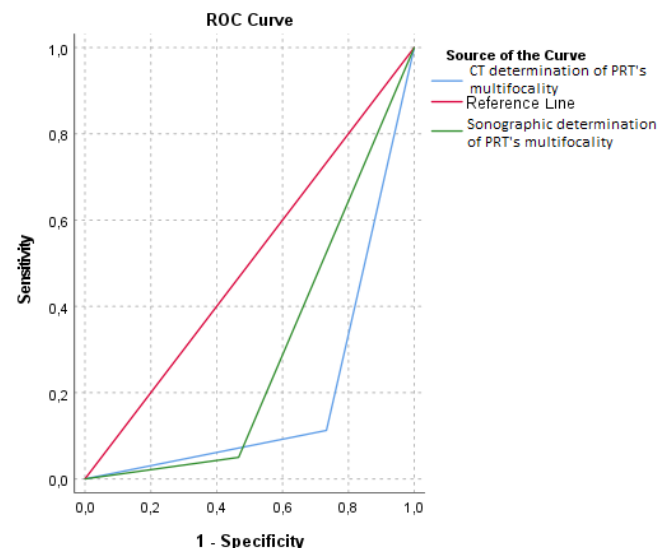


Fig. 1. ROC curve for USG and CT accuracy in determining the uni- or multicenter character of the tumor

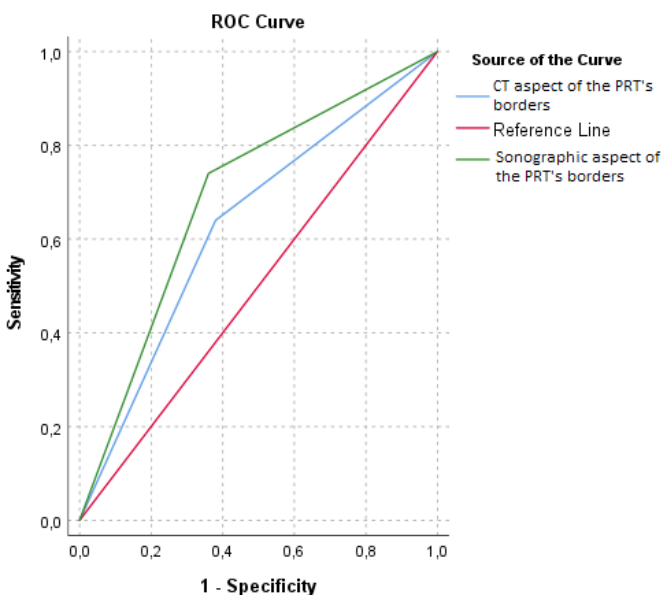


Fig. 2. ROC curve for USG and CT accuracy in determining the character of tumor margins

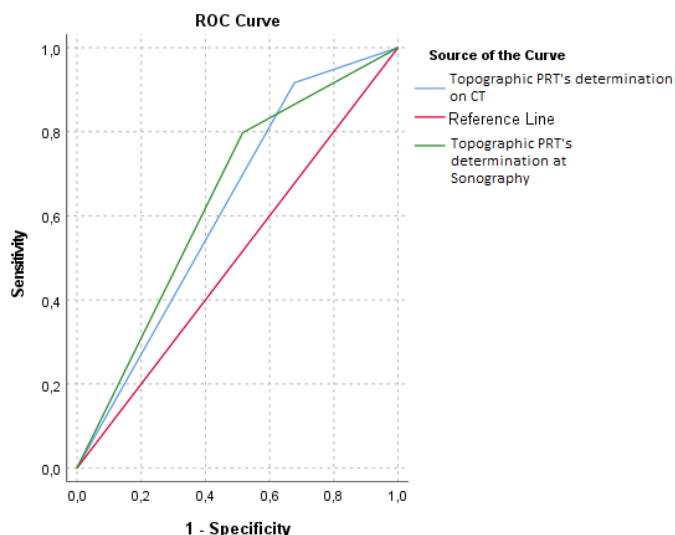


Fig. 3. ROC curve for USG and CT accuracy in determining the intra- or retroperitoneal location of the tumor

Conclusions

The symptomatic and imaging aspect of retroperitoneal tumors is not specific. The important diagnostic challenges are: the precise location of the tumor, the exact assessment of the tumor extension and invasion, the qualitative identification of the tumor cell origin. CT and USG can provide important information about the anatomy of the retroperitoneal space, so tumors can be located accurately. The retroperitoneal tumor can be assessed by determining the specific nature of the tumor (cystic, solid, or cystic-solid), appearance (round, oval, irregular, or lobed), size, relationship with neighboring organs, tissue structure, and tumor margins (clear or blurred). Contrast-enhanced CT and simple USG or DOPPLER regimen, in most cases can rule out the organic origin of the tumor, and in some cases can determine the type of growth and invasive behavior of the tumor. Although the exact structural component of the tumor cannot be determined, the diagnosis of a retroperitoneal tumor is tentative. Imaging data allow surgeons to plan surgery, select an optimal surgical approach, and evaluate the effectiveness and possible recurrence in the postoperative period. Based on the partial correlation calculated between the estimated dimensions at CT 0.789 (95% CI 0.693, 0.873, $p < 0.001$), USG 0.540 (95% CI 0.295, 0.737, $p < 0.001$) and the actual dimensions of tumors assessed intraoperatively or postoperatively, there was made the conclusion that CT provides more accurate data than USG. The image obtained at the USG examination is flat, therefore the dimensional measurements of the tumor are not always performed on the longest tumor axis, especially in the case of polylobulated or giant tumors, while the tomographic examination techniques allow the three-dimensional reconstruction of the tumor with more accurate assessment of the tumor size.

References

1. Aragón-Mendoza RL, Arenas-Gamboa J, Vieira-Serna S, Sierra IAJ. Primary retroperitoneal tumor during pregnancy: case report and review of the literature. *Rev Colomb Obstet Ginecol.* 2020;71(2):195-207. doi: 10.18597/rcog.3477.
2. Roată C, Bosânceanu ML, Pantazescu AN, Luncă S. [Thoraco-retroperitoneal neurogenic tumors. Report of two cases]. *J Chir (Iasi).* 2013;9(3):261-7. doi: 10.7438/1584-9341-9-3-10. Romanian.
3. Paun S, Ganescu R, Negoii I, Nestianu A. Abordul laparoscopic al tumorilor retroperitoneale primitive [Laparoscopic approach for primary retroperitoneal tumors]. *Med Connect.* 2011;6(3):109-13. Romanian.
4. Brennan C, Kajal D, Khalili K, Ghai S. Solid malignant retroperitoneal masses – a pictorial review. *Insights Imaging.* 2014;5(1):53-65. doi: 10.1007/s13244-013-0294-0.
5. Schmitz E, Nessim C. Retroperitoneal sarcoma care in 2021. *Cancers (Basel).* 2022;14(5):1293. doi: 10.3390/cancers14051293.
6. Şchiopu V. Diagnosticul tumorilor retroperitoneale primitive: reviu literaturii [The diagnosis of primitive retroperitoneal tumors: the review of literature]. *Bul Acad Sci Mold. Med Sci.* 2018;2-3(59-60):125-132. Romanian.
7. Rasulov RI, Dvornichenko VV, Muratov AA, Songolov GI, Mozgunov DV. Neorgannye zabriushinnye opukholi: proshloe i nastoiashchee [Primary retroperitoneal tumors: past and present]. *Sibirskii Med J (Irkutsk).* 2015;(7):5-14. Russian.
8. Hui JYC. Epidemiology and etiology of sarcomas. *Surg Clin North Am.* 2016;96(5):901-14. doi: 10.1016/j.suc.2016.05.005.
9. Zubkov RA, Rasulov RI. Epidemiologia neorgannyykh zabriushinnykh opukholei v irkutskoi oblasti [The epidemiology of non-organic retroperitoneal tumors in Irkutsk area]. *Sibirskii Med J (Irkutsk).* 2008;(1):57-9. Russian.
10. Park SY, Kim SR, Choe YH, Lee KY, Park SJ, Lee HB, et al. Extra-axial chordoma presenting as a lung mass. *Respiration.* 2009 Feb;77(2):219-23. doi: 10.1159/000134306.
11. Luo CH, Zou B, Miao C. Retroperitoneal neurofibroma. In: Luo CH, editor. *Retroperitoneal tumors.* Dordrecht: Springer; 2017. p. 233-4. https://doi.org/10.1007/978-94-024-1167-6_26.
12. Wee-Stekly WW, Mueller MD. Retroperitoneal tumors in the pelvis: a diagnostic challenge in gynecology. *Front Surg.* 2014;1:49. doi: 10.3389/fsurg.2014.00049.
13. Messiou C, Moskovic E, Vanel D, Morosi C, Benchimol R, Strauss D, et al. Primary retroperitoneal soft tissue sarcoma: Imaging appearances, pitfalls and diagnostic algorithm. *Eur J Surg Oncol.* 2017;43(7):1191-8. doi: 10.1016/j.ejso.2016.10.032.
14. Morosi C, Stacchiotti S, Marchianò A, Bianchi A, Radaelli S, Sanfilippo R, et al. Correlation between radiological assessment and histopathological diagnosis in retroperitoneal tumors: analysis of 291 consecutive patients at a tertiary reference sarcoma center. *Eur J Surg Oncol.* 2014;40(12):1662-70. doi: 10.1016/j.ejso.2014.10.005.

Authors' ORCID iDs and academic degrees

Victor Schiopu, MD, PhD Student, Assistant Professor – <https://orcid.org/0000-0002-2244-0280>

Corina Scerbatiuc-Condur, MD, Surgeon – <https://orcid.org/0000-0003-3971-5161>

Nicolae Ghidirim, MD, PhD, Professor – <https://orcid.org/0000-0003-1430-5203>

Authors' contributions

VS interpreted the data and performed the analytical part of the work, drafted the first version of the manuscript; CS-C and NG conceptualized the project, designed the research and revised the manuscript critically.

Funding

This study was supported by *Nicolae Testemitanu* State University of Medicine and Pharmacy. The trial was the authors' initiative. The authors are independent and take responsibility for the integrity of the data and accuracy of the data analysis.

Ethics approval and consent to participate

The research project was approved by the Research Ethics Committee of *Nicolae Testemitanu* State University of Medicine and Pharmacy (Protocol No 84, 20.06.2017).

Conflict of Interests

No competing interests were disclosed.

