

Impact Factor:

ISRA (India) = 6.317
ISI (Dubai, UAE) = 1.582
GIF (Australia) = 0.564
JIF = 1.500

SIS (USA) = 0.912
PIHLI (Russia) = 3.939
ESJI (KZ) = 8.771
SJIF (Morocco) = 7.184

ICV (Poland) = 6.630
PIF (India) = 1.940
IBI (India) = 4.260
OAJI (USA) = 0.350

SOI: [1.1/TAS](#) DOI: [10.15863/TAS](#)

International Scientific Journal Theoretical & Applied Science

p-ISSN: 2308-4944 (print) e-ISSN: 2409-0085 (online)

Year: 2022 Issue: 07 Volume: 111

Published: 13.07.2022 <http://T-Science.org>

Issue

Article



G.Kh. Abdiyeva

Azerbaijan Medical University
Department of Surgical Diseases III
Baku, Azerbaijan

TREATMENT OF EXTRASPHINCTERIC FISTULAS OF THE RECTUM

Abstract: The article analyzes the results of 16 patients with extrasphincteric fistula of the rectum, treated with Loose seton, aged 40 to 50 years. Of the 16 patients, there were 14 men (87.5%) and 2 women (12.5%). Endorectal ultrasound examination was performed in all patients. Urinary incontinence and gas incontinence were observed in one patient for 15 weeks. No fecal incontinence was observed in any of the patients. Recovery was observed in 13 (81.25%) patients with extrasphincteric fistula when Loose seton was used. Unsuccessful results were in 3 (18.75%) patients. Our study shows the possibility of successful and effective treatment of extrasphincteric fistulas with the use of one-stage Loose seton.

Key words: extrasphincteric fistulas, Seton, endorectal ultrasonography.

Language: English

Citation: Abdiyeva, G. Kh. (2022). Treatment of extrasphincteric fistulas of the rectum. *ISJ Theoretical & Applied Science*, 07 (111), 30-32.

Soi: <http://s-o-i.org/1.1/TAS-07-111-6> **Doi:**  <https://dx.doi.org/10.15863/TAS.2022.07.111.6>

Scopus ASCC: 2700.

Introduction

Treatment of extrasphincteric fistulas of the rectum still remains a serious problem. Despite the proposals of numerous surgical methods, frequent occurrence after them of serious unsatisfactory results as recurrence in 11-38%, sphincter insufficiency in 3-45% of cases are observed (1). In almost 1/3 of patients with incontinence, fecal and gas incontinence occurred in connection with an operation for chronic paraproctitis (9,11).

The traditionally used methods of surgical treatment are fistulotomy, fistulectomy, in which anal incontinence reaches 60%. Ligation of the fistula in the intersphincter layer (LIFT) is also used (7,8). This operation is technically difficult, the disadvantage is that it leaves an internal hole, leading to relapses (2,10). Another method is plastic surgery. The views of coloproctologists on the choice of this operation are very contradictory (3). Fibrin gel, sealing tampons (PLUG), VAAFT technique are also used, but they have a number of significant disadvantages and requires high qualification (4).

In the diagnosis of extrasphincteric fistulas of the rectum, the most informative methods are endorectal ultrasound and MRI (5,6).

Thus, the issues of treatment of extrasphincteric fistulas of the rectum are currently relevant.

The aim of the study was to improve the results of treatment of patients with extrasphincteric fistulas of the rectum when using Loose seton.

Materials and methods of the research. For the period from 2018 to 2021, in the Department of Surgical Diseases III of the Azerbaijan Medical University, under our supervision, there were 16 patients with extrasphincteric fistula who received treatment with Loose seton. Loose seton is a rubber tube that is placed in the fistulous canal. Of the 16 patients, there were 14 men (87.5%) and 2 women (12.5%). The patients were aged 40 to 50 years. The most informative diagnostic method was rectal ultrasound, which made it possible to clarify the topography of the fistulous tract in relation to the anal sphincter. Endorectal ultrasound examination was performed for all patients (Fig. 1).

Impact Factor:

ISRA (India) = 6.317
ISI (Dubai, UAE) = 1.582
GIF (Australia) = 0.564
JIF = 1.500

SIS (USA) = 0.912
ПИИИ (Russia) = 3.939
ESJI (KZ) = 8.771
SJIF (Morocco) = 7.184

ICV (Poland) = 6.630
PIF (India) = 1.940
IBI (India) = 4.260
OAJI (USA) = 0.350

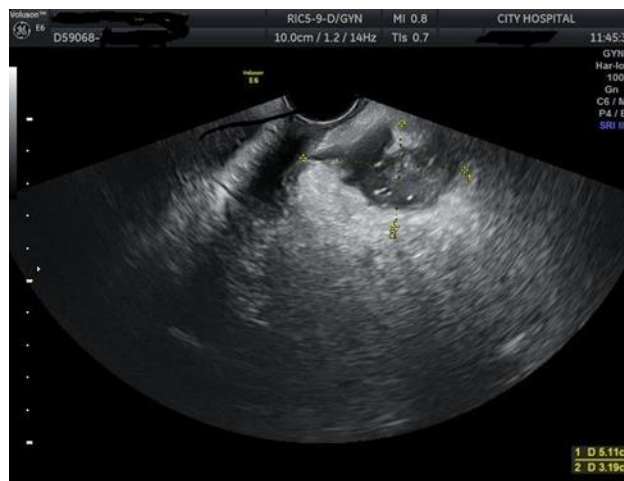

Fig.1. Posterior extrasphincteric fistula of the rectum

Operations were performed under epidural anesthesia after a preliminary cleansing enema. Probing of the fistulous tract was performed with a metal flexible probe. The imposed Loose seton was left free (Fig. 2). Seton was left for 3 months. After the operation, the patients were prescribed sitz baths 2 times a day and analgesics. The first bowel movement was carried out after 3-4 days using laxatives to soften the stool. Patients were discharged after the first act of

defecation. Until complete healing of the wound, the patients were under regular examination. Repeated examinations were carried out every 4 weeks. During the examination, we paid attention to the position of the seton and assessed the wound, asking for the presence of anal incontinence. Seton was removed after 3 months. The patients were followed up for a year.

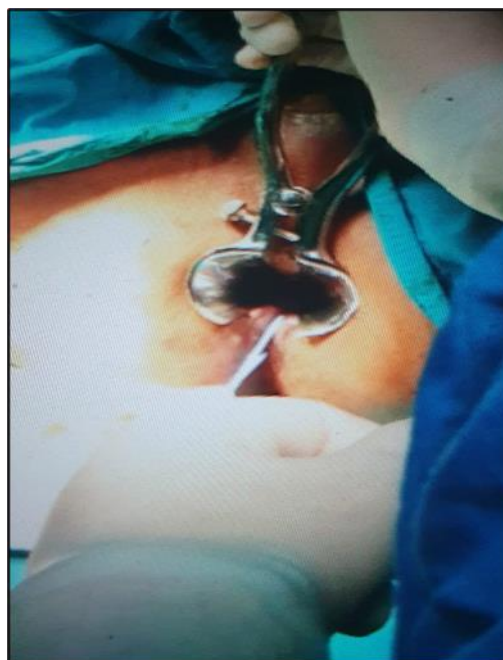
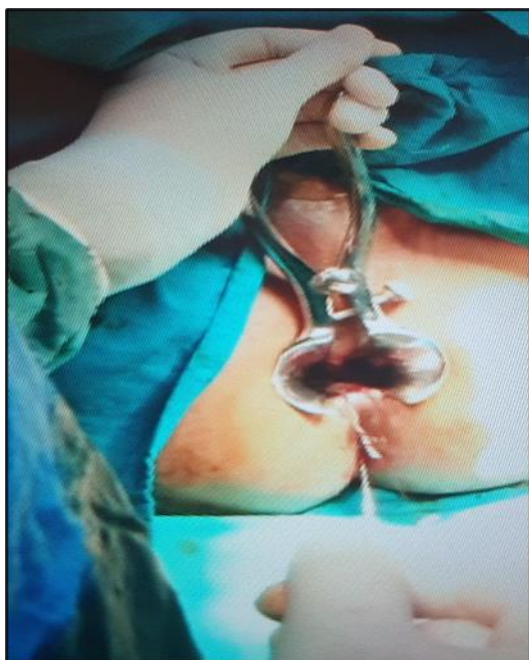


Fig.2 Loose seton overlay.

Results and discussions. 16 patients with extrasphincteric fistula were hospitalized. Urinary incontinence and gas incontinence were observed in one patient for 15 weeks. No anal incontinence was observed in any of the patients. Complete recovery was observed in 13 (81.25%) patients with

extrasphincteric fistula when using Loose seton. Unsuccessful results were in 3 (18.75%) patients.

Treatment of extrasphincteric fistulas of the rectum remains a serious, surgical problem. The formation of a fistula of the rectum predisposes a simple opening and drainage of the abscess without

Impact Factor:

ISRA (India) = 6.317
ISI (Dubai, UAE) = 1.582
GIF (Australia) = 0.564
JIF = 1.500

SIS (USA) = 0.912
PIHII (Russia) = 3.939
ESJI (KZ) = 8.771
SJIF (Morocco) = 7.184

ICV (Poland) = 6.630
PIF (India) = 1.940
IBI (India) = 4.260
OAJI (USA) = 0.350

eliminating the routes of infection. Through the area of the affected anal crypt or through the routes of another etiology (trauma), there is a constant infection of pararectal tissues from the intestinal lumen. Usually, the reason for a visit to the doctor is purulent or sanious discharge. In the majority, in the treatment of patients suffering from extrasphincteric fistulas of

the rectum, the Loose seton ligature method remains the operation of choice.

Conclusion. Our study shows the possibility of successful and effective treatment of extrasphincteric fistulas with the use of one-stage Loose seton. In our study, the recurrence rate was low. Urinary and gas incontinence were impermanent.

References:

1. Balongh, G. (1999). Tube loop (seton) drainage treatment of recurrent extrasphincteric perianal fistulae. *Am.J.Surg.*, Vol.177, N2, pp.147-149.
2. Cosman, B.C. (1998). Alls Well That Ends Well/Shakerspeare s treatment of anal fistula. *Dis Colon Rectum/Jul.*, 41 (7): 914-24.
3. Deroide, G., & Deroide, J.P. (2000). Anal fistulae and abscesses-diaqnostic and therapeutic aspects. *J. Chir/Paris/*, pp.83-92.
4. Gordon, P.H. (2007). *Principles and practice of surgery for the colon, rectum, and anus*. 3rd ed. (p.1354). N.Y.
5. Göttgens, K.W., Smeets, R.R., Stassen, L.P., et al. (2015). Systematik review and mete-analysis of surgical interventions for high cryptoglandular perianal fistula. *Inter.J Colorectal Dis.*, 30 (5): 583-593.
6. Johnson, E.K., Gaw, J.U., & Armstrong, D.N. (n.d.). *Efficacy of anal fistula plug vs/fibrin glue in closure of anarectal fistulas*. Dis.Colon.Rectum.
7. (2009). Mosbys medical dictionary.8 th edition. Elsevier. 2009: 2240 p. S.V. "Seton". Retrieved 30.10.2017 from <https://medical-dictionary.thefreedictionary.com/seton>
8. Nazari, H., Solotani, Z.E., Asbagh, R.A., et al. (2022). Advancing standart techniques for treatment of peranal fistula; when tissue engineering meets seton. *Health Sciences Review*, 3, p.10026.
9. Schwarz, F., Bieling, K., & Sculean, A. (2004). Treatment of periimplantitiswith lazer or ultrasound. *Schweiz Monatsschr.*, Vol.114: pp.1228-1235.
10. Toyonaga, T., Tanaka, Y., Song, J.F., et al. (2007). Microbiological analysis and endoanal ultrasonography for diagnosis of anal fistula in acute anarectal sepsis. *Int J Colorectal Dis.*, 22: 209-213.
11. Vatansev, C., Alabaz, O., Tekin, A. et al. (2007). A new seton type for the treatment of anal fistula. *Dig. Dis.Sci.*, 52 (8):1920-1923.