

## Impact Factor:

ISRA (India) = 6.317  
ISI (Dubai, UAE) = 1.582  
GIF (Australia) = 0.564  
JIF = 1.500

SIS (USA) = 0.912  
ПИИИ (Russia) = 3.939  
ESJI (KZ) = 9.035  
SJIF (Morocco) = 7.184

ICV (Poland) = 6.630  
PIF (India) = 1.940  
IBI (India) = 4.260  
OAJI (USA) = 0.350

SOI: [1.1/TAS](#) DOI: [10.15863/TAS](#)

### International Scientific Journal Theoretical & Applied Science

p-ISSN: 2308-4944 (print) e-ISSN: 2409-0085 (online)

Year: 2022 Issue: 03 Volume: 107

Published: 12.03.2022 <http://T-Science.org>

QR – Issue



QR – Article



**T.S. Guliyeva**

Azerbaijan Medical University  
Department of Oncology  
[tamarakuliyeva@gmail.com](mailto:tamarakuliyeva@gmail.com)

**Sh.Sh. Osmanov**

Baku City Hospital  
Patomorphology laboratory

## PHYLLODES TUMORS OF THE BREAST DIAGNOSTIC AND PATOMORPHOLOGY RESEARCH

**Abstract:** This article examines issues related to the diagnosis, treatment and provides clinical examples of phylloid tumors of breast.

**Key words:** phylloides tumors of the breast, leaf-shaped tumors of the breast.

**Language:** English

**Citation:** Guliyeva, T. S., & Osmanov, Sh. Sh. (2022). Phylloides tumors of the breast diagnostic and patomorphology research. *ISJ Theoretical & Applied Science*, 03 (107), 401-405.

**Soi:** <http://s-o-i.org/1.1/TAS-03-107-24> **Doi:**  <https://dx.doi.org/10.15863/TAS.2022.03.107.24>

**Scopus ASCC:** 2730.

### Introduction

The group of fibroepithelial tumors of the mammary gland includes two-component tumors with proliferation of connective tissue and epithelial component. Fibroadenomas are one of the most common tumors of the mammary gland, with 2% of them being rare leaf-shaped tumors compared to oncological practice [2]. All these tumors are characterized as neoplasms with a two-component structure, in which the connective tissue component predominates. In sarcomas, this component is absolute, and in the group of fibroepithelial tumors, it is found in parallel with the development of epithelial tissue. The rarity of these neoplasms, the characteristics of the clinical course and the polymorphism of the morphological structure are based on different views on the nature of these processes and the principles of treatment tactics [1].

Fibroadenoma is a tumor that develops from the epithelium of the mammary glands and the stroma of the terminal part of the urinary system and involves the proliferation of stromal and epithelial elements. The disease is mainly found in patients of young age with high morbidity in the third decade of life. Fibroadenomas are mainly located in the upper outer

quadrant of the mammary gland; the right and left mammary glands are damaged with the single frequency. The tumor is usually solitary, but in 25% of cases there are numerous nodules that develop synchronously and asynchronously.

The vast majority of phylloid tumors described in the literature are found in women, and in men these tumors are rarely encountered [5].

According to the literature, phylloid tumors can occur at any age - from early puberty to old age; the interval varies from 10 to 90 years [6].

The fibrous component has an increased number of cells and is hypercellular. However, atypia is not observed in the cells; individual mitotic figures are observed.

The etiology and pathogenesis of phylloid tumors are unknown. It is believed that the tumor is caused by a violation of the hormonal balance in the body, primarily estrogen. The formation of phylloid tumors and its recurrences also occur during pregnancy. Pregnancy and lactation stand on the agenda as factors that stimulate tumor growth. Both benign and malignant tumors of the thyroid gland, diabetes, liver disease, apparently are the factors that disrupt hormone metabolism and contribute to the

**Impact Factor:**

**ISRA (India) = 6.317**  
**ISI (Dubai, UAE) = 1.582**  
**GIF (Australia) = 0.564**  
**JIF = 1.500**

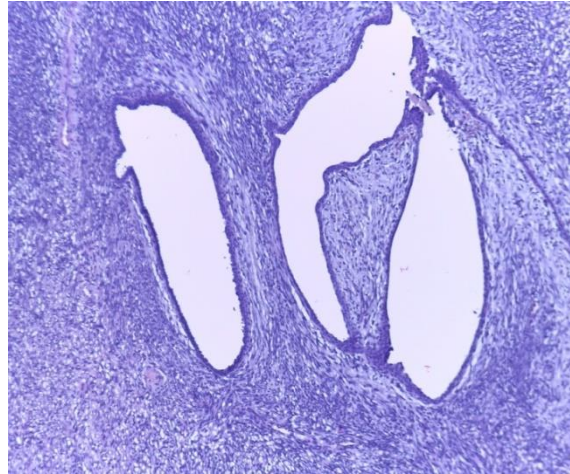
**SIS (USA) = 0.912**  
**ПИИИ (Russia) = 3.939**  
**ESJI (KZ) = 9.035**  
**SJIF (Morocco) = 7.184**

**ICV (Poland) = 6.630**  
**PIF (India) = 1.940**  
**IBI (India) = 4.260**  
**OAJI (USA) = 0.350**

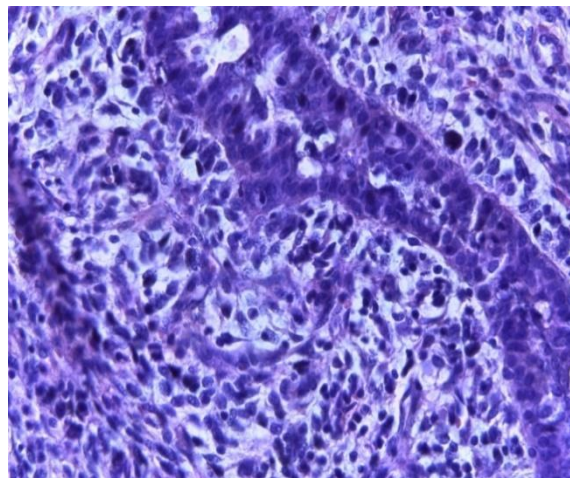
---

development of neoplasms [8].Leaf tumor is similar to fibroadenoma, but is characterized by the predominance of the connective component. Phylloid tumors are characterized by an unusual clinical picture, difficult to diagnose, prone to recurrence and high probability of deterioration of the condition.

According to the International Histological Classification of the World Health Organization (1995), fibroepithelial neoplasms are divided into 3 variants of phylloid tumors (9020/0) - benign (picture 1), borderline (picture 2) and malignant (picture 3).



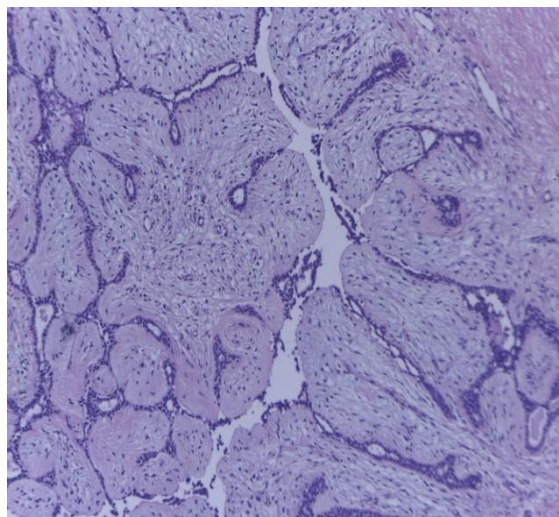
**Picture 1. Mammary gland: benign phylloid tumor 100 magnification. Dye hematoxillin-eosin. The derivative is two-component: glandular component and fibrous component. The fibrous component is hypocellular.**



**Picture 2. Borderline phylloid tumor of the breast 100 magnification. The derivative has two components: the epithelial component and the fibrous component.**

**Impact Factor:**

<b>ISRA (India)</b>	<b>= 6.317</b>	<b>SIS (USA)</b>	<b>= 0.912</b>	<b>ICV (Poland)</b>	<b>= 6.630</b>
<b>ISI (Dubai, UAE)</b>	<b>= 1.582</b>	<b>ПИИИ (Russia)</b>	<b>= 3.939</b>	<b>PIF (India)</b>	<b>= 1.940</b>
<b>GIF (Australia)</b>	<b>= 0.564</b>	<b>ESJI (KZ)</b>	<b>= 9.035</b>	<b>IBI (India)</b>	<b>= 4.260</b>
<b>JIF</b>	<b>= 1.500</b>	<b>SJIF (Morocco)</b>	<b>= 7.184</b>	<b>OAJI (USA)</b>	<b>= 0.350</b>



**Picture 3. Malignant phylloid tumor of the mammary gland MFT. 400 magnification. Dye hematoxylin-eosin.**

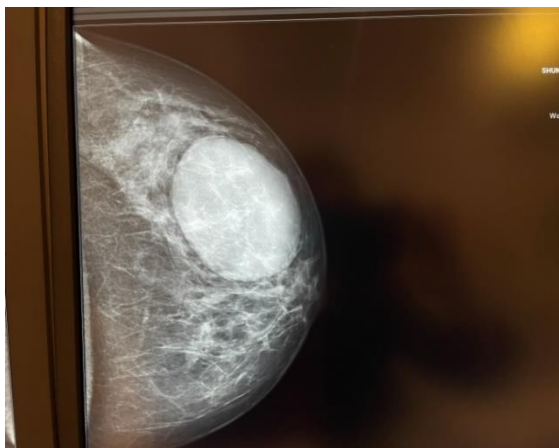
The derivative has two components: the epithelial component and the fibrous component. The fibrous component is hypercellular, atypical. Numerous mitotic figures are observed.

Phylloid tumors have a great potential for malignant changes in the stroma of the mammary gland sarcoma. However, the presence of an epithelial component does not exclude the development of a carcinoma-type malignant tumor. In addition, the development of both components can lead to the formation of carcinoma sarcoma.

Carcinosarcoma is a very rare tumor pathology, characterized by malignancy of both stromal and epithelial components, metastasizing both lymphogenically and hematogenously. The leading morphological feature of deciduous tumors of the mammary gland is the excess of fibrous cells of fibroblast type. The absence of this symptom negates the diagnosis of phylloid tumor. On the other hand, a malignant phylloid tumor differs from stromal sarcoma of the mammary gland in the presence of

epithelial structures. The main feature of phylloid tumors is relapse and malignancy with the formation of mammary sarcoma. The most common and specific clinical symptom is the large size of the phylloid tumor. The literature describes tumors with a diameter of 45 cm. The average size of tumors is from 5 cm to 10 cm, but there are also 1 cm phylloid tumors [1]. Tumor size is not relevant as a prognostic factor (the potential for metastasis of a 2 cm tumor is described), but most authors confirm the high degree of malignancy of large tumors [9].

The clinical picture does not differ in specificity and can range from small tumors with precise contours to tumors covering the entire mammary gland. From large tumors, the skin of the mammary gland becomes cyanotic, thinning, and the subcutaneous veins dilate sharply. In some cases, skin ulcers are observed, but these symptoms do not always appear as a feature of the malignant process. There are no radiological criteria for distinguishing malignant phylloid tumor from mammary sarcoma (picture 4, 5).



**Picture 4. Benign phylloid tumor. The skin, gills and areola have not changed.**

## Impact Factor:

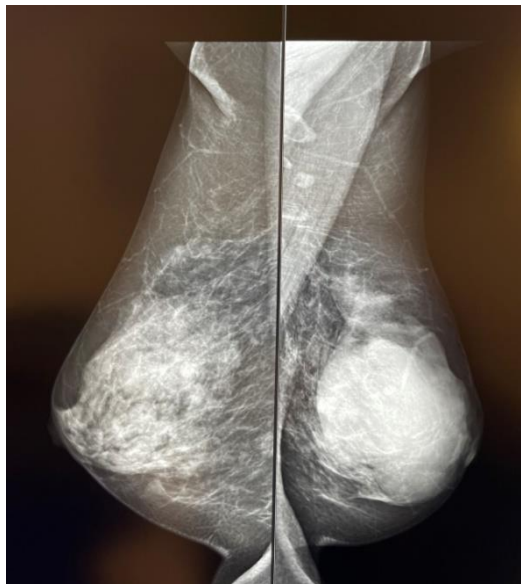
ISRA (India) = 6.317  
ISI (Dubai, UAE) = 1.582  
GIF (Australia) = 0.564  
JIF = 1.500

SIS (USA) = 0.912  
ПИИИ (Russia) = 3.939  
ESJI (KZ) = 9.035  
SJIF (Morocco) = 7.184

ICV (Poland) = 6.630  
PIF (India) = 1.940  
IBI (India) = 4.260  
OAJI (USA) = 0.350

Existing diagnostic methods (radiology, USM, cytology) often do not allow the differentiation of epithelial and non-epithelial tumors of the mammary gland. Absolute and sufficient operation in benign and transitional variants of phylloid tumor - is a sectoral

resection of the mammary gland in the case of total damage to the breast and in the malignant variant - mastectomy. In most cases, there is no need for lymph dissection.



**Picture 5. Borderline phylloid tumor. Infiltrative areas are noted around the tumor.**

Recent studies have revealed changes in the genotype of tumor cell nuclei [4]. The study of phylloid tumors at the genetic level is very rare. Molecular-genetic markers that reveal significant mutations in gene suppressors, such as BRCA1-2, TP53, represent single-nucleotide polymorphic variants [3]. Both stromal and epithelial components of phylloid tumors were described as allelic losses and cytogenetic transformation zones, such as FHIT (locus D3 S1300) 3p12-p14 [11]. These indicators confirm that both components are part of the neoplastic process. Chromosome small shoulder deletion and allelic imbalance have been associated with more aggressive course and recurrence of tumors. Specific locus panel (LOH) with disappearance of heterozygous pruritus was found in patients with multiple and contralateral phylloid tumors, which is not typical for ordinary fibroadenomas. Early phylloid tumors and their

recurrences were of a single clonic nature, but LOH was characteristic of pathological progression and metastasis [10]. According to the results of this study, malignant epithelial and stromal components carry the same LOH genotype, which in turn determines the overall pathological mechanism. K. Reiem and co-authors study discovers the association of the R1699W missense variant of the BRCA1 gene with a malignant variant of breast phylloid tumor [7]. According to the authors, carriers of hereditary mutations of the BRCA1 gene, which are rarely removed (change protein function), are more likely to develop this histopathological variant. In addition, allelic loss of the D22S264 locus of the TP53 gene contributes to the progression of phylloid tumors. In our opinion, genetic studies of phylloid tumors can respond to many factors, considering the structural and functional changes of genes (BRCA1-2 and TP53).

## References:

1. Vorotnikov, I.K., Bogatyrev, V.N., & Korzhenkova, G.P. (2006). Leaf-shaped tumors and sarcomas of the mammary glands: clinic, diagnosis, treatment. *Mammology*, No. 1, pp. 20-23.
2. Grigoruk, O.G., Bogatyrev, V.N., Lazarev, A.F., Sokolova, V.K., Frolova, T.S., & Bazulina, L.M. (2005). Cytological diagnosis of leaf-shaped tumors and breast sarcomas. *Mammology*, №1, pp.30-32.

<b>Impact Factor:</b>	<b>ISRA (India) = 6.317</b>	<b>SIS (USA) = 0.912</b>	<b>ICV (Poland) = 6.630</b>
	<b>ISI (Dubai, UAE) = 1.582</b>	<b>PIHII (Russia) = 3.939</b>	<b>PIF (India) = 1.940</b>
	<b>GIF (Australia) = 0.564</b>	<b>ESJI (KZ) = 9.035</b>	<b>IBI (India) = 4.260</b>
	<b>JIF = 1.500</b>	<b>SJIF (Morocco) = 7.184</b>	<b>OAJI (USA) = 0.350</b>

---

3. Lyubchenko, L. N., Portnoy, S. M., Pospekhova, N. I., et al. (2007). Clinical and molecular aspects of hereditary breast cancer. *Molecul. honey*, No. 1, pp. 8-9.
4. Draghi, F., Sabolla, L., & Campani, R. (1996). *Radiol-Med-Torino*. 1996 May. 91(5). pp.585-590.
5. Kahan, Z., Toszegi, A.M., Szarvas, F., et al. (1997). Recurrent phyllodes tumor in a man. *Pathology Research and Practice*, 193/9, pp.653-658.
6. Mallebre, B., Ebert, A., Perez-Canto, A., et al. (1996). Cystosarcomaphylloides of the breast. A retrospective analysis of 12 cases. *Geburtshilfe-Frauenheilkd*, Jan. 56(1), pp. 35-40.
7. Reiem, K., Flucke, U., Engel, C., et al. (2007). Associated of the BRCA1 missense variant R1699W with a malignant phyllodes tumor of the breast. *Cancer Genet. Cytogenet*, Vol. 176, pp.76-79.
8. Salvadori, B., Cusumano, F., & Del Bo, R. (1990). Chirurgia e tumorifillodideiimammella. *Argomentioncol*, 11. № 2, pp.157-163.
9. Salvadori, B., Cusumano, F., & Del Bo, R. (1990). *Argomentioncol*. 1th ed. — UFO, pp. 157-163.
10. Sawyer, E., Hanby, A., Lakhani, S., et al. (2000). Molecular analysis of phyllodes tumors reveals distinct changes in the epithelial and stromal components. *Am. J. Pathol.*, Vol. 156, N 3, pp. 1093-1098.
11. Wang, Z., Buraimoh, A., Iglehart, J., et al. (2006). Genomewide analysis for loss of heterozygosity in primary and recurrent phyllodes tumor and fibroadenoma of breast using single nucleotide polymorphisms array. *Breast Cancer Res. Treat.*, Vol. 97, N 3, pp. 301-309.