

Yu.H. Antipkin¹,
L.H. Kyrylova¹,
O.O. Miroshnykov¹,
O.O. Yuzva¹,
V.V. Orzheshkovskiy²,
A.F. Nechay³

**AUTOSOMAL RECESSIVE LIMB-GIRDLE
 MUSCULAR DYSTROPHY TYPE 2A:
 TWO CASES IN UKRAINE
 WITH DIFFERENT AGE OF ONSET**

State institution "Institute of pediatrics, obstetrics and gynecology named after academician Elena M. Lukyanova National academy of medical sciences of Ukraine"¹

P. Maiborody str, 8, Kyiv, 04050, Ukraine

Shupyk National Medical Academy of Postgraduate Education²

9 Dorohozhytska Str. Kyiv, 04112 Ukraine

Kyiv city children clinical hospital No. 1³

Vogatyrska str., 30, Kyiv, 04209, Ukraine

ДУ «Інститут педіатрії, акушерства і гінекології імені академіка О.М. Лук'янової НАМН України»¹

вул. Майбороди, 8, Київ, 04050, Україна

Національна медична академія післядипломної освіти ім. П.Л. Шупика МОЗ України²

вул. Дорогожицька, 9, Київ, 04112, Україна

Київська міська дитяча клінічна лікарня № 1³

вул. Богатирська, 30, Київ, 04209, Україна

e-mail: kirilova.lgr@gmail.com

Цитування: Медичні перспективи. 2021. Т. 26, № 3. С. 212-218

Cited: Medicni perspektivi. 2021;26(3):212-218

Key words: limb-girdle muscular dystrophy, CAPN3 gene, Gower's sign, proximal muscle weakness

Ключові слова: кінцівково-поперекова м'язова дистрофія, ген CAPN3, прийом Говерса, проксимальна м'язова слабкість

Ключевые слова: конечностно-поясничная мышечная дистрофия, ген CAPN3, прием Говерса, проксимальная мышечная слабость

Abstract. Autosomal recessive limb-girdle muscular dystrophy type 2A: two cases in Ukraine with different age of onset. Antipkin Yu.H., Kyrylova L.H., Miroshnykov O.O., Yuzva O.O., Orzheshkovskiy V.V., Nechay A.F. The paper reports on two cases of young women from Ukraine with autosomal recessive limb-girdle muscular dystrophy type 2A with different age of symptoms onset and an absence of any family history presented with gradual onset of proximal muscle weakness in four limbs and thinning of shoulders, arms and thighs. Both patients had elevated creatine phosphokinase level and c.550delA mutations in CAPN3 gene. Sequence analysis and deletion/duplication testing of the 159 genes from skeletal muscles disease testing panel of 5-year-old girl identified deletion of exon 8 (heterozygous) and c.550delA (p.Thr184Argfs*36) mutation (heterozygous), were in CAPN3 gene. Magnetic Resonance Imaging of soft tissue of the proximal lower extremities was performed which showed signs of symmetrical atrophic changes in the major adductor muscle, the long and short adductor muscles, the semitendinosus muscle of the thigh, as a manifestations of autosomal recessive limb-girdle muscular dystrophy type 2A. Homozygous, pathogenic variant of the defect in the CAPN3 gene c.550del (p.Thr184Argfs * 36) was identified in a 25-year-old woman. Type 2A is the most common form of limb-girdle muscular dystrophy, accounting for about 30% of cases. The autosomal recessive limb-girdle muscular dystrophy type 2A is on caused by mutations in the CAPN3 gene, and it is characterized by selective atrophy and weakness of proximal limb and girdle muscles. The age of onset of muscle weakness is extremely variable; the most common being between 8 and 15 years, although it can range between 2 and 50 years. The diagnosis can be suspected by findings on a muscle biopsy or when a doctor experienced in muscular dystrophy examines you. A serum creatine kinase blood test may also show raised levels which indicate a problem in the muscles. The diagnosis has to be confirmed by means of identifying a mutation in the CAPN3 gene which is done on a deoxyribonucleic acid sample from a blood test. To date there are no specific treatments for limb-girdle muscular dystrophy, however careful management of the symptoms of the condition can improve a person's quality of life. Joint contractures (tightening) can occur in limb-girdle muscular dystrophy and therefore regular physiotherapy is recommended.

Реферат. Автосомно-рецесивна кінцівково-поперекова м'язова дистрофія типу 2А: два випадки в Україні з різним віком виникнення. Антипкін Ю.Г., Кирилова Л.Г., Мірошников О.О., Юзва О.О., Оржешковський В.В., Нечай А.Ф. У статті представлено два клінічні випадки двох пацієнток з України з автосомно-рецесивною кінцівково-поперековою м'язовою дистрофією типу 2А з різним віком виникнення симптомів та відсутністю сімейного анамнезу, яка проявлялася поступовим виникненням проксимальної

*м'язової слабкості в усіх чотирьох кінцівках та стоншенням плечей, верхніх кінцівок і стегон. Обидві пацієнки мали підвищений рівень креатинфосфокінази та мутації c5050delA в гені CAPN3. Аналіз послідовності та тестування на делеції/дуплікації 159 генів із тестування на захворювання скелетних м'язів у 5-річної дівчинки виявив делецію екзону 8 (у гетерозиготній формі) та мутацію c5050delA (p.Thr184Argfs*36) (у гетерозиготній формі) гена CAPN3. Було проведено магнітно-резонансну томографію м'язих тканин проксимальних відділів нижніх кінцівок, яка показала ознаки симетричних атрофічних змін великого привідного м'яза, довгого й короткого привідних м'язів, півсухожильного м'яза стегна як прояви кінцівково-поперекової м'язової дистрофії типу 2A. Гомозиготний, патогенний варіант мутації гена CAPN3 c.550del (p.Thr184Argfs*36) також був виявлений у 25-річної жінки. Тип 2A – найпоширеніша форма кінцівково-поперекової м'язової дистрофії, що становить близько 30% усіх випадків. LGMD2A викликається мутаціями гена CAPN3 і характеризується селективною атрофією та слабкістю м'язів проксимальних відділів кінцівок та м'язів верхнього й нижнього поясу. Вік виникнення м'язової слабкості надзвичайно мінливий: найчастіше – від 8 до 15 років, хоча він може коливатися в межах від двох до 50 років. Запідозрити діагноз можна за результатами клінічного огляду або біопсії м'язів. Аналіз крові на рівень креатинкінази в сироватці крові може також показати підвищений рівень, який свідчить про проблеми з м'язами. Діагноз повинен бути підтверджений шляхом виявлення мутації гена CAPN3, який проводиться в зразку дезоксирибонуклеїнової кислоти з аналізу крові. На сьогоднішній день не існує спеціальних методів лікування кінцівково-поперекової м'язової дистрофії, проте ретельне лікування симптомів захворювання може поліпшити якість життя людини. При кінцівково-поперековій м'язовій дистрофії можуть виникати контрактури суглобів, тому рекомендується регулярна фізіотерапія.*

The limb-girdle muscular dystrophies (LGMDs) are a mixed, group of genetically determined progressive disorders characterized by increasing weakness and atrophy of the pelvic and shoulder girdle muscles with a strongly inconstant course of the disease [2]. Other name of this disease – Erb's muscular dystrophy. Presently twenty-four autosomal recessive forms (LGMD2) and eight autosomal dominant (LGMD1) forms have been described [7]. The most hurtable muscles are proximal muscles of limbs, mostly the muscles of the shoulders, upper limbs, and pelvic area [12].

The symptoms generally appear during the first 20 years of life, with a progressive course that leads to the loss of the ability to walk between 10 to 20 years after debut [3].

Muscle weakness and atrophy may lead to changes in the patient's posture and in the shape of the patient's shoulders, back, and arm. Affected shoulder muscles may cause a symptom that is known as wing-like scapulae [4].

Children with LGMD could also have deformations of the spine like scoliosis and lordosis. Some patients may have joint contractures that can create difficulties in the movement in their hips, knees, ankles, and elbows. Some people with limb-girdle muscular dystrophy can have hypertrophy of the shin muscles [4, 12].

At the onset of LGMD1, patients could have changes and disturbances of gait, such as waddling or walking on tiptoes, and could have difficulty with jumping and running. Gowers' sign also is a typical symptom in children [4, 9].

Some patients have muscle pain, mostly in their hips and calves. Joint contractures (tightening) could appear and mostly injured the ankles. Facial and neck muscles are rare involved and therefore swallowing problems are unlikely [4, 9, 12].

The diagnostic criteria of limb-girdle muscular dystrophy include increased serum creatine phosphokinase (CPK) level, electromyography signs of myopathy, muscle biopsy with features of myopathic or dystrophic changes and absence or reduction of a protein, involved in a specific form of LGMDs, on western blotting [4, 8, 12].

Cardiomyopathy is very frequent and typical symptom of LGMD1 and other forms of limb-girdle muscular dystrophy. Some patients experience mild to severe breathing problems due to the problems with respiratory muscles. Patients with LGMD2A have increased risk of developing respiratory muscle weakness and experience breathing difficulties with the progression of respiratory insufficiency, but this is usually a very rare and late complication [4, 9, 12].

Cognitive functions are typically not impaired in individuals with in limb-girdle muscular dystrophy; but, developmental delay and intellectual disability have been reported in rare forms of this disorder [4, 12].

Life expectancy generally remains within a normal range because the myocardium and respiratory muscles are intact. In later stages of the condition, breathing difficulties can occur but are usually less severe than in other muscular dystrophies. These symptoms can include sleep disorders, nightmares, tiredness or headaches after waking up in the morning, lack of appetite and falling asleep during the day [4, 9, 12].

Prevalence of LGMD2A estimates range from 1 per 14,500 to 1 per 123,000 individuals [6].

Currently there are no specific treatments for LGMD2A, yet careful management of the symptoms of the disease may increase patients' quality of life. Keeping mobile is important for all people affected by muscular dystrophy. There are no guidelines about the type or intensity of activities however it is recommended that any exercise undertaken is done within patients' abilities and comfort. Extreme tiredness,

muscle pain and cramps during or after activities could mean that patient have pushed himself too hard and therefore those activities should be avoided. Swimming is a good activity because it promotes movement of all muscles without increased strain [4, 9, 12].

In this article we present two cases of patients from Ukraine with confirmed limb-girdle muscular dystrophy type 2A. The research was conducted in accordance with the principles of bioethics set out in the WMA Declaration of Helsinki – “Ethical principles for medical research involving human su-

bjects” and “Universal Declaration on Bioethics and Human Rights” (UNESCO).

Case 1

A 5-year-old girl from Ukraine presented with gradually progressive muscular weakness in the lower limbs, difficulty in walking up stairs, getting up from the floor and a waddling gait. These symptoms had been observed since the age of 4. She also had increasing difficulties with holding heavy objects and joining her hands above the head (Fig. 1-3).

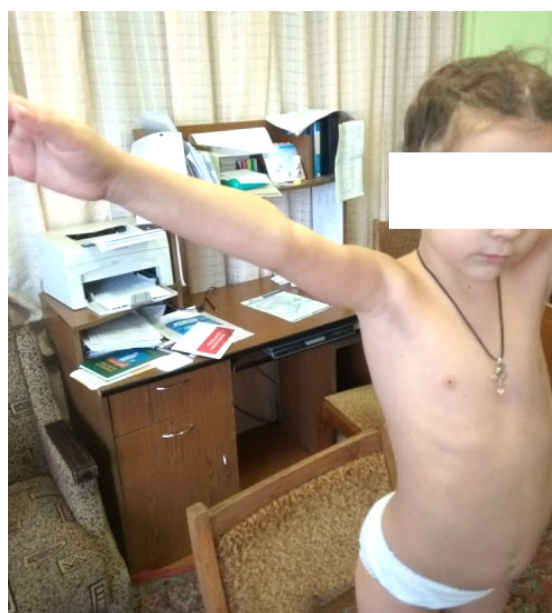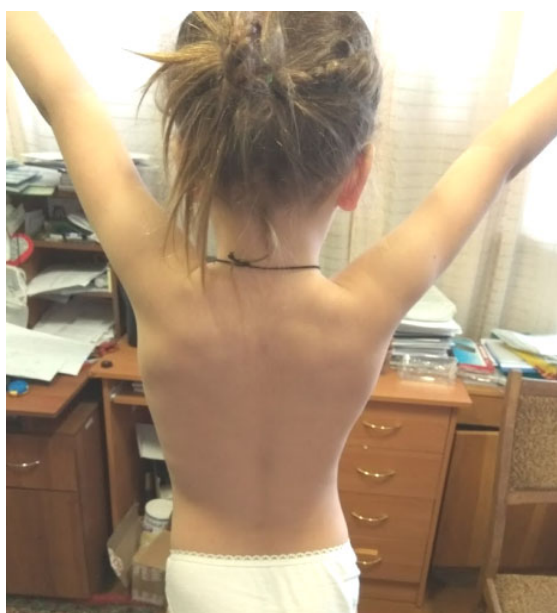


Fig. 1. 5 years old girl with limb-girdle muscular dystrophy type 2A. Atrophy of both shoulders with wasting of both deltoids. Lordosis

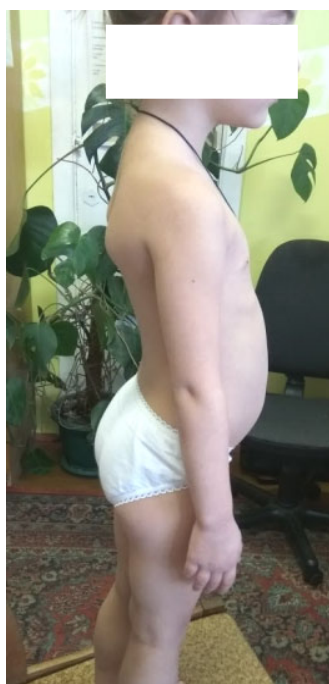

Fig. 2. Lordosis. Pseudohypertrophy of calves

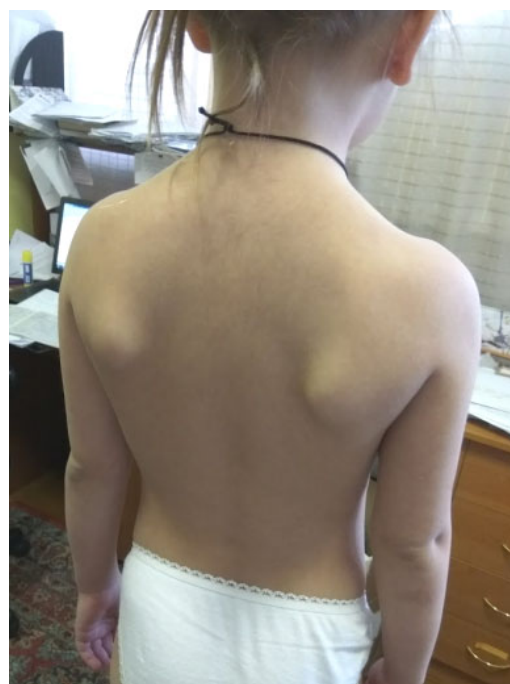

Fig. 3 Wing-like scapulae

The girl was born from healthy parents, second pregnancy and birth. There were no complications during labor. The birth was normal. Her birth weight was 4600 g, Apgar scores – 8 and 9 points. She is the second eldest child of four siblings, has 3 healthy brothers. Motor patterns during infancy and early childhood developed normally. Was not in the follow-up by neurologist. At the age of 5 years increased transaminases level was revealed after respiratory infection. Autoimmune and viral hepatitis were excluded. Then she was referred to the neurology department for further investigations.

Neurological examination showed a severe, symmetrical, predominantly limb-girdle weakness (Medical Research Council score of 0/5 in deltoid, 1/5 in biceps and triceps, 3/5 in wrist extension, 4+/5 in wrist flexion, 0/5 in psoas, 1/5 in hip adductors and abductors, 2/5 in quadriceps, posterior femoris and tibialis anterior, and 4/5 in plantar flexion muscles bilaterally) as well as muscular atrophy. Muscle tone and limb strength were decreased mainly in the proximal parts of the lower (predominantly) and upper extremities. Pseudohypertrophy of calves, wing-like scapulae and Gover's symptom were observed. Ocular, facial, bulbar and neck muscles were spared. All deep tendon reflexes were negative.

There were no fasciculation, upper motor signs, or joint contractures. Sensation (pinprick, light touch, vibration and position sense) was also normal. No intellectual disability was detected. Serum creatine phosphokinase (CPK) was slightly elevated (5500-6000 UI/L). Forced vital capacity was 72% in a sitting position. ECG, echocardiography and chest X-ray were normal. Child's somatic status was without significant abnormalities.

Parents and all siblings had CPK levels within the normal range and no symptoms of weakness or gait disorders.

Sequence analysis and deletion/duplication testing of the 159 genes from skeletal muscle disease testing panel identified deletion of exon 8 (heterozygous) and c.550delA (p.Thr184Argfs*36) mutation (heterozygous) were in CAPN3 gene. The CAPN3 gene is associated with autosomal recessive limb-girdle muscular dystrophy type 2A (LGMD2A) (MedGen UID: 358391).

MRI of soft tissue of the proximal lower extremities was performed which showed signs of symmetrical atrophic changes in the major adductor muscle, the long and short adductor muscles, the semitendinosus muscle of the thigh, as a manifestations of LGMD2A (Fig. 4).

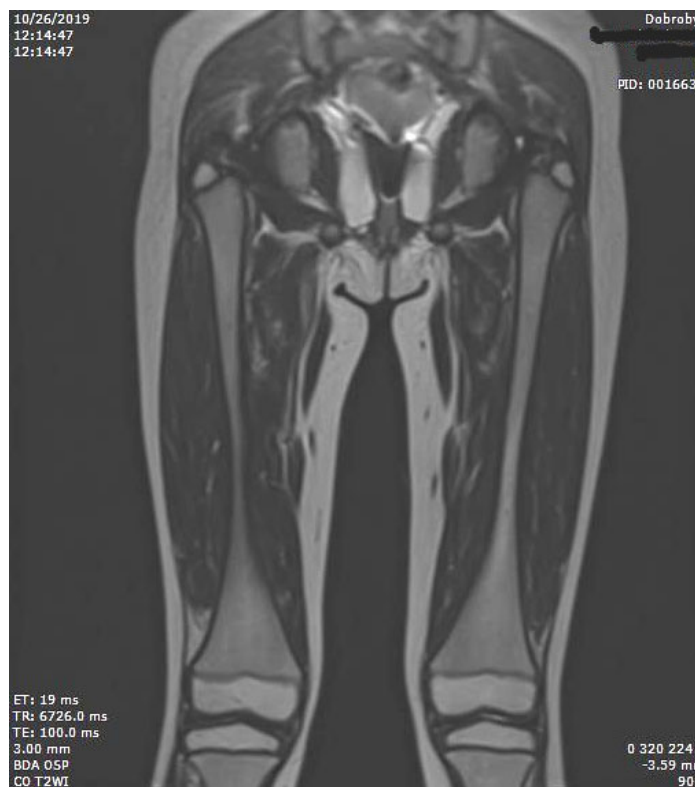


Fig. 4. MRI of the proximal lower extremities (5-years old girl with LGMD2A) showed symmetrical atrophic changes in the major adductor muscle, the long and short adductor muscles, the semitendinosus muscle of the thigh

Case 2

Patient B., 25 year old woman from Ukraine, complained of gradually progressive weakness of the muscles of the hip, shoulder, pelvic and shoulder girdles, which caused walk difficulty and changes in the gait, as well as difficulty when climbing stairs, getting up from the floor, abduction in the upper limbs, flexion and extension in the elbow joints (Fig. 5). The first signs of the disease were observed at the age of 15 years as the weakness of pelvic girdle muscles, the progression of which, by the age of 18, caused difficulties in walking; since the age of 23, the patient noticed the appearance of weakness in the muscles of the shoulder girdle and upper limbs. The only child in the family, she was born from the first uncomplicated pregnancy, early development was normal, motor development in childhood was normal. At the age of 23, she visited a doctor for the above-mentioned complaints and, due to the presence of clinical signs of a neuromuscular disease, electromyography and a laboratory test for CPK were performed. A myopathic pattern on electromyography and high levels of CPK were discovered. In the neurological status, a pattern of moderate, symmetrical, prevailing weakness of the muscles of the shoulder, hip, shoulder and pelvic girdle was observed (Medical Research Council score – 2/5 in major pectoral muscle, 2/5 – subscapular, 2/5 – in suprascapular, 2/5 – in infrascapular, 3/5 – in

deltoid, 3/5 – in biceps and triceps, 4+/5 – in wrist extension, 4+/5 – in wrist flexion, 1/5 – in psoas, 2/5 – in hip adductors and abductors, 2/5 – in quadriceps, 2/5 – in shin flexion, 4/5 – in posterior femoris and tibialis anterior, and 4+/5 – in plantar flexion muscles bilaterally as well as muscular atrophy.

Decreased muscle tone and limb strength were mainly seen in the proximal parts of the lower (predominantly) and upper extremities. Wing-like scapulae winging and Gover's symptom were present. Ocular, facial, bulbar and neck muscles were not involved. All deep tendon reflexes were absent. There was no fasciculation or upper motor signs, calf pseudo-hypertrophy or joint contractures. Sensation (pinprick, light touch, vibration and position sense) was also normal. There was no intellectual disability. Blood serum CPK was elevated (1500-2100 UI/L). Somatic status, forced vital capacity, ECG, echocardiography and chest X-ray did not show any significant abnormalities.

Parents of the young woman both exhibited normal CPK levels and had no symptoms of weakness or gait disorders. A sequence analysis and a testing of deletion/duplication of the 123 genes of Comprehensive Neuromuscular Disorders Panel was researched. As a result, a homozygous, pathogenic variant of the defect in the CAPN3 gene c.550del (p.Thr184Argfs * 36) was identified.

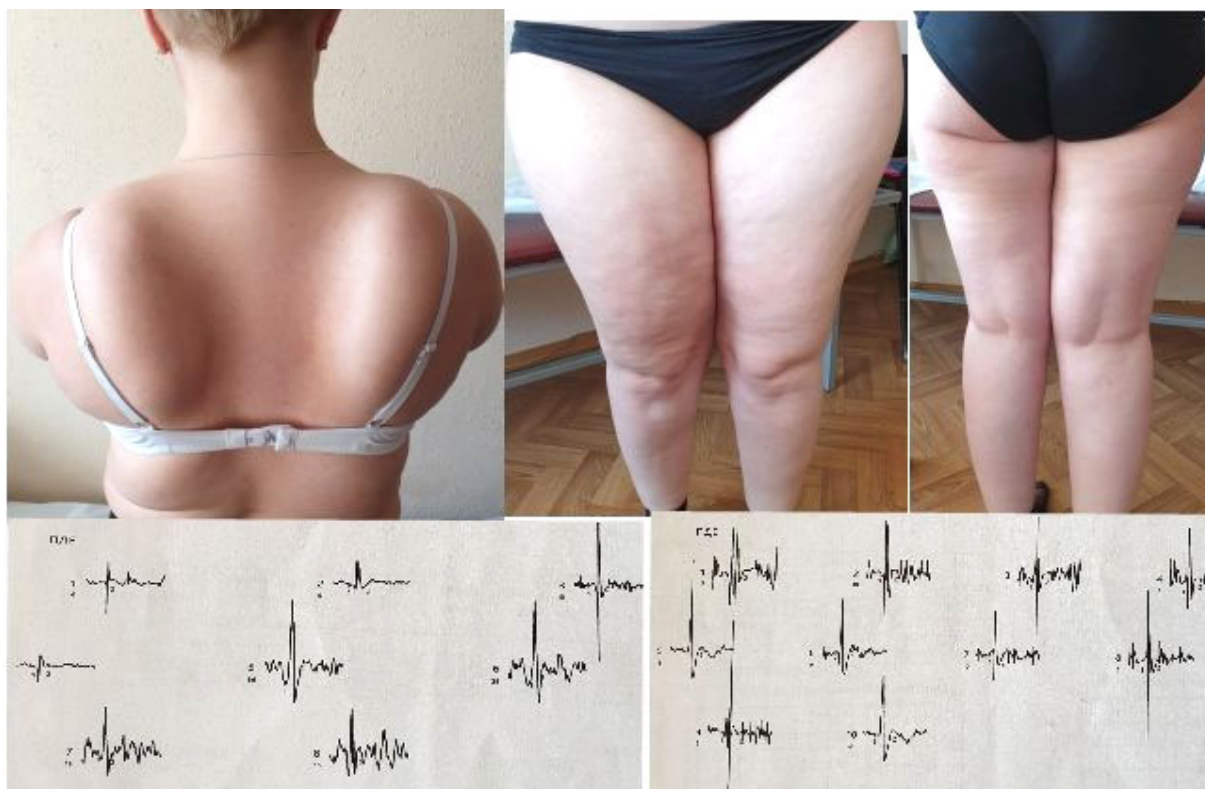


Fig. 5. 25-year-old woman with limb-girdle muscular dystrophy type 2A

Discussion

The various forms of limb-girdle muscular dystrophy are caused by mutations in many different genes. Calpainopathy or limb-girdle muscular dystrophy type 2A (LGMD2A), is one of the most common forms caused by mutations in the CAPN3 gene (locus15q15.1) (OMIM *114240), encoding calpain-3, a calcium dependent protease [1]. Cases of LGMD2A were reported in different geographic regions [1, 10, 11]. However, its prevalence in Ukraine and other Eastern Europe countries is currently unknown and patients with this form of muscular dystrophy have never been described in Ukraine previously.

Clinical features of LGMD2A are similar to other types of LGMD and include a slowly progressive, symmetrical, limb-girdle weakness and selective muscle atrophy of proximal limbs and pelvic muscles, wing-like scapulae winging, scoliosis and joint contractures [4, 14, 12].

LGMD2A patients can be subdivided in three different clinical phenotypes depending on age of onset: 1) "early onset of LGMD" with onset of muscle weakness occurring in the pelvic girdle before the age of 12; 2) "LGMD" with onset of weakness in the pelvic-femoral girdle (the classical Leyden-Mobius type) or in the shoulder girdle (Erb phenotype with wing-like scapulae) between the age of 13 and 29 years; 3) "late onset of LGMD" with onset of weakness in the pelvic girdle at the age of 30 years or more [14].

Respiratory failure in calpainopathy is known to occur in patients with an advanced stage of the disease, particularly after ambulation loss [13].

We report two young women with LGMD2A due to mutation in CAPN3 gene with different ages of the onset of the symptoms. In Ukraine there is no statistics regarding the prevalence of muscle disorders.

In the first case deletion of exon 8 and c.550delA (p.Thr184Argfs*36) mutation was found in CAPN3. Second patient has had homozygous, pathogenic variant of the defect in the CAPN3 gene c.550del but despite homozygous mutation she had more later age of onset. In German patients with LGMD2A c.550delA mutation was found in 8.1% (n=1 homozygous, n=7 heterozygous) so this mutation is rather frequently observed in people with LGMD2 [5, 10].

CONCLUSION

Two case reports present young women from Ukraine with autosomal recessive LGMD2 both with negative family anamnesis, increased creatinine phosphokinase level and c.550delA mutations. Onset, progression and distribution of the weakness and muscle wasting vary considerably among individuals and genetic subtypes. In conclusion, this is the first reported Ukrainian LGMD2A patients with a novel c.550delA mutations. Molecular diagnosis should be considered when characteristic muscle pathology and imaging are observed. We hope that our report can further enhance the identification of more LGMD2A patients and help to elucidate genotypic and clinical characteristics of these patients in Ukraine.

Conflict of interests. The authors declare no conflict of interest.

REFERENCES

1. Albuquerque M. Limb-girdle muscular dystrophy in Brazilian children: clinical, histological and molecular characterization. *Arquivos de Neuro-Psiquiatria*. 2014;72(6):481-481
doi: <https://doi.org/10.1590/0004-282x20140037>
2. Cotta A, Carvalho E, da-Cunha-Júnior A, Paim J, Navarro M, Valicek J, et al. Common recessive limb girdle muscular dystrophies differential diagnosis: why and how?. *ArquivosdeNeuro-Psiquiatria*. 2014;72(9):721-734. doi: <https://doi.org/10.1590/0004-282X20140110>
3. Dincer P. A cross section of autosomal recessive limb-girdle muscular dystrophies in 38 families. *Journal of Medical Genetics*. 2000;37(5):361-367.
doi: <https://doi.org/10.1136/jmg.37.5.361>
4. Liu W, Pajusalu S, Lake N, Zhou G, Ioannidis N, Mittal P et al. Estimating prevalence for limb-girdle muscular dystrophy based on public sequencing databases. *Genetics in Medicine*. 2019;21(11):2512-2520. doi: <https://doi.org/10.1038/s41436-019-0544-8>
5. Grimm D, Hanisch F, Liu X, Müller-Reible C, Zierz S, Deschauer M. Frequency of calpain-3 c.550delA mutation in limb girdle muscular dystrophy type 2 and isolated hyperCKemia in German patients. *Aktuelle Neurologie*. 2006;33(S 1).
doi: <https://doi.org/10.1055/s-2006-95302211>
6. Haberlová J. Evaluation and Treatment of Myopathies. *European Journal of Human Genetics*. 2015;23(10):1433-1433.
doi: <https://doi.org/10.1038/ejhg.2015.127>
7. Kaplan J, Hamroun D. The 2015 version of the gene table of monogenic neuromuscular disorders (nuclear genome). *Neuromuscular Disorders*. 2014;24(12):1123-1153.
doi: <https://doi.org/10.1016/j.nmd.2014.11.001>
8. Khadilkar S. Limb girdle muscular dystrophies in India. *Neurology India*. 2015;63(4):495.
doi: <https://doi.org/10.4103/0028-3886.161989>

9. Broglio L, Tentorio M, Cotelli M, Mancuso M, Vielmi V, Gregorelli V, et al. Limb-Girdle Muscular Dystrophy-Associated Protein Diseases. *The Neurologist*. 2010;16(6):340-352.
doi: <https://doi.org/10.1097/NRL.0b013e3181d35b39>
10. Wang C, Liang W, Minami N, Nishino I, Jong Y. Limb-girdle Muscular Dystrophy Type 2A with Mutation in CAPN3: The First Report in Taiwan. *Pediatrics & Neonatology*. 2015;56(1):62-65.
doi: <https://doi.org/10.1016/j.pedneo.2013.01.018>
11. Oliveira Santos M, Ninitas P, Conceição I. Severe limb-girdle muscular dystrophy 2A in two young siblings from Guinea-Bissau associated with a novel null homozygous mutation in CAPN3 gene. *Neuromuscular Disorders*. 2018;28(12):1003-1005.
doi: <https://doi.org/10.1016/j.nmd.2018.09.009>
12. Pegoraro E, Hoffman EP. Limb-Girdle Muscular Dystrophy Overview. 2000 Jun 8 [Updated 2012 Aug 30]. In: Adam MP, Ardinger HH, Pagon RA, et al., editors. *GeneReviews®* [Internet]. Seattle (WA): University of Washington, Seattle; 1993-2019. Available from: <https://www.ncbi.nlm.nih.gov/books/NBK1408/>
13. Stöllberger C, Finsterer J. Cardiopulmonary involvement in limb girdle muscular dystrophy 2A. *Muscle & Nerve*. 2017;56(4):E38-E38.
doi: <https://doi.org/10.1002/mus.25369>
14. Angelini C, Nardetto L, Borsato C, Padoan R, Fanin M, Nascimbeni A, et al. The clinical course of calpainopathy (LGMD2A) and dysferlinopathy (LGMD2B). *Neurological Research*. 2010;32(1):41-46.
doi: <https://doi.org/10.1179/174313209X380847>

СПИСОК ЛІТЕРАТУРИ

1. Albuquerque M. Limb-girdle muscular dystrophy in Brazilian children: clinical, histological and molecular characterization. *Arquivos de Neuro-Psiquiatria*. 2014. Vol. 72, No. 6. P. 481-481.
DOI: <https://doi.org/10.1590/0004-282x20140037>
2. Common recessive limb girdle muscular dystrophies differential diagnosis: why and how? / A. Cotta et al. *Arquivos de Neuro-Psiquiatria*. 2014. Vol. 72, No. 9. P. 721-734.
DOI: <https://doi.org/10.1590/0004-282X20140110>
3. Dincer P. A cross section of autosomal recessive limb-girdle muscular dystrophies in 38 families. *Journal of Medical Genetics*. 2000. Vol. 37, No. 5. P. 361-367.
DOI: <https://doi.org/10.1136/jmg.37.5.361>
4. Estimating prevalence for limb-girdle muscular dystrophy based on public sequencing databases / W. Liu et al. *Genetics in Medicine*. 2019. Vol. 21, No. 11. P. 2512-2520.
DOI: <https://doi.org/10.1038/s41436-019-0544-8>
5. Frequency of calpain-3 c.550delA mutation in limb girdle muscular dystrophy type 2 and isolated hyperCKemia in German patients / D. Grimm et al. *Aktuelle Neurologie*. 2006. Vol. 33, S 1.
DOI: <https://doi.org/10.1055/s-2006-95302211>
6. Haberlová J. Evaluation and Treatment of Myopathies. *Eur. Journal of Human Genetics*. 2015. Vol. 23, No. 10. P. 1433-1433.
DOI: <https://doi.org/10.1038/ejhg.2015.127>
7. Kaplan J., Hamroun D. The 2015 version of the gene table of monogenic neuromuscular disorders (nuclear genome). *Neuromuscular Disorders*. 2014. Vol. 24, No. 12. P. 1123-1153.
DOI: <https://doi.org/10.1016/j.nmd.2014.11.001>
8. Khadilkar S. Limb girdle muscular dystrophies in India. *Neurology India*. 2015. Vol. 63, No. 4. P. 495.
DOI: <https://doi.org/10.4103/0028-3886.161989>
9. Limb-Girdle Muscular Dystrophy-Associated Protein Diseases / L. Broglio et al. *The Neurologist*. 2010. Vol. 16, No. 6. P. 340-352.
DOI: <https://doi.org/10.1097/NRL.0b013e3181d35b39>
10. Limb-girdle Muscular Dystrophy Type 2A with Mutation in CAPN3: The First Report in Taiwan / C. Wang et al. *Pediatrics & Neonatology*. 2015. Vol. 56, No. 1. P. 62-65.
DOI: <https://doi.org/10.1016/j.pedneo.2013.01.018>
11. Oliveira Santos M., Ninitas P., Conceição I. Severe limb-girdle muscular dystrophy 2A in two young siblings from Guinea-Bissau associated with a novel null homozygous mutation in CAPN3 gene. *Neuromuscular Disorders*. 2018. Vol. 28, No. 12. P. 1003-1005.
DOI: <https://doi.org/10.1016/j.nmd.2018.09.009>
12. Pegoraro E., Hoffman E. P. Limb-Girdle Muscular Dystrophy Overview. 1993-2019. *GeneReviews®* [Internet]. Seattle (WA): University of Washington, Seattle. 2000. 8 Jun. [Updated 2012 Aug 30]. Available from: <https://www.ncbi.nlm.nih.gov/books/NBK1408/>
13. Stöllberger C., Finsterer J. Cardiopulmonary involvement in limb girdle muscular dystrophy 2A. *Muscle & Nerve*. 2017. Vol. 56, No. 4. P. E38-E38.
DOI: <https://doi.org/10.1002/mus.25369>
14. The clinical course of calpainopathy (LGMD2A) and dysferlinopathy (LGMD2B) / C. Angelini et al. *Neurological Research*. 2010. Vol. 32, No. 1. P. 41-46.
DOI: <https://doi.org/10.1179/174313209X380847>

The article was received
2020.06.15

