

CASE REPORT

NEW-ONSET ISOLATED ACALCULIA AS A CONSEQUENCE OF RIGHT TEMPORO-PARIETO-OCCIPITAL JUNCTION INFARCT

Nataliya NEKRASOVA¹, Olena TOVAZHNYANSKA¹, Rhea SINGH^{1✉}, Serhii RUDENKO¹,
Olena RIZNYCHENKO¹, Kseniia ZUB¹

¹ Department of Neurology, Kharkiv National Medical University, Kharkiv, Ukraine

Received July 05th, 2022, accepted August 22nd, 2022

<https://doi.org/10.31688/ABMU.2022.57.3.13>

ABSTRACT

Introduction. Acalculia is defined as a form of cognitive impairment, manifested by the loss of ability to perform calculations and use arithmetical concepts because of the damage to some parts of the cerebral cortex, with a subcortical extension.

Case presentation. We present a unique case of a 74-year-old right-handed patient with isolated acalculia on a background of ischaemic stroke in the right parietal lobe. Physical examination, laboratory tests, and various instrumental and neurological investigations including electroencephalogram and magnetic resonance imaging (MRI) were performed. Brain MRI showed a subacute infarct in the area of the right temporo-parieto-occipital junction and multiple subcortical lesions of vascular origin in the frontal and parietal lobes. The patient was treated with aspirin, enalapril, and atorvastatin, along with cognitive rehabilitation therapy. During subsequent follow-up visits, a decrease in the severity of acalculia was noticed, but complete recovery was yet to be achieved.

Conclusions. Acalculia is a form of cognitive impairment, which may either be part of Gerstmann syndrome, or an isolated symptom of cognitive decline in stroke, tumours, Binswanger's disease, several types of

RÉSUMÉ

Acalculie isolée d'apparition nouvelle à la suite d'un infarctus de jonction temporo-pariéto-occipital droite

Introduction. L'acalculie est définie comme une forme de déficience cognitive, manifestée par la perte de capacité à effectuer des opérations de calcul et à utiliser des concepts arithmétiques en raison de dommages à certaines parties du cortex cérébral avec une extension sous-corticale.

Rapport du cas. Nous présentons un cas unique d'un patient droitier de 74 ans présentant une manifestation d'acalculie isolée sur fond d'accident ischémique cérébral dans le lobe pariétal droit. Des examens systématiques, des analyses de laboratoire, diverses investigations instrumentales et neurologiques, y compris l'EEG et l'IRM, ont été effectués. Acalculie comme une variante rare de déficience cognitive chez un patient ukrainien de 74 ans dont le cerveau d'IRM a montré un infarctus subaigu dans la région de la jonction pariéto-occipitale droite et des lésions sous-corticales multiples d'origine vasculaire dans les lobes frontaux et pariétaux. Le patient a été traité avec de l'aspirine, de l'énalapril et de l'atorvastatine, ainsi que par une thérapie de réadaptation cognitive. Au cours

✉ Address for correspondence:

Rhea SINGH
Kharkiv National Medical University
Address: Kharkiv Nauky Avenue 4, 61022, Kharkiv, Ukraine
E-mail: rheasingh@yahoo.com; Phone: +91 9888929093

dementia, epilepsy, and some other diseases. However, a subacute isolated presentation is rare.

Keywords: acalculia, right parietal lobe infarct, ischaemic stroke, cognitive impairment.

des visites de suivi subséquentes, on a remarqué une diminution de la gravité des calculs, mais le rétablissement complet n'a pas encore été atteint.

Conclusions. L'acalculie est une forme de déficience cognitive, qui peut faire partie du syndrome de Gerstmann, ou un symptôme isolé de déclin cognitif dans l'AVC, la tumeur, la maladie de Binswanger, plusieurs types de démence, l'épilepsie, et quelques autres maladies. Cependant, une présentation isolée subaiguë est rare.

Mots-clés: acalculie, infarctus du lobe pariétal droit, accident ischémique cérébral, déficience cognitive.

Abbreviations list:

NIH Stroke Scale = National Institute of Health Stroke Scale

CAD= coronary artery disease

GCS= Glasgow coma scale

MoCA= Montreal Cognitive Assessment

MCI= mild cognitive impairment

AD= Alzheimer disease

MS= multiple sclerosis

PML= progressive multifocal leukoencephalopathy

HF=heart failure

EEG= electroencephalography

ECG= electrocardiography

BP= blood pressure

INTRODUCTION

The term „acalculia” was originally used by Henschen in 1925 to define an impaired ability to perform calculations, resulting from various brain lesions. Before that, calculation disturbances were considered as a form of language disorder¹. Primary acalculia is defined as a form of cognitive impairment, manifested by the loss of ability to perform calculating operations and use arithmetical concepts. Secondary acalculia is the inability to perform numerical operations due to mental or intellectual disabilities². Gerstmann, in 1940, combined primary acalculia with finger agnosia, agraphia, and left-right disorientation in a single clinical syndrome, which is now known as „angular gyrus syndrome” or „Gerstmann syndrome”³. In recent years, isolated acalculia and Gerstmann syndrome were associated not only with the lesion of the posterior parietal cortex (predominantly left, sometimes right), but also with the disconnection of neural pathways in the subcortical parietal white matter^{1,3-5}. There is some data about the association of acalculia with ischaemic and haemorrhagic stroke⁶, brain tumours^{7,8}, several types of dementia (Alzheimer's disease, vascular dementia)⁹,

multiple sclerosis⁵, and infectious diseases^{3,10-12}. Most of the articles related to acalculia are single-case reports and cases of „pure” acalculia are uncommon.

CASE PRESENTATION

A 74-year-old right-handed male was hospitalized to the Department of Neurology in the Regional Clinical Hospital in Kharkiv, Ukraine in June 2021, on the third day of the disease with complaints of new-onset amnesia related to numbers, including inability to perform basic arithmetic operations like counting money, inability to read the clock, remember phone numbers or combine individual sounds into a single melody, along with easy distractibility, fatigue and slight hemiparesthesia on the left side. The disease began with an acute speech impairment, the patient having difficulty in pronouncing simple words, even his own name. Although the aphasia resolved by the second day of disease, the acalculia gradually worsened over the period of day 2 and day 3, with the deficit reaching its peak on day 3. Upon admission, the initial diagnosis of ischaemic stroke in the right parietal lobe was made.

The medical history of the patient was significant for primary arterial hypertension and heart failure (HF). The patient's average blood pressure (BP) remained in the range of 130-140/80 mm Hg, with periodic increases up to 180/100 mm Hg, for which he occasionally took indapamide 2.5 mg, metoprolol 25 mg, amlodipine 5 mg and enalapril 10 mg. The patient also suffered from coronary artery disease (CAD) treated with atorvastatin 40 mg and aspirin 75 mg. There was no history of diabetes mellitus or severe infectious diseases. He reported no medical history of any neurological disturbances, no history of smoking, drug or alcohol abuse. He was a biology teacher at a public school by profession. His family history was insignificant for any major diseases.

The initial medical examination revealed intact consciousness with Glasgow Coma Scale (GCS) score of 15/15. However, the patient answered the questions with a slight delay (1-2 seconds). He had skin pallor. The cardiovascular examination revealed muffled heart sounds without carotid bruit and a BP of 130/80 mm Hg. The examination of the respiratory, digestive, urinary, and musculoskeletal systems was insignificant.

Upon neurological examination, a slight asymmetry of the nasolabial folds was revealed. All other cranial nerves were intact, with no visual field defects. Tendon reflexes were symmetrical on both sides, with muscle strength grade of 5/5 in all limbs. Pathological reflexes, coordination/balance impairment and sensory deficits were not detected. Meningeal irritation signs (neck stiffness, Brudzinski sign, Kernig sign) were all negative. NIH Stroke Scale score on admission was 1 point (due to slight asymmetry of the nasolabial folds).

A comprehensive evaluation of cognitive functions using the Montreal Cognitive Assessment (MoCA) revealed that the patient is unable to identify written numbers, perform basic arithmetic calculations (addition, subtraction, multiplication, division) or correctly perform clock drawing task. He was incapable of performing the Digit-Span (forward and backward) tests, as well as couldn't execute the task for visuospatial constructive abilities related to numbers. At the same time, the short-term memory recall task was accurate and the ability to name the current date, month, and year was also preserved. The overall MoCA score was 23/30, which can be interpreted as mild cognitive impairment (MCI)¹³. No signs of trauma were detected. A complete blood count revealed no abnormalities. Troponin I test and coagulation profile also revealed no abnormality. Blood glucose level was within normal limits. The lipid panel showed presence of hyperlipidaemia IIb type.

Brain magnetic resonance imaging (MRI) with contrast was performed, demonstrating

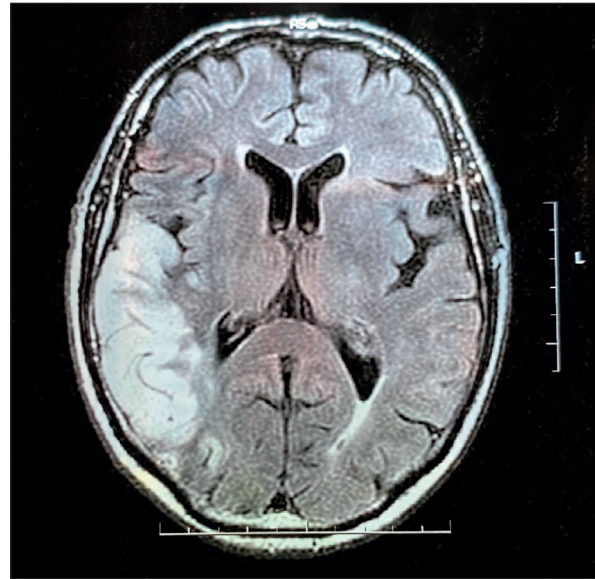


Figure 1. T2-FLAIR brain MRI images, demonstrating a hyperintense area in the right temporo-parieto-occipital (TPO) junction and subcortical white matter, consistent with a subacute infarction, about the size of 78x34x43 mm.

hyperintensity in the middle cerebral artery supply area, involving the right temporo-parieto-occipital (TPO) junction (area of angular gyrus) and subcortical white matter, consistent with a subacute infarction, about a size of 78x34x43 mm (Figure 1). The widespread multifocal subcortical ischaemic lesions in the deep regions of the frontal and parietal lobes were also detected.

Neck ultrasound revealed signs of carotid artery disease without hemodynamic stenosis (26%). Electroencephalography (EEG) didn't reveal any pathological pattern. Electrocardiography (ECG) showed signs of left ventricular hypertrophy. Echocardiography also revealed signs of left ventricular hypertrophy, as well as mild mitral regurgitation and diastolic heart failure. Cardiovascular consultation exhibited primary arterial hypertension, HF, CAD and valvular heart disease.

Thrombolysis was not performed, due to exceeding of its therapeutic time interval according to the American Heart Association/American Stroke Association guidelines. The patient was prescribed aspirin 200 mg once a day (OD) for 14 days, 0.9% normal saline 200 ml twice a day for 7 days and OD for the next 7 days, atorvastatin 40 mg OD for 14 days, enalapril 10 mg OD for 14 days. Cognitive rehabilitation therapy, involving exercises for training calculations, was also recommended.

After 14 days, the patient was discharged from the neurological department with strict advice to continue antihypertensive, lipid-lowering therapy, and

cognitive rehabilitation. During subsequent follow-up visits, a decrease in the severity of acalculia was noticed, but complete recovery had yet to be achieved. In general, the patient was doing well, without other impairment or neurological deficits.

DISCUSSION

The first case report of a patient presenting with difficulties in performing calculations accompanied by the absence of language impairment was mentioned by Lewandowsky and Stadelmann in 1908¹⁵. Before this case, calculation disturbances were considered as a form of language disorders. The term „acalculia” was used by Henschen in 1925 and was defined as impaired ability to perform calculations resulting from numerous brain lesions. Later, acalculia was classified by Berg into primary and secondary¹⁶. Ardila and Rosselli in 2002¹ proposed to classify secondary acalculia into: a) Aphasic, b) Agraphic, c) Alexic, d) Spatial, e) Dysexecutive.

There is no united statistical data about the incidence of acalculia, but the clinical experience of individual specialists shows that acalculia is rarely found as an isolated impairment. Mostly, it is accompanied by various combinations of motor, sensory, or any other neurological deficit¹⁵. Sometimes, it is a symptom of progressive cognitive decline or even dementia. Primary acalculia is often associated with finger agnosia, agraphia, and left-right disorientation which can be combined under a single clinical syndrome known as „angular gyrus syndrome” or „Gerstmann syndrome” (firstly described by Gerstmann in 1940)³. Modern authors neuroanatomically associate acalculia and Gerstmann syndrome not only with the lesion of the posterior parietal cortex (predominantly left, sometimes right)¹⁷, as it was considered historically, but also with the disconnection of neural pathways in the subcortical parietal white matter, that is, with the subcortical extension^{1,3,4,18}. According to some authors, acalculia can be a sign of different neurological disorders. In ischaemic stroke, acalculia is a manifestation of cortical and subcortical arterial insufficiency. Its onset can be acute or gradual (within a couple of days) and can be accompanied by any other neurological deficit. The lesion is usually located in one of the mentioned strategic areas^{6,19}. Our patient presented initially with speech impairment, which resolved within 24 hours, but the calculation difficulties gradually developed and over the next two days, the deficit reached its maximum. His brain MRI revealed subacute infarction in the area of the right TPO junction, so the intracerebral hemorrhage or chronic subdural hematoma were excluded.

In Alzheimer disease (AD), acalculia is one of the symptoms of complex cognitive decline, along with impairment of memory, speech, attention, personality changes, inability to perform day-to-day household activities, etc. Typically, cognitive decline in AD develops gradually within 5-10 years and is accompanied by significant disability⁹. The onset of the disease in our patient was subacute. Before the mentioned episode, he did not experience any issues related to cognitive dysfunction despite his advanced age, which was also confirmed by his family. Moreover, the patient’s MRI did not reveal any diffuse cortical atrophy with enlargement of the ventricles, which is typical for AD. Therefore, AD is unlikely in this case.

Acalculia can also present as a symptom of demyelinating diseases, such as multiple sclerosis (MS)⁵. Our patient did not have any sensory, motor, or ophthalmological complaints that would allow to „stick” for the diagnosis of MS. In addition, the MRI did not reveal hyperintense demyelinating plaques in white matter, which are typical for MS. Thus, multiple sclerosis was also ruled out.

Widespread multifocal subcortical ischaemic lesions in the deep regions of the frontal and parietal lobes, which were found in our patient, can be associated with vascular dementia (for example, Binswanger’s disease), but the absence of any other symptoms of subcortical dementia as cognitive decline (except for acalculia), ataxia, gait, or posture changes made this diagnosis unlikely.

Infectious diseases such as encephalitis of various etiology, mucormycosis, and progressive multifocal leukoencephalopathy (PML) can also be accompanied by acalculia^{11,12}. However, our patient had no typical symptoms of infectious disease and inflammatory blood changes, therefore encephalitis was excluded. MRI did not reveal multiple hyperintense asymmetric lesions in the frontal, parietal, or occipital white matter, which are typical for PML, thus ruling out PML.

The treatment options depend on the cause of the underlying disease. In the case of an ischaemic stroke, according to modern guidelines, this is thrombolytic therapy. If it is impossible to use thrombolytics due to some reason (contraindications or time limit of the therapeutic window is exceeded), then symptomatic and supportive therapy is prescribed¹⁴. The rehabilitation strategy includes two options:

- The recovery of lost calculating abilities or
- The development of alternative ways to compensate the patient’s deficit.

Both strategies include cognitive rehabilitation exercises aimed at learning numerical concepts and performing various arithmetic operations¹. Sometimes, acalculia can be considered as an early

symptom of subsequent cognitive decline and even as a prognostic marker of dementia development after an ischaemic stroke (it develops in 15% of patients after an ischaemic stroke)¹⁵.

CONCLUSIONS

We presented a new-onset isolated acalculia in a 74-year-old patient as a result of right sided temporo-parieto-occipital junction ischaemic stroke, with no prior neurological deficits or any history of chronic diseases associated with acalculia.

Author Contributions

„S.R. and N.N. performed the clinical examination of the patient. N.N. performed neck ultrasound. N.N., O.T. and K.Z. analyzed and interpreted the patient data. N.N., R.S. and O.R. performed the literature review. N.N. and R.S. were the major contributors for writing the manuscript. All authors read and approved the final manuscript.”

Compliance with Ethics Requirements:

„The authors declare no conflict of interest regarding this article”

„The authors declare that all the procedures and experiments of this study respect the ethical standards in the Helsinki Declaration of 1975, as revised in 2008(5), as well as the national law. Informed consent was obtained from the patient included in the study. The clinical case presentation was approved by the Ethics Committee of the Kharkiv National Medical University, Kharkiv, Ukraine on the 14th of July 2021”

„No funding for this study”

Acknowledgments

We would like to thank all the colleagues involved in this case.

REFERENCES

- Ardila A, Rosselli M. Cognitive rehabilitation of acquired calculation disturbances. from: <http://dx.doi.org/10.1155/2019/3151092>
- Ardila A. Gerstmann syndrome. *Curr Neurol Neurosci Rep*. 2020;20(11):48.
- Altabakhi IW, Liang JW. Gerstmann Syndrome. In: StatPearls. StatPearls Publishing; 2021.
- Ardila A. A proposed reinterpretation of Gerstmann's syndrome. *Arch Clin Neuropsychol*. 2014;29(8):828-33.
- Puthenparampil M, Poggiali D, Causin F, et al. Cortical relapses in multiple sclerosis. *MultScler*. 2016;22(9):1184-91.
- João RB, Filgueiras RM, Mussi ML, de Barros JEF. Transient Gerstmann syndrome as manifestation of stroke: Case report and brief literature review. *Dement Neuropsychol*. 2017;11(2):202-5.
- Jang A, Smith TA, Trainor S, Caldwell PC. Manifestation of metastatic lung adenocarcinoma as Gerstmann syndrome. *BMJ Case Rep*. 2020;13(10):e238098.
- Natteru P, Ramachandran Nair L, Luzardo G, Shaikh N. Meningeal hemangiopericytoma presenting as pure Gerstmann syndrome: A double rarity. *Cureus*. 2021;13(6):e15863.
- Mendez MF, Moheb N, Desarant RE, Teng EH. The progressive acalculia presentation of parietal variant Alzheimer's disease. *J Alzheimers Dis*. 2018;63(3):941-8.
- Nekrasova N, Tovazhnyanska O, Sushetska D, et al. Neurocysticercosis with symptomatic epilepsy manifestation. *Med Glas (Zenica)*. 2021;18(2):444-9.
- Sanjo N, Kina S, Shishido-Hara Y, et al. Progressive multifocal leukoencephalopathy with balanced CD4/CD8 T-cell infiltration and good response to mefloquine treatment. *Intern Med*. 2016;55(12):1631-5.
- Stretz C, Mook A, Modak JM, Rodriguez JM, Nouh AM. Gerstmann syndrome in a patient with aggressive mucormycosis. *Neurohospitalist*. 2017;7(2):102-3.
- Ciesielska N, Sokołowski R, Mazur E, Podhorecka M, Polak-Szabela A, Kędziora-Kornatowska K. Is the Montreal Cognitive Assessment (MoCA) test better suited than the Mini-Mental State Examination (MMSE) in mild cognitive impairment (MCI) detection among people aged over 60? Meta-analysis. *Psychiatr Pol*. 2016;50(5):1039-52.
- Powers WJ, Rabinstein AA, Ackerson T, et al. Guidelines for the early management of patients with Acute Ischemic Stroke: 2019 update to the 2018 guidelines for the early management of Acute Ischemic Stroke: A guideline for health-care professionals from the American Heart Association/American stroke association. *Stroke*. 2019;50(12):e344-418.
- Grimaldi M, Jeanmonod R. Acute stroke presenting with isolated acalculia. *Am J Emerg Med*. 2018;36(10):1923.e1-1923.e3.
- Gonzalez R, Rojas M, Rosselli M, Ardila A. Acalculia in aphasia. *Arch Clin Neuropsychol*. 2021;36(4):455-64.
- Benavides-Varela S, Piva D, Burgio F, et al. Re-assessing acalculia: Distinguishing spatial and purely arithmetical deficits in right-hemisphere damaged patients. *Cortex*. 2017; 88:151-64.
- Rusconi E. Gerstmann syndrome: historic and current perspectives. *Handb Clin Neurol*. 2018; 151:395-411.
- Nicastro N, Tafer N, Schnider A, Di Pietro M. Gerstmann's syndrome associated with right parietal hemorrhage and arteriovenous malformation. *J Clin Neurol*. 2017;13(3):306-7.