

## CASE REPORT

# ACUTE MESENTERIC THROMBOSIS, SMALL INTESTINE NECROSIS AND PERITONITIS AS A COMPLICATION OF COVID-19 – A CASE REPORT

Nevena G. IVANOVA<sup>1,2</sup>✉

<sup>1</sup> Department of Urology and General Medicine, Faculty of Medicine, Medical University of Plovdiv, Plovdiv, Bulgaria

<sup>2</sup> St Karidad MBAL, Karidad Medical Health Centre, Cardiology, Plovdiv, Bulgaria

Received May 10<sup>th</sup>, 2022, accepted July 17<sup>th</sup>, 2022

<https://doi.org/10.31688/ABMU.2022.57.3.11>

### ABSTRACT

**Introduction.** Severe acute respiratory syndrome coronavirus 2 (SARS-CoV-2) belongs to a family of ribonucleic acid (RNA) viruses, causing novel coronavirus disease 2019 (COVID-19). Because of a global inflammatory response and endothelial damage, COVID-19 may predispose to coagulation disorders and severe thrombotic events.

**Case presentation.** A 62-year-old man patient was admitted for COVID-19 pneumonia and abdominal pain for 10 days. Because of the rapid deterioration of the clinical status, shock and evidence of peritoneal irritation, the patient was consulted by a surgeon. The native spiral computed tomography (CT) of the abdomen detected enlarged colon filled with air collections and hydro-aeric levels. The surgical intervention revealed diffuse peritonitis with necrosis of the distal ileum secondary to mesenteric thrombosis. A partial resection of the ileum was done. The histological examination showed an infarcted small bowel, with hemorrhage, vascular thrombosis, and signs of necrotizing endovascularitis.

**Conclusions.** SARS-CoV-2 binds to ACE2 receptor, which results in increased signalling by thrombin

### RÉSUMÉ

**Thrombose mésentérique aiguë, nécrose de l'intestin grêle et péritonite en tant que complication du COVID-19 – rapport du cas**

**Introduction.** Le coronavirus 2 du syndrome respiratoire aigu sévère (SARS-CoV-2) appartient à une famille de virus à acide ribonucléique (ARN), provoquant une nouvelle maladie à coronavirus (COVID-19). En raison d'une réponse inflammatoire globale et de lésions endothéliales, le COVID-19 peut prédisposer aux troubles de la coagulation et aux événements thrombotiques graves.

**Rapport du cas.** Un homme de 62 ans a été hospitalisé pour une pneumonie au COVID-19 et des douleurs abdominales pendant 10 jours. En raison de la détérioration rapide de l'état clinique, du choc et des signes d'irritation péritonéale, le patient a été consulté par un chirurgien. La tomographie par ordinateur en spirale native de l'abdomen a détecté une hypertrophie du côlon remplie de collections d'air et de niveaux hydro-aériques. L'intervention chirurgicale a révélé une péritonite diffuse avec nécrose de l'iléon distal secondaire

✉ Address for correspondence:

Nevena G. IVANOVA  
St Karidad MBAL, Karidad Medical Health Centre, Cardiology, Plovdiv,  
Bulgaria  
Address: 23A Nikola Vapcarov St., Plovdiv 4004, Bulgaria  
Email: nevenai@yahoo.com, Phone +35 9889130416

receptors on platelet and endothelial cells, leading to coagulopathy. In older patients presenting with abdominal pain, shock and peritonitis, the most common underlying cause is mesenteric thrombosis which could be a complication of COVID-19.

**Keywords:** SARS-CoV-2, ACE2 receptor, endothelial damage, coagulopathy, mesenteric thrombosis

#### **List of abbreviations**

SARS-CoV-2 – severe acute respiratory syndrome coronavirus 2

RNA – ribonucleic acid

COVID-19 – coronavirus disease 2019

ACE2 – angiotensin-converting enzyme 2

GIT – gastrointestinal tract

CT – computed tomography

ECG – electrocardiogram

CRP – C-reactive protein

PCR – polymerase chain reaction

PAI-1 – plasminogen activator inhibitor 1

GM-CSF – granulocyte-macrophage colony-stimulating factor

TNF- $\alpha$  – tumour necrosis factor- $\alpha$

#### **INTRODUCTION**

Severe acute respiratory syndrome coronavirus 2 (SARS-CoV-2) belongs to a family of ribonucleic acid (RNA) viruses causing a novel coronavirus disease (COVID-19). It emerged in Wuhan, China in December 2019 and became pandemic in March 2020. It has changed the human history and is still a challenge for doctors, healthcare systems, science, and global economics. COVID-19 symptoms are non-specific and their severity can vary. The disease affects mainly the respiratory tract, causing either mild symptoms or bilateral pneumonia and even acute respiratory distress syndrome. The most common symptoms are fever, dry cough, fatigue, and headache. The angiotensin-converting enzyme 2 (ACE2) receptors serve as the virus gateway expressed in the surfaces of the respiratory and gastrointestinal (GIT) tracts, heart and vessels, particularly in the endothelial layer. GIT involvement can be characterized by abdominal pain, nausea, and vomiting with a variable incidence ranging from 5% to 50% of cases<sup>1,2</sup>. Due to a global inflammatory response and endothelial damage, COVID-19 may predispose to coagulation disorders and severe thrombotic events. Endothelial dysfunction and systemic inflammation may lead to a diffuse intravascular coagulation, blood stasis, causing severe ischaemia and necrotic tissue damages. Therefore, myocardial infarction, pulmonary embolism, stroke,

à une thrombose mésentérique. Une résection partielle de l'iléon a été réalisée. L'examen histologique a montré un infarctus de l'intestin grêle, avec hémorragie, thrombose vasculaire et signes d'endovascularite nécrosante. L'examen clinique a montré un infarctus de l'intestin grêle, avec hémorragie, thrombose vasculaire et signes d'endovascularite nécrosante.

**Conclusions.** Le SRAS-CoV-2 se lie au récepteur ACE2, ce qui entraîne une augmentation de la signalisation par les récepteurs de la thrombine sur les plaquettes et les cellules endothéliales, entraînant une coagulopathie. Chez les patients âgés présentant des douleurs abdominales, un choc et une péritonite, la cause sous-jacente la plus fréquente est la thrombose mésentérique qui pourrait être une complication du COVID-19.

**Mots-clés:** SARS-CoV-2, récepteur ACE2, lésions endothéliales, coagulopathie, thrombose mésentérique.

arterial (mesenteric) and venous thrombosis (deep vein), acute pericarditis, and rhythm disorders may develop.

The article presents a patient with acute mesenteric thrombosis, small intestine necrosis, and peritonitis as a complication of COVID-19, requiring emergency surgery.

#### **CASE PRESENTATION**

A 62-year-old man patient was admitted to hospital for shortness of breath, chills, severe weakness, fatigue, low-grade fever (37.2°C), and recurrent abdominal pain for 10 days. The pain, which seemed to be located in the epigastric area, radiating to both hypochondria and back, was more intense during the last 3 days. The patient lost his appetite and a significant amount of his weight. His past medical history was significant for arterial hypertension, treated with angiotensin receptor blockers (valsartan 160 mg once daily), beta blockers (bisoprolol 5 mg once daily), calcium channel blockers (amlodipine 5 mg twice daily), loop diuretic (furosemide 40 mg once daily). The physical examination revealed a poor general condition, tachypnea (25 breaths/min), weakened vesicular murmur with bilateral crepitations, tachycardia (100 beats per minute) and high blood pressure (180/60 mmHg). Pulse oximetry showed an oxygen saturation of 97%. Because of the rapid deterioration of

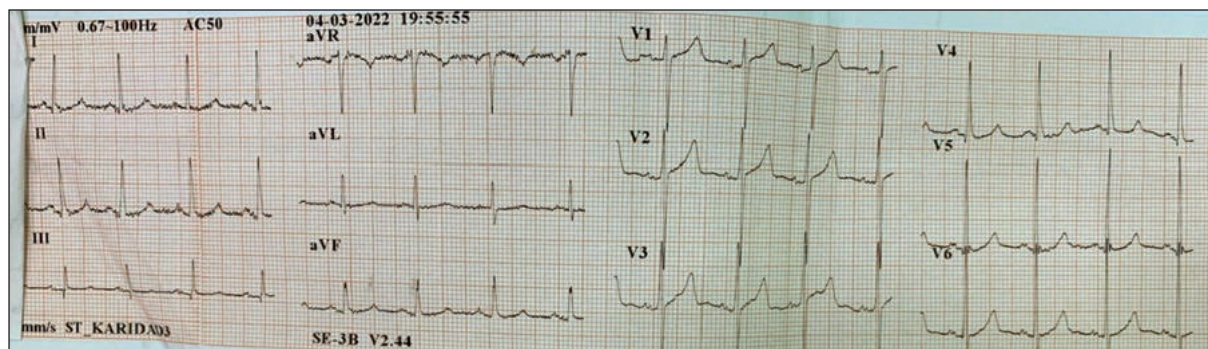


Fig. 1. Electrocardiogram

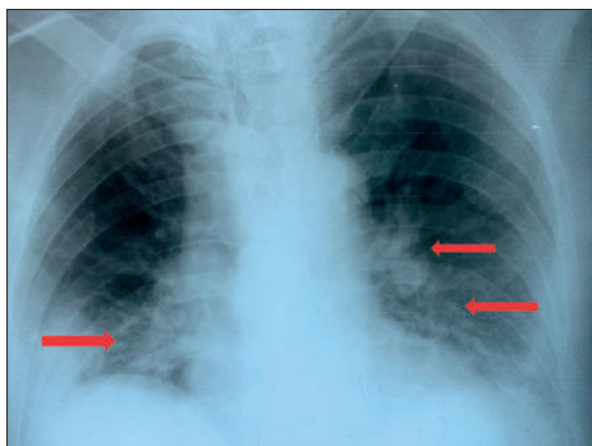


Fig. 2. Chest X-ray.  
Bilateral infiltrative-inflammatory changes

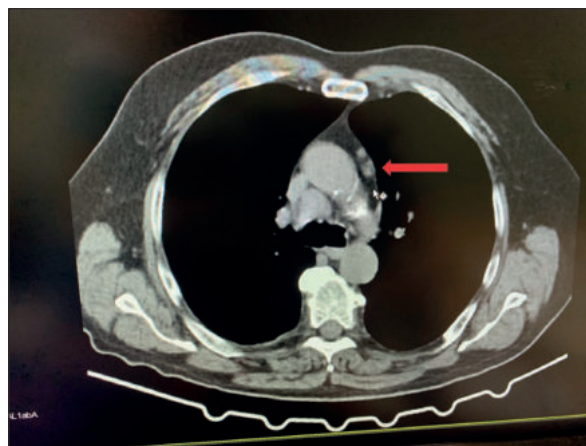


Fig. 3. Spiral CT scan of the mediastinum and lungs, 3D reconstructions.  
Pathologically enlarged mediastinal lymph nodes

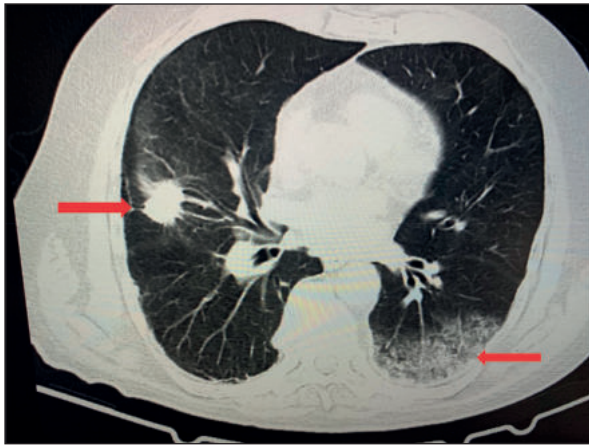
the clinical status, severe persistent pain in the right lower abdomen, shock, and evidence of peritoneal irritation, the patient was consulted by a surgeon. Several non-invasive investigations were done. The electrocardiogram (ECG) showed left axis deviation and sinus tachycardia (Fig. 1). Chest X-ray revealed bilateral infiltrative-inflammatory changes (Fig. 2). The findings of the laboratory tests were indicative of anaemia [erythrocytes  $1.97 \times 10^{12}/L$  (normal range for males  $4.2-6.2 \times 10^{12}/L$ ), haemoglobin 61.0 g/L (normal range 140-180 g/L), haematocrit 0.1668% (normal range 0.37-0.55%)], leukocytosis [ $32.06 \times 10^9/L$  (normal range 3.5 to  $10.5 \times 10^9/L$ )], thrombocytopenia [platelets  $118 \times 10^9/L$  (normal range  $130-440 \times 10^9/L$ )], and hypoproteinemia [total protein 39.0 g/L (normal range 63-84 g/L), serum albumin 22 g/L (normal range 35-55 g/L)]. The patient presented elevated levels of C-reactive protein (CRP) [164.4 mg/L (normal range 5-10 mg/L)], fibrinogen [6.57 g/L (normal range 2-4 g/L)], blood glucose [9.15 mmol/L (normal range 3.8-6.0 mmol/L)], creatinine [146.0  $\mu\text{mol}/L$  (normal range 71-115  $\mu\text{mol}/L$ )], urea [17.3 mmol/L (normal range 3-11.9 mmol/L)], potassium

[5.73 mmol/L (normal range 3.5-5.6 mmol/L), and D-dimer ( $>0.5$ , positive). The polymerase chain reaction (PCR) test for COVID-19 was positive.

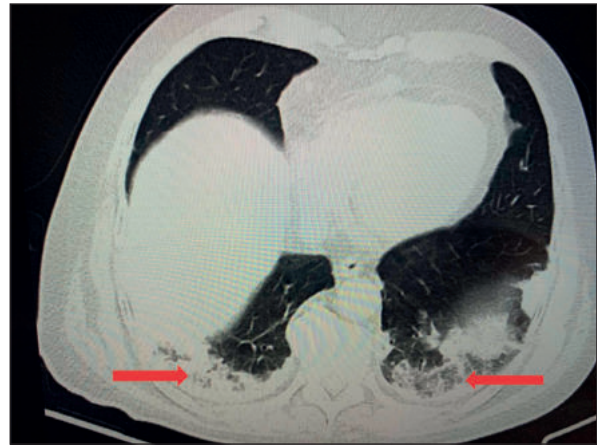The spiral computed tomography (CT) scan of the mediastinum and lungs with 3D reconstructions revealed pathologically enlarged mediastinal lymph nodes (Fig. 3). The bronchial tree structure had normal patency. A soft tissue lesion of about 2.4 cm, homogeneous structure, and uneven spiculoid external outlines was identified in the middle lobe of the right lung (Fig. 4). The CT findings were consistent with a bilateral basal and dorsal pulmonary fibrosis - COVID-pneumonitis with pleural seals (Fig. 4,5). The costodiaphragmatic sinuses were effusion-free. The conclusion was of a peripheral right lung tumour with mediastinal lymphadenopathy combined with COVID pneumonia.

The native spiral CT of the abdomen showed normal liver, with homogeneous structure and unexpanded intrahepatic bile ducts and blood vessels. No concretions were seen in the gallbladder. The spleen appeared normal. The pancreas was of normal size and with homogeneous structure. The left kidney had

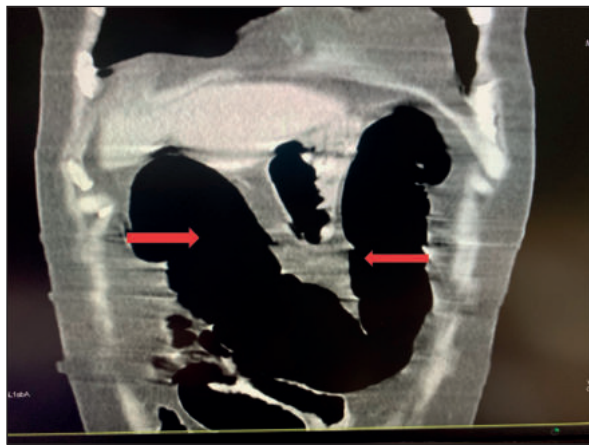




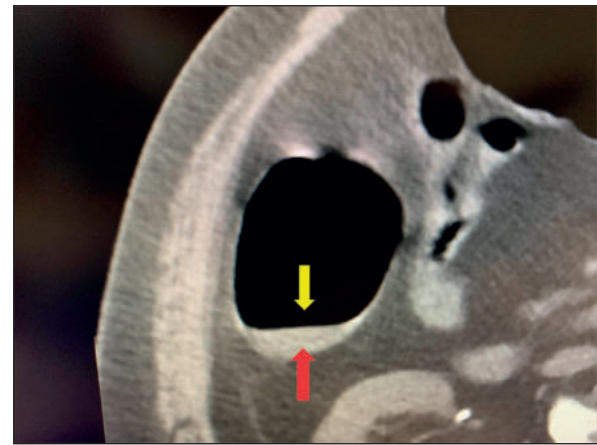
**Fig. 4. Spiral CT scan of the mediastinum and lungs, 3D reconstructions. Tissue lesion and bilateral basal and dorsal pulmonary fibrosis – COVID-pulmonitis**



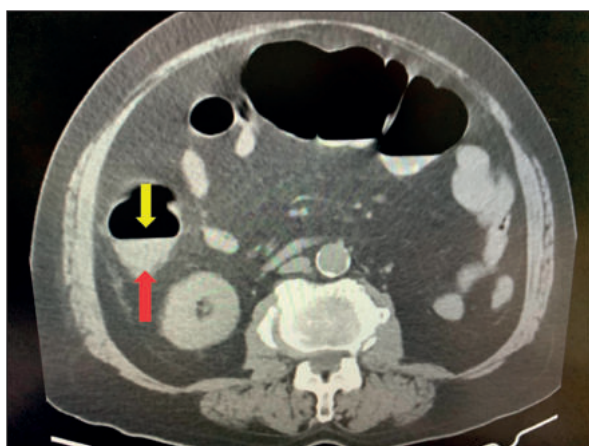
**Fig. 5. Spiral CT scan of the mediastinum and lungs, 3D reconstructions. Bilateral basal and dorsal pulmonary fibrosis – COVID-pulmonitis**



**Fig. 6. Native spiral CT scan of the abdomen. Aerocolia – enlarged colon filled with air collections.**



**Fig. 7. Native spiral CT of the abdomen. Hydro-aeric lesion in the area of the caecum.**



**Fig. 8. Native spiral CT of the abdomen. Hydro-aeric lesion in the area of the cecum.**

reduced parenchyma, nephrolithiasis, and parenchymal cysts. Important aerocolia was detected and: the colon was enlarged and filled with air collections (Fig.

6); a single hydro-aeric lesion was observed in the area of the caecum (Fig. 7, 8). There were no enlarged lymph nodes or free fluid. Due to the deteriorating condition of the patient, peritoneal involvement, enlarged colon, and hydro-aeric levels, he underwent emergency surgery for acute surgical abdomen, by midline laparotomy extended to the suprapubic area. The surgical intervention revealed diffuse peritonitis with necrosis of the distal ileum secondary to mesenteric thrombosis. A partial resection of the ileum was done with two sutures at 20 cm from the Bauhin's valve and proximal to a section about 45-50 cm long, then a latero-lateral anastomosis was performed. The histological examination showed an infarcted small bowel, with haemorrhage, vascular thrombosis, and signs of necrotizing endovascularitis. Nine days post-operatively, the presence of intestinal contents in the drain was reported and surgical revision of the abdominal cavity was done. Intact anastomosis, but intestine necrosis because of local thrombosis was

found. The whole anastomosis was excised, and a double-tube ileostomy was performed. Another histological sample showed the small intestine with focal haemorrhagic infarction, severe inflammatory changes in serosa, and thrombosis of small vessels. The treatment included blood transfusion, anticoagulant (nadroparin calcium), corticosteroid (methylprednisolone), antibiotic (ceftriaxone sodium), antihypertensive drugs (angiotensin receptor blocker, beta blocker, calcium channel blocker, loop diuretic).

## DISCUSSION

SARS-CoV-2 infection is associated with a high incidence of thromboembolic complications<sup>3</sup>. The acute thromboinflammatory/immunothrombotic response following SARS-CoV-2 infection impairs the tissue microcirculation, causing injury initially to the lung that can cascade to other organs<sup>4</sup>. The inflammatory response, which occurs because of the lack of prior immunity, triggers the release of multiple cytokines that may produce a systemic inflammatory response syndrome, often described as a cytokine storm in COVID-19<sup>5</sup>. Cytokines, including tumour necrosis factor (TNF)- $\alpha$ , interleukin-6, and interleukin-8, are released<sup>6</sup>. The SARS-CoV-2 affinity for ACE2 and/or receptors in the vascular endothelium locally causes acute injury and activates local and then systemic inflammatory responses<sup>6-9</sup>, with loss of the protective anticoagulant endothelial and glycocalyx interface, further contributing to the microvascular thrombotic sequelae. As a result of acute endothelial cell injury, other critical procoagulant factors, including von Willebrand factor, are also released that further augment the hypercoagulable response<sup>9-11</sup>. Fibrinolytic shutdown (fibrinolysis inhibition) has been observed in COVID-19. It may be in part due to increased release of plasminogen activator inhibitor 1 (PAI-1), a finding that has been reported as a host defense response to infection, and increased PAI-1 and tissue plasminogen activator (tPA) level. Organ damage in some COVID-19 patients may be caused by severe systemic inflammation caused by upregulation of cellular and natural immunity. SARS-CoV-2 infection triggers the activation of T lymphocytes and the inflammatory signaling pathway, which results in the release of multiple proinflammatory cytokines, such as granulocyte-macrophage colony-stimulating factor (GM-CSF), interleukin (IL)-2, IL-6, IL-7, IL-10, and tumour necrosis factor- $\alpha$  (TNF- $\alpha$ )<sup>12</sup>. This cytokine cascade can eventually result in extensive cell damage, necrosis, and injury to multiple organs and may partially explain the different multisystem symptoms in patients with confirmed viral infections, including gastrointestinal necrosis<sup>12,13</sup>. The most common cause

of intestinal necrosis is acute mesenteric thrombosis, which could be a consequence of SARS-CoV-2 infection and triggered coagulopathy. COVID-19 may present with typical symptoms and complaints as a result of respiratory tract involvement, including fever, dry cough, dyspnoea, although in some patients other systems might be affected, such as the gastrointestinal tract. In these cases, the main symptoms are abdominal pain, nausea, vomiting, diarrhea, with peritonitis and shock because of acute mesenteric thrombosis. Microvascular thrombosis including mesenteric ischaemia is seen in less than 1% of cases. In patients with mesenteric ischaemia, the reported postoperative mortality is 23.8%, especially during the first 30 days<sup>14</sup>. Elevated D-dimer level  $\geq 0.5$  is an independent risk factor for mortality in COVID-19 patients<sup>16</sup>.

## CONCLUSIONS

The key mechanism of cellular and tissue injury in COVID-19 is dysregulation of the angiotensin signaling occurring because of SARS-CoV-2 binding to its cellular ACE2 receptor, which results in increased signaling by thrombin (proteinase-activated) receptors on platelet and endothelial cells, leading to coagulopathy and thrombosis<sup>15</sup>. In older patients presenting with abdominal pain, shock, and peritonitis, the most common underlying cause is mesenteric thrombosis which could be a result of coagulation disorders developed in COVID-19. Intestinal thrombosis in patients with SARS-CoV-2 infection increases the mortality rate<sup>14</sup>.

### Author contributions:

*The author was responsible for preoperative and postoperative cardiology consultation, concept, design and manuscript writing.*

### Compliance with Ethics Requirements:

*The author declares no conflict of interest regarding this article.*

*The author declares that all the procedures and experiments of this study are in full compliance of the ethical standards in the Helsinki Declaration of 1975, as revised in 2008, as well as the national law. Informed consent was obtained from the patient included in the study.*

*No funding was received for this study.*

### Acknowledgements

*None*

## REFERENCES

1. Jin X, Lian JS, Hu JH, et al. Epidemiological, clinical and virological characteristics of 74 cases of coronavirus-infected disease 2019 (COVID-19) with gastrointestinal symptoms. *Gut*. 2020;69(6):1002-9.
2. Lin L, Jiang X, Zhang Z, et al. Gastrointestinal symptoms of 95 cases with SARS-CoV-2 infection. *Gut*. 2020;69(6):321013.
3. Levy JH, Iba T, Olson LB, et al. COVID-19: Thrombosis, thromboinflammation, and anticoagulation considerations. *Int J Lab Hematol*. 2021;43 Suppl 1(Suppl 1):29-35.
4. Iba T, Levy JH, Levi M, Thachil J. Coagulopathy in COVID-19. *J Thromb Haemost*. 2020;18(9):2103-2109.
5. Del Valle DM, Kim-Schulze S, Huang HH, et al. An inflammatory cytokine signature predicts COVID-19 severity and survival. *Nat Med*. 2020;26(10):1636-1643.
6. Iba T, Connors JM, Levy JH. The coagulopathy, endotheliopathy, and vasculitis of COVID-19. *Inflamm Res*. 2020;69(12):1181-1189.
7. Connors JM, Levy JH. COVID-19 and its implications for thrombosis and anticoagulation. *Blood*. 2020;135(23):2033-2040.
8. Ranucci M, Ballotta A, Di Dedda U, et al. The procoagulant pattern of patients with COVID-19 acute respiratory distress syndrome. *J Thromb Haemost*. 2020;18(7):1747-1751.
9. Iba T, Levy JH, Connors JM, Warkentin TE, Thachil J, Levi M. The unique characteristics of COVID-19 coagulopathy. *Crit Care*. 2020;24(1):360.
10. Varga Z, Flammer AJ, Steiger P, et al. Endothelial cell infection and endothelitis in COVID-19. *Lancet*. 2020;395(10234):1417-1418.
11. Levy JH, Iba T, Connors JM. Vascular injury in acute infections and COVID-19: everything old is new again. *Trends Cardiovasc Med*. 2021;31(1):6-7.
12. Wan S, Yi Q, Fan S, et al. Characteristics of lymphocyte subsets and cytokines in peripheral blood of 123 hospitalized patients with 2019 novel coronavirus pneumonia (NCP). medRxiv. 2020. <https://doi.org/10.1101/2020.02.10.20021832>.
13. Li J, Fan J-G. Characteristics and mechanism of liver injury in 2019 coronavirus disease. *J Clin Transl Hepatol*. 2020;8(1):13-7.
14. Romero MDCVR, Morales Cárdenas A, Briseño Fuentes A, et al. Acute mesenteric arterial thrombosis in severe SARS-Co-2 patient: A case report and literature review. *Int J Surg Case Rep*. 2021; 86: 106307.
15. Sriram K, Paul A. Inselecorresponding. Inflammation and thrombosis in COVID-19 pathophysiology: proteinase-activated and purinergic receptors as drivers and candidate therapeutic targets. *Physiol Rev*. 2021; 101(2): 545-567.
16. Korkusuz R, Karandere F, Senoglu F, Kocoglu H, Yasar KK. The prognostic role of D-dimer in hospitalized COVID-19 patients. *Bratisl Lek Listy* 2021;122(11):811-815.