

CASE REPORT

CONTINUOUS HEMATOSPERMIA FOR 5 YEARS CAUSED BY COITUS RESERVATUS AS A METHOD OF CONTRACEPTION – A CASE REPORT

Petar A. ANTONOV¹, Atanas S. IVANOV^{1✉}, Pavel E. STANCHEV², Pencho P. GENOV³

¹ Department of Urology and General Medicine, Clinic of Urology, Medical University of Plovdiv, UMHAT „St. George”- Plovdiv, Bulgaria

² Department of Endocrinology, Clinic of Endocrinology and Metabolic Diseases, Medical University of Plovdiv, UMHAT „St. George”- Plovdiv, Bulgaria

³ Department of Urology, UMHAT Ruse, Bulgaria

Received July 25th, 2022, accepted August 17th, 2022

<https://doi.org/10.31688/ABMU.2022.57.3.10>

ABSTRACT

Introduction. The presence of blood in the semen is called haematospermia or haemospermia. The condition is always accompanied by patients' fear and anxiety and in most cases is intermittent and on short-term. In cases when haematospermia is continuing for long time or associates other symptoms it requires diagnostic evaluation for the numerous possible causes – inflammatory, neoplastic, iatrogenic and obstructive.

Case presentation. We present a case of coitus reservatus – an unpopular practice of sexual intercourse and a contraceptive method which is clinically manifested with haematospermia. A 38-year-old male patient, married, with one 6-year-old child, has been consulted for persistent haematospermia after each ejaculation in the last 5 years. The physical, laboratory and imaging examinations identified the cause of haematospermia as being coitus reservatus.

Conclusions. Haematospermia is a relatively rare and typically harmless condition, with a multifactorial aetiology. The presented case of coitus reservatus is an

RÉSUMÉ

Hématospermie continue pendant 5 ans causée par coït réservé en tant que méthode de contraception – rapport de cas

Introduction. La présence de sang dans le sperme est appelée hématospermie ou hémospérmie. La condition est toujours accompagnée de la peur et de l'anxiété des patients et, dans la plupart des cas, elle est intermittente et à court terme. Dans les cas où l'hématospermie se poursuit pendant une longue période de temps ou se combine avec d'autres symptômes, elle nécessite une évaluation diagnostique pour les nombreuses causes qui peuvent être présentes – inflammatoire, néoplasique, iatrogène et obstructive.

Rapport du cas. Nous présentons un cas de coït réservé – une pratique impopulaire des rapports sexuels et une méthode contraceptive qui se manifeste cliniquement par une hématospermie. Un homme de 38 ans, marié, père d'un enfant de 6 ans, a été consulté pour une hématospermie persistante après chaque

✉ Address for correspondence:

Atanas S. IVANOV
Department of urology and general medicine, Clinic of Urology, Medical University of Plovdiv, UMHAT „St. George”- Plovdiv, Bulgaria
Address: Blvd Peshtersko no 66 , 9th floor, Plovdiv 4000, Bulgaria
E-mail: atanasivanovmd@yahoo.com; Phone: +35 988 674 0407

unpopular practice of sexual intercourse and a contraceptive method which is clinically manifested with haemospermia.

Keywords: haemospermia, coitus reservatus, contraception

List of abbreviations:

PSA – prostate specific antigen

CRP – C-reactive protein

PCR – polymerase chain reaction

MRI – magnetic resonance imaging

INTRODUCTION

The cellular elements of the semen are represented by spermatozoa, epithelial cells of the genitourinary system, leukocytes, anigd immature germ cells. The presence of erythrocytes in the semen is called haemospermia or haemospermia¹. The condition is always accompanied by patients' fear and anxiety and in most cases is intermittent and on short-term. In cases when haemospermia is continuing for long time or combined with other symptoms it requires diagnostic evaluation for the numerous etiological factors – inflammatory, neoplastic, iatrogenic and obstructive².

CASE REPORT

A 38-year-old male patient, married, with one 6-year-old child, has been consulted for persistent haemospermia after each ejaculation in the last 5 years (Figure 1). The onset was sudden, there was no history of trauma or other urological or systemic disease. There were no disorders of the lower urinary tract, libido, and erectile function. The extensive physical examination (penis, testicles, and digital rectal examination of the prostate) and ultrasonography of the urinary and male reproductive systems were performed, which showed no pathological abnormalities. Repeated prostate-specific antigen (PSA) studies below 1 ng/mL and microbiological studies that showed no evidence of infection have been performed. However, antibiotic treatment with doxycycline and ciprofloxacin had been recommended twice by other urologist, without any improvement. Laboratory tests for haemostasis, biochemical parameters, C-reactive protein (CRP), urine exam, microbiological tests (conventional and polymerase chain reaction – PCR) were performed. All tests were negative or in the reference range, except for glucose (6.8 mmol/L), so the patient was consulted by an endocrinologist. Magnetic resonance imaging (MRI) of the pelvis with contrast enhancement did not reveal

éjaculation au cours des 5 dernières années. Tous les examens physiques, de laboratoire et d'imagerie effectués ont montré la cause de l'hématospermie: le coït réservé.

Conclusions. L'hématospermie est une affection relativement rare et généralement inoffensive d'étiologie multifactorielle. Le cas présenté de coït réservé est une pratique impopulaire de rapport sexuel et une méthode contraceptive qui se manifeste cliniquement par une hématospermie.

Mots-clés: hématospermie, coït réservé, contraception

any abnormalities (Figure 2). The patient was offered an endoscopic examination (cystoscopy), which he refused. During a further check-up, the patient was asked additional questions about the frequency and duration of sexual intercourse. The patient reported that he and his wife had regular sexual intercourse 2 to 4 times a week for about 20-30 minutes, practicing the so-called „coitus reservatus” for contraception. During sexual intercourse he does not ejaculate, and ejaculations take place every 15-20 days only through masturbation. The patient was instructed to discontinue „coitus reservatus” practice and ejaculate after each sexual intercourse. Over a period of 3 weeks, the intensity of haemospermia decreased, after which it stopped completely. During the 6-month follow-up period, the patient had no new episodes of haemospermia or other symptoms and the couple uses condoms as a method of contraception.

DISCUSSION

Haemospermia is a relatively rare entity in which blood is found in the semen. Because most episodes can go unnoticed, its frequency is unknown³. Historically, it was described by Hippocrates and Galen. Haemospermia always causes anxiety and fear⁴. Because in most cases it is episodic and self-limiting, urological evaluation is required in a small number of cases. Historically, haemospermia was linked to sexual behaviour, and patients were warned about excessive overindulgence, prolonged sexual abstinence and interrupted coitus⁵. It can occur at any age; the average age of patients with haemospermia is 37 years, with a period of manifestation from 1 to 24 months. While in the past up to 70% of cases were considered idiopathic, currently, due to the use of modern imaging methods, idiopathic cases are only about 15%. In the diagnostic algorithm, it is necessary to perform a thorough physical examination with an emphasis on the genital system and blood pressure monitoring.




Figure 1. Haematospermia after ejaculation

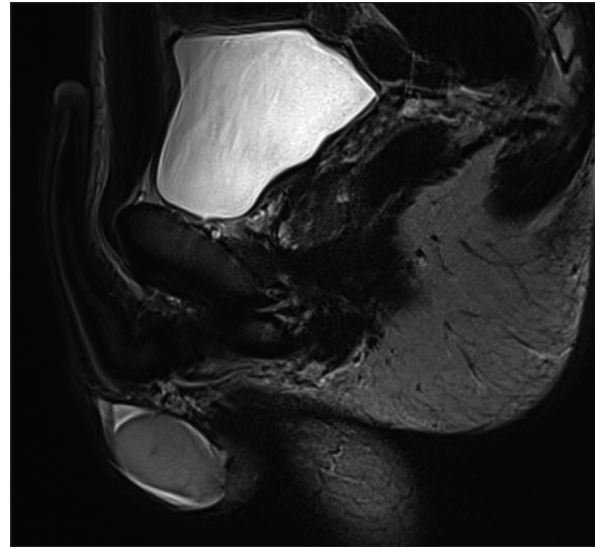


Figure 2. Pelvic MRI of the patient – normal data.

The diagnostic investigations include imaging (ultrasonography, computed tomography and MRI), microbiological (to detect urinary tract infections and sexually transmitted diseases), laboratory (haemostasis study) and instrumental (cystoscopy) methods⁶. The most common causes are inflammatory and infectious diseases of the male reproductive system, tumours and tumour-like diseases (carcinoma of the prostate, seminal vesicles and testicles, condyloma acuminatum, tumours of the spermatic cord), iatrogenic causes and injuries (after prostate biopsy, trauma of the perineum and pelvis), obstruction of the ejaculatory ducts (microlithiasis and dilatation) and cystic diseases (of the prostate), as well as systemic diseases (arterial hypertension, haematological diseases, arteriovenous malformations)⁷.

Contraceptive methods are widely used in family planning of births. Unlike female contraception, which is more common and includes a variety of options, effective methods of male contraception include vasectomy and condom use⁸. However, their use worldwide is limited to 9% of all contraceptive methods. Interrupted sexual intercourse („coitus interruptus”) is a common method in which a man takes an active part in contraception by ejaculating outside the woman’s vagina⁹. In contrast, „coitus reservatus” represents sexual intercourse that does not end with ejaculation, as the man tries to stay longer in the plateau phase of the human sexual response cycle. The method is described very briefly in the literature, mainly in the sexual practices of Daoist and the Oneida Community (founded in the 19th century and lasted about 25 years) and is considered uncertain about contraception¹⁰.

CONCLUSION

Haematospermia is a relatively rare and typically harmless condition with a multifactorial aetiology. The presented case of coitus reservatus is an unpopular practice of sexual intercourse and a contraceptive method which is clinically manifested with haematospermia.

Author Contributions

„A.I. and P.A. were responsible for consultations of patient. A.I. and P.S. analysed and interpreted the patient data. P.A. and P.G. performed the literature review. A.I. and P. A. were the major contributors for writing the manuscript. All authors read and approved the final manuscript.”

Compliance with Ethics Requirements:

„The authors declare no conflict of interest regarding this article”

„The authors declare that all the procedures and experiments of this study respect the ethical standards in the Helsinki Declaration of 1975, as revised in 2008(5), as well as the national law. Informed consent was obtained from the patient included in the study”

„No funding for this study”

Acknowledgements:

None

REFERENCES

1. Efesoy O, Çayan S, Akbay E. Novel algorithm for the management of hematospermia. *Turk J Urol.* 2020; doi: 10.5152/tud.2020.20428

2. Drury RH, King B, Herzog B, Hellstrom WJG. Hemospermia etiology, diagnosis, treatment, and sexual ramifications: a narrative review. *Sex Med Rev.* 2021; S2050-0521(21)00064-0.
3. Polito M, Giannubilo W, d'Anzeo G, Muzzonigro G. Hemospermia: diagnosis and treatment. *Arch Ital Urol Androl.* 2006;78(2):82-5.
4. Marshall VF, Fuller NL. Hemospermia. *J Urol.* 1983;129(2):377-8.
5. Mulhall JP, Albertsen PC. Hemospermia: diagnosis and management. *Urology* 1995; 46: 463-467.
6. Leocádio DE, Stein BS. Hemospermia: etiological and management considerations. *Int Urol Nephrol.* 2009;41(1):77-83.
7. Ahmad I, Krishna NS. Hemospermia. *J Urol.* 2007;177(5):1613-8.
8. Amory JK. Male contraception. *Fertil Steril.* 2016;106(6):1303-1309.
9. United Nations Department of Economic and Social Affairs, Population Division (2018). World Contraceptive Use 2018. Available at <https://www.un.org/en/development/desa/population/publications/dataset/contraception/wcu2018.asp> (accessed 02 July 2022)
10. Rocha LA. The way of sex: Joseph Needham and Jolan Chang. *Studies in History and Philosophy of Science Part C: Studies in History and Philosophy of Biological and Biomedical Sciences.* 2012; 43(3):611-626.