

RESEARCH ARTICLE

The Effect of Curcumin on Regression of Liver Fibrosis through Decreased Expression of Transforming Growth Factor- β 1 (TGF- β 1)

Supriono^{1,*}, Asri Nugraheni¹, Handono Kalim¹, Mudjiwijono Handaru Eko²

¹Department of Internal Medicine, Brawijaya University School of Medicine, Saiful Anwar Hospital, Jl. Veteran, Malang 65145, Indonesia

²Department of Anatomical Pathology, Brawijaya University School of Medicine, Saiful Anwar Hospital, Jl. Veteran, Malang 65145, Indonesia

*Corresponding author. E-mail: supriono_ipd.fk@ub.ac.id

Received date: May 15, 2018; Revised date: Sep 20, 2018; Accepted date: Sep 26, 2018

Abstract

BACKGROUND: Transforming growth factor (TGF)- β 1 has a pivotal role in liver fibrogenesis. Curcumin effectively prevent the progression of liver fibrosis through inhibition of TGF- β 1/Sma and drosophila MAD (Smad) signaling pathway. However, the role of curcumin in the regression of liver fibrosis is still unknown. This study investigated the role of curcumin and TGF- β 1 in liver fibrosis regression.

METHODS: An experimental Wistar rat model included 6 treatment groups as well as positive and negative control groups. The treatment and positive control groups were injected with carbon tetrachlorid (CCl₄) for 9 weeks to induce liver fibrosis. After cessation of injection, 3 of the treatment groups were given curcumin and 3 were given carboxymethylcellulose (CMC) for 2, 5 and 9 weeks, while the positive control was untreated. The negative control was injected with normal saline. TGF- β 1 liver tissue levels were analyzed by ELISA, while the TGF- β 1 expression in

liver cells was analyzed by immunohistochemical assay. The metavir score was used to assess the degree of liver fibrosis. Values of $p < 0.05$ were regarded as statistically significant.

RESULTS: Nine weeks of CCl₄ injection induced liver fibrosis (metavir F3); and significantly increased TGF- β 1 levels and expression in tissues ($p = 0.00$, $p = 0.021$, respectively). Curcumin administration decreased levels and expression of TGF- β 1 in the liver and accelerated regression of liver fibrosis. There was a significant correlation between duration of administration of curcumin with an expression of TGF- β 1 in the liver tissue ($r = 0.87$; $p < 0.00$).

CONCLUSION: Curcumin accelerates regression of liver fibrosis, likely through decreasing of TGF- β 1 expression in the liver.

KEYWORDS: curcumin, TGF- β 1, liver fibrosis regression, CCl₄, animal model

Indones Biomed J. 2019; 11(1): 52-8

Introduction

Regardless of the etiology, there is clinical evidence that the liver fibrosis may regress when its etiology is removed. (1) Inhibition of transforming growth factor (TGF)- β signaling by administering an anti-TGF- β agent is one of the strategies in liver fibrosis treatment. (2) However, the role of TGF- β in the regression of liver fibrosis when its etiology is removed is still not widely known. TGF- β has a

pivotal role in the process of liver fibrogenesis, from acute inflammation of the liver to chronic liver disease, through modulation of the inflammatory process. TGF- β is also involved in the process of liver carcinogenesis. (3,4) In liver fibrogenesis, TGF- β triggers the trans-differentiation of hepatic stellate cells (HSCs) to myofibroblast-like cells and thus mediates progression of liver fibrosis. Activation of the TGF- β 1 pathway by interleukin (IL)-6/signal transducer and activator of transcription (Stat)3 inhibits HSC apoptosis, increases HSC activation and aggravates fibrosis. (5)

Curcumin has been extensively studied as an anti-fibrosis agent. Curcumin inhibited liver fibrosis and blocked HSC activation *in vitro* and *in vivo*.(6) The mechanism of curcumin as an anti-fibrosis agent associated with TGF- β has also been widely studied. Curcumin may be an effective anti-fibrotic drug in the prevention of liver disease progression; curcumin significantly attenuated the severity of carbon tetrachlorid (CCl₄)-induced liver inflammation and fibrosis through inhibition of the TGF- β 1/Sma and drosophila MAD (Smad) signaling pathway.(7,8) In acute liver injury, curcumin may protect against oxidative stress and inflammation by inhibition of TGF- β 1/Smad3 pathways.(9) However, the roles of curcumin and TGF- β in the regression of liver fibrosis are still unknown. We have therefore evaluated the ability of curcumin to cure CCl₄-induced liver fibrosis in animal models and investigated the level and expression of TGF- β 1 in this model.

Methods

Animal

This study was an *in vivo* experimental study using rats (*Rattus norvegicus*, Wistar strain) with a post-test control group and complete randomized design. The inclusion criteria of the animal subjects were male, 150-250 g body weight, and in healthy condition. All experimental procedures were approved by the institutional and local committee on the care and use of animals of Brawijaya University School of Medicine, Malang, East Java, Indonesia (No. 76/EC/KEPK/03/2016).

Development of Liver Fibrosis Models

There were 8 groups in total, including 6 groups as treatment groups and 2 groups as controls. The treatment groups include the treatment of curcumin (Tc) and treatment of carboxymethylcellulose (CMC) as vehicle (Tv). The control groups include negative control (C-) and positive control (C+). Each group consisted of 4 rats. The treatment groups and C+ were injected intraperitoneally 2 times/week with CCl₄ 10% (CCl₄ dissolved in corn oil with a ratio of 1: 9), 1 cc/kgBW for 9 weeks to induce liver fibrosis. The C- received a normal saline injection, 1 cc/kgBW, twice/week for 9 weeks (see flowchart in Figure 1). Both of controls were untreated after the initial 9-week injection cycle. A metavir score was used to assess the level of liver fibrosis. The C- and C+ groups were sacrificed within 72 hours after the cessation of injection.

Curcumin Treatment in Liver Fibrosis Models

After cessation of CCl₄ injection, three groups were given curcumin 94% purity (#820354.0010, MERCK, Schuchardt, Germany), for 2 weeks (Tc2), 5 weeks (Tc5) and 9 weeks (Tc9). The dose of curcumin was 200 mg/kgBW/day, by sonde. Three groups (the CMC groups) were given just the solvent, CMC 1% by sonde, for 2 weeks (Tv2), 5 weeks (Tv5) and 9 (Tv9) weeks. All animal models in the treatment groups were sacrificed after 72 hours of curcumin or CMC administration.

Histological Examination

Liver specimens were preserved in 10% neutral buffered formalin solution for 24 hours and washed with 70% ethanol.

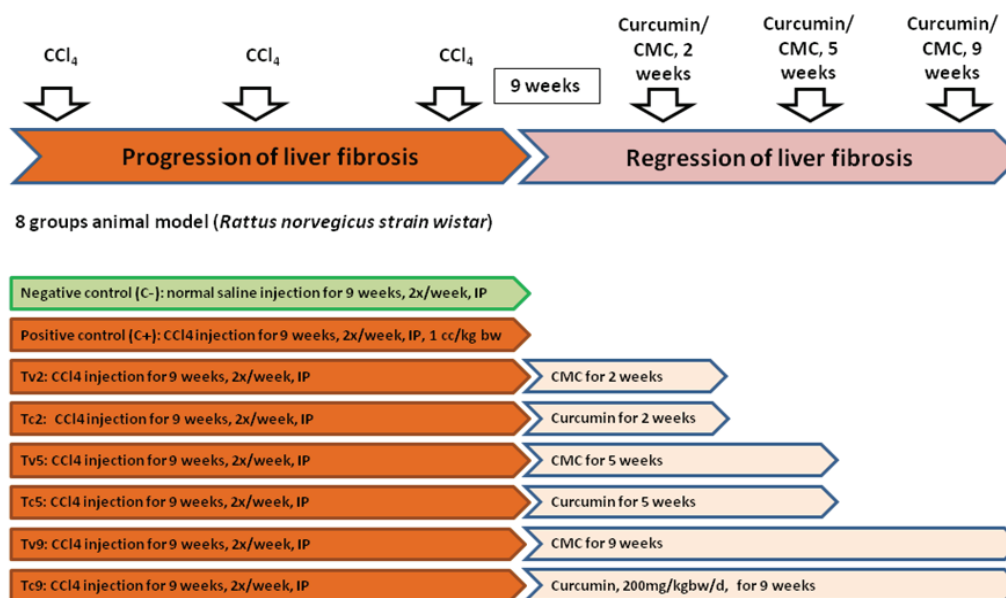


Figure 1. Flowchart of study and research methods. CCl₄: carbon tetrachlorid; CMC: carboxymethylcellulose; IP: intraperitoneal.

Tissues were then placed in small metal caskets, stirred by a magnetic stirrer, dehydrated using an alcohol series from 70% to 100% alcohol, and embedded in paraffin using an embedding machine. Paraffin blocks were sectioned using a rotary ultramicrotome, distributed onto glass slides and then dried overnight. Slides were observed under a light microscope after being stained with hematoxylin and eosin (H&E).

Enzyme-linked Immunosorbent Assay (ELISA)

The analysis of level TGF- β 1 in liver tissue was measured by using an ELISA kit (Biolegend, San Diego, USA) according to the manufacturer instructions. Briefly, liver extracts were prepared by homogenizing 200 mg liver tissue in 2 mL of buffer phosphate 0.1 M pH 7.0 and 500 μ L of trichloroacetic acid (TCA) 10% using micropestle dan homogenizer. The supernatants were collected after centrifugation at 10000 rpm for 10 minutes at 4°C and used for TGF- β 1 ELISA. The concentration in each sample well was determined by interpolation from a standard curve. The analysis of TGF- β 1 level was conducted at the Physiology Laboratory of Brawijaya University School of Medicine.

Immunohistochemistry

The analysis of TGF- β 1 expression in liver tissue was measured by immunohistochemical kits Anti TGF- β 1 (No. BS series 0086R, Elabscience, Singapore, Singapore) and Secondary Antibodies (ScyTek, Utah, USA). The hot spot method was used to calculate the expression of TGF- β 1 in all brown-colored liver cells. The picture was taken using the 40x objective. Ten shots were taken on each slide, then the average of the brown colored liver cells per slide was calculated to obtain a measure of the expression of TGF- β 1 in the liver tissue. The expression measurements of TGF- β 1 in liver tissue were performed in Pathology Anatomy Laboratory of Brawijaya University School of Medicine.

Statistical Analysis

The data were analyzed using a statistical analysis program, IBM Statistical Products and Service Solutions (SPSS) Statistics, version 22.0 for Windows. A 95% confidence interval ($\alpha=0.05$) was used as a decision threshold for significance. If the distribution and variant data were normally distributed with homogenous variability, the data were analyzed using statistical parametric analysis using one-way ANOVA; a Tukey Test for post-hoc multiple comparisons was used to calculate the differences between groups. Non-parametric analyses, namely the Kruskal-Wallis and Mann-Whitney tests, were used when the data

did not fulfill the assumptions of normal distribution and homogenous variability. A Pearson Correlation test was done to the relationship between duration treatment and levels of TGF- β 1. Differences between two variables were calculated with an independent T-test or Mann-Whitney test.

Results

The mean body weight of rats at the beginning of the study was 181.56 \pm 15.46 g, while the mean body weight of rats at the end of the study was 229.87 \pm 35.06 g. The average increase in body weight was 48.31 \pm 23.91 grams (data not shown).

The degree of liver fibrosis was measured using metavir score. Figure 2 shows the H&E staining results, whereas Figure 3 shows the median metavir scores for each treatment. As seen in Figure 3, the injection of 1 cc/kgBW CCl₄ intraperitoneally twice a week for 9 weeks (see e.g., group C+) produced stage F-3 of liver fibrosis (portal-central septae fibrosis). The negative control group, which received an injection of NaCl twice a week for 9 weeks (C-) had an F-0 score for liver fibrosis. The degree of liver fibrosis in curcumin groups was less than the CMC groups for 2, 5 and 9 weeks, although not statistically significant. When compared to C+ and Tc9, there was a significant difference ($p=0.001$).

The level of TGF- β 1 in liver tissue in the C+ group was significantly higher than C- ($p=0.000$). Based on the duration of curcumin administration, the level of TGF- β 1 in liver tissue also decreased significantly for 2 weeks administration ($p=0.021$), but the TGF- β 1 level then significantly increased in week 5 and stabilized in week 9 (Figure 4A). The same pattern also occurred in the groups that were given CMC.

The treatment groups were administered curcumin had lower levels of TGF- β 1 in liver tissue than the control groups that were given CMC. When compared over time separately (week 2, week 5 and week 9), the level of liver tissue of TGF- β 1 in groups given curcumin was significantly lower than that those given CMC, $p=0.041$, $p=0.000$ and $p=0.008$, respectively (data not shown).

As seen in Figure 4B, the expression of TGF- β 1 in C+ was significantly higher than C-. Administration of curcumin significantly decreased the TGF- β 1 expression, especially in Tc2 ($p=0.021$) and Tc5 ($p=0.020$). Figure 5 shows an example photograph of immunohistochemical staining of TGF- β 1 expression in the liver tissue.

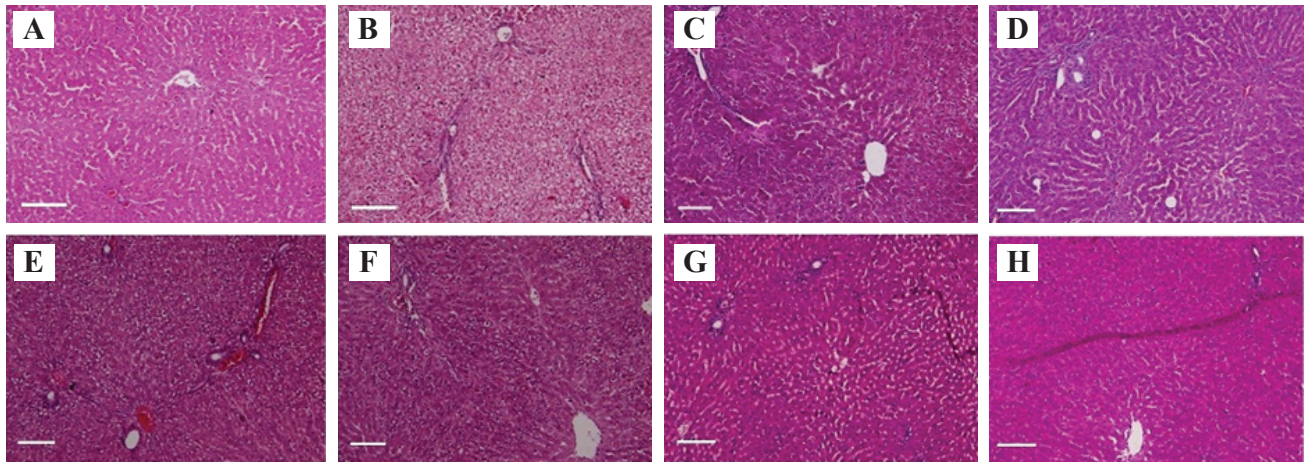


Figure 2. Photomicrographs of liver tissues of rats (H&E staining). A: C-, treated with normal saline; B: C+, treated with CCl₄; C: Tv2, treated with CCl₄ + vehicle 2 weeks; D: Tc2, treated with CCl₄ + curcumin 2 weeks; E: Tv5, treated with CCl₄ + vehicle 5 weeks; F: Tc5, treated with CCl₄ + curcumin 5 weeks; G: Tv9, treated with CCl₄ + vehicle 9 weeks; H: Tc9, treated with CCl₄ + Curcumin 9 weeks. White bar: 10 μm. C-: negative control; C+: positive control; Tc: curcumin treatment group; Tv: carboxymethylcellulose treatment group.

Interestingly, the expression of TGF-β1 in Tc2 had a similar level with the expression of TGF-β1 in C-. This means that the administration of curcumin for 2 weeks can restore the degree of fibrosis as well as the condition in the negative group (normal condition). Thereafter, the expression of TGF-β1 in curcumin groups gradually increased over time. Interestingly, the expression of TGF-β1 in Tc9 was still significantly lower than the expression of TGF-β1 in C+ ($p=0.02$).

As also seen in Figure 4B, the expression of TGF-β1 in groups given CMC increased at week 2 (Tv2), week 5 (Tv5) and declined at week 9 (Tv9). The expression of TGF-β1 at week 9 (Tv9) was almost the same as the expression of TGF-β1 in Tc9 ($p=0.703$). Based on the treatment, the expression of TGF-β1 in the curcumin groups was significantly decreased compared to the CMC groups,

especially in week 2 and week 5 ($p=0.021$ and $p=0.020$, respectively).

In the correlation analysis, there was a significant correlation between duration of administration of curcumin with an expression of TGF-β1 in the liver tissue, $r=0.865$; $p=0.000$ (Figure 6). This means there is an increase in expression of TGF-β1 along with the duration of curcumin administration. Whereas there was no correlation between duration administration of curcumin and decrease of TGF-β1 in liver tissue (data not shown).

Discussion

This study may be the first research that explores the role of curcumin as a curative therapy for liver fibrosis, in which

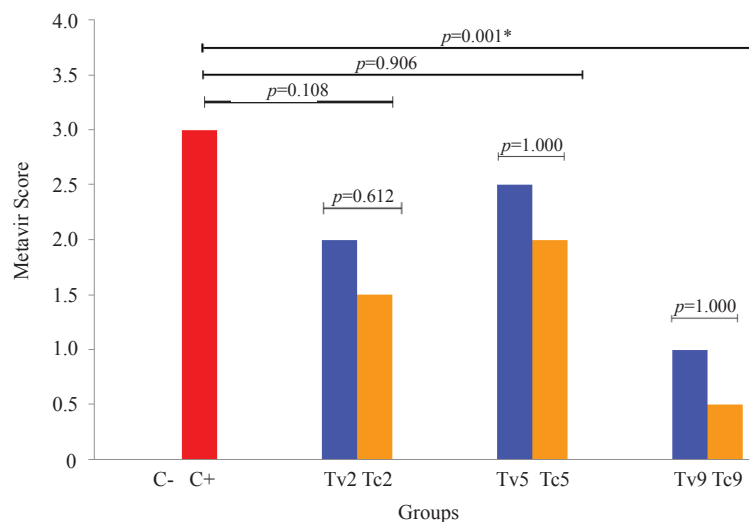


Figure 3. Degree of fibrosis based on metavir score (data presented in median). C-: negative control; C+: positive control; Tc: curcumin treatment group; Tv: carboxymethylcellulose treatment group.

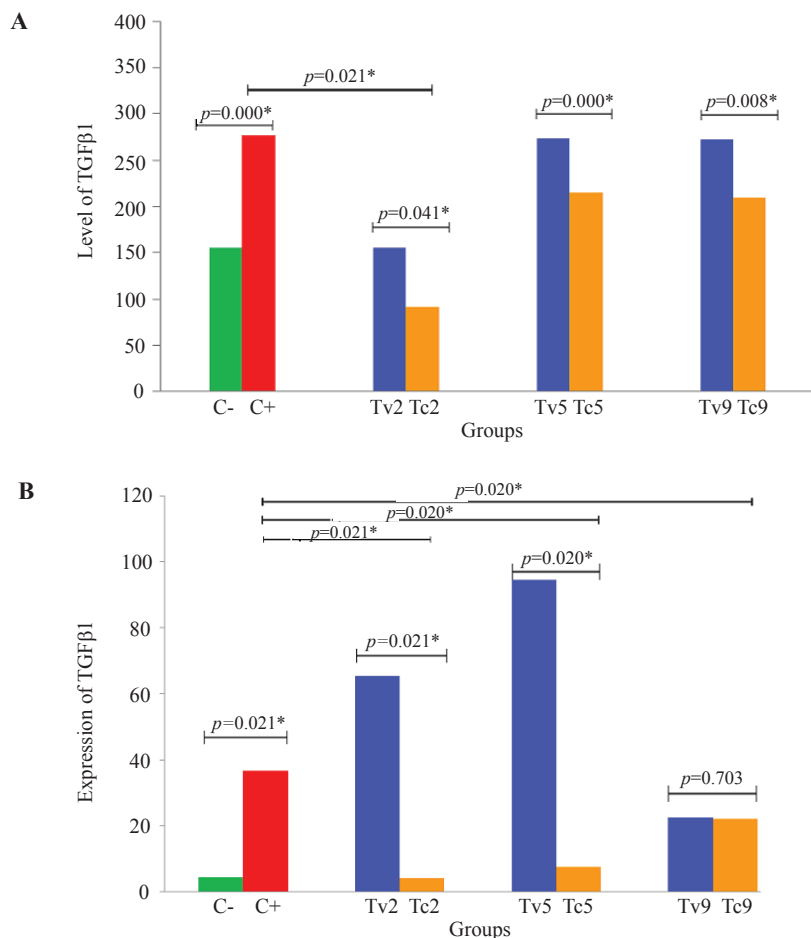


Figure 4. The level (A) and expression (B) of TGF-β1 in the liver tissue. TGF: Transforming growth factor; C-: negative control; C+: positive control; Tc: curcumin treatment group; Tv: carboxymethylcellulose treatment group.

curcumin was given in rat with liver fibrosis conditions after its etiology has been removed.

The CCl₄ liver fibrosis model is the toxic model of liver fibrosis induction most commonly used worldwide. The mechanism of CCl₄-induced liver fibrosis has been studied and the best administration route is the application via CCl₄ intraperitoneal injection.(10,11) The duration of 9 weeks of CCl₄ administration was determined as sufficient in a preliminary study. In our study, CCl₄ injection for 9 weeks, 2 times/week, intraperitoneally produced an F-3 stage of liver fibrosis (metavir score).

HSCs and TGF-β1 have a central role in liver fibrogenesis. TGF-β1 is a key member of the TGF-β superfamily, playing a critical role in the development of liver fibrosis, while HSC activation and trans-differentiation into myofibroblasts are believed to be the key events in liver fibrogenesis. TGF-β1 participates in every step of HSC activation. TGF-β1 triggers phenotypical trans-differentiation of HSCs from quiescence HSC to activated HSC (myofibroblast-like cells) by paracrine and autocrine action. Stat3 activation modulates connective tissue growth factor (CTGF) production upon TGF-β1 challenge in activated HSCs.(5,12)

High levels of TGF-β as a consequence of chronic liver damage also lead to massive hepatocyte cell death, which contributes to the promotion of the development of NASH, liver fibrosis and hepatocellular carcinoma.(4,13,14) Induction of CCl₄ through intraperitoneal injection for 9 weeks causes a chronic inflammatory process and results in

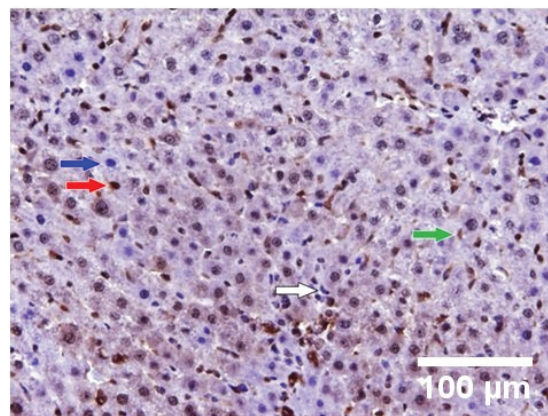


Figure 5. Immunohistochemical staining results in C+. Blue arrow: normal hepatocyte; Red arrow: expression of TGFβ-1 in hepatocyte; White arrow: normal hepatic stellate cell; Green arrow: expression of TGFβ-1 in hepatic stellate cell; White bar: 100 μm.

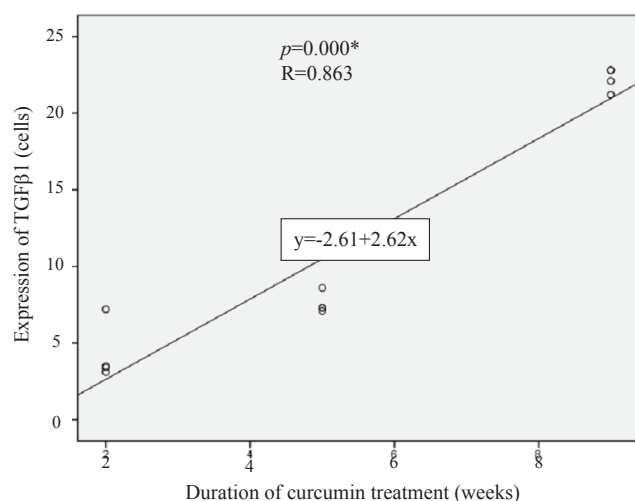


Figure 6. The correlation of duration curcumin administration with the expression of TGF-β1 in liver tissue.

liver fibrosis. In our study, there was a significant increase of TGF-β1 expression in liver tissue after 9 weeks of CCl₄ intraperitoneal injection (Figure 4B). This helps to explain how important the role of TGF-β1 is in the process of liver fibrogenesis.

HSCs have a critical role in the pathogenesis of liver fibrosis, therefore inhibition of HSC activation and induction of HSC apoptosis has become potentially important for the prevention or treatment of liver fibrosis. It has been suggested that curcumin may be safely used to treat liver fibrosis by several different mechanisms. Curcumin not only inhibits HSC proliferation and transformation of HSC to an activated phenotype, but curcumin also induces apoptosis of HSC. Apoptosis of HSC will reduce secretion of type I collagen and production of TGF-β.(15,16) In our study, after the injection of CCl₄ for 9 weeks resulted in a stage F3 degree of liver fibrosis, curcumin administration accelerated regression of liver fibrosis for all lengths of administration. Interestingly, at 9 weeks of administration, the curcumin appeared to decrease the degree of liver fibrosis significantly (Figure 3).

We have shown here that treatment with curcumin significantly decreased of level of expression of TGF-β1 in the liver tissue, especially in week 2 (Figure 4B). The expression of TGF-β1 in liver tissue at week 2 (Tc2) was significantly decreased, approaching the expression of TGF-β1 basal (C-) although increasing again in the Tc5 and Tc9 groups.

Thus, curcumin appears to reduce expression of TGF-β1 optimally in liver tissue after administration for 2 weeks. Decreases of TGF-β1 levels were correlated to the reduction of liver fibrosis degree in week 2. The degree of

liver fibrosis in the second week after the administration of curcumin was metavir score F1.5 (Figure 3). Likely, curcumin's significant attenuation of the severity of CCl₄-induced liver inflammation and fibrosis was through inhibition of TGF-β1/Smad signaling pathway and CTGF expression.(7, 12)

As noted above, the administration of curcumin increased the expression of TGF-β1 gradually at 5 and 9 weeks, but was still significantly lower than without curcumin administration (CMC groups) in the week 5 and became the same in week 9 (Figure 4B). Suppression of TGF-β1 by curcumin during that time period was used to accelerate the regression of liver fibrosis. The results correlated with the degree of liver fibrosis in this study, where the degree of liver fibrosis in the curcumin group was lower than without curcumin administration (Figure 3).

It is interesting that in the CMC groups there was also an increase of TGF-β1 expression. The increase was seen in week 2 and reached a peak in week 5 and decreased in week 9. It is suspected that the increase of TGF-β1 was needed for the regeneration process in the resolution of liver fibrosis. During the course of chronic liver disease progression, various phases occur, such as initiation, regeneration, perpetuation, fibrogenesis, tumorigenesis, and metastasis. Depending on the specific disease stage, TGF-β may have beneficial outcomes, especially in the initiation and regeneration phases.(17)

In the initiation phase of response to liver injury, TGF-β enhances hepatocyte damage and induce HSC activation to mediate liver tissue wound healing. This initial phase can heal the damaged liver tissue when the inflammatory process is not continuous and prolonged. In the regeneration phase, there is a proliferation of hepatocytes, which is also controlled by TGF-β.(17) TGF-β signaling that controls the proliferation of hepatocyte is particularly mediated through β2-Spectrin (β2SP). The spatial expansion of β2SP may activate hepatic progenitor cells that regulate hepatocyte proliferation.(18)

There was a significant correlation between the duration of curcumin administration and the expression of TGF-β1 in the liver tissue (Figure 6), but not in line with our prior expectations. Our expectations were that long-term curcumin administration may further lower the levels of TGF-β1. However, long-term curcumin administration resulted in a higher level of TGF-β1 expression. The optimal TGF-β1 expression reduction was achieved at week 2 of curcumin administration. Further research is needed to elucidate these results.

Conclusion

As a curative treatment, curcumin may accelerate regression of liver fibrosis may through the decrease of TGF- β 1. Further research is needed to explain these mechanisms in more detail.

References

1. Ellis EL, Mann DA. Clinical evidence for the regression of liver fibrosis. *J Hepatol.* 2012; 56: 1171-80.
2. Breitkopf K, Haas S, Wiercinska E, Singer MV, Dooley S. Anti-TGF-beta strategies for the treatment of chronic liver disease. *Alcohol Clin Exp Res.* 2005; 29: 121S-31S.
3. Yoshida K, Murata M, Yamaguchi T, Matsuzaki K. TGF- β /Smad signaling during hepatic fibro-carcinogenesis. *Int J Oncol.* 2014; 45: 1363-71.
4. Fabregat I, Moreno-Caceres J, Sanchez A, Dooley S, Dewidar B, Giannelli G, *et al.* TGF- β signaling and liver disease. *FEBS J.* 2016; 283: 2219-32.
5. Xu MY, Hu JJ, Shen J, Wang ML, Zhang QQ, Qu Y, *et al.* Stat3 signaling activation crosslinking of TGF- β 1 in hepatic stellate cell exacerbates liver injury and fibrosis. *Biochim Biophys Acta.* 2014; 1842: 2237-45.
6. Wu P, Huang R, Xiong YL, Wu C. Protective effects of curcumin against liver fibrosis through modulating DNA methylation. *Chin J Nat Med.* 2016; 14: 255-64.
7. Yao QY, Xu BL, Wang JY, Liu HC, Zhang SC, Tu CT. Inhibition by curcumin of multiple sites of the transforming growth factor-beta1 signaling pathway ameliorates the progression of liver fibrosis induced by carbon tetrachloride in rats. *BMC Complement Altern Med.* 2012; 12: 156. doi: 10.1186/1472-6882-12-156.
8. Chen N, Geng Q, Zheng J, He S, Huo X, Sun X. Suppression of the TGF- β /Smad signaling pathway and inhibition of hepatic stellate cell proliferation play a role in the hepatoprotective effects of curcumin against alcohol-induced hepatic fibrosis. *Int J Mol Med.* 2014; 34: 1110-6.
9. Peng X, Dai C, Liu Q, Li J, Qiu J. Curcumin attenuates on carbon tetrachloride-induced acute liver injury in mice via modulation of the Nrf2/HO-1 and TGF- β 1/Smad3 pathway. *Molecules.* 2018; 23: E215. doi: 10.3390/molecules23010215.
10. Boll M, Weber LWD, Becker E, Stampfl A. Mechanism of carbon tetrachloride-induced hepatotoxicity. Hepatocellular damage by reactive carbon tetrachloride metabolites. *Z Naturforsch C.* 2001; 56: 649-59.
11. Scholten D, Trebicka J, Liedtke C, Weiskirchen R. The carbon tetrachloride model in mice. *Lab Anim.* 2015; 49: 4-11.
12. Liu Y, Liu H, Meyer C, Li J, Nadalin S, Koenigsrainer A, *et al.* TGF- β mediated connective tissue growth factor (CTGF) expression in hepatic stellate cells requires Stat3 activation. *J Biol Chem.* 2013; 288: 30708-19.
13. Yang L, Roh YS, Song J, Zhang B, Liu C, Loomba R, *et al.* Transforming growth factor beta signaling in hepatocytes participates in steatohepatitis through regulation of cell death and lipid metabolism in mice. *Hepatology.* 2014; 59: 483-95.
14. Yang L, Inokuchi S, Roh YS, Song J, Loomba R, Park EJ, Seki E. Transforming growth factor- β signaling in hepatocytes promotes hepatic fibrosis and carcinogenesis in mice with hepatocyte-specific deletion of TAK1. *Gastroenterology.* 2013; 144: 1042-54.e4.
15. Kang HC, Nan JX, Park PH, Kim JY, Lee SH, Woo SW, *et al.* Curcumin inhibits collagen synthesis and hepatic stellate cell activation in-vivo and in-vitro. *J Pharm Pharmacol.* 2002; 54: 119-26.
16. Shu JC, He YJ, Lv X, Zhao JR, Zhao J, Shen Y, *et al.* Effect of curcumin on the proliferation and apoptosis of hepatic stellate cells. *Braz J Med Biol Res.* 2009; 42: 1173-8.
17. Dooley S, ten Dijke P. TGF- β in the progression of liver disease. *Cell Tissue Res.* 2012; 347: 245-56.
18. Thenappan A, Li Y, Kitisin K, Rashid A, Shetty K, Johnson L, *et al.* Role of transforming growth factor β signaling and expansion of progenitor cells in regenerating liver. *Hepatology.* 2010; 51: 1373-82.