

Relationship between maxillary sinus volume and nasal septal deviation concha bullosa and infundibulum size using cone-beam computed tomography (CBCT)

Azadeh Zakariaee Jubari^{1✉}, Azadeh Torkzadeh^{2*}

1. Postgraduate Student, Department of Oral And Maxillofacial Radiology, School of Dentistry, Isfahan (Khorasgan) Branch, Islamic Azad University, Isfahan, Iran.

2. Assistant Professor, Department of Oral And Maxillofacial Radiology, School of Dentistry, Isfahan (Khorasgan) Branch, Islamic Azad University, Isfahan, Iran.

Article Type

ABSTRACT

Research Paper

Introduction: The maxillary sinuses are the largest paranasal sinuses adjacent to the teeth. Due to anatomical variations in different people, knowledge of these variations is essential for rhinoplasty and sinusitis. The aim of the present study was to determine the relationship between maxillary sinus volume with nasal septal deviation, concha bullosa and infundibulum size using cone-beam computed tomography (CBCT).

Materials & Methods: In this descriptive -analytical study, CBCT images of 135 patients who underwent maxillofacial imaging were evaluated. In order to measure the volume of maxillary sinuses, CBCT images of axial sections were used with a thickness of 2 mm and Digimizer image analysis software. In the coronary section of nasal septum deviation, types of concha bullosa and infundibulum size were determined. Data were analyzed using one-way ANOVA, paired t-test, Pearson correlation test and regression. A value of $P < 0.05$ was considered significant.

Results: There was a significant inverse relationship between the mean of volume of the right sinus ($p = 0.012$, $r = -0.216$) and left sinus ($p < 0.001$, $r = -0.303$) with the deviation of the nasal septum. A significant inverse relationship was found between the mean volume of right maxillary sinus ($p < 0.012$, $r = -0.357$) and left maxillary sinus ($p = 0.006$, $r = -0.357$) with infundibulum size. The mean volume of right sinuses and left sinuses from coronal view was not significantly different in the presence or absence of concha bullosa. There was no significant difference between male and female in the mean volume of the right and left sinuses.

Conclusion: The present findings suggest that maxillary sinus volume is smaller the deviation in moderate and severe septal deviation cases and that the maxillary and with increasing size of infandibulum, the volume of maxillary sinus was larger.

Keywords: Maxillary Sinus, Cone-Beam Computed Tomography, Patients, Maxilla

Received: 12 Sept 2021

Revised: 22 Nov 2021

Accepted: 26 Mar 2022

Cite this article: Zakariaee Jubari A, Torkzadeh A. Relationship between maxillary sinus volume and nasal septal deviation concha bullosa and infundibulum size using cone-beam computed tomography (CBCT). *Caspian J Dent Res* 2022; 11 (1): 56-63.



© The Author(s).

Publisher: Babol University of Medical Sciences

* **Corresponding Author:** Azadeh Torkzadeh, School of Dentistry, Isfahan (Khorasgan) Branch, Islamic Azad University, Isfahan, Iran.

Tel: +989112298040

E-mail: azadehh.torkzadeh@gmail.com

Introduction

Maxillary sinuses are the largest paranasal sinuses adjacent to the teeth. Some paranasal sinuses develop in the late embryonic period, such as the maxillary sinus, and some develop after birth. Although many developmental changes occur during the embryonic and fetal periods, and often during the third to eighth week of development, some important changes occur in the postpartum period, and most evolutionary changes are completed by the age of 25. [1] The average volume of an adult maxillary sinus is approximately 15 ml, but the sinuses change continuously throughout life. [2] According to the studies, some factors can affect the volume of the maxillary sinus. The maxillary sinus has a special place in dentistry due to its proximity to the tooth and the surrounding structures. [3]

The nasal septum is an essential component in the development of the nose and paranasal sinuses, and nasal septal deviation is one of the most common disorders in humans [4] in which the nasal septum deviates to the right or left. [5] The prevalence of nasal deviation is determined by genetics as well as environmental and cultural factors [6] and its causes are trauma, nasal polyps, neoplasia, infection and genetics. [5] Deviation of the nasal septum increases the likelihood of nasal obstruction and can affect vocal pronunciation, beauty and respiration. Moreover, it can cause sinusitis as well as upper airway and middle ear infections. [7, 8]

Concha is present all around the nasal cavity. Trauma, nasal septal deviation and oral respiration are known to predispose to concha bullosa and are possible etiologic factors in recurrent chronic sinusitis. [9] The infundibulum is the junction between the bony canal and lumen connecting the maxillary sinus ostium and hiatus semilunaris. [10, 11]

Al-Rawi et al. [12] evaluated the effects of concha bullosa and nasal septal deviation on maxillary sinus volume and found that although nasal deviation and concha bullosa were present in more than two-thirds and more than one-third of the samples, respectively, only concha bullosa had a significant effect on maxillary sinus volume. In the study of Kucybała et al. [13], the effects of nasopharyngeal deviation and concha bullosa on maxillary sinus volume and the prevalence of maxillary sinusitis were investigated, and they concluded that there was a relationship between the presence of concha bullosa and the direction of nasal septal deviation, but only concha bullosa affected maxillary sinus volume.

Sugono et al. [14] suggested that the increase in infundibulum size was significantly associated with the increase in maxillary sinusitis.

Given the anatomical variations and the possibility of involvement of this structure in fractures and pathologies, considering the development of the use of CBCT in diagnostic dentistry and the differentiation and management of the observed findings for maxillofacial radiologists and considering the fact that these anatomical variations occur in different forms, the aim of the present study was to determine the relationship between maxillary sinus volume with nasal septal deviation, concha bullosa and infundibulum size using CBCT scans.

Materials & Methods

This study was approved by the Ethics Committee of Islamic Azad University, Isfahan (Khorasgan) Branch (IR.IAU.KHUISF.REC.1400.037). In this descriptive-analytical study, CBCT images of 135 patients who underwent maxillofacial imaging for an implant (65 males and 70 females) aged 18 years and older, referred to the department of radiology, Islamic Azad University, Isfahan (Khorasgan) Branch in 2020-2021 were evaluated, and all patients had posterior teeth. The sample size was determined based on the following formula

$$\left(\frac{1.96+0.84}{\sqrt{\frac{1}{2} \cdot 10g \cdot \frac{1.25}{0.75}}} \right)^2 + 3 \cong 123$$

$$Z_{\alpha} = 1.96$$

$$Z_{\beta} = 0.84$$

$$\gamma = 0.25$$

In the images, the radiation field in the upper jaw, which includes the maxillary sinus and nasal cavities, was used.

CBCT images of the patients were obtained using a Galileos device (Sirona, Germany, Bensheim) with exposure conditions of 85 kV and 2.5 to 7 mA (depending on the age and size of the patient). In the preparation of the images, a radiation field was used in maxilla, which includes the areas of maxillary sinus and nasal cavity.

The multiplanar reconstructed images (axial, sagittal and coronal sections) were examined using OnDemand3d Dental software (cybermed, Seoul, Korea). First, the sagittal plane was vertically adjusted and the position of the patient's head was corrected in a computer program, then the necessary measurements were performed.

Measurements were performed on both the right and left sides of the patient, and all measurements were done under the supervision of an oral and maxillofacial radiologist.

To measure the maxillary sinus volume, axial CBCT sections with 2mm slice thickness and 2mm intervals were used. The CBCT sections were subjected to Digimizer software version 5.4.7 (MedCalc software Ltd., Brussels, Belgium) and the surface area of the sinus was automatically measured and stored in Excel format. The surface area of all sections of the sinus (about 20 to 25 sections) in both sides was calculated for each patient. Then, to calculate the volume of the sinus in cubic centimeters, the following formula was used: Sum of the surface area of the sinus in each section \times thickness of each section (Figure 1). [15]

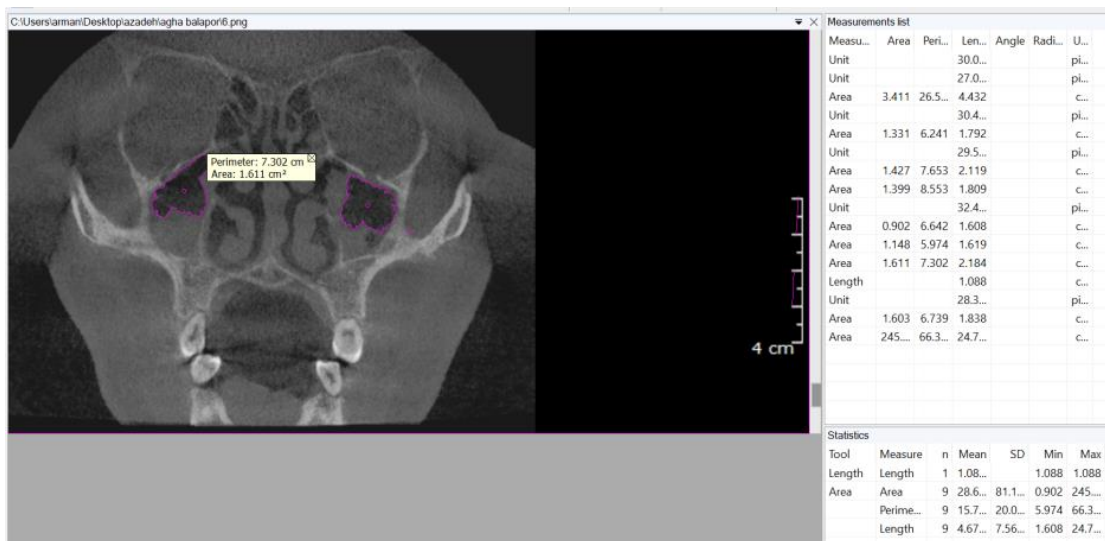


Figure 1. Measuring the area of maxillary sinus sections by Digimizer software

For measuring the angle of deviation of the nasal septum in the coronal plane from the ethmoid bone crystallinity, a line was drawn to ANS and another line from the crystal to the highest deviation of the nasal septum was drawn, and the angle between them was determined. The categories were divided into a low angle (>9 first group), medium angle (9-15 second group) and severe angle ($15 <$ third group) (Figure 2).

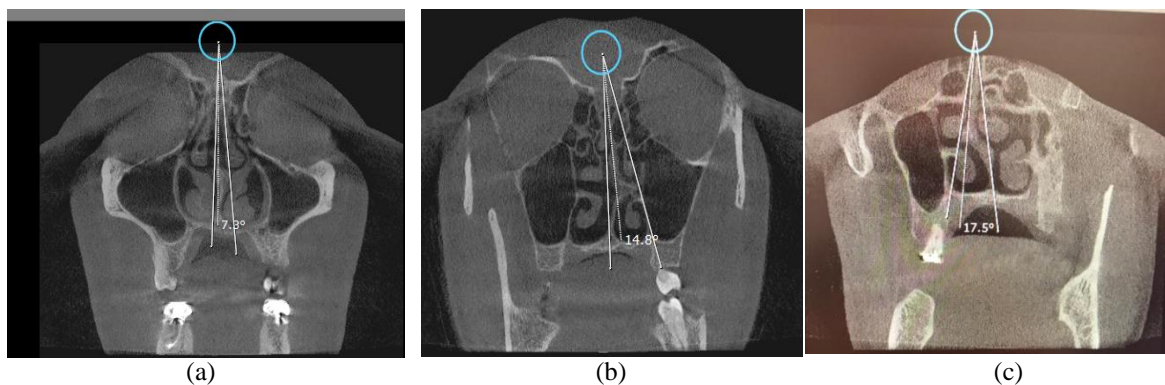


Figure 2. CBCT coronal view of the deviation of the nose using angle measurements a: low angle b: medium angle c: extreme angle

Different types of concha bullosa were divided into three groups: lamellar (local pneumatization in the vertical lamella in concha), bullosa (local pneumatization in the concha bullosa section) and severe (severe pneumatization in the whole middle turbine section) [16] (Figure 3).

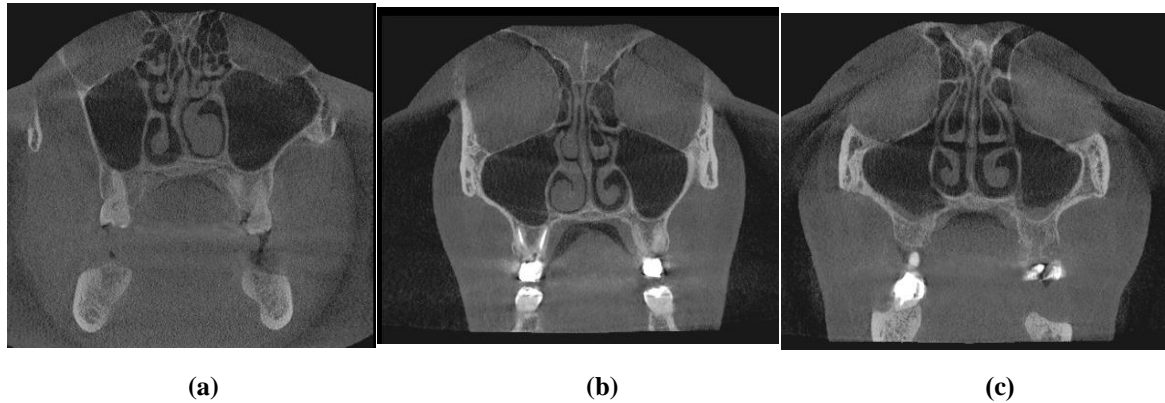


Figure 3. CBCT coronal view of different types of concha bullosa a: Concha bullosa lamellar b: Concha bullosa c: Progressive concha bullosa

For measuring the size of the infundibulum, the diameter of the infundibulum was determined in the coronal plane at a distance of 1 mm from the maxillary sinus ostium (Figure 4).

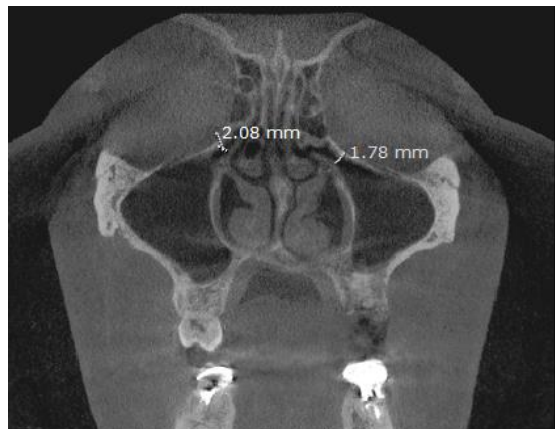


Figure 4. Measuring the infundibulum in CBCT coronal view (white line on both sides indicates measured length)

Data were analyzed using one-way ANOVA, paired t-test, Pearson correlation and regression tests through SPSS 22. Pvalue <0.05 is statistically significant.

Results

In CBCT images, most patients were in the age group of 31-40 years (27.4%) and the mean age of patients was 37.85 ± 12.08 . When comparing the volume of the maxillary sinus from a coronal view in the presence of the nasal septum, the mean volume of the right maxillary sinus was not significantly different in mild, moderate and severe nasal deviation ($p = 0.073$). The mean volume of the right maxillary sinus was less in people with severe nasal deviation than in those with mild and moderate nasal deviation. The mean left sinus volume was significantly different in the presence of mild, moderate and severe nasal deviation ($p < 0.001$) and it was significantly less in people with severe deviation than in those with low and moderate nasal deviation (Table 1). Based on the Pearson correlation coefficient,

there was a significant inverse relationship between right sinus volume and nasal septal deviation ($p = 0.012$, $r = -0.216$). As the amount of nasal deviation increased, the volume of the right sinus was lower. Moreover, there was a significant inverse relationship between left sinus volume and nasal septal deviation ($p = 0.001$, $r = -0.303$). As the amount of nasal deviation increased, the volume of the left sinus was lower.

Table1. Comparing the volume of maxillary sinus from coronal view in the presence of nasal septum

Variable	nasal septum	No	Mean±SD	Pvalue*
	mild	80	11.39±2.82	
	moderate	33	11.09±3.18	
	severe	22	9.77±2.84	
	mild	80	11.32±2.77	
	moderate	33	11.29±3.11	
	severe	22	8.33±2.84	

* by ANOVA

By comparison of maxillary sinus volume from coronal view in the presence and absence of concha bullosa, mean right sinus volume ($p = 0.449$) and left sinus volume ($p = 0.748$) in the presence of lamellar, bulbous and progressive concha bullosa and absence of concha bullosa was not significantly different (Table 2).

Table2. Comparing the maxillary sinus volume from coronal view in the presence and absence of concha bullosa

Variable	Concha bullosa	No	Mean±SD	Pvalue*
	no	63	11.49±3.09	
	lamellar	33	10.74 ± 2.86	
	bulbous	23	10.63±3.03	
	progressive	16	10.58 ±2.47	
	no	63	10.88±2.26	
	lamellar	33	10.57±2.63	
	bulbous	23	10.56±3.10	
	progressive	16	11.52 ± 3.15	

* by ANOVA

In the study of maxillary sinus volume from coronal view and infundibulum size, based on Pearson correlation coefficient, there was a direct and significant relationship between right sinus volume and right infundibulum size ($p < 0.001$, $r = -0.307$). As the volume of the right sinus increased, the size of the right infundibulum was higher and there was a direct and significant relationship between the volume of the left sinus and the size of the left infundibulum ($p = 0.006$, $r = -0.237$). As the size of the left sinus increased, the size of the left infundibulum was larger (Table 3).

Table 3. Correlation coefficient of maxillary sinus volume from coronal view and infundibulum size

Variable	No	left		right	
		r	Pvalue*	r	Pvalue
left sinus volume	135	-0.237	0.006	0.046	0.599
right sinus volume	135	0.176	0.041	-0.307	<0.001

There was no significant difference between the gender and presence and absence of concha bullosa ($p = 0.352$) (Table 4). There was no significant relationship between gender and severity of nasal septal deviation ($p = 0.193$) (Table 5).

Table 4. Relationship between the presence and absence of concha bullosa and gender

Sex	male		women		Total		Pvalue
	no	Percent	no	Percent	no	Percent	
Concha bullosa							
no	34	48.6	29	44.6	63	46.7	
lamellar	14	20.0	19	29.2	33	4.24	
bulbous	11	15.7	12	5.18	23	17.0	
progressive	11	15.7	5	7.7	16	11.9	

Table 5. Relationship between nasal septal deviation severity and gender

Sex	male		women		Total		Pvalue
	no	Percent	no	Percent	no	Percent	
nasal septum							
mild	46	65.7	34	52.3	80	59.3	
moderate	16	22.0	17	26.2	33	24.4	
severe	8	11.4	14	21.5	22	16.3	

Discussion

In the present study, the results showed that there was a significant inverse relationship between the volume of the right and left maxillary sinuses among people with severe nasal septal deviation compared to people with mild and moderate nasal deviation. Besides, a direct and significant relationship was observed between right and left maxillary sinus volume and infundibulum size so that with increasing infundibulum size, maxillary sinus volume was higher, but there was no relationship between the mean sinus volume and gender in the presence or absence of concha bullosa.

Sogono et al. ^[14] studied the prevalence of nasal septal deviation, concha bullosa and infundibulum size and its relationship with maxillary sinusitis by CT scan and concluded that the prevalence of sinusitis was higher in men and the relationship between nasal septal deviation, concha bullosa and maxillary sinusitis was not found. In the current study, there was no significant difference between the maxillary sinus and concha bullosa, but as the extent of nasal deviation increased, the volume of the maxillary sinus was lower, and the mean volume of maxillary sinus was lower in people with severe and moderate nasal deviation, which may be helpful to understand the sinus problems of patients. In contrast to the study by Sogono et al., ^[14] the reason for this difference could be the differences in sinus anatomy in different geographical areas between different races.

In the study by Kalabalik et al. ^[17] on the relationship between maxillary sinus volume and nasal septal deviation, concha bullosa and impacted and missing teeth using CBCT, the mean maxillary sinus volume was significantly higher in males than in females, which contradicts the present study. Therefore, maxillary sinus volume cannot be a good determinant of gender and in the direction of moderate to the severe deviation of the nasal septum, the maxillary sinus was smaller, and maxillary sinus volume decreased with age. There was no significant relationship between maxillary sinus volume and concha bullosa and latent and missing teeth, which is consistent with the findings of the present study.

Kapusuz Gencer et al. ^[18] in the study on the effects of nasal septum deviation on maxillary sinus volume and spread of sinusitis in the maxillary sinus found that maxillary sinus volume was greater on the side of severe nasal septum deviation and probability, developing sinusitis was significantly increased in the present study, the mean volume of the maxillary sinus was less in people with severe deviated nasal septum than in those with mild and moderate deviated nasal septum, which may be due to easier drainage on the opposite side of the deviated nasal septum.

In the study by Smith et al. ^[19] on the prevalence of concha bullosa and nasal septal deviation and their association with maxillary sinusitis using three-dimensional tomography, no relationship was found between the presence of concha bullosa or nasal septum deviation and progression of maxillary sinusitis. According to the results of the current study, but in contrast to the above study, the mean volume of the maxillary sinus in severe deviation of the nasal septum was much less than in moderate and mild deviations, perhaps because severe nasal septal deviation may cause discharge from the sinuses and predispose the patient to sinusitis.

Bahemmat et al. [20] investigated the frequency of nasal septal deviation and concha bullosa and their association with maxillary sinusitis using CBCT and concluded that the presence of concha bullosa as a natural finding may be a risk factor for nasal deviation as well as maxillary sinusitis. Therefore, nasal deviation due to factors such as trauma may cause maxillary sinusitis. However, some risk factors for maxillary sinusitis including concha bullosa may be related to the patient's age. In general, maxillary sinusitis is not significantly related to age and gender, which is consistent with the ongoing study.

The limitations of the current study included difficulties in obtaining CBCT images of patients with complete dental systems and healthy maxillary sinus.

Conclusion

The present findings suggest that mean volume of the maxillary sinus was smaller in people with severe nasal deviation than that in people with mild and moderate nasal deviation. As the size of the infundibulum increased, the volume of the maxillary sinus was higher.

Funding

This study was a research project [Grant No: 2150285479], supported and funded by Isfahan (Khorasgan) Branch, Islamic Azad University, Isfahan, Iran.

Conflicts of Interest

There is no conflict of interest.

Authors' Contribution

The study was designed by Azadeh Torkzadeh. The study data were collected by Azadeh Zakariaee Jubari. Azadeh Torkzadeh and Azadeh Zakariaee Jubari edited and reviewed the article.

References

1. Moore KL, Persaud TV, Torchia MG. The developing human clinically oriented embryology. 7th ed. Philadelphia: Elsevier Health Sciences; 2003.p. 301-24.
2. Mallya SM, Lam EWN. White and Pharoah's Oral radiology: principles and interpretation. 8th ed. St. Louis: Elsevier; 2019.p. 506-23.
3. Ghassemi A, Prescher A, Riediger D, Axer H. Anatomy of the SMAS revisited. *Aesthetic Plast Surg* 2003;27:258-64.
4. Yildirim I, Okur E. The prevalence of nasal septal deviation in children from Kahramanmaraş, Turkey. *Int J Pediatr Otorhinolaryngol* 2003;67:1203-6.
5. Kim YM, Rha KS, Weissman JD, Hwang PH, Most SP. Correlation of asymmetric facial growth with deviated nasal septum. *Laryngoscope* 2011;121:1144-8.
6. Zielnik-Jurkiewicz B, Olszewska-Sosińska O. The nasal septum deformities in children and adolescents from Warsaw, Poland. *Int J Pediatr Otorhinolaryngol* 2006;70:731-6.
7. Yasan H, Doğru H, Baykal B, Döner F, Tüz M. What is the relationship between chronic sinus disease and isolated nasal septal deviation? *Otolaryngol Head Neck Surg* 2005;133:190-3.
8. Aziz T, Ansari K, Lagravere MO, Major MP, Flores-Mir C. Effect of non-surgical maxillary expansion on the nasal septum deviation: a systematic review. *Prog Orthod* 2015;16:15.

9. Arredondo de Arreola G, López Serna N, de Hoyos Parra R, Arreola Salinas MA. Morphogenesis of the lateral nasal wall from 6 to 36 weeks. *Otolaryngol Head Neck Surg* 1996;114:54-60.
10. Akbulut A, Dilaver E. Correlation between prevalence of Haller cells and postoperative maxillary sinusitis after sinus lifting Procedure. *Br J Oral Maxillofac Surg* 2019;57:473-6.
11. Bhattacharyya N. Do maxillary sinus retention cysts reflect obstructive sinus phenomena? *Arch Otolaryngol Head Neck Surg* 2000;126:1369-71.
12. Al-Rawi NH, Uthman AT, Abdulhameed E, Al Nuaimi AS, Seraj Z. Concha bullosa, nasal septal deviation, and their impacts on maxillary sinus volume among Emirati people: A cone-beam computed tomography study. *Imaging Sci Dent* 2019;49:45-51.
13. Kucybała I, Janik KA, Ciuk S, Storman D, Urbanik A. Nasal Septal Deviation and Concha Bullosa - Do They Have an Impact on Maxillary Sinus Volumes and Prevalence of Maxillary Sinusitis? *Pol J Radiol* 2017;82:126-33.
14. Sogono PG. Prevalence of Nasal Septal Deviation, Concha bullosa, and Infundibular Size and their Association with Maxillary Sinusitis by Computed Tomography in Filipinos with Paranasal Sinus Disease. *J Otolaryngol Facial Plast Surg* 2019;5:1-6.
15. Ono N, Kase K, Homma H, Kusunoki T, Ikeda K. Maxillary sinus infundibulum narrowing influences sinus abnormalities in spite of the presence or absence of allergy. *Acta Otolaryngol* 2011;131:1193-7.
16. Etemadi Sh, Seylavi G, Yadegari A. Correlation of the maxillary sinus volume with gender and some of craniofacial indices using cone beam computed tomography. *Biosc Biotech Res Comm* 2017;10:580-6.
17. Kalabalık F, Tarım Ertuş E. Investigation of maxillary sinus volume relationships with nasal septal deviation, concha bullosa, and impacted or missing teeth using cone-beam computed tomography. *Oral Radiol*.2019;35:287-95.
18. Kapusuz Gencer Z, Ozkırış M, Okur A, Karaçavuş S, Saydam L. The effect of nasal septal deviation on maxillary sinus volumes and development of maxillary sinusitis. *Eur Arch Otorhinolaryngol* 2013;270:3069-73.
19. Smith KD, Edwards PC, Saini TS, Norton NS. The prevalence of concha bullosa and nasal septal deviation and their relationship to maxillary sinusitis by volumetric tomography. *Int J Dent* 2010;2010:404982.
20. Bahemmat N, Hadian H. The frequency of nasal septal deviation and concha bullosa and their relationship with maxillary sinusitis based on CBCT finding. *Int J Med Res Health Sci*2016; 5:152-6.