



Uncommon Tumor of the Breast - A Case Report

Author: Prashanth K¹

Co Authors: Subhas Bhakta S²

^{1,2}Department of Shalyatantra, Sri Dharmasthala Manjunatheshwara Ayurveda Hospital, Kuthpady, Udupi, Karnataka, India

ABSTRACT

A female patient came with a large lump in the right breast, FNAC revealed phyllodes tumor which was treated surgically by tumor excision. Instead of the conventional mastectomy, breast conserving approach was carried out. The case was followed up for 18 months to check for recurrence of the tumor.

Key Words: *Phyllodes tumor, Excision biopsy, Breast conserving Approach*

INTRODUCTION

Breast, a modified sweat gland which is derived from ectoderm, as branching epithelial chords¹ which forms lactiferous ducts. About 15-20 lobes², in females mature during adolescence, each of which drains into a single lactiferous duct. True secretory alveoli start during pregnancy and lactation under influence of estrogen, progesterone and prolactin³.

About 1/3 of the women suffer from breast diseases at least once in their life. Incidence of breast cancer in India is about 25.8 per 1 lakh women with a mortality of 12.7 per 1 lakh women⁴. Benign Breast diseases are at least 10 times more common than malignant ones in hospital clinics. Currently malignant to benign ratio is 1:10 as seen in breast clinics⁵. The incidence of benign breast disease commences rising from the second decade of life and peaks at fourth to fifth decades. Benign breast disease encapsulates a wide variety of disorder one among

them is Phyllodes tumor of the breast, which is a rare fibro-epithelial type of lesion. These lesions makes up about 0.3 to 0.5% of the diagnosed case of female breast tumors⁶ and have a prevalence of about 2.1 per 10 Lakh cases. The peak of Phyllodes tumor occurs in the age group of 45 to 49 years^{7,8}. These tumors show a wide range of activity, varying from almost a benign condition (in 85% of the cases), to locally aggressive ones and sometimes metastatic tumor (in 15% of the cases).

Hence, accurate preoperative examination and pathological diagnosis allows for precise surgical intervention and thereby avoids reoperation, either by achieving wider excision of tumor mass or by reducing subsequent tumor recurrence⁹⁻¹¹. Treatment of phyllodes tumor ranges from extensive local excision to radical mastectomy, depending upon the mitotic index^{12,13} which is provided histopathologically.



CASE REPORT

Presenting complaints:

A female patient aged 37 years, visited OPD of *Shalyatantra* at S.D.M AYURVEDA HOSPITAL KUTHPADY with a H/O painless lump in her Right breast for 6 months. The lump was small initially and eventually grew to a considerable size in a span of 4 months to an extent that, there was a significant difference in the size of her breasts. She noticed gradual prominence of veins on the affected breast and painless small lump in the ipsilateral axilla. Negative history for nipple discharge, breast trauma or weight loss. She gave a history of breast abscess in the same breast during lactation about 4 years back and improper breast-feeding from the affected breast until the baby was weaned. The abscess resolved with medical management. History is not significant for DM, HTN, bleeding tendency, menstrual irregularities and familial malignancies.

Clinical findings & diagnostic assessments

Systemic examinations were within normal limits and examination of the breast revealed enlargement of the right breast compared to left. Size (L*B) of right breast 18 cm* 19 cm, left breast 15 cm*16 cm. Engorged veins were visible in the upper quadrants in the affected breast. Nipple of right breast found depressed when compared to the left. No puckering or tethering of the skin was observed during examination. On palpation swelling was globular and bosselated, non-tender, swelling extended from right upper outer quadrant to right lower outer quadrant, number was single, size 9 cm* 7 cm (L*B),

consistency was firm, fluctuation absent, the swelling was confined to breast. Few ipsilateral axillary lymph nodes (pectoral and central groups) were palpable, which were movable, nontender and firm in consistency.

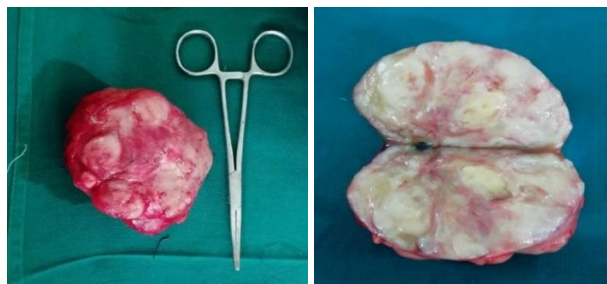U.S.G of the Rt breast reported Fibroadenoma of the breast with non-specific enlargement of axillary lymph nodes. However, FNAC reported as Phyllodes tumor.

MATERIALS AND METHODS

Therapeutic intervention:

After the preoperative investigations, Excision biopsy of the breast tumor was carried out under general anaesthesia.

Prepping was done with antiseptics. The lesion was approached through an upper quadrant by a radial incision as the mass was significantly large. Mass was dissected clearly from all around with a thin rim of tissue covering the mass. Bleeders were secured with diathermy and ligatures. A corrugated drain was placed through a stab incision to drain out any fluid collection. The subcutaneous layer was approximated by Interrupted Vicryl 3-0 sutures. Skin closure was done with running Subcuticular suture 3-0 Ethylon sutures considering cosmesis. The drain was removed after 24 hrs and suture was removed on 7th PO day. The excised tumour as shown in **Image 1 & Image 2** was sent for histopathological study. Patient was periodically followed up for 18 months for recurrence.



Images of excised phyllodes tumor (**Image 1 and Image 2**)

DISCUSSION

The phyllodes are one such tumor which has a wide range of activity, based on the mitotic index and extent of pleomorphism they are graded from low-grade tumor to a high-grade tumor. It is most commonly occurring nonepithelial neoplasm of the breast, although it represents only 1 percent of all breast tumors. The Mammographic evidence of morphology, calcification and necrosis cannot differentiate between a benign, borderline and malignant variety of phyllodes tumor. However, the tumor margin is usually well defined and differentiated from the adjacent breast tissue, which is crushed and altered. The tumor mass contains connective tissues; with mixed gelatinous, solid and cystic regions. These gross alteration in the tumor gives it a classical LEAF-LIKE appearance in gross cross-section. Phyllodes tumor has greater cellular activity than that of a fibroadenomas. Most malignant phyllodes tumor contain liposarcomatous or rhabdomyosarcomatous elements. All these features can only be noted operatively or post operatively i.e. after histopathological investigation as shown in **Image 3**. Hence, the nomenclature, presentation and diagnosis of

phyllodes tumor have posed many problems for surgeons even after careful history taking, examination and investigations¹⁴. In the present case, the differential diagnosis ranged from chronic abscess to carcinoma of the breast given the history, age and parity. Only by diligent and thorough clinical examination, the case was diagnosed as phyllodes tumor.

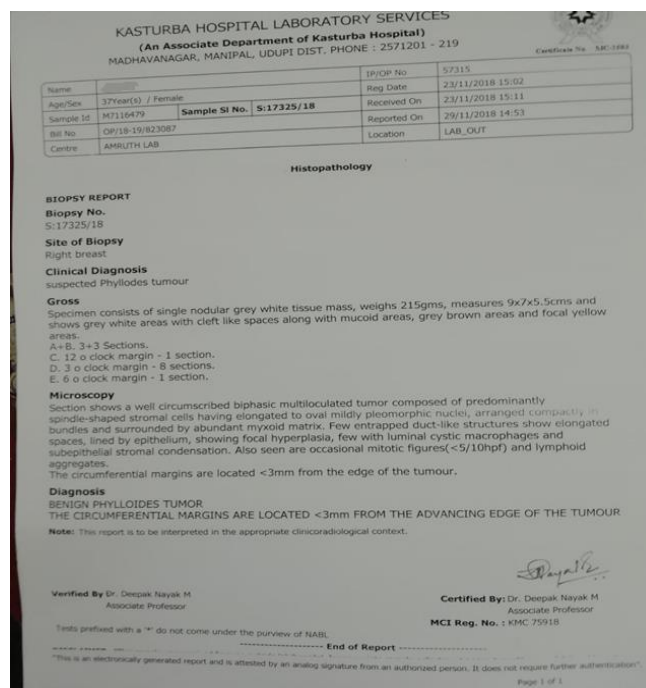


Image 3 Biopsy report of phyllodes tumor

Though surgery is the prime treatment, type of surgery has been a matter of debate over the years. Mastectomy and Breast conserving surgery have both been advocated as surgical treatment for this tumor. Prior studies have found no significant differences among the above two surgical procedures in terms of overall survival or metastasis-free survival. However, the frequency of local recurrence of the tumor has been found more with the latter¹⁵. Hence, a regular follow up for 18 months was carried out in this study and no recurrence of the tumor observed.



In *Ayurveda*, the presented clinical features like a constantly growing tumor, huge in size and non-suppurative resembles the description of *Arbuda*¹⁶, explained in *Sushruta Samhita* especially the *Kaphaja* variety. Management of *kaphaja arbuda*¹⁷ is both medical and surgical. In the early stages of the growth, *shodhana* followed by *vimlapanadi* external treatment is carried out. When the growth is refractive to medical management and not in *marma sthaana* (vital region), excision with *agnikarma* is the therapeutic choice.

CONCLUSION

Phyllodes tumor is an uncommon growth in the breast. The name phyllodes is due to typical leaf like appearance of the tumor in the cross section. Although the tumor is considered benign it has malignant potential. The treatment ranges from mastectomy to breast conserving tumor excision. In *Ayurveda* this condition, based on its presentation resembles *Acharya sushruta's Kaphaja Arbuda*. Were, he advises management with *Kshara, Agni and Shastra Karma*. Hence, in this case taking that into consideration, a breast conserving approach was planned, with the circumferential tumor margin less than 3 mm from the advancing edge, there by preserving maximum viable breast tissue for a better cosmetic outcome. A follow up period of 18 months revealed no recurrence of the growth.



REFERENCES

1. Bhat, S., M. (2013). *SRBs manual of surgery* (5th ed.). New Delhi: Jaypee Brothers Medical (P)..Pg no. 512
2. Bland, K. I., & Copeland, E. M. (2009). *The Breast: Comprehensive management of benign and malignant diseases* (3rd ed.). Philadelphia: Saunders/Elsevier. Pg no.10
3. Bailey, H. C., Love, M. S., Russell, R. J., Williams, N. U., Bulstrode, C. U., & Bailey, H. U. (2006). *Bailey & Love's Short Practice of surgery* (27th ed., Vol. 2). Boca Raton, Florida: CRC Press, Taylor & Francis group. Pg no. 870
4. Selvakumaran, S., & Sangma, M. B. (2016). Study of various benign breast diseases. *International Surgery Journal*, 4(1), 339. doi:10.18203/2349-2902.isj20164466.
5. Sabiston, D. C., Townsend, C. M., Evers, M. B., Mattox, K. L., & Beauchamp, D. R. (2004). *Sabiston textbook of surgery: The biological basis of modern surgical practice* (17th ed., Vol. 1). Philadelphia, PA: Elsevier, Saunders. Pg no. 892
6. Rowell, M. D., Perry, R. R., Hsiu, J., & Barranco, S. C. (1993). Phyllodes tumors. *The American Journal of Surgery*, 165(3), 376-379. doi:10.1016/s0002-9610(05)80849-9
7. Salvadori, B., Cusumano, F., Bo, R. D., Delledonne, V., Grassi, M., Rovini, D., . . . Clemente, C. (1989). Surgical treatment of phyllodes tumors of the breast. *Cancer*, 63(12), 2532-2536. doi:10.1002/1097-0142(19890615)63:123.0.co;2-q
8. Bernstein, L., Deapen, D., & Ross, R. K. (1993). The descriptive epidemiology of malignant cystosarcoma phyllodes tumors of the breast. *Cancer*, 71(10), 3020-3024. doi:10.1002/1097-0142(19930515)71:103.0.co;2-g
9. Ridgway, P., Jacklin, R., Ziprin, P., Harbin, L., Peck, D., Darzi, A., & Rajan, P. (2004). Perioperative diagnosis of cystosarcoma phyllodes of the breast may be enhanced by MIB-1 index. *Journal of Surgical Research*, 122(1), 83-88. doi:10.1016/j.jss.2004.07.003
10. El-Naggar, A. K., Mackay, B., Sneige, N., & Batsakis, J. G. (1990). Stromal neoplasms of the breast: A comparative flow cytometric study. *Journal of Surgical Oncology*, 44(3), 151-156. doi:10.1002/jso.2930440306
11. Jacklin, R. K. (2006). Optimising preoperative diagnosis in phyllodes tumour of the breast. *Journal of Clinical Pathology*, 59(5), 454-459. doi:10.1136/jcp.2005.025866
12. Chaney, A. W., Pollack, A., Mcneese, M. D., Zagars, G. K., Pisters, P. W., Pollock, R. E., & Hunt, K. K. (2000). Primary treatment of cystosarcoma phyllodes of the breast. *Cancer*, 89(7), 1502-1511. doi:10.1002/1097-0142(20001001)89:73.0.co;2-p
13. Foucher, T. D., Roussel, H., Hivelin, M., Rossi, L., Cornou, C., Bats, A., . . . Ngô, C. (2017). Atypical Distant Metastasis of Breast Malignant Phyllodes Tumors: A Case Report and Literature Review. *Case Reports in Obstetrics and Gynecology*, 2017, 1-6. doi:10.1155/2017/8963013



14. Cohn-Cedermark, G., Rutqvist, L. E., Rosendahl, I., & Silfverswärd, C. (1991). Prognostic factors in cystosarcoma phyllodes. A clinicopathologic study of 77 patients. *Cancer*, 68(9), 2017-2022. doi:10.1002/1097-0142(19911101)68:93.0.co;2-v
15. Khan, S. A., & Badve, S. (2001). Phyllodes tumors of the breast. *Current Treatment Options in Oncology*, 2(2), 139-147. doi:10.1007/s11864-001-0056-y
16. Professor Shrikanth Murthy KR (2012) Sushrut Samhita vol 1st NidhanaSthana 11/6 & 14 Chaukhamba Orientalia Varanasi, Pg no. 533,534.
17. Professor Shrikanth Murthy KR (2012) Sushrut Samhita vol 1st NidhanaSthana 18/35-40 Chaukhamba Orientalia Varanasi, Pg no. 178.