

## REVIEW

# Emerging concepts in heart failure management and treatment: focus on point-of-care ultrasound in cardiogenic shock

Mariela Ruben<sup>1,2</sup>, María Sol Molinas<sup>1,2</sup>, Hugo Paladini<sup>3</sup>, Wissam Khalife<sup>4</sup>, Alejandro Barbagelata<sup>1,5</sup>, Sergio Perrone<sup>1,6</sup>, Edgardo Kaplinsky<sup>7</sup>

<sup>1</sup>Catholic University Argentina, Buenos Aires, Argentina; <sup>2</sup>Cardiology Service, MIT Group, Santa Fe, Argentina; <sup>3</sup>Medical Images Service, MIT Group, Santa Fe, Argentina; <sup>4</sup>Division of Cardiology, University of Texas Medical Branch, Galveston, TX, USA; <sup>5</sup>Duke University School of Medicine, Durham, NC, USA; <sup>6</sup>Fleni Institute, Buenos Aires, Argentina; <sup>7</sup>Cardiology Unit, Medicine Department, Hospital Municipal de Badalona, Spain

## Abstract

Point-of-care ultrasound (POCUS) plays a strategic role in the diagnostic and therapeutic evaluation of critically ill patients and, especially, in those who are haemodynamically unstable. In this context, POCUS allows a more precise identification of the cause, its differential diagnosis, the eventual coexistence with another entity and, finally, guiding of the therapeutic approach. It implies a portable use of ultrasound in acute settings covering different specified protocols, such as echocardiography, vascular, lung or abdominal ultrasound. This article reviews POCUS application in the emergency department or the intensive care unit, focused on severely compromised patients with cardiogenic shock with an emergent bedside assessment. Considering the high mortality rate of this entity, POCUS provides the intensivist/clinician with an appropriate tool for accurate diagnoses and a timely management plan. The authors propose practical algo-

rithms for the diagnosis of patients using POCUS in these settings.

This article is part of the *Emerging concepts in heart failure management and treatment* Special Issue: [https://www.drugsincontext.com/special\\_issues/emerging-concepts-in-heart-failure-management-and-treatment](https://www.drugsincontext.com/special_issues/emerging-concepts-in-heart-failure-management-and-treatment)

**Keywords:** cardiogenic shock, heart failure hypotension, POCUS, point-of-care ultrasound.

## Citation

Ruben M, Molinas MS, Paladini H, Khalife W, Barbagelata A, Perrone S, Kaplinsky E. Emerging concepts in heart failure management and treatment: focus on point-of-care ultrasound in cardiogenic shock. *Drugs Context*. 2023;12:2022-5-8. <https://doi.org/10.7573/dic.2022-5-8>

## Introduction

The presence of a cardiogenic shock (CS) represents a dramatic situation characterized by significant in-hospital mortality (30–60%), where half of the deaths usually occur during the first 24 hours of initiation of symptoms. It is the superlative expression of the acute heart failure (HF) spectrum, representing 2–5% of cases; therefore, CS requires an early and precise diagnosis in order to differentiate from other types of shock and to establish effective initial treatment.<sup>1–5</sup>

In 2020, CS was defined by the Heart Failure Association of the European Society of Cardiology as a 'syndrome

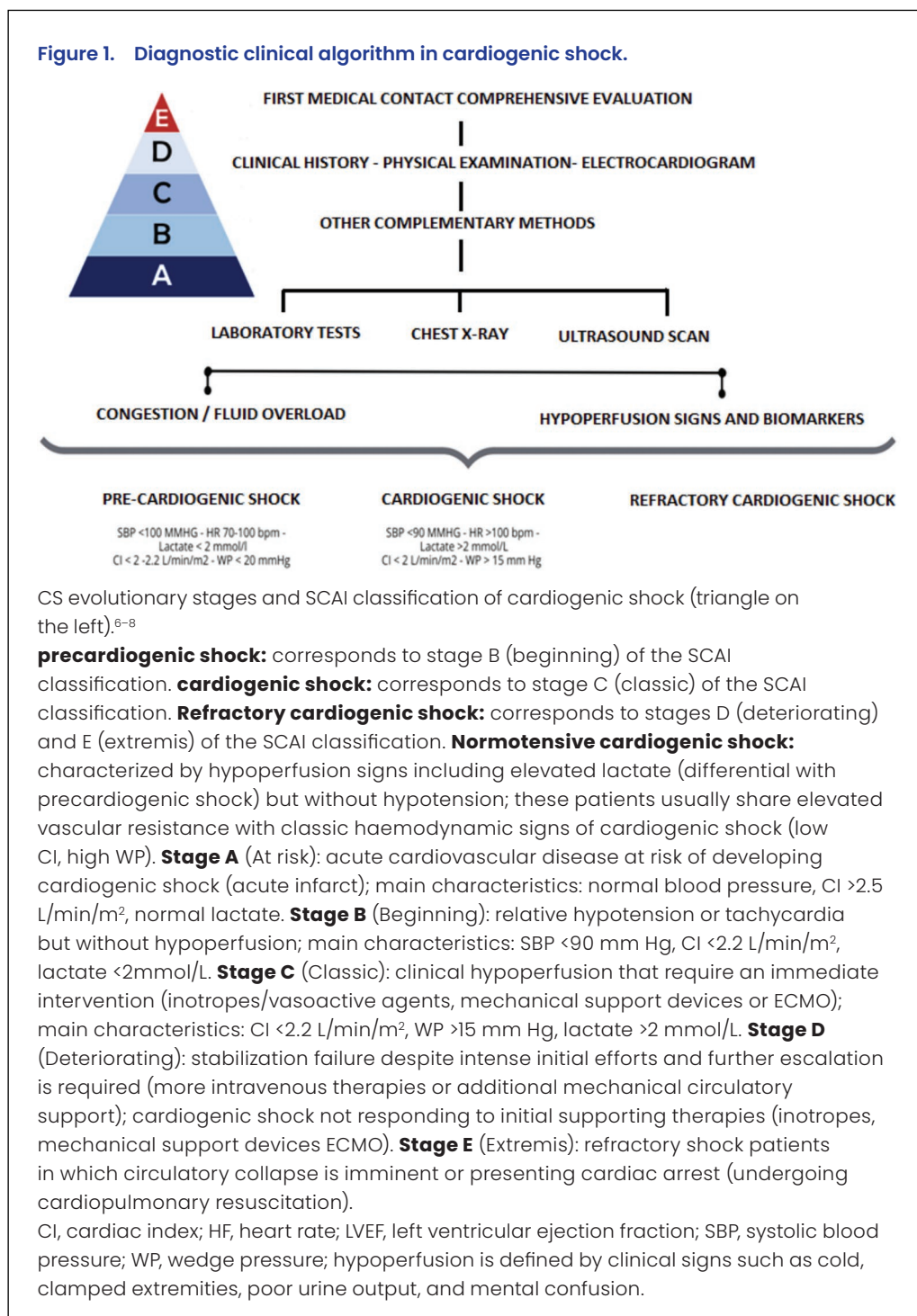
caused by a primary cardiovascular disorder in which inadequate cardiac output results in a life-threatening state of tissue hypoperfusion associated with impairment of tissue oxygen metabolism and hyperlactatemia which, depending on its severity, may result in multiorgan dysfunction and death'.<sup>6</sup> Considering its clinical impact and treatment effects, three evolutionary stages of CS could be described: pre-CS, CS and refractory CS.<sup>7</sup> Pre-CS is characterized by hypoperfusion and systolic blood pressure (SBP) >90 mm Hg without circulatory support, whilst CS is defined by hypoperfusion signs, SBP <90 mm Hg (>30 min), or the requirement for inotropic support or an intra-aortic balloon pump to maintain SBP >90 mm Hg. Finally, refractory CS is the clinical condition in which hypoperfusion persists despite

the administration of adequate doses of at least two vasoactive drugs for the treatment of the underlying aetiology<sup>7</sup> (Figure 1).

A relevant issue to highlight is the difference between pre-CS and so-called 'normotensive CS'. Both entities show signs of hypoperfusion without hypotension but, in the case of pre-CS, there is still no compromise of cellular metabolism (normal lactate), whilst in normotensive CS the lactate level is elevated (cellular hypoxia).<sup>6</sup>

In 2019, the Society of Cardiovascular Angiography and Interventionism published a classification of CS that seeks to account for mortality according to its degree of severity, which consist of five evolutionary stages, from patients with risk conditions for developing CS (Stage A 'at risk') to patients with extremely severe CS (stage E 'extremis')<sup>8</sup> (Figure 1).

In a CS setting, point-of-care ultrasound (POCUS) becomes the first echocardiographic line of compre-



hensive evaluation because it allows the identification of the possible underlying aetiology as well as of its pathophysiology. It provides information on heart structure, ventricular function and haemodynamic parameters in a non-invasive, portable (bedside) and timely manner. In addition, POCUS includes other extremely useful ultrasound protocols (vascular, lung or abdominal) that are relevant when evaluating, for example, congestion or early signs of organ damage.<sup>9</sup>

Considering all these benefits, in 2015, the American Society of Echocardiography proposed echocardiography as a key tool for the diagnosis, monitoring and treatment of critically ill patients in different scenarios. In consequence, it should be applied in, for example, cardiac and non-cardiac interventions, volume replacement therapy, control of pericardial effusions, placement or weaning of ventricular assist devices, and in postoperative controls of cardiac and non-cardiac surgeries.<sup>10</sup> In the case of patients hospitalized in the ICU, there are two different echocardiographic approaches: a basic one that can be performed by an intensivist, and an advanced one, which requires a very well-trained operator (echocardiographer).<sup>9</sup>

The purpose of this narrative review is to present the advantages and limitations of POCUS protocols in CS. In addition, some practical diagnostic algorithms are proposed, ranging from basic to advanced approaches. For the elaboration of this article, the most relevant bibliographic sources (in the authors' opinion) indexed in PubMed (written only in English since the year 2000) were used, searching with the keywords: "cardiogenic shock", "ultrasound at the point of care", "shock", "hypotension" and "undifferentiated hypotension".

## Review

### Basic POCUS algorithm

A basic POCUS algorithm is proposed based on three sonographic areas: echocardiography, lung ultrasound and venous ultrasound.

### Echocardiography

Basic echocardiography is an initial step that should be conducted at the patient's bedside by the intensive care physician, focusing on a rapid diagnosis, ruling out major complications, and allowing treatment guidance. This evaluation is performed with a 2D Transthoracic Echo and M-mode in five views (left parasternal long axis, left parasternal short axis, four-chamber apical view, five-chamber apical view and subcostal view)<sup>9,10</sup> (Figure 2).

The analysis of left ventricle function is a capital parameter to be determined in patients who are unstable

because it permits us to verify the need for inotropic support and/or volume replacement. When left ventricular ejection fraction (LVEF) is compromised, myocardial contractility is globally or regionally reduced and constitutes a strong prognostic marker for CS.<sup>11,12</sup>

An initial inspection could bring qualitatively vital information by viewing heart chamber dimensions and wall motion in real time, allowing the establishment of three degrees of ventricular dysfunction (mild, moderate, severe).<sup>11</sup> However, an objective measurement should always be considered (advanced studies) and, in this context, the most recommended method for calculating it is the Simpson biplane<sup>11</sup> (Figure 2).

As previously mentioned, the determination of LVEF at admission is crucial in patients with CS because it represents a strong prognostic marker.<sup>12</sup> In the SHOCK trial, a LVEF <8% with mild-to-severe mitral insufficiency was linked with a very high mortality (10% 1-year survival) compared with patients with LVEF >28% and no or mild mitral regurgitation (70% 1-year survival).<sup>12</sup> In a multivariate analysis performed by Jentzer et al., hospital mortality resulted higher in patients with CS exhibiting LVEF <40% (*versus* >40%) at every stage of CS (A–E).<sup>13</sup>

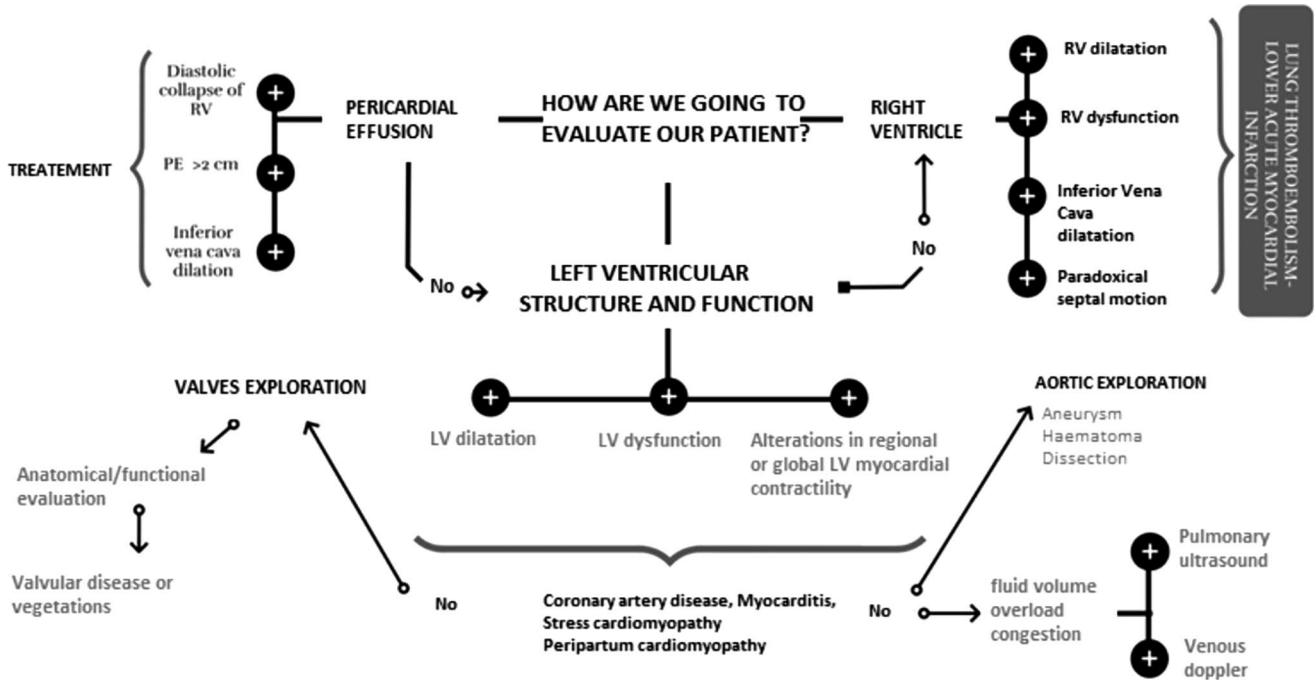
The analysis of right ventricular (RV) function is also important, and it should not be overlooked because its deterioration may also be the basis or favour CS aggravation or perpetuation; this can be due to a primary lack of contractility (RV infarction) or secondary to a volume overload (e.g. interventricular septal defects) or pressure overload (e.g. pulmonary thromboembolism, acute respiratory distress)<sup>14</sup> (Figure 2). Systolic RV function can be estimated by measuring tricuspid annular plane systolic excursion, tricuspid S wave velocity (S') and RV fractional area change. An S' velocity of the lateral tricuspid annulus of <11.5 cm/s determines RV dysfunction in a practical and early way (90% sensitivity and 85% specificity).<sup>15</sup>

Visually, RV dilation can be estimated by comparing its dimensions with LV end-diastole dimensions; in healthy individuals, this RV/LV ratio is <0.6; a ratio of >1 is considered to indicate severe RV dilatation.<sup>14</sup>

It is extremely important to know RV function in critically ill patients requiring mechanical ventilation because hyperinflation can prevent venous return and reduce RV filling by increasing intrathoracic pressure.<sup>9</sup>

The determination of the intravascular volume status, including ventricular volumes, is another relevant issue in patients who are haemodynamically unstable and represents a real challenge for ICU operators (Figure 2). In this context, the assessment of LV end-diastolic diameter

Figure 2. Basic echocardiogram approach.



Basic echocardiographic examination comprises six classical windows:<sup>9,11,25</sup>

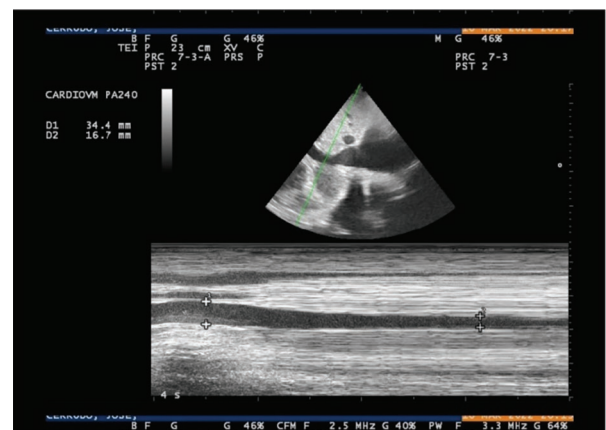
- Left ventricular function: visual estimation and, if possible, objective determination (Simpson biplane)
- Valvular examination: mainly focus on mitral regurgitation assessment
- Aortic root and ascendant aorta
- Intravascular volume and preload status: left ventricle, right heart and inferior vena cava examination
- Pulmonary congestion: pulmonary ultrasound
- High venous pressure markers: evaluation of large veins (inferior vena cava, internal jugular vein) and detection of abnormal venous waveforms (portal, hepatic and intrarenal veins)

(myocardial fibre length before systolic contraction) and of its area and volume could be analysed as indicators of preload status.<sup>14</sup> For example, the observation of an obliterated or collapsed LV cavity ('kissing ventricles') can point towards severe hypovolaemia.<sup>14</sup>

Another relevant parameter of intravascular volume status is the measurement of the diameter of the inferior vena cava (IVC) and its grade of collapsibility<sup>14</sup> (Figure 3) and, in this context, a recent study also showed the importance of adding the right internal jugular collapsibility to IVC size and collapsibility in estimating an accurate right atrial pressure.<sup>16</sup>

A further important issue is a basic but complete examination of cardiac valves, which requires reasonable but not necessarily expert skills and, in this setting, the presence of mitral insufficiency becomes relevant because it is also considered a predictor of mortality in patients with CS.<sup>12,13,17</sup> Its severity could reflect closure anomalies of an ischaemic origin or secondary to ventricular geometry alterations (increased end-diastolic volume)<sup>12</sup> (Figure 2).

Figure 3. Venous ultrasound – IVC evaluation.



The evaluation of the inferior vena cava (IVC) dimension is used to assess intravascular volume status by estimating right atrium pressure. An IVC dimension of  $\geq 21$  mm (at the end of expiration) with a respiratory collapsibility of  $< 50\%$  is significantly associated with an elevated right atrial pressure.<sup>16</sup>



Aortic pathology can be revealed in the parasternal long-axis view, where the ascending aorta is observed in its sinus, sinotubular and tubular portions; this window allows measurement of its diameters and the presence of dissection flaps or intramural haematomas<sup>115</sup> (Figure 2). In addition, and only by supporting the transducer on the patient's chest wall, the presence of pericardial effusion can be easily evidenced, thus allowing assessment of whether it is severe (>2 cm) and/or if it has signs of tamponade such as right cavity collapse or an inferior plethoric vena cava with a reduced respiratory variation<sup>12</sup> (Figure 2). Of note, even smaller magnitudes of pericardial effusion but with clinical or echocardiographic signs of haemodynamic compromise should be treated as severe.<sup>10</sup>

A plethoric vena cava has diagnostic and prognostic value because its association with cardiac tamponade is highly sensitive (97%) but with a lower specificity (40%) than other signs such as the collapse of right heart cavities or jugular venous distention (requirement of drainage, evolution to constriction, etc.).<sup>18</sup>

### Lung ultrasound

Lung ultrasound (LU) is increasingly recommended in the management of patients who are severely compromised because it is easily accessible and permits a quick evaluation of multiple pathologies. This tool is a useful complement to transthoracic echocardiography in an acute HF setting that allows assessment of the presence of pulmonary congestion

or pleural effusion and helps to rule out other clinical scenarios such as pneumothorax or a pulmonary consolidation.<sup>19,20</sup>

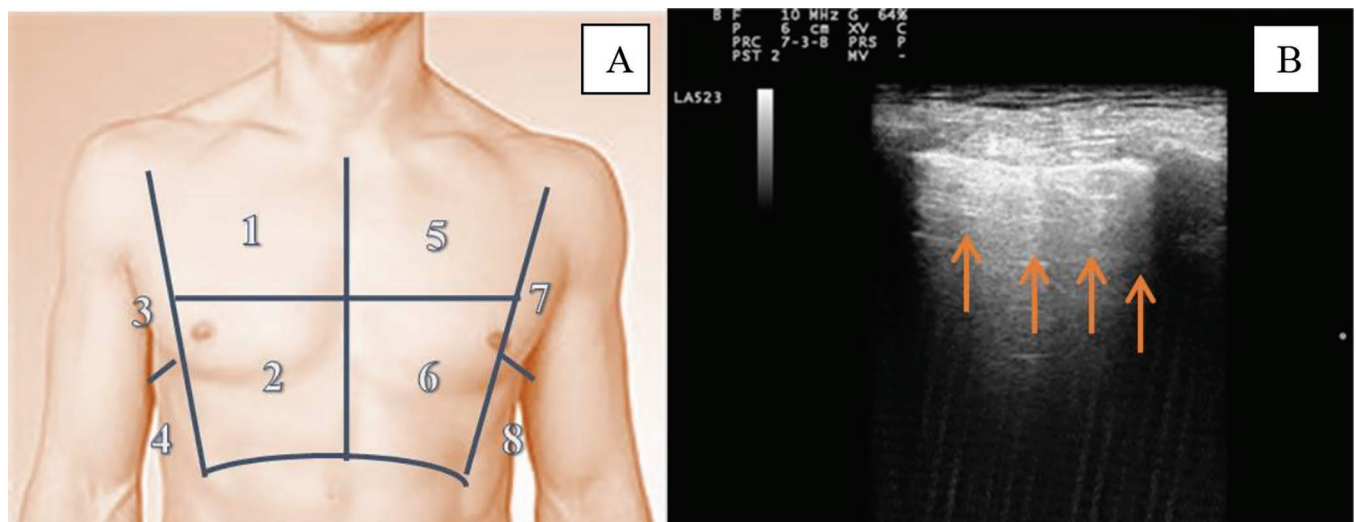
The presence of oedema in lung tissue is manifested by the finding of B lines or comet tail images (hyperechoic vertical artifacts), which should start and extend from the pleural line, reach the lower edge of the screen, erase the A lines and, finally, accompany respiratory movements.<sup>19</sup> The presence of pulmonary oedema is considered when at least three or more B lines (two or more intercostal spaces bilaterally) are visualized (94% sensitivity/92% specificity)<sup>19</sup> (Figure 4).

The finding of multiple bilateral B lines in an acute HF setting has been adequately correlated with elevated levels of natriuretic peptides but variably in relation to pulmonary capillary wedge pressure.<sup>19</sup> Usually, the number of B lines decreases with decongestant treatment; therefore, echocardiography could be useful in monitoring pulmonary oedema response to therapy. On the other hand, hospital discharge of patients who still have a high number of B lines could be an indicator of poor prognosis.<sup>21</sup>

Pleural effusion is another common finding in patients with HF and is observed as an anechoic space between both pleural lines (parietal and visceral).<sup>10</sup>

When using the M-mode through a pleural effusion, a dynamic change in its size (sinusoidal wave) that ap-

**Figure 4. Pulmonary ultrasound.**



**a** | There are several lung ultrasound imaging protocols ranging from 4 to 28 thoracic regions but the simplified 8-zone protocol is the most widely used. **b** | Lung ultrasound is more sensitive in detecting pulmonary oedema than clinical examination and chest radiography and its presence is manifested by the finding of B lines or comet tail images as seen in image.<sup>25</sup>

proaches and recedes from the pleural line can sometimes be observed, which is characterized by inspiratory decrease (or respirator insufflation) followed by increased expiratory. This sign is known as the ‘sinusoid sign’ and is highly specific for pleural effusion, as it can distinguish even a small pleural effusion from pleural thickening.<sup>22</sup>

The lungs are particularly sensible to the adverse effects of fluid overload and, in this setting, lung congestion has been also correlated with mortality in critically ill patients.<sup>20</sup> In 2016, the European Heart Failure Guidelines included LU as a diagnostic tool for patients with acute HF (including CS).<sup>23</sup>

### Venous ultrasound diagnostic algorithm

The presence of venous congestion as an expression of increased central venous pressure and cardiac filling pressures is a common finding in individuals with CS<sup>24</sup> and, in this context, POCUS represents a widely available tool that allows the clinician to obtain both vascular anatomy and Doppler flow images.<sup>25</sup> In this context, the evaluation of different large veins (IVC, internal jugular) as well as the detection of abnormal venous waveforms in certain venous circuits (portal, hepatic and intrarenal) is useful for the detection of congestion (high venous pressures).<sup>25</sup>

In patients with HF, portal pulsatile flow has been shown to be the best predictor of bilirubin elevation (liver congestion), whereas the detection of abnormal intrarenal and portal venous flow patterns is connected with a worse outcome (hospitalization or death).<sup>26</sup>

Therefore, and considering the importance of increased venous pressures, a venous congestion classification system was developed to detect hepatic, intestinal and renal congestion, which is very useful in predicting early signs of organ damage (postcardiac surgery kidney injury) and to guide fluid management.<sup>24</sup>

### Hepatic veins

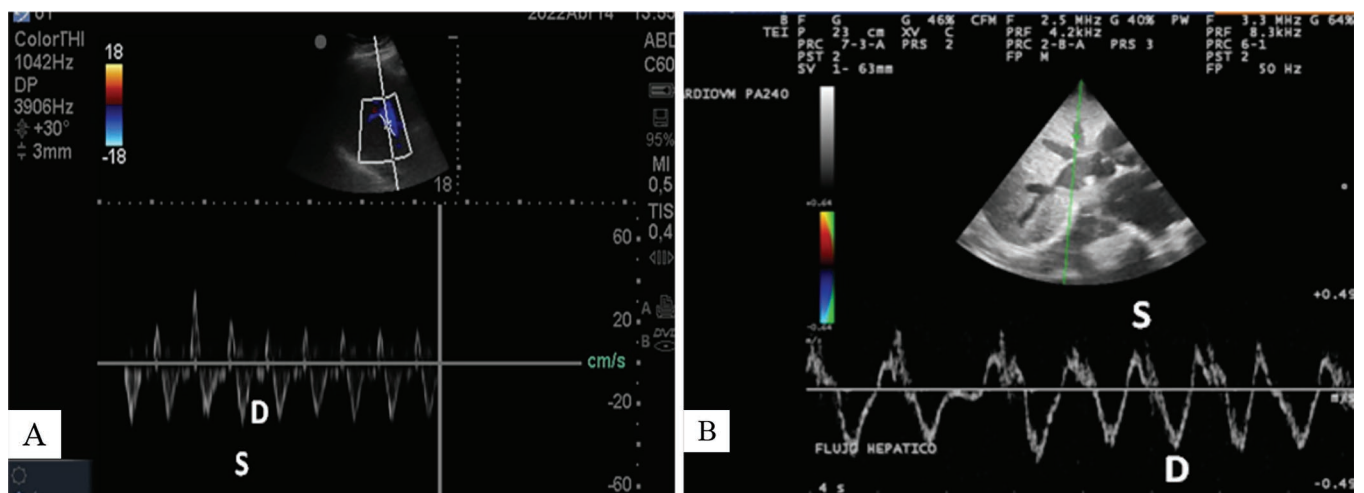
The hepatic veins (right, middle and left) are observed as anechoic tubular structures that converge in the inferior cava vein. Its normal Doppler appearance is a triphasic flow pattern reflecting the physiological changes of the cardiac cycle; there are two negative waves, the S wave (systolic) and the D wave (diastolic) in a relation S>D followed by a small positive (reverse) wave corresponding to atrial systole. Congestion is considered mild when the systolic phase is smaller than the diastolic phase (S<D) and severe when the normal negative systolic phase (S) turns into positive reverse<sup>27</sup> (Figure 5).

### Portal vein

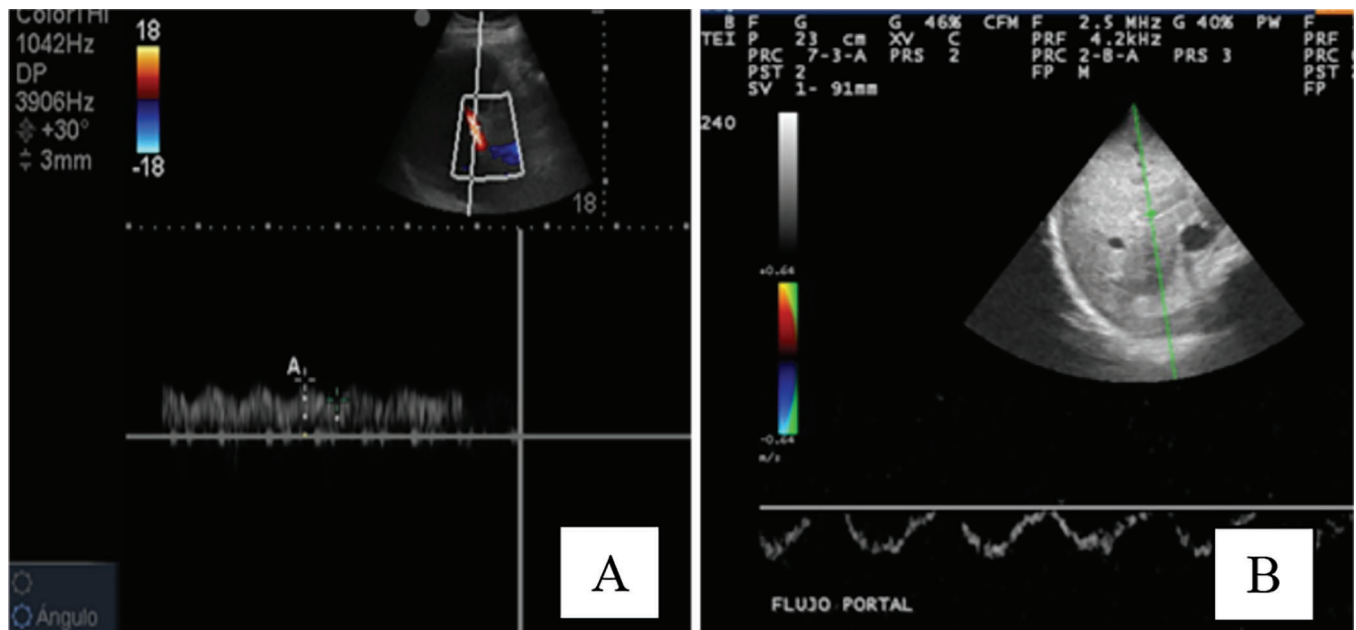
The portal vein has a normal diameter of 13 mm, which increases by up to 20% on deep inspiration; its flow is hepatopetal, slightly undulating, laminar and varies with respiratory movements (velocity, 20–30 cm/s). Normally, there is no pulsatility but, as venous congestion increases, pulsatility increases<sup>28</sup> (Figure 6). This parameter can be estimated through the pulsatility fraction (PF), which is calculated knowing the values of maximum ( $V_{max}$ ) and minimum velocity ( $V_{min}$ ) by using the following formula:<sup>24</sup>

$$PF = \frac{V_{max} - V_{min}}{V_{max}} \times 100$$

Figure 5. Venous ultrasound – suprahepatic vein flow.



The normal suprahepatic vein flow has a triphasic pattern with a negative S wave (systolic) followed by another negative D wave (diastolic) and then, by a small positive or reverse wave corresponding to atrial systole. **a** | Mild congestive pattern: when the S wave is smaller than D wave (S<D). **b** | Severe congestion pattern: when a reverse systolic phase (positive S) is present.<sup>27</sup>

**Figure 6. Venous ultrasound–portal venous flow evaluation.**

Portal venous flow is hepatopetal, slightly undulating (varies with respiratory movements) and normally it does not present any pulsatility. Venous congestion is characterized by the presence of pulsatility measured by the pulsatility fraction (PF).<sup>24</sup>  
**a** | PF: 30–49% indicates mild congestion **b** | PF: >50% indicates severe congestion.

where a PF of <30% is considered normal, of 30–49% is considered as mild congestion and of >50% is considered severe congestion.<sup>24</sup>

### Intrarenal veins

This assessment is probably the most difficult because intrarenal veins are quite small and their localization is difficult due to the respiratory movements. To find the interlobar vessels, the ideal corticomedullary junction is located and intrarenal flow is measured during two or three cardiac cycles at the end of expiration.<sup>25</sup>

The intrarenal venous pattern is normally continuous but, as venous congestion increases, the systolic phase decreases; mild congestion exhibits a discontinuous biphasic pattern (systolic and diastolic phase) whilst severe congestion presents a monophasic diastolic pattern<sup>24</sup> (Figure 7).

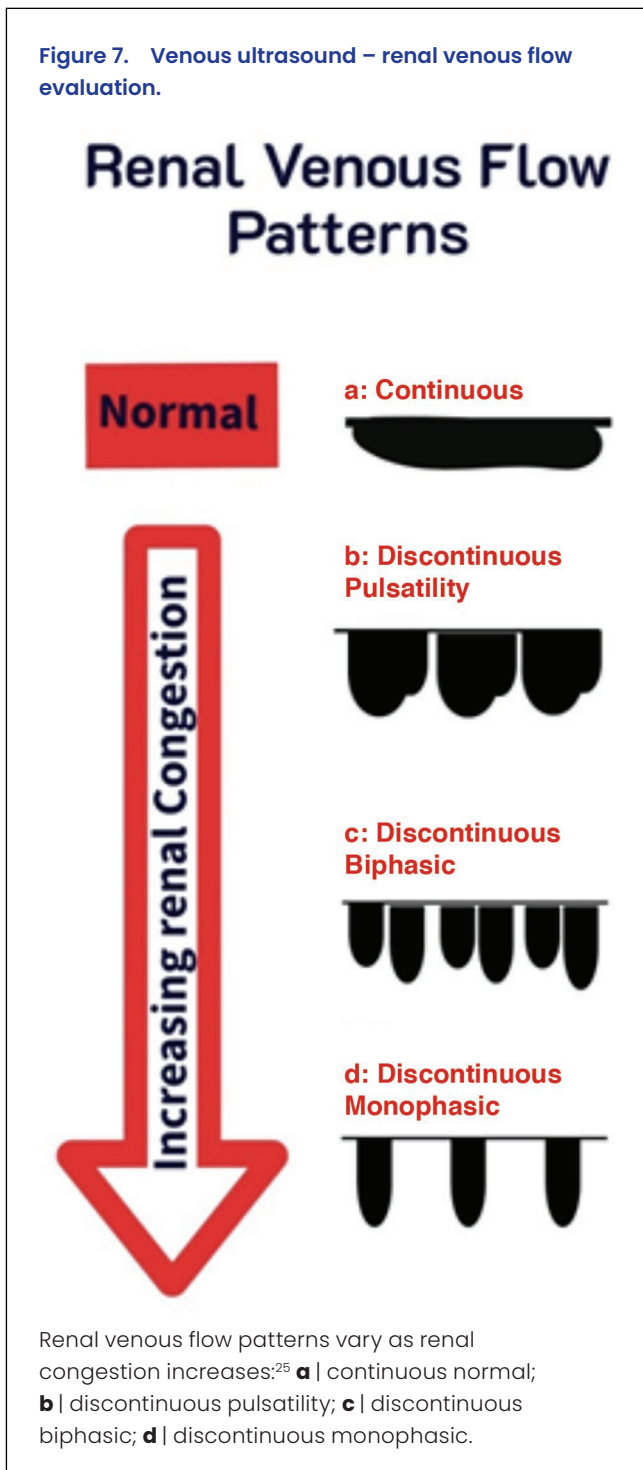
The utilization of a single echographic parameter for diagnostic and prognostic purposes or to determine fluid overload could be very limited in critically ill patients. Therefore, a multisite ultrasound exploration (IVC, internal jugular vein, suprahepatic, portal and intrarenal) can allow the detection of elevated venous pressures; additionally, these techniques could be complemented with echocardiography and LU for a more accurate and better assessment of these patients.<sup>24,25</sup>

## Advanced echocardiography diagnostic algorithm

Advanced echocardiography requires a higher level of specific training and technique based on the uses of full-range two-dimensional views and Doppler measurements.<sup>9</sup> These tools allow a more complex assessment of ventricular function, valve integrity, intravascular volume condition, pericardial effusion (tamponade) detection, and certain hemodynamic parameters such as cardiac output, LV end-diastolic pressure, pulmonary artery pressures (systolic, mean and diastolic), right atrial pressure, and vascular and systemic resistance<sup>14</sup> (Figure 8). Echocardiography allows an indirect and non-invasive (bedside) estimation of these haemodynamic parameters providing clinical information of similar quality to that obtained with right heart catheterization.<sup>29</sup> In this context, in-hospital mortality was elevated in patients with the following characteristics: LVEF <40%, cardiac index <1.8 L/min/m<sup>2</sup>, stroke volume index <35 mL/m<sup>2</sup>, cardiac power output <0.6 W, or medial early mitral valve inflow velocity to early diastolic annular velocity ( $E/e'$ ) ratio >15.<sup>13</sup>

Patients in advanced CS stages (C and D) will probably require more complex therapeutic measures, including inotropes, mechanical respiratory assistance, or temporary mechanical circulatory support devices and, in this

**Figure 7. Venous ultrasound – renal venous flow evaluation.**



echocardiography can guide device positioning, adjust control parameters (revolutions per minute), identify possible complications and assess the optimal weaning time.<sup>21</sup> In a bridge to recovery, weaning is recommended when ejection fraction is >35% associated with a velocity time integral of the LV outflow tract >15 cm/s in a context of a minimum ECMO flow of <1.5 L/min or 1500 rpm.<sup>32</sup>

The evaluation of RV function by using parameters such as tricuspid valve tissue Doppler (S' tricuspid) and tricuspid annular plane systolic excursion as well as estimating right-sided filling pressure can also be as important in the weaning process. Kim et al.<sup>33</sup> suggested evaluating the improvement of the lateral e' and tricuspid annular S' velocities to achieve successful device removal; the improvement of these parameters accounts for biventricular function recovery in patients with CS.<sup>33–35</sup>

Although there have been advances in the echocardiographic evaluation of weaning from ECMO and other short-term circulatory assistance devices, such as aortic balloon counterpulsation or Impella, a complete clinical appraisal of these unstable remains the best way to assess the progression of disease and readiness for device removal.<sup>36</sup>

## Discussion

The aetiological identification of CS can be extremely difficult because many causes exhibit a similar clinical presentation.<sup>37</sup> In this context, the addition of POCUS to its clinical assessment has been effective in increasing the diagnostic accuracy in patients with CS.

The first POCUS application in patients showing undifferentiated hypotension was reported in 2001 by Rose et al. using three different sonographic sites (cardiac, Morrison's pouch and abdominal aorta).<sup>38</sup> In 2004, Jones et al. reported that an immediate incorporation (minute 0) of an ultrasound protocol *versus* a delayed one (minute 15) resulted in a more precise aetiological diagnosis of adult patients ( $n=184$ ) with symptomatic undifferentiated hypotension.<sup>39</sup>

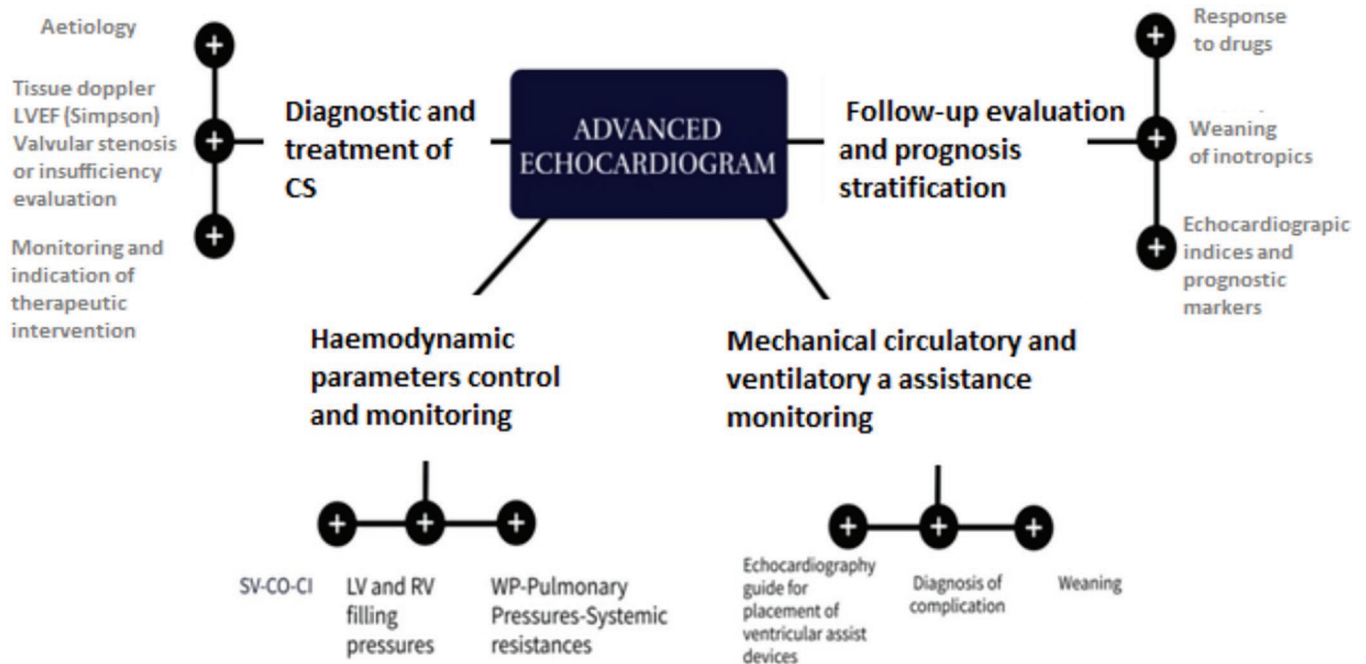
In 2009, Atkinson et al. proposed the 'ACES' protocol that included six ultrasound windows (cardiac, peritoneal, pleural, IVC and aortic view) in order to shorten the diagnosis in patients with undifferentiated hypotension<sup>40</sup> and, in 2010, Perera et al. presented the RUSH protocol that included an extended multisite evaluation (heart, IVC, thoracic and abdominal compartments, large arteries and veins) in three steps: 'pump', 'tank' and 'pipes'.<sup>41</sup> Thus, both protocols basically proposed a useful, reproducible and systematized use of ultrasound in patients with hypotension or CS.

context, echocardiogram can provide valuable haemodynamic data for the weaning process.<sup>30,31,32</sup> For example, certain diastolic dysfunction parameters ( $E/e'$  ratio >14 or a pseudonormal or restrictive transmitral pattern) are associated with a failure weaning from ventilatory support.<sup>32</sup>

In the case of using temporary circulatory assist devices (venous-arterial extracorporeal membrane oxygenation (ECMO), LV Impella or intra-aortic balloon pump) in patients with CS (bridge to transplantation or recovery),

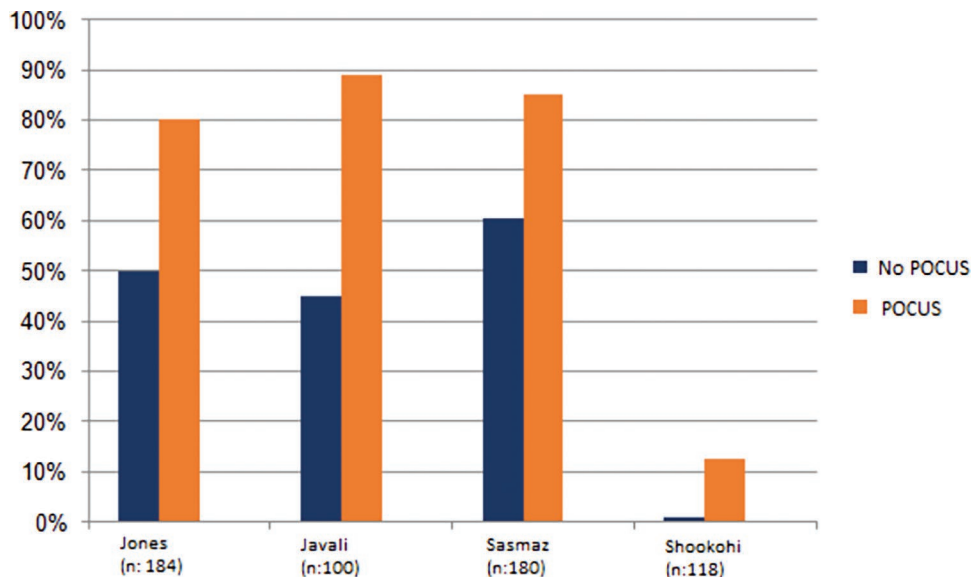


Figure 8. Advanced echocardiography approach.



An advanced echocardiography approach involves the analysis of left and right ventricular diameters, walls motility, systolic and diastolic function, valve structure and function, and haemodynamic measures of volume, pressure and resistance.<sup>14</sup> CI, cardiac index; CO, cardiac output; LV, left ventricle; LVEF, left ventricle ejection fraction; RV, right ventricle; SV, stroke volume; WP, wedge pressure.

Figure 9. Diagnostic accuracy of point-of-care ultrasound (POCUS) versus no-POCUS.



Systematic review to compare POCUS against standard practice regarding diagnostic accuracy in patients with undifferentiated shock in the emergency department. In three studies, the result was statistically significant.<sup>49</sup> No-POCUS versus POCUS: Jones et al., 50% versus 80%; Javali et al., 45% versus 89%; Sasmaz et al., 61% versus 85%; Shookohi et al., 1% versus 13%. The use of POCUS in patients with hypotension in the emergency department improved the diagnostic accuracy of the shock type and final diagnosis when compared to the standard care group.

In another prospective experience published in 2013, Volpicelli et al. showed that a clinical diagnosis guided by POCUS was more accurate considering the final retrospective diagnostic review (Cohen's kappa coefficient, 0.710; 95% CI 0.614–0.806;  $p < 0.0001$ ) in adult patients ( $n=108$ ) presenting symptomatic hypotension of uncertain aetiology.<sup>42</sup>

In a further prospective study published in 2015, Ghane et al. found that the RUSH protocol resulted in a satisfactory concordance between the initial and final diagnosis (Cohen's kappa coefficient=0.7;  $p=0.000$ ) in a cohort of patients ( $n=52$ ) with CS. This study also showed that ultrasound reached 100% sensitivity for hypovolaemic and obstructive shock and 91.7% sensitivity for CS with 100% specificity for all types of shock.<sup>43</sup>

In a prospective observational study also published in 2015, Shokoohi et al. showed that the early use of POCUS in patients with hypotension ( $n=118$ ) improves diagnostic guidance. The ultrasound protocol revealed a high degree of concordance with the final diagnosis (Cohen's kappa coefficient=0.80) and exhibited a significant increase in the final diagnostic accuracy (from 0.8% to 12.7%).<sup>44</sup>

In another prospective experience published in 2017 and conducted in adult patients presenting with hypotension or CS, POCUS was also found to be concordant with the final diagnosis in 85.0% ( $n=153$ ) of 180 patients included in the study ( $p < 0.001$ ).<sup>45</sup>

An additional prospective experience published in 2018 in patients with CS admitted to ICU ( $n=100$ ), POCUS exhibited (within 1 hour of admission) an overall good agreement (Cohen's kappa coefficient  $\geq 0.6$ ) with the clinical diagnosis in identifying the type of shock. In this cohort, POCUS showed the maximum sensitivity, specificity, negative and positive predictive values in the setting of obstructive shock.<sup>46</sup>

In a prospective study published in 2020, Javali et al. highlighted the value of adding POCUS to the initial clinical assessment ( $n=100$ ). In this study, the combined accuracy of both was 89% (Cohen's kappa coefficient=0.89) whilst diagnoses based on clinical assessment alone and POCUS alone were precise in only 45% and 47% of patients.<sup>47</sup>

Finally, the diagnostic accuracy of POCUS in patients with undifferentiated shock was assessed in a very recent (2022) systemic review that included six studies with a total of 852 patients (mean age varied from 52 to 63 years). Two studies were randomized controlled trials, two had a prospective before–after design, one was a post hoc analysis (prospective trial) and the last was a prospective explorative study. The analysis showed that POCUS improved the general diagnostic quality and aetiological diagnostic certainty of patients with CS in comparison with clinical evaluation without using POCUS (Figure 9). No differences were observed regarding the use of POCUS on volume replacement therapy or inotropic management of individuals with CS.<sup>48</sup>

## Conclusion

CS represents the superlative expression of acute HF clinical presentations and patients with CS have a high mortality that persists to date even despite the therapeutic advanced achieved. In this setting, POCUS is an invaluable tool to approach individuals with CS in order to obtain an accurate diagnosis and to favour proper clinical management. In consequence, we believe that the emergency department or ICU physician/clinician should be trained to handle different ultrasound techniques (from basic to advanced ones) to cover different aspects (diagnosis, prognosis, placement or removal of temporary mechanical circulatory support devices, etc.). Therefore, POCUS undoubtedly represents an effective and advantageous tool in the clinical approach and management of patients with CS.

**Contributions:** MR, MSM and EK prepared the manuscript. HP collaborated with the images. WK guided the orientation of the manuscript. AB and SP reviewed the manuscript. All named authors meet the International Committee of Medical Journal Editors (ICMJE) criteria for authorship for this article, take responsibility for the integrity of the work as a whole and have given their approval for this version to be published.

**Disclosure and potential conflicts of interest:** The authors declare that they have no conflicts of interest relevant to this manuscript. The International Committee of Medical Journal Editors (ICMJE) Potential Conflicts of Interests form for the authors is available for download at: <https://www.drugsincontext.com/wp-content/uploads/2022/09/dic.2022-5-8-COI.pdf>

**Acknowledgements:** None.

**Funding declaration:** There was no funding associated with the preparation of this article.

**Copyright:** Copyright © 2023 Ruben M, Molinas MS, Paladini H, Khalife W, Barbagelata A, Perrone S, Kaplinsky E. Published by *Drugs in Context* under Creative Commons License Deed CC BY NC ND 4.0, which allows anyone to copy, distribute, and transmit the article provided it is properly attributed in the manner specified below. No commercial use without permission.

**Correct attribution:** Copyright © 2023 Ruben M, Molinas MS, Paladini H, Khalife W, Barbagelata A, Perrone S, Kaplinsky E. <https://doi.org/10.7573/dic.2022-5-8>. Published by *Drugs in Context* under Creative Commons License Deed CC BY NC ND 4.0.

**Article URL:** <https://www.drugsincontext.com/emerging-concepts-in-heart-failure-management-and-treatment-focus-on-point-of-care-ultrasound-in-cardiogenic-shock>

**Correspondence:** Mariela Ruben, Cardiology Service, MIT Group, Avenida Freyre 3074, Zip code 3000, Santa Fe, Argentina. Email: [marielaruben.45@gmail.com](mailto:marielaruben.45@gmail.com)

**Provenance:** Invited; externally peer reviewed.

**Submitted:** 31 May 2022; **Accepted:** 26 July 2022; **Published:** 4 January 2023.

*Drugs in Context* is published by BioExcel Publishing Ltd. Registered office: 6 Green Lane Business Park, 238 Green Lane, New Eltham, London, SE9 3TL, UK.

BioExcel Publishing Limited is registered in England Number 10038393. VAT GB 252 7720 07.

For all manuscript and submissions enquiries, contact the Editorial office [editorial@drugsincontext.com](mailto:editorial@drugsincontext.com)

For all permissions, rights and reprints, contact David Hughes [david.hughes@bioexcelpublishing.com](mailto:david.hughes@bioexcelpublishing.com)

## References

1. Hochman JS, Sleeper LA, Webb JG, et al. Early revascularization in acute myocardial infarction complicated by cardiogenic SHOCK. SHOCK Investigators. Should we emergently revascularize occluded coronaries for cardiogenic shock. *N Engl J Med*. 1999;341(9):625–634. <https://doi.org/10.1056/NEJM199908263410901>
2. Maggioni AP, Dahlstrom U, Filippatos G, et al. Heart Failure Association of ESC (HFA). EURObservational research programme: the heart failure pilot survey (ESC-HF Pilot). *Eur J Heart Fail*. 2010;12:1076–1108. <https://doi.org/10.1093/eurjhf/hfq154>
3. Follath F, Yilmaz MB, Delgado JF, et al. Clinical presentation, management and outcomes in the Acute Heart Failure Global Survey of Standard Treatment (ALARM-HF). *Intensive Care Med*. 2011;37:619–626. <https://doi.org/10.1007/s00134-010-2113-0>
4. Spinar J, Parenica J, Vitovec J, et al. Baseline characteristics and hospital mortality in the Acute Heart Failure Database (AHEAD) main registry. *Crit Care*. 2011;15(6):R291. <https://doi.org/10.1186/cc10584>
5. Oliva F, Mortara A, Cacciatore G, et al. Acute heart failure patient profiles, management and in-hospital outcome: results of the Italian Registry on Heart Failure Outcome. *Eur J Heart Fail*. 2012;14:1208–1217. <https://doi.org/10.1093/eurjhf/hfs117>
6. Chioncel O, Parissis J, Mebazaa A, et al. Epidemiology, pathophysiology and contemporary management of cardiogenic shock—a position statement from the Heart Failure Association of the European Society of Cardiology. *Eur J Heart Fail*. 2020;22(8):1315–1341. <https://doi.org/10.1002/ejhf.1922>
7. Furer A, Wessler J, Burkhoff D. Hemodynamics of cardiogenic shock. *Interv Cardiol Clin*. 2017;6:359–371. <https://doi.org/10.1016/j.iccl.2017.03.006>
8. Baran DA, Grines CL, Bailey S, et al. SCAI Clinical expert consensus statement on the classification of cardiogenic shock: this document was endorsed by the American College of Cardiology (ACC), the American Heart Association (AHA), the Society of Critical Care Medicine (SCCM), and the Society of Thoracic Surgeons (STS) in April 2019. *Catheter Cardiovasc Interv*. 2019;94(1):29–37. <https://doi.org/10.1002/ccd.28329>
9. Vieillard-Baron A, Millington SJ, Sanfilippo F, et al. A decade of progress in critical care echocardiography: a narrative review. *Intensive Care Med*. 2019;45(6):770–788. <https://doi.org/10.1007/s00134-019-05604-2>

10. Porter TR, Shillcutt SK, Adams MS, et al. Guidelines for the use of echocardiography as a monitor for therapeutic intervention in adults: a report from the American Society of Echocardiography. *J Am Soc Echocardiogr*. 2015;28(1):40–56. <https://doi.org/10.1016/j.echo.2014.09.009>
11. Bansal M, Ranjan S. Echocardiography in the management of cardiogenic shock. *Indian J Clin Cardiol*. 2020;1(1):20–30. <https://doi.org/10.1177/2632463619897849>
12. Picard MH, Davidoff R, Sleeper LA, et al. Echocardiographic predictors of survival and response to early revascularization in cardiogenic shock. *Circulation*. 2003;107(2):279–284. <https://doi.org/10.1161/01.cir.0000045667.11911.f6>
13. Jentzer JC, Wiley BM, Anavekar NS, et al. Noninvasive hemodynamic assessment of shock severity and mortality risk prediction in the cardiac intensive care unit. *JACC Cardiovasc Imaging*. 2021;14(2):321–332. <https://doi.org/10.1016/j.jcmg.2020.05.038>
14. Azcarate Ayuela JM, Terré Clau F, Ochagavia A, Pereira Vicho R. Role of echocardiography in the hemodynamic monitorization of critical patients. *Med Intensiva*. 2012;36(3):200–232. <https://doi.org/10.1016/j.medin.2011.11.025>
15. McLean AS. Echocardiography in shock management. *Crit Care*. 2016;20:275. <https://doi.org/10.1186/s13054-016-1401-7>
16. Albaeni A, Sharma M, Ahmad M, Khalife WI. Accurate estimation of right-filling pressure using handheld ultrasound score in patients with heart failure. *Am J Med*. 2022;135(5):634–640. <https://doi.org/10.1016/j.amjmed.2021.11.020>
17. Lancellotti P, Price S, Edvardsen T, et al. The use of echocardiography in acute cardiovascular care: recommendations of the European Association of Cardiovascular Imaging and the Acute Cardiovascular Care Association. *Eur Heart J Cardiovasc Imaging*. 2015;16(2):119–146. <https://doi.org/10.1093/ehjci/jeu210>
18. Himelman RB, Kircher B, Rockey DC, Schiller NB. Inferior vena cava plethora with blunted respiratory response: a sensitive echocardiography sign of cardiac tamponade. *J Am Coll Cardiol*. 1988;12(6):1470–1477. [https://doi.org/10.1016/s0735-1097\(88\)80011-1](https://doi.org/10.1016/s0735-1097(88)80011-1)
19. Picano E, Scali MC, Ciampi Q, Lichtenstein D. Lung ultrasound for the cardiologist. *JACC Cardiovasc Imaging*. 2018;11(11):1692–1705. <https://doi.org/10.1016/j.jcmg.2018.06.023>
20. Claire-Del Granado R, Mehta RL. Fluid overload in the ICU: evaluation and management. *BMC Nephrol*. 2016;17(1):109. <https://doi.org/10.1186/s12882-016-0323-6>
21. Price S, Platz E, Cullen L, et al. Acute Heart Failure Study Group of the European Society of Cardiology Acute Cardiovascular Care Association. Expert consensus document: echocardiography and lung ultrasonography for the assessment and management of acute heart failure. *Nat Rev Cardiol*. 2017;14(7):427–440. <https://doi.org/10.1038/nrcardio.2017.56>
22. Milojevic I, Lemma K, Khosla R. Ultrasound use in the ICU for interventional pulmonology procedures. *J Thorac Dis*. 2021;13(8):5343–5361. <https://doi.org/10.21037/jtd-19-3564>
23. Ponikowski P, Voors AA, Anker SD, et al. ESC Scientific Document Group. 2016 ESC guidelines for the diagnosis and treatment of acute and chronic heart failure: the task force for the diagnosis and treatment of acute and chronic heart failure of the European Society of Cardiology (ESC). Developed with the special contribution of the Heart Failure Association (HFA) of the ESC. *Eur Heart J*. 2016;37(27):2129–2200. <https://doi.org/10.1093/eurheartj/ehw128>
24. Beaubien-Souligny W, Rola P, Haycock K, et al. Quantifying systemic congestion with point-of-care ultrasound: development of the venous excess ultrasound grading system. *Ultrasound J*. 2020;12(1):16. <https://doi.org/10.1186/s13089-020-00163-w>
25. Pellicori P, Platz E, Dauw J, et al. Ultrasound imaging of congestion in heart failure: examinations beyond the heart. *Eur J Heart Fail*. 2021;23(5):703–712. <https://doi.org/10.1002/ejhf.2032>
26. Ikeda Y, Ishii S, Yazaki M, et al. Portal congestion and intestinal edema in hospitalized patients with heart failure. *Heart Vessels*. 2018;33(7):740–751. <https://doi.org/10.1007/s00380-018-1117-5>
27. Koratala A. Venous congestion assessment using point-of-care Doppler ultrasound: welcome to the future of volume status assessment. *Clin Case Rep*. 2021;9(3):1805–1807. <https://doi.org/10.1002/ccr3.3840>
28. Denault AY, Azzam MA, Beaubien-Souligny W. Imaging portal venous flow to aid assessment of right ventricular dysfunction. *Can J Anesth*. 2018;65:1260–1261. <https://doi.org/10.1007/s12630-018-1125-z>
29. Nagueh SF, Smiseth OA, Appleton CP, et al. Recommendations for the evaluation of left ventricular diastolic function by echocardiography: an update from the American Society of Echocardiography and the European Association of Cardiovascular Imaging. *Eur Heart J Cardiovasc Imaging*. 2016;17(12):1321–1360. <https://doi.org/10.1093/ehjci/jew082>
30. Hameed AK, Gosal T, Fang T, et al. Clinical utility of tissue Doppler imaging in patients with acute myocardial infarction complicated by cardiogenic shock. *Cardiovasc Ultrasound*. 2008;6:11. <https://doi.org/10.1186/1476-7120-6-11>



31. Stainback RF, Estep JD, Agler DA, et al. Echocardiography in the management of patients with left ventricular assist devices: recommendations from the American Society of Echocardiography. *J Am Soc Echocardiogr*. 2015;28(8):853–909. <https://doi.org/10.1016/j.echo.2015.05.008>
32. Muñoz-Rodríguez R, García-González MJ, Jorge-Pérez P, et al. Ultrasound assessment in cardiogenic shock weaning: a review of the state of the art. *J Clin Med*. 2021;10(21):5108. <https://doi.org/10.3390/jcm10215108>
33. Kim D, Jang WJ, Park TK, et al. Echocardiographic predictors of successful extracorporeal membrane oxygenation weaning after refractory cardiogenic shock. *J Am Soc Echocardiogr*. 2021;34(4):414–422.e4. <https://doi.org/10.1016/j.echo.2020.12.002>
34. Nanjayya VB. Response to “echocardiographic predictors of successful extracorporeal membrane oxygenation weaning after refractory cardiogenic shock”. *J Am Soc Echocardiogr*. 2022;35(1):134. <https://doi.org/10.1016/j.echo.2021.07.014>
35. Essandoh M, Graul T, Awad H. Venoarterial extracorporeal membrane oxygenation weaning in refractory cardiogenic shock—echocardiographic guidance may improve success. *J Am Soc Echocardiogr*. 2022;35(1):134–135. <https://doi.org/10.1016/j.echo.2021.10.007>
36. Randhawa VK, Al-Fares A, Tong MZY, et al. A pragmatic approach to weaning temporary mechanical circulatory support: a state-of-the-art review. *JACC Heart Fail*. 2021;9(9):664–673. <https://doi.org/10.1016/j.jchf.2021.05.011>
37. Elmer J, Noble VE. An evidence-based approach for integrating bedside ultrasound into routine practice in the assessment of undifferentiated shock. *ICU Director*. 2010;1(3):163–174. <https://doi.org/10.1177/1944451610369150>
38. Rose JS, Bair AE, Mandavia D, Kinser DJ. The UHP ultrasound protocol: a novel ultrasound approach to the empiric evaluation of the undifferentiated hypotensive patient. *Am J Emerg Med*. 2001;19(4):299–302. <https://doi.org/10.1053/ajem.2001.24481>
39. Jones AE, Tayal VS, Sullivan DM, Kline JA. Randomized, controlled trial of immediate versus delayed goal-directed ultrasound to identify the cause of nontraumatic hypotension in emergency department patients. *Crit Care Med*. 2004;32(8):1703–8. <https://doi.org/10.1097/01.ccm.0000133017.34137.82>
40. Atkinson PR, McAuley DJ, Kendall RJ, et al. Abdominal and Cardiac Evaluation with Sonography in Shock (ACES): an approach by emergency physicians for the use of ultrasound in patients with undifferentiated hypotension. *Emerg Med J*. 2009;26(2):87–91. <https://doi.org/10.1136/emj.2007.056242>
41. Perera P, Mailhot T, Riley D, Mandavia D. The RUSH exam: rapid ultrasound in shock in the evaluation of the critically ill. *Emerg Med Clin North Am*. 2010;28(1):29–56. <https://doi.org/10.1016/j.emc.2009.09.010>
42. Volpicelli G, Lamorte A, Tullio M, et al. Point-of-care multiorgan ultrasonography for the evaluation of undifferentiated hypotension in the emergency department. *Intensive Care Med*. 2013;39(7):1290–1298. <https://doi.org/10.1007/s00134-013-2919-7>
43. Ghane MR, Gharib M, Ebrahimi A, et al. Accuracy of early rapid ultrasound in shock (RUSH) examination performed by emergency physician for diagnosis of shock etiology in critically ill patients. *J Emerg Trauma Shock*. 2015;8(1):5–10. <https://doi.org/10.4103/0974-2700.145406>
44. Shokoohi H, Boniface KS, Pourmand A, et al. Bedside ultrasound reduces diagnostic uncertainty and guides resuscitation in patients with undifferentiated hypotension. *Crit Care Med*. 2015;43(12):2562–2569. <https://doi.org/10.1097/CCM.0000000000001285>
45. Sasmaz MI, Gungor F, Guven R, et al. Effect of focused bedside ultrasonography in hypotensive patients on the clinical decision of emergency physicians. *Emerg Med Int*. 2017;2017:6248687. <https://doi.org/10.1155/2017/6248687>
46. Vaidya T, D’costa P, Pande S. Role of ultrasound in evaluation of undifferentiated shock in ICU settings. *J Assoc Physicians India*. 2018;66(8):13–17.
47. Javali RH, Loganathan A, Srinivasarangan M, et al. Reliability of emergency department diagnosis in identifying the etiology of nontraumatic undifferentiated hypotension. *Indian J Crit Care Med*. 2020;24(5):313–320. <https://doi.org/10.5005/jp-journals-10071-23429>
48. Berg I, Walpot K, Lamprecht H, et al. A systemic review on the diagnostic accuracy of point-of-care ultrasound in patients with undifferentiated shock in the emergency department. *Cureus*. 2022;14(3):e23188. <https://doi.org/10.7759/cureus.23188>