

Lateral transperitoneal laparoscopic management for paragangliomas in para-aortic position: Surgical experience from case reports of three patients

Ngoc Hung Nguyen¹, Huy Du Nguyen², Hai Dang Do², Tuan Hiep Luong^{2*}, Thanh Khiem Nguyen¹

¹Gastrointestinal and Hepato-Biliary-Pancreatic Surgery Department, Bach Mai Hospital

²Department of Surgery, Hanoi Medical University

Received 14 January 2022; accepted 4 April 2022

Abstract:

Paragangliomas are a type of neuroendocrine tumour with catecholamine secretion outside of the adrenal medulla. These tumours are frequently found in the para-aortic region, which makes them difficult to manage laparoscopically. We herein present a case report of three patients with paragangliomas in a difficult superior para-aortic position. All cases had symptoms of catecholamine release with uncontrolled episodic hypertension and had their tumours successfully removed by transperitoneal laparoscopic management. We have found this method to be a suitable approach because it reveals a wide surgical field and a view over all organs, especially blood vessels around the tumour. Although blood and urine dopamine and noradrenaline levels were not measured postoperatively, all three patients were discharged without complication and they did not display any more clinical symptoms. Lateral transperitoneal laparoscopic surgery provided a wide field of view, which clearly revealed the tumour and surrounding components indicating it is one of the safest and most effective approaches, especially for paragangliomas adjacent to large blood vessels.

Keywords: case report, laparoscopic, lateral transperitoneal, paragangliomas.

Classification number: 3.2

Introduction

Paraganglioma is a rare type of neuroendocrine tumour with an incidence of 0.0005-0.1% of the population and is most commonly found during the third through fifth decades of life in women [1, 2]. Tumours located outside the adrenal glands mainly secrete catecholamines and may have an origin of adrenal medulla (pheochromocytoma) or not (paraganglioma). Genetic factors account for about 25% of cases and most commonly in bilateral tumours [3]. The specific clinical symptoms, which are called fight-or-flight sympathetic symptoms, occur due to increased release of catecholamines including episodic hypertension, heart palpitations, headache, fatigue, and profuse sweating. Of these symptoms, the triad of profuse sweating, heart palpitations, and headache has a sensitive rate of 89% and a specific rate of 67%, which is close to 95% in patients with hypertension [4]. Most of the time, however, this tumour is often discovered incidentally by diagnostic imaging. These tumours are mostly benign, with only a small percentage of malignancies and metastases, and often insensitive to chemotherapy or radiotherapy. Surgical resection is thus the optimal treatment option [3]. Recently, with the development of minimally invasive techniques, laparoscopic surgery has become a new choice due to the

advantages of decreased surgical time and hospital stay as well as a reduced postoperative complication rate. However, because the tumour is often located between the aorta and vena cava, laparoscopic surgery remains a challenge for surgeons [3]. Herein, we report successful laparoscopic surgeries used to treat three patients with paraganglioma located in relatively difficult locations. Our research objectives are aimed at sharing our approach and experiences with paragangliomas in the para-aortic region as well as reviewing the literature on the outcomes of laparoscopic surgery for paraganglionic tumours.

Case presentation

Surgical procedure

In this study, we placed the patient in the lateral position using the intra-abdominal laparoscopic technique.

For tumours located adjacent to or in between the abdominal aorta (AA) and inferior vena cava (IVC), the patient is placed in the left lateral position and the 4 trocars are placed, respectively, as follows: two 10-cm trocars above the umbilical and suprapubic and two 5-cm trocars in the right lumbar region and right iliac region. The patient underwent surgery according to the following procedure: fasciotomy, ascending colon and

*Corresponding author: Email: hiep1995hsgs@gmail.com

mesenteric mobility, descending duodenal dissection, inferior duodenal flexure, and horizontal duodenal dissection (if necessary). Then, reveal and resect the paraganglioma.

For tumours located between the left renal artery and the left renal vein, we had chosen the placement of 4 trocars as follows: two 10-mm trocars were placed just above the umbilical and below the left sternum, and two 5-mm trocars were placed in the right hypochondrium and the left anterior axillary line, respectively. Our surgical procedure was as follows: mobilise the descending colon, splenic flexure, distal pancreas, and spleen; then expose the left renal peduncle. The tumour was found between the renal artery and the renal vein, and a part of the tumour was attached to the left renal vein. Then, dissection was conducted, the tumour dissected, and the infiltrated left renal vein was sutured. In these cases, we chose to place the trocar and the approach was similar to the left adrenalectomy. We successfully performed this procedure in three cases.

Case 1

A male patient, 17 years old, with a history of glomerulonephritis and an appendectomy at 12 years old. The patient was admitted to the hospital because of paroxysmal hypertensive crises 3 months before admission with each episode lasting 5-6 minutes with sweating. The highest blood pressure recorded was 220 mmHg with generalised seizures one day before admission. Physical examination was unremarkable except for a few brief episodes of hypertension during the day. Computed tomography (CT) scans showed a retroperitoneal tumour in front of the AA, at the level of the inferior mesenteric artery, 48x28 mm in size and was clearly demarcated, hyper-enhanced, and possessed central necrosis (Fig. 1). Blood tests showed increased dopamine (328.5 pg/ml) and increased noradrenaline (1177.71 pg/ml) with slightly increased aldosterone, normal cortisol and adrenocorticotropic hormone (ACTH), and normal blood potassium concentration. The patient was then diagnosed with paraganglioma. Intraoperative exploration: The abdomen is dry, the peritoneum is smooth, and there is a tumour measuring 4x5 cm close to the IVC and the AA without invasion. Tumour resection was performed according to the following procedure: The patient lies on the left side with 4 trocars placed, respectively, as follows: two 10-cm trocars above the umbilical and suprapubic and two 5-cm trocars in right lumbar region and right iliac region. The patient underwent surgery according to the following procedure: fasciectomy, ascending colon and mesenteric mobility, extensive exposure of the retroperitoneal space including the aorta, and tumour, meticulous dissection of the tumour from the aorta and IVC. Surgery time was 80 minutes and blood loss was less than 30 ml. The pathological result was pheochromocytoma with pheochromocytoma of the adrenal gland scaled score (PASS) of 5 points. Postoperatively, the patient was stable and discharged without any complications.

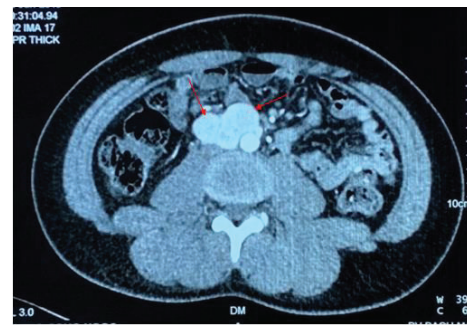

Fig. 1. CT scan showed a retroperitoneal tumour in front of the AA, at the level of the inferior mesenteric artery, with 48x28 mm in size, clearly demarcated, hyper-enhancing, with a central necrosis (red arrows).

Case 2

A male patient, 47 years old, with a history of episodes of paroxysmal hypertensive crisis peaking at 200/150 mmHg over five years but no intervention. In the recent year, the hypertensive crises began to appear more and more severe with an average of 10-15 attacks per day, each attack lasting about one minute, and the highest blood pressure was 275/135 mmHg. Magnetic resonance imaging (MRI) and Positron emission tomography and computed tomography (PET-CT) scans show a lymph-node-like structure of the 3rd and 4th level of the lumbar spine with a size of 23x17 mm, clearly demarcated, and located in between the IVC and the AA (Fig. 2). Blood levels of dopamine, noradrenalin, aldosterone, and cortisol were 112.3 pg/ml, 686 pg/ml, 126 pg/ml (high), and 334.3 nmol/l (normal), respectively. Urine catecholamine test presented a urine dopamine level of 68.1 µg in 24 hours, and increased noradrenaline and adrenaline of 113.3 and 142.2 µg, respectively, in 24 hours. Location of trocar placement and the stages of surgery were similar to the first case. Operating time was 75 minutes and the blood loss was less than 30 ml. The pathological result was paraganglioma with raft-forming cells with large, irregular nuclei. The postoperative process was normal.

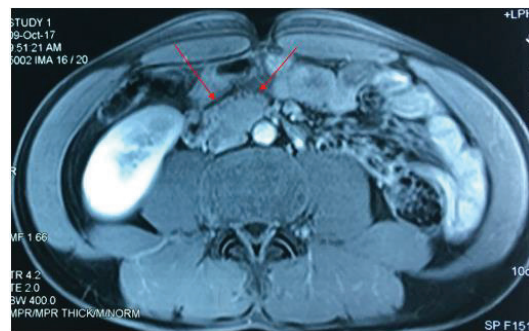


Fig. 2. The MRI scans show the lymph-node-like structure of the lumbar spine 3rd and 4th level with the size of 23x17 mm, located between the inferior vena cava and the AA, clearly demarcated (red arrows).

Case 3

A female patient, 16 years old, with a history of stable polycythaemia vera was admitted to our hospital. The patient presented with intermittent dyspnoea, dizziness, and heart palpitations with the highest blood pressure of 220 mmHg. On the CT scan, two vascular-enhanced masses are seen at the level of the renal hilum and the right and left dimensions were 29 and 15 mm, respectively (Fig. 3). Blood tests showed a normal dopamine level of 84.83 pg/ml, a high noradrenaline level of 1153 pg/ml, a normal adrenaline level of 27.67 pg/ml, and pituitary hormones were within normal limits. After stabilizing medical treatment, the patient underwent surgery in two stages: the first stage was on April 13th, 2021, and the second was on April 19th, 2021. Unlike the above two cases, the tumour was located close to the renal artery and vein, and a part of the tumour was attached to the posterior surface of the renal vein. First, after releasing the splenic flexure and distal pancreas, the surgeon exposed the left renal peduncle, wiggled the renal vein and renal artery, and sutured the infiltrated vein (Fig. 4). Duration of the first surgery was 180 minutes. In the second surgery, a tumour in the renal hilum measuring 2x3 cm with solid density and firmly attached to the posterior genital vein was revealed. After dissecting and releasing the ascending colon, exposing the duodenum, and dissecting the tumour from the posterior genital vein, the tumour was resected. The operation time was 150 minutes and the patient was monitored at the Department of Endocrinology with stable condition after surgery. Postoperative pathological result was paraganglioma.

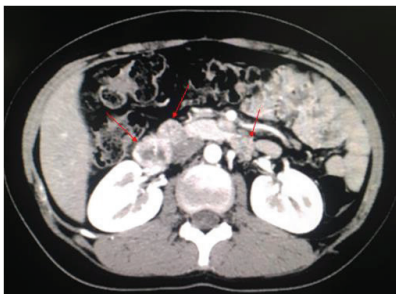


Fig. 3. On the CT scan, two vascular-enhanced masses are seen at the level of the renal hilum, the right and left dimensions are 29 and 15 mm, respectively (red arrows).

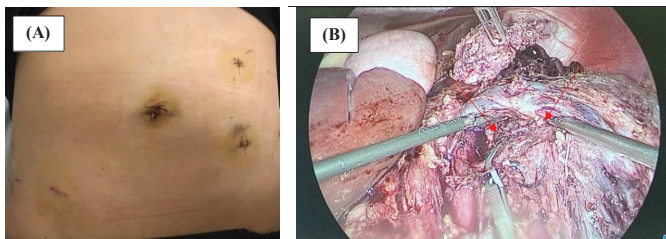


Fig. 4. (A) Trocars' placements; (B) Intraoperative injury: A tumour in the renal hilum measuring 2x3 cm, solid density, firmly attached to the posterior genital vein (black arrows).

Treatment of paraganglioma is a complicated process, and the surgeon also needs to consult and closely coordinate with many other specialties such as endocrinology, cardiology, and anaesthesiology to develop an appropriate strategy. All patients were consulted by an endocrinologist for a definitive diagnosis as well as a cardiologist and anaesthetist to maintain blood pressure pre-, intra-, and post-operatively.

Discussion

Paragangliomas were first described by Pick in 1912 and first operated on in 1937 by Charles Mayo [3]. Through the three reported cases, we found that the most specific symptom was an episodic hypertensive crisis due to increased secretion of catecholamine. About 50-60% of cases will present with headache, heart palpitations, and profuse sweating, and a paroxysmal hypertensive crisis. Depending on the type of tumour, the characteristics of hypertension are different. Of these characteristics, noradrenaline-secreting tumours are often associated with prolonged hypertension, while episodic hypertensive crises are common in both noradrenaline and adrenaline-secreting groups. The estimated malignancy rate is about 15% and the 5-year survival rate ranges from 40 to 85% [5, 6] with paragangliomas having a higher malignancy potential than pheochromocytomas [6]. Although the risk factors for malignancy have not been well identified, some factors predisposed to malignancy are tumour size >5 cm, genetic mutations, failed resection of primary tumour, and presence of synchronous metastases [7]. Therefore, it is necessary to follow-up with patients postoperatively to determine if there is recurrence [8].

Radical resection remains the optimal treatment for paragangliomas. There are different treatment methods such as open surgery, laparoscopic lateral transperitoneal adrenalectomy (LTA), and laparoscopic posterior retroperitoneal adrenalectomy (PRA) [9, 10]. Based on the criteria of surgical time, intraoperative blood loss, pain level, hospital stay, and time to return to normal life, as well as potential complications, most studies have shown that PRA has the advantage. However, recent studies show an equivalent role of these two methods in the treatment of adrenal tumours [11]. Currently, indications for laparoscopic surgery are applied in cases of hormone-secreting tumours such as paraganglioma and other equivalents with tumour size less than 7 cm. For tumour sizes over 7 cm, with highly qualified surgeons capable of endoscopic dissection of related components such as Kocher duodenum endoscopy, colonic motility, etc., laparoscopic management is still possible [12]. Z. Jawad, et al. (2017) reported a successful laparoscopic surgery to remove an 8.2-cm paraganglioma [13].

In this study, we placed the patient in a supine position using the intra-abdominal laparoscopic technique because of the short hospital stay and high efficiency compared to

other methods [14]. Our trocar placement and approach were different from that of X. Ren, et al. (2020) [12]. These authors used four trocars with corresponding positions as follows: 10-mm trocar above the umbilicus, another 10-mm trocar in the epigastric region, one 5-mm trocar in the right hypochondrium, and one 5-mm trocar in the right anterior axillary line. The author's approach to the tumour consisted of the following steps: first, the right hepatic triangular ligament and the hepatocolic ligament were cut, the liver was lifted to expose the upper pole of the right kidney. Then, the mesentery of the ascending colon was dissected and extruded to expose the right kidney and right renal vein followed by dissecting sections D2 and D3 of the duodenum to reveal the tumour. Then, the vessels feeding the tumour were clamped and the tumour resected. Our tumour approach provided a wide field of view, which clearly revealed the tumour and surrounding components, especially the adjacent large blood vessels. In addition, it was possible to fully observe the abdominal viscera to investigate any other abnormalities. This approach is especially beneficial in cases of large tumours and those with vascular invasion. The operating time of our two cases were 80 and 75 minutes, respectively, with very little blood loss of just under 30 ml. This result was better than of [12], which took 120 minutes and 50 ml of blood in surgery. Our patients were in stable condition and did not have any postoperative complications. However, when performing this technique, we also found that there were some difficulties when we had to move many bowel segments such as the ascending colon, the mesentery, and a part of the duodenum to reach the tumour. The risk of injury to intra-abdominal organs is also higher than in the retroperitoneal approach.

For tumours located between the left renal artery and left renal vein, we chose a placement of 4 trocars as follows: two 10-mm trocars were placed just above the umbilical and below the left sternum, and two 5-mm trocars were placed in the right hypochondrium and the left anterior axillary line, respectively. We have found this to be a very suitable approach because it reveals a wide surgical field, which allowed an evaluation of all the organs and especially the blood vessels around the tumour. In our case, the tumour also invaded the left renal vein. Therefore, a wide and clear disclosure would make it easier and safer to remove the tumour and suture the invasive blood vessel. As a result, the intraoperative blood loss, in this case, was 140 ml and the surgery time was 180 minutes. In a study by S. Hattori, et al. (2014) who performed surgery on 9 cases of paragangliomas, the operation time was 189.8 ± 44.9 minutes and the intraoperative blood loss was about 404.9 to 1036.3 ml [15]. It can be seen that our surgery time was similar, but we had a much lower amount of blood loss intraoperatively compared to this study. However, choosing this approach will make it difficult for the surgeon to reveal the tumour when

moving the colon, spleen, and especially the distal pancreas. All manipulations have the risk of damaging organs and causing complications intra- and post-operatively.

Paraganglioma often occurs around the great vessels in the retroperitoneum and the location of the tumour significantly affects the difficulty of procedure. T. Hakariy, et al. (2019) [16] reported a case of paraganglioma located posterior to the IVC and bilateral renal veins. In that study, five trocars were placed in the abdomen as follows: one 10-mm trocar above the umbilicus and proximal to the right white line for camera placement, two 12-mm trocars placed below the right costal margin deviated to the sternal and in the longitudinal side of the right white line with the level of the umbilicus, and two 5-mm trocars placed in the right anterior axillary line, respectively. The process of approaching the tumour: dissection of the tumour from the underside of the liver, dissection of the tumour from the right renal vein, left renal vein, right kidney, and AA. It was identified that there were two veins going from the tumour that drained into the IVC, then resection was performed. The tumour was separated from the AA and the two arteries supplying the tumour were cut off; then, dissection of the tumour from the renal artery continued. Finally, the tumour was released from the IVC and completely removed from the surrounding surgery. In this case, the most difficult and dangerous step in the surgical procedure was dissecting the tumour from the IVC. Therefore, in order to safely release it, the author dissected tissue surrounding the tumour and achieved tumour mobility before separating the tumour from the IVC. In addition, the tumour was located between the right renal vein and the right renal artery. These vessels were all dissected from the tumour intact. The operation time was 231 minutes, and the blood loss was about 200 ml. The tumour was located behind many large blood vessels, and, although many reports suggest that the retroperitoneal approach is feasible, safer, and faster, the authors chose the transperitoneal approach instead of the retroperitoneal approach because it can provide a wide surgical field and make it easy to realise the anatomical relationship between the tumour and the surrounding components in the abdominal cavity. If necessary, this approach can be converted to open surgery.

It is important to control blood pressure pre-, peri- and post-operatively. Patients should be given anti-alpha- or beta-adrenergic drugs in preoperative preparation [17]. One note to the surgeons is to limit the impact on the tumour hemodynamically by ligating the adrenal vein early. According to N. Rao, et al. (2016) [18], the rate of using antihypertensive drugs after surgery depends on the number of episodes of hypertension and the degree of impact on the adrenal gland during surgery. Anaesthesiologists need to coordinate with surgeons to use invasive arterial blood pressure or

antihypertensive drugs during the procedure. Intraoperative hemodynamic instabilities typically include hypertension before tumour removal and hypotension after tumour isolation. Because of this, the American Society of Anaesthesiologists recommends using central venous access and invasive blood pressure (IBP) monitoring. Hypertension and bradycardia/tachycardia due to norepinephrine (NE) secretion should be managed with short-acting and potent vasodilators such as sodium nitroprusside and nitroglycerine or esmolol, a short-acting beta-receptor antagonist [17]. After ligation of the adrenal veins and tumour removal, many patients may experience a sudden drop in blood pressure (hypotension) and may require vasopressor support. Indeed, treatment of paraganglioma is a complicated process and it is imperative that the surgeon consult and closely coordinate with many specialties such as endocrinology, cardiology, and anaesthesiology to form an appropriate strategy [19].

Conclusions

Paraganglioma is a rare disease that is located frequently in para-aortic region, which makes it difficult to manage laparoscopically. However, lateral transperitoneal laparoscopic surgery is a safe and effective treatment, especially for tumours in difficult locations. Our tumour approach provides a wide field of view, which clearly reveals the tumour and surrounding components, especially adjacent large blood vessels. In addition, full observation of the abdominal viscera is another advantage of this method, which can be used to investigate any other abnormalities in the region. The treatment of paraganglioma requires the coordination of endocrinologists, cardiologists, surgeons, and anaesthesiologists for the most appropriate treatment strategy and follow-up.

COMPETING INTERESTS

The authors declare that there is no conflict of interest regarding the publication of this article.

REFERENCES

- [1] E.A. Mittendorf, et al. (2007), "Pheochromocytoma: Advances in genetics, diagnosis, localization, and treatment", *Hematology/Oncology Clinics of North America*, **21(3)**, pp.509-525.
- [2] L.C. Pederson, J.E. Lee (2003), "Pheochromocytoma", *Current Treatment Options in Oncology*, **4(4)**, pp.329-337.
- [3] H.P.H. Neumann, W.F. Young, C. Eng (2019), "Pheochromocytoma and Paraganglioma", *The New England Journal of Medicine*, **381(6)**, pp.552-565.
- [4] F.A. Farrugia, et al. (2017), "Pheochromocytoma, diagnosis and treatment: Review of the literature", *Endocrine Regulations*, **51(3)**, pp.168-181.
- [5] S. Hescot, et al. (2019), "Prognosis of malignant pheochromocytoma and paraganglioma (MAPP-Prono Study): A European network for the study of adrenal tumours retrospective study", *The Journal of Clinical Endocrinology & Metabolism*, **104(6)**, pp.2367-2374.
- [6] E.P.M. Corssmit, M. Snel, E. Kapiteijn (2020), "Malignant pheochromocytoma and paraganglioma: Management options", *Current Opinion in Oncology*, **32(1)**, pp.20-26.
- [7] P. Goffredo, J.A. Sosa, S.A. Roman (2013), "Malignant pheochromocytoma and paraganglioma: A population level analysis of long-term survival over two decades", *Journal of Surgical Oncology*, **107(6)**, pp.659-664.
- [8] P.F. Plouin, et al. (2016), "European Society of Endocrinology Clinical Practice Guideline for long-term follow-up of patients operated on for a pheochromocytoma or a paraganglioma", *European Journal of Endocrinology*, **174(5)**, pp.1-10.
- [9] Y.J. Chai, et al. (2014), "Systematic review of surgical approaches for adrenal tumours: Lateral transperitoneal versus posterior retroperitoneal and laparoscopic versus robotic adrenalectomy", *International Journal of Endocrinology*, **2014**, DOI: 10.1155/2014/918346.
- [10] J.W.M. Lenders, et al. (2014), "Pheochromocytoma and paraganglioma: An endocrine society clinical practice guideline", *The Journal of Clinical Endocrinology & Metabolism*, **99(6)**, pp.1915-1942.
- [11] A. Balla, et al. (2019), "Laparoscopic bilateral anterior transperitoneal adrenalectomy: 24 years experience", *Surgical Endoscopy*, **33(11)**, pp.3718-3724.
- [12] X. Ren, et al. (2020), "Laparoscopic resection of a large clinically silent paraganglioma at the organ of Zuckerkandl: A rare case report and review of the literature", *BMC Urology*, **20(1)**, DOI: 10.1186/s12894-020-00732-0.
- [13] Z. Jawad, et al. (2017), "Complete laparoscopic excision of a giant retroperitoneal paraganglioma", *Annals of the Royal College of Surgeons of England*, **99(5)**, pp.148-150.
- [14] C. Aggeli, et al. (2017), "Surgery for pheochromocytoma: A 20-year experience of a single institution", *Hormones (Athens, Greece)*, **16(4)**, pp.388-395.
- [15] S. Hattori, et al. (2014), "Surgical outcome of laparoscopic surgery, including laparoendoscopic single-site surgery, for retroperitoneal paraganglioma compared with adrenal pheochromocytoma", *Journal of Endourology*, **28(6)**, pp.686-692.
- [16] T. Hakariya, et al. (2019), "Successful laparoscopic resection of a paraganglioma immediately behind the inferior vena cava and bilateral renal veins", *IJU Case Reports*, **2(5)**, pp.261-264.
- [17] R. Ramachandran, V. Rewari (2017), "Current perioperative management of pheochromocytomas", *Indian Journal of Urology*, **33(1)**, pp.19-25.
- [18] N. Rao, et al. (2016), "Surgical and hemodynamic outcomes in pheochromocytoma surgery: A prospective cohort study", *Urology*, **98**, pp.103-106.
- [19] G. Janetschek, H.P. Neumann (2001), "Laparoscopic surgery for pheochromocytoma", *The Urologic Clinics of North America*, **28(1)**, pp.97-105.