

---

## MORPHOLOGICAL FEATURES OF THE DORSAL AND VENTRAL WALLS OF THE OROPHARYNX IN THE COMMON PIGEON (*Columba livia*)

---

**IGWEBUIKE, Udensi Maduabuchi, UGWUOKE, Wilfred Ikechukwu and UDOUMOH, Anietie Francis**

Department of Veterinary Anatomy, Faculty of Veterinary Medicine, University of Nigeria, Nsukka, Nigeria

**Corresponding Author:** Igwebuik, U. M. Department of Veterinary Anatomy, Faculty of Veterinary Medicine, University of Nigeria, Nsukka, Nigeria. **Email:** [udensi.igwebuik@unn.edu.ng](mailto:udensi.igwebuik@unn.edu.ng) **Phone:** +234 8038726150

---

### ABSTRACT

*Morphological characteristics of the dorsal and ventral walls of the oropharynx were studied in ten common pigeons. Gross observation showed that left and right maxillary ramphotheca constituted the lateral boundaries of the dorsal wall of the oropharynx, while the palate, choana and infundibulum were the prominent structures in this region. The palate, which lacked palatine papillae on its mucosal surface, was characterized by a median palatine ridge and two lateral palatine ridges. The choanal slit appeared as a roughly triangular opening with a narrow tapered rostral terminus and a broad rounded caudal border. Its cavity was partially demarcated into two compartments by a median ridge. The ventral wall of the oropharynx presented as a concave inter-ramal depression, whose lateral boundaries were formed by left and right mandibular ramphotheca. The caudal surface of the ventral wall of the oropharynx exhibited a mucosal elevation, the laryngeal mound and an oval opening, the glottis. Histologically, the entire mucosal surface of the oropharyngeal cavity was lined by non-keratinized stratified squamous epithelium. Beneath this epithelium was a dense irregular connective tissue, the lamina propria-submucosa which contained numerous glandular acini, blood vessels, bundles of skeletal muscle fibres, as well as solitary and aggregate lymphoid follicles. These observations were discussed in relation to the function of the oropharynx in procurement, maintenance/movement of food in the oral cavity and swallowing of food bolus. It was concluded that the major morphological adaptations of the oropharynx are a reflection of the mode of feeding and nature of diet consumed by the common pigeon.*

**Keywords:** Common pigeon, *Columba livia*, Oropharynx, Palate, Salivary glands, Lymphoid follicles

---

### INTRODUCTION

Avian mouth and pharynx do not show any definite line of demarcation, but constitute a common oropharyngeal cavity (Bacha and Bacha, 2000; Gussekloo, 2006; Igwebuik and Eze, 2010; Igwebuik and Anagor, 2013). The oropharyngeal cavity plays a very important role in the maintenance/movement of food in the oral cavity, and in swallowing of food bolus. Generally, anatomical structures found in the dorsal wall of the oropharynx include the palate,

choanal slit and infundibulum, while structures in the ventral wall of the oropharynx include a concave depression between the rami of the lower beak, laryngeal mound and glottis. However, avian oropharynx is known to exhibit major morphological variations as a reflection of differences in habitat, feeding habit and nature of diet consumed by the birds (King and McLelland, 1984). Indeed, it has been demonstrated that some correlations exist between the form-function complexes of the feeding apparatus and the extent of diversity of

food-habits shown by birds (Bhattacharyya, 1994). Some recent studies on the morphology of the avian oropharynx have been restricted in general to gross inspection of the region (Igwebuike and Eze, 2010; Igwebuike and Anagor, 2013). However, the histological structure of the palate has been investigated in the domestic fowl (Samar *et al.*, 2002) and some wild birds (Crole and Soley, 2011). The present study seeks to provide information on both gross and histological characteristics of the oropharyngeal wall in the common pigeon. The common pigeon is a member of the family columbidae, and feeds mainly on seeds and grains.

## MATERIALS AND METHODS

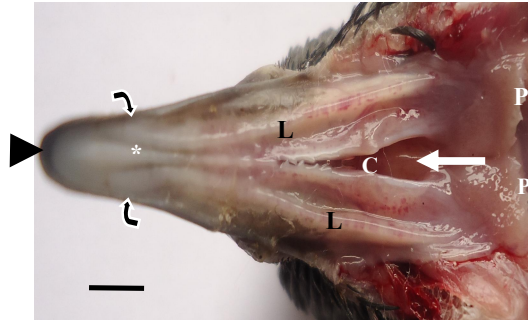
**Animals:** All procedures involving animals were conducted according to the guidelines for the protection of animal welfare in the University of Nigeria Nsukka. The ten adult common pigeons ( $325.4 \pm 6.12$  g) used for this study were obtained from local markets in Nsukka Local Government Area, Enugu State, Nigeria. The birds were sacrificed by euthanasia using intravenous injection of ketamine (1 ml / 100 g body weight of bird).

**Gross Anatomy:** Following death, structures in the oropharynx were dissected and studied in terms of their shape, physical appearance and *in-situ* topographical relationships. Gross photographs were captured using a Sony 14.1 mega pixels digital camera.

**Histological Preparations:** Specimens taken from different parts of the dorsal and ventral walls of the oropharynx were cut and fixed by immersion in Bouin's fluid for 48 hours. Later, these specimens were dehydrated in increasing concentrations of ethanol, cleared in xylene and embedded in paraffin wax. The 5 $\mu$ m thick sections were cut, mounted on glass slides and differentially stained with Haematoxylin and Eosin (H&E) for light microscopy. Photomicrographs were captured using a Moticam Images Plus 2.0 digital camera (Motic China Group Limited.).

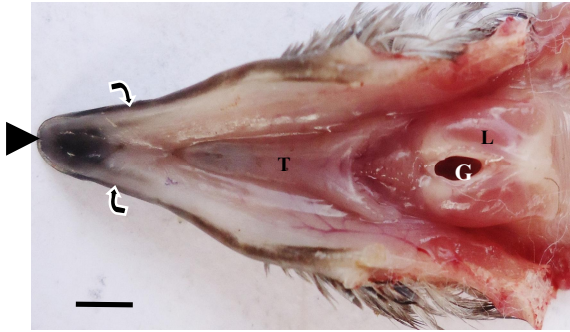
## RESULTS

**Gross Anatomy:** The anatomy of the dorsal wall of the oropharyngeal cavity showed that both the right and left maxillary ramphotheca formed the lateral boundaries of the dorsal wall of the oropharynx (Figure 1).

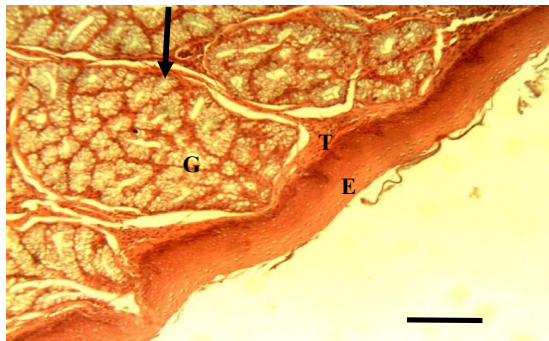


**Figure 1: Dorsal wall of oropharynx; showing maxillary ramphotheca (curved arrows), maxillary rostrum (arrow head), club-shaped median palatine ridge (asterisk), lateral palatine ridges (L), choanal slit (C), median ridge (white arrow) and pharyngeal papillae (P), Scale bar = 2 cm.**

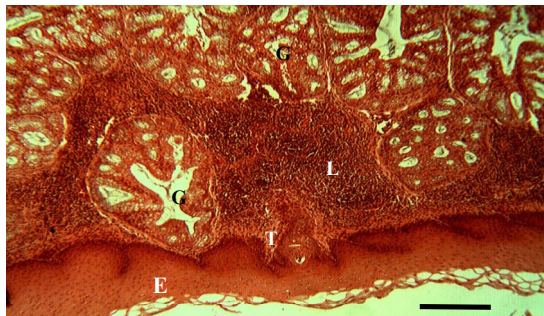These ramphotheca merged rostrally forming the maxillary rostrum. The palate was characterized by a median palatine ridge and two lateral palatine ridges. The club-shaped median palatine ridge extended from the rostral terminus of the choanal slit through the rostral half of the oropharynx. Rostrally, the left and right lateral palatine ridges were aligned parallel to the median palatine ridge. These lateral palatine ridges extended caudally on both sides of the choana. The choanal slit was roughly triangular in shape, with a narrow tapered rostral terminus and a broad rounded caudal border. The narrow rostral part of the choanal slit showed presence of few papillae that point caudally and medially. A median ridge partially separated the single choanal slit into right and left compartments. Caudal to the choana was the infundibular slit. Although papillae were absent on the palatine mucosa of the pigeon, a row of caudally pointed papillae, the pharyngeal papillae was present at the most caudal boundary of the roof of the oropharynx (Figure 1).



**Figure 2: Ventral wall of the oropharynx; showing mandibular ramphotheca (curved arrows), mandibular rostrum (arrow head), tongue (T), laryngeal mound (L) and glottis (G), Scale bar = 2 cm.**



**Figure 3: Photomicrograph of the rostral part of the palate; showing non-keratinized stratified squamous epithelium (E), dense connective tissue (T), glandular units (G), connective tissue sheath (arrow) surrounding the glandular acini. H & E stain, scale bar = 60  $\mu$ m.**



**Figure 4: Photomicrograph of the caudal part of the palate; showing non-keratinized stratified squamous epithelium (E), dense connective tissue (T), glandular units (G) and lymphoid follicles (L). H & E stain, scale bar = 60  $\mu$ m.**

The ventral wall of the oropharyngeal cavity of the common pigeon presented as a concave depression between the rami of the lower beak (Figure 2).

The tongue was located in this concave inter-ramal depression. The right and left mandibular ramphotheca that form the lateral boundaries of the ventral wall of the oropharynx converged rostrally forming the mandibular rostrum. The caudal of the surface of the ventral wall of the oropharynx exhibited a mucosal elevation, the laryngeal mound and its associated opening, the glottis.

**Histology:** Under the light microscope, it was observed that both the rostral (Figure 3) and caudal (Figure 4) parts of the dorsal wall of the oropharynx were lined by non-keratinized stratified squamous epithelium. The dense irregular connective tissue beneath this epithelium constitutes the lamina propria-submucosa, which contained numerous glandular acini and blood vessels. Each glandular unit was surrounded by a condensed connective tissue sheath, from which arose connective tissue septa that demarcated individual secretory acini. Secretory cells of the glands exhibited lightly stained 'foamy' cytoplasm and basally displaced nuclei characteristic of mucus-secreting cells (Figure 3).

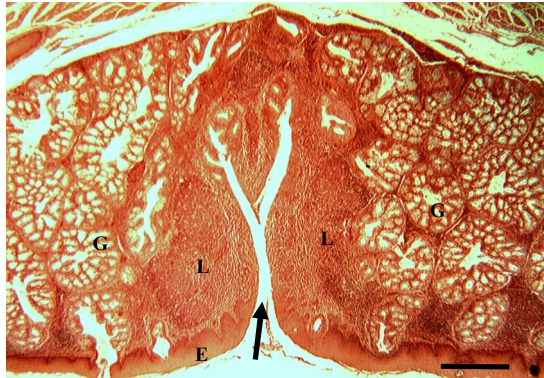In addition, the lamina propria-submucosa in the caudal part of the dorsal wall of the oropharynx showed many aggregations of lymphoid follicles (Figure 4). More so, dense aggregation of lymphoid follicles surrounding a crypt was also present in the caudal part of the dorsal wall of the oropharynx (Figure 5). This structure was associated with numerous glandular acini. The glandular acini in the caudal part of the dorsal wall of the oropharynx were composed of serous secreting units (Figures 4 and 5). Non-keratinized stratified squamous epithelium lined the entire ventral wall of the oropharynx of the pigeon (Figure 6). Beneath the epithelium was a dense connective tissue layer, the lamina propria-submucosa. Structures found in the connective tissue include numerous glandular acini, blood vessels, bundles of skeletal muscle fibres and solitary lymphoid



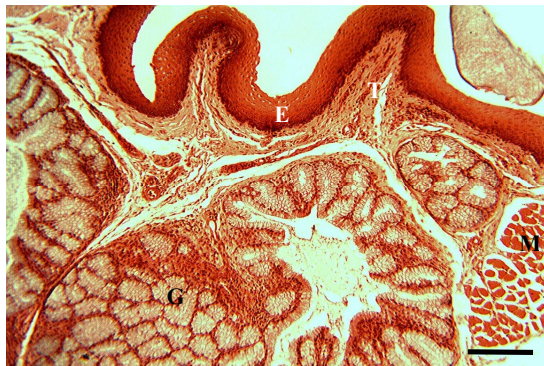follicles. The morphology of the glandular units in the ventral wall of the oropharynx (Figure 6) was similar to that of the mucus-secreting glands observed in the dorsal wall of the oropharynx.

## DISCUSSION

In the pigeon, rostral convergence of the right and left maxillary ramphotheca in the upper beak, and a similar convergence of the left and right mandibular ramphotheca in the lower beak result in a pointed rostral extremity in which the hard horny sheath of the upper beak extends in a hook beyond that of the lower beak.



**Figure 5: Photomicrograph of the caudal part of the palate; showing non-keratinized stratified squamous epithelium (E), crypt (arrow), lymphoid follicles (L) and glandular units (G). H & E stain, scale bar = 60  $\mu$ m.**



**Figure 6: Photomicrograph of the ventral wall of the oropharynx; showing non-keratinized stratified squamous epithelium (E), dense connective tissue (T), skeletal muscles (M) and glandular units (G). H & E stain, scale bar = 60  $\mu$ m.**

This structure functions as a prehensile organ, and may play significant roles in procurement, handling and incomplete break down of food materials. Although median and lateral palatine ridges are present in some birds including the domestic fowl (Dyce *et al.*, 2002), the origin and alignment of the lateral palatine ridges relative to the median palatine ridge in the pigeon is unique. Lateral palatine ridges are absent in the duck (Igwebuike and Anagor, 2013), rhea (Gussekkloo, 2006) and ostrich (Tivane *et al.*, 2011). Palatine papillae, which has been reported as a typical feature of the palate in most birds (McLelland, 1979; Igwebuike and Eze, 2010) are lacking on the mucosal surface of the pigeon's palate. This adaptation may be related to the mode of feeding of the pigeon. The row of caudally pointed papillae at the most-caudal border of the dorsal wall of the pigeon's oropharynx may be important in ensuring unidirectional movement of food bolus towards the oesophagus, and may prevent regurgitation. This study shows that the single choanal slit in the pigeon is partially compartmentalized by a median ridge. This is similar to the anatomy of the choana in the duck (Igwebuike and Anagor, 2013) and ostrich (Tivane *et al.*, 2011), but differs from that of the African pied crow which lacks a median ridge (Igwebuike and Eze, 2010).

The observed non-keratinized stratified squamous epithelial lining of the entire mucosal surface of the oropharyngeal cavity is in agreement with what has been reported in most birds (Nickel *et al.*, 1977) except the emu (Crole and Soley, 2011) and ostrich (Tivane, 2008), in which the epithelium is keratinized. Variation in keratinization of palatine mucosal epithelium among avian species may be a reflection of the evolutionary adaptations observed between different birds (Sagsoz *et al.*, 2012). Furthermore, lack of keratin on the epithelium of the pigeon's oropharynx may be an indication that this region is not subject to much abrasion. An important histological feature of the wall of the oropharynx in the pigeon is occurrence of solitary and aggregate lymphoid follicles in the lamina propria-submucosa. This was not different from the reports in other birds (Samar *et al.*, 2002; Tivane, 2008; Crole and Soley,

2011; Sagsoz *et al.*, 2012). Moreover, the present study provides evidence for presence of pharyngeal tonsil in the pigeon, with its associated crypt and dense accumulation of lymphoid follicles. Pharyngeal tonsil was demonstrated in the emu and ostrich (Crole and Soley, 2012). These lymphocytic aggregations are part of the well-organized gut-associated lymphoid tissues (GALT), a sub-division of mucosa-associated lymphoid tissues (MALT) (Liebler-Tenorio and Reinhard, 2006). Thus, the wall of the oropharynx represents the first strategic anatomical location of GALT in avian species, and may be a suitable and easily accessible site for immune response surveillance.

Our study shows that glandular tissues form a major component of the sub-epithelial connective tissue in both dorsal and ventral walls of the pigeon's oropharynx. This is akin to what has been demonstrated in the chicken (Samar *et al.*, 2002) and some wild species of bird (Crole and Soley, 2011; Sagsoz *et al.*, 2012). It has been reported that glands are best developed in birds that feed on dry diet such as seeds and grains (King and McLelland, 1984). Definitive 'large salivary glands' do not occur in birds; rather there are numerous independent glandular units that form glandular fields (Banks, 1993). Although there has neither been consensus nor uniformity as regards the localization and terminology of intramural glands of the avian oropharynx (Crole and Soley, 2011), these glands may generally be classified according to the anatomical regions and sub-regions of the oropharynx in which they are located. Thus, such classifications as palatine, oral angular and pharyngeal tonsillar glands on the dorsal wall, as well as mandibular and crico-arytenoid glands on the ventral wall were suggested by Crole and Soley (2011). In chicken (Samar *et al.*, 2002), the palatine glands are further classified into two groups referred to as the lateral and medial palatine glands.

The histological appearance of the glands seen in the pigeon indicates that they are composed mostly of mucus-secreting cells, with lightly stained 'foamy' cytoplasm and basally displaced nuclei. However, serous-

secreting units occur in the caudal part of the dorsal wall of the oropharynx. Although serous-secreting units have also been identified in the medial palatine glands of chicken (Samar *et al.*, 2002), results of many previous studies support the idea that mucus-secreting glands predominate in the avian oropharynx (Samar *et al.*, 1995; 1999; Tivane, 2008; Crole and Soley, 2011, Sagsoz *et al.*, 2012). All the glandular units in the wall of the oropharyngeal cavity of the pigeon contribute to the secretion of saliva. The mucous glands are thought to secrete lubricating molecules (Samar *et al.*, 1995; Liman *et al.*, 2001) which form a protective layer on the oral cavity against desiccation, mechanical damage, external toxic substances and microbial toxins (Samar *et al.*, 2002; Crole and Soley, 2011; Sagsoz *et al.*, 2012). In addition, secretions of the glands may aid in swallowing of food by lubricating the caudal part of the oropharynx and probably, the initial part of the oesophagus as reported in the African pied crow (Igwebuike and Eze, 2010). Moreover, occurrence of serous glandular units in the oropharyngeal region of the pigeon indicates that the saliva may contain digestive enzymes. This suggests that some degree of enzymatic breakdown of food particles may begin in the oropharynx of the common pigeon.

In conclusion, the present study has provided necessary information on the morphology of the oropharyngeal cavity of the common pigeon in relation to the function of this region of the bird in procurement, maintenance/movement of food in the oral cavity and swallowing of food bolus. The study demonstrates that the major morphological adaptations of the oropharynx are a reflection of the mode of feeding and nature of diet consumed by the common pigeon.

## REFERENCES

- BACHA, W. J. and BACHA, L. M. (2000). Digestive system. In: BALADO, D. (Editor), *Colour Atlas of Veterinary Histology*. Lippincott Williams and Wilkins, Philadelphia.

- BANKS, W. J. (1993). *Applied Veterinary Histology*. Third Edition, Mosby Incorporated, St. Louis, Missouri, USA.
- BHATTACHARYYA, B. N. (1994). Diversity of feeding adaptations in certain columbid birds: a functional morphological approach. *Journal of Bioscience*, 19: 415 – 427.
- CROLE, M. R. and SOLEY, J. T. (2011). Distribution and structure of glandular tissue in the oropharynx and proximal oesophagus of the emu (*Dromaius novaehollandiae*). *Acta Zoologica* (Stockholm), 92: 206 – 215.
- CROLE, M. R. and SOLEY, J. T. (2012). Evidence of a true tonsil in birds: a novel lymphoid organ in *Dromaius novaehollandiae* and *Struthio camelus*. *Frontiers in Zoology*, 9: 21 – 35.
- DYCE, K. M., SACK, W. O. and WENSING, C. J. G. (2002). *Textbook of Veterinary Anatomy*. W. B. Saunders Company, Philadelphia.
- GUSSEKLOO, S. W. S. (2006). Feeding structures in birds. In: BELS, V. (Ed.). *Feeding in Domestic Vertebrates: From Structure to Behaviour*. CABI Publishing, Wallingford, UK.
- IGWEBUIKE, U. M. and EZE, U. U. (2010). Anatomy of the oropharynx and tongue of the African pied crow (*Corvus albus*). *Veterinarski Arhiv*, 80: 523 – 531.
- IGWEBUIKE, U. M. and ANAGOR, T. A. (2013). Morphology of the oropharynx and tongue of the Muscovy duck (*Cairina moschata*). *Veterinarski Arhiv*, 83: 685 – 693.
- KING, A. S. and McLELLAND, J. (1984). *Birds – Their Structure and Function*. Second Edition, Bailliere Tindall, London.
- LIEBLER-TENORIO, E. M. and REINHARD, P. (2006). MALT structure and function in farm animals. *Veterinary Research*, 37: 257 – 280.
- LIMAN, N., BAYRAM, G. and KOCAK, M. (2001). Histological and histochemical studies on the lingual, preglottal and laryngeal salivary glands of the Japanese quail (*Conturnix conturnix japonica*). *Archives of Oral Biology*, 38: 649 – 655.
- McLELLAND, J. (1979). Digestive system. In: KING, A. S. and McLELLAND, J. (Eds.). *Form and Function in Birds*. Academic Press, San Diego, California.
- NICKEL, R., SCHUMMER, A. and SEIFERLE, E. (1977). *Anatomy of the Domestic Birds*. Volume 5, Verlag Paul Parey, Berlin.
- SAGSOZ, H., ERDOGAN, S. and AKBALIK, M. E. (2012). Histomorphological structure of the palate and histochemical profiles of the salivary palatine glands in the chukar partridge (*Alectoris chukar*). *Acta Zoologica* (Stockholm), 100: 1 – 10.
- SAMAR, M. E., AVILA, R. E., DE FABRO, S. P. and CENTURION, C. (1995). Structural and cytochemical study of salivary glands in the magellanic penguin (*Spheniscus magellanicus*) and the kelp gull (*Larus dominicanus*). *Marine Ornithology* 23: 154 – 156.
- SAMAR, M. E., AVILA, R. E., DE FABRO, S. P., PORFIRIO, V., ESTEBAN, F. J., PEDROSA, J. A. and PEINADO, M. A. (1999). Histochemical study of Magellanic penguin (*Spheniscus magellanicus*) minor salivary glands during postnatal growth. *Anatomical Record* 254: 298 – 306.
- SAMAR, M. E., AVILA, R. E., ESTEBAN, F. J., OLMEDO, L., DETTIN, L., MASSONE, A., PEDROSA, J. A. and PEINADO, M. A. (2002). Histochemical and ultrastructural study of the chicken salivary palatine glands. *Acta Histochemica*, 104: 199 – 207.
- TIVANE, C. (2008). *A morphological study of the oropharynx and oesophagus of the ostrich (Struthio camelus)*. M.Sc. Dissertation, University of Pretoria, South Africa.
- TIVANE, C., RODRIGUES, M. N., SOLEY, J. T. and GROENEWALD, H. B. (2011). Gross anatomical features of the oropharyngeal cavity of the ostrich (*Struthio camelus*). *Presquisa Veterinaria Brasileira*, 31: 543 – 550.

