

<https://doi.org/10.52418/moldovan-med-j.64-6.21.05>
UDC: 611.137/.147+616.718-089.844-092.9



In vivo experimental study of the arterial supply of the rabbit posterior limb

*^{1,2}Elena Pavlovski, ^{1,2}Alina Stoian, ²Grigore Verega, ¹Viorel Nacu

¹Laboratory of Tissue Engineering and Cells Culture, ²Department of Orthopedics and Traumatology Nicolae Testemitanu State University of Medicine and Pharmacy, Chisinau, the Republic of Moldova

Authors' ORCID iDs, academic degrees and contributions are available at the end of the article

*Corresponding author – Elena Pavlovski, e-mail: pavlovski.elena@gmail.com

Manuscript received November 11, 2020; revised manuscript August 18, 2021; published online December 17, 2021

Abstract

Background: The use of bone graft has been a successful step in the treatment of a large number of diseases of the osteoarticular system. But a massive bone defect remains a dilemma for modern reconstructive surgery. Present methods used have a high level of morbidity and complication. Literature indicates the absence of an optimal solution in massive bone defects healing. The aim of this study: to perform an *in vivo* preliminary study of vascularization of the hind limb in the rabbit model, for obtaining a graft able for further inclusion in the host blood circulation, without immunosuppression by decellularization.

Material and methods: The study was performed on the 12 laboratory rabbits. After euthanasia of the rabbit, the femoral and tibiofibular bone was collected without soft tissue, only with the vascular pedicle, and keeping the passage through the vessels. In the abdominal aorta was injected contrast material, with the subsequent preparation of the arterial vessels, succeeded by anatomical, morphological, radiography, and microangiography study of this vascularized bone segment.

Results: The principal nutrient artery of the rabbit femur springs from the lateral circumflex femoral artery. The optimal segment for vascularized allografting (the rabbit model) was determined the upper third of the femur with the up to the level of the internal iliac artery. So, it could be used as a bone graft for further conservation and decellularization.

Conclusions: The vascularized allogeneic bone without immunosuppression would be a perfect alternative in the treatment of the massive bone defects.

Key words: vascularized bone grafts, bone allograft surgical revascularization, angiography.

Cite this article

Pavlovski E, Stoian A, Verega G, Nacu V. *In vivo* experimental study of the arterial supply of the rabbit posterior limb. *Mold Med J.* 2021;64(6):26-32. <https://doi.org/10.52418/moldovan-med-j.64-6.21.05>.

Introduction

Reconstruction of the large bone defects, caused by severe trauma, infection, tumor resection, or congenital deformity, is an actual clinical problem and the approach challenges. They were dictated by a multitude of clinical factors, including the defect size, patient comorbidities, soft tissue condition, and the risk of infection present in the defect. Current reconstructive options include the use of cryopreserved allografts, bone transport, prosthetic replacement, membrane-induced osteogenesis, re-implantation of autoclaved tumor bone and, vascularized bone autografts, all with a significant incidence of complications and failure. Unfortunately, almost all of these substitutes have been only used to refill small cavitary defects in the clinic. A multidisciplinary approach that involves orthopedic, plastic, and vascular surgeons are essential to optimize success rates [1-3].

The large bone defects, called critical-sized defects (CSDs), describe a bone void that will not spontaneously fill, without intervention. That means CSDs would not heal despite simple stabilization and require further intervention in addition to fixation. This type of defect is difficult to

characterize because diagnosis is subjective. Whereas, the critical defect varies based on patient age, overall health, and the size of the lack of bone. The significant defects that are less than 4 to 6 cm are classified as small-scale defects, and those that are larger than 4 to 6 cm are considered large-scale defects. In adult patients, a critical bone defect generally has circumferential loss of 50% or a length of 2 cm. The anatomic location and the condition of the surrounding soft tissue are the two contributing factors that dictate the healing potential of a defect. Healing potential varies based on the anatomic location of the defect [3-5].

The healing of bone fractures is a well-orchestrated physiological complex process involving interactions between different cells and signals to form new mineralized tissue, to replace and repair bone tissue without scar formation. Blood vessels serve as a basic template, around which bone development takes place and also brings together the critical elements for bone homeostasis into the osteogenic microenvironment, including minerals, growth factors, and osteogenic progenitor cells [2, 3, 4, 6].

The healthy growth and development of a bone are exclusively linked to its vascular and, in particular, its

arterial supply. Well, it is generally agreed that there are three sources of blood supply in long bones. They are the nutrient artery, epiphyseal-metaphyseal arteries, and periosteal arteries. Johnson R. concluded that the nutrient artery was the essential source, by interfering with two of the three sources of blood supply of the tibia in dogs. The nutrient artery is capable of maintaining the viability of the entire shaft and of supporting the repair of bone defects, and that the periosteal source was the least important [7, 8]. An interesting question may be raised. From where does the remaining intact blood supply come to these three segments after ligation of the nutrient artery? The quantitative observation in this study that the nutrient artery contributes at least 71 percent of the total blood supply of the shaft agrees very well with their comments. Very effective communication between the Bone Marrow vascular system and external circulation must exist, a fact that has been exploited in emergency medicine for many years. Initially developed for battlefield administration of fluids and analgesics, the use of direct intraosseous infusion is now widely utilized in emergency medicine when peripheral venous access is difficult. Here it is shown that murine long bones are supplied with approximately 16 nutrient arteries and a central sinus with two exit sites. Trans-cortical vessels (TCV) require the presence of narrow canals in the cortical bone that is then lined by endothelial cells, in all types of murine long bones investigated. These TCVs can be either arterioles or venules and effectively transport blood and thereby also neutrophils. TCVs can be either arterial or venous and directly connect the periosteum to BM [9, 10].

The “diamond concept,” being a conceptual framework for a successful bone repair response, gives equal importance to mechanical stability and the biological environment. Moreover, adequate bone vascularity and the physiological state of the host are thought to be essential within this framework of fracture repair. Overall, the “diamond concept” refers to the availability of osteoinductive mediators, osteogenic cells, an osteoconductive matrix (scaffold), optimum mechanical environment, adequate vascularity, and addressing any existing comorbidities of the host [11].

The bone graft is commonly used in reconstructive surgery, a complicated surgical procedure that replaces missing bone. The bone grafts can be autografts, allografts (cadaveric bone usually obtained from a bone bank), or synthetic (often made of hydroxyapatite or other naturally occurring and biocompatible substances) with similar mechanical properties to bone. Vascularized autografts – the gold standard between grafts is limited primarily to the fibula and iliac crest for significant skeletal defects. Each site of autologous bone graft has its advantages, but also has the disadvantages like donor site morbidity, the limited volume available, no structural capability, and occasional unsatisfactory biologic activity have led to increased use of allografts. For CSDs, there are two primary options to consider, in the actual clinical approach: induced membrane technique and distraction osteogenesis. Choosing between

these two techniques should be based on the associated soft tissue injury, the local vascularity, and the possibility of residual infection. Transplantation of living vascularized allogeneic bone should have the potential to combine the same biological benefits as vascularized autografts with the mechanical advantages provided by the size- and shape-matched allogeneic bone segments [12-14]. The significant benefits of vascularized bone grafts are more rapid and complete incorporation of the graft, which provides immediate structural support. The orthobiologic ability of the transplanted (living) bone to form new bone and the addition of new blood supply to the recipient is the crucial element of the “diamond concept.” Free vascularized bone grafts allow living bone tissue to be transplanted to replace a bone defect. The use of vascularized bone grafts requires microvascular dissection and attachment to a recipient site artery and vein [15-17].

Therefore, the data of the literature presents suggestions of the need to increase vascularized bone allograft, which remains at the stage of preclinical studies on the need for long-term post-interventional immunosuppression, which is irrational in the case of bone transplantation. Current studies are investigating alternative options to maintain the viability of the allograft by practicing drug-induced and surgical neoangiogenesis with the short-term immunosuppression [18, 19].

The vascularization of the rabbit femur, the closest segment to the required demand of *in-vivo* study, has been earlier researched [10, 20].

In this literature context, the aim of *in-vivo* research for the first stage is to study the vascularization of the posterior limb – femur and the tibiofibular segment in the rabbit model and establish the most suitable portion of bone with the vessel. This bone portion must be able to serve as a vascularized allograft, for the future microsurgical inclusion in the host circuit. The success after a bone vascularized allograft procedure is ensured by keeping the passage of nutrient artery and microcirculation of this graft.

Material and methods

This study is a part of the doctoral program of the Doctoral School of Medical Sciences. It was approved by the Research Ethics Committee, dated 21.05.2018, and performed during 2019-2020, in the Tissue Engineering and Cells Cultures Laboratory, of *Nicolae Testemitanu* State University of Medicine and Pharmacy, Chisinau, the Republic of Moldova.

The first stage of the present study was performed in the animal model (New Zealand White Rabbit) on their bodies. The study was carried out on twenty adult white rabbits of about four months old and weighing about three kilograms. The animals' bodies were taken from the abattoir, mandatory that has the sanitary-veterinary certificate for euthanasia. Following dissection, the individual bones were stripped of all extra-osseous soft tissue, only with the vascular pedicle and including periosteum to permit clear visualization of

intraosseous vessels alone, and to avoid confusion arising from the superimposition of vessels in soft tissues. This procedure kept the passage through the vessels and didn't remove periosteal arterial twigs from the cortex since. In the abdominal aorta was injected contrast material, with the subsequent preparation of the arterial vessels, succeeded by anatomical, radiography, histology, and microangiography study of this vascularized bone segment. Thus, was determined the vascularized bone segment that could be used as a bone graft for further conservation and decellularization.

The macroscopic study of the vascularization of the posterior limb in the rabbit model

The research was performed on the vascularization of the posterior limb in the carcasses of laboratory animals, New Zealand White rabbit. We injected polymerizing material (Protacryl - M) in the abdominal aorta, and the *inferior vena cava* (fig. 1), with the subsequent preparation of the limb's vessel (fig. 2, 3).

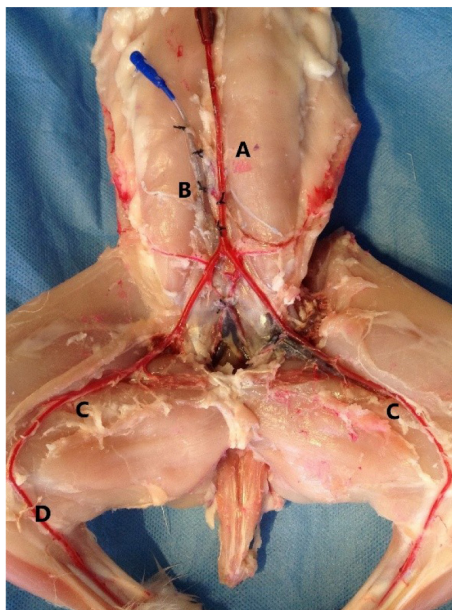


Fig. 1. A - the cannulated dorsal aorta, B - the cannulated inferior vena cava, C - the femoral artery, D - the saphenous artery

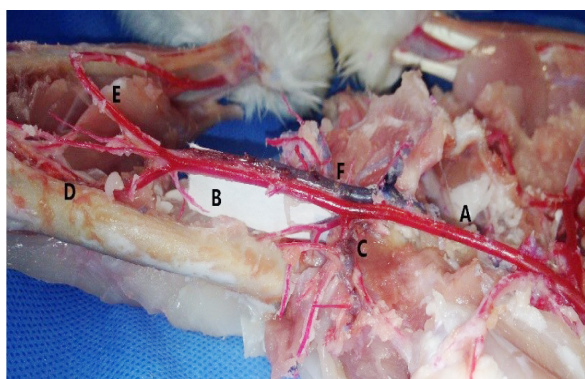


Fig. 2. A - the common iliac left artery, B- the femoral artery, C - the lateral circumflex femoral artery, D - *Arteria suprema genu*, E - the saphenous artery, F - the femoral intercondylar vein

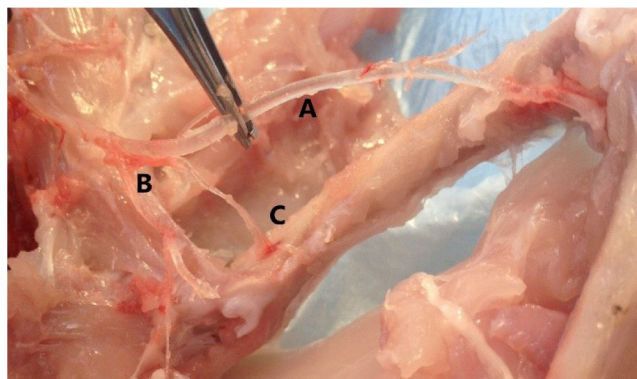


Fig. 3. A - the femoral artery, B - the lateral circumflex femoral artery, C - the principal nutrient artery of the rabbit femur

The angiographic study of vascularization by introducing the contrast substance into the abdominal aorta.

The contrast substance-Urografin® 30% was injected in the abdominal aorta under pressure. The radiological examination was performed in the standard way (fig. 4).

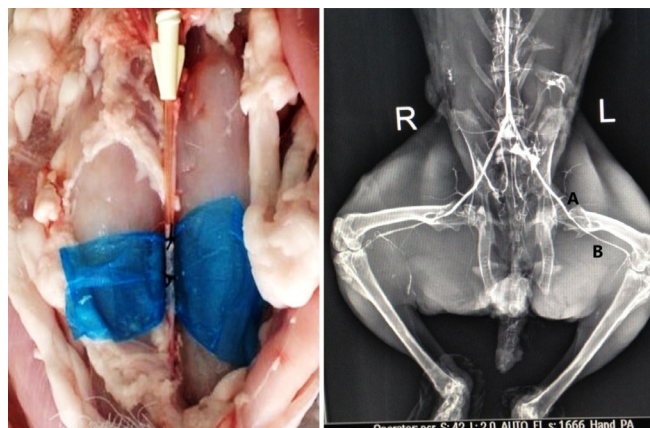


Fig. 4. I. The cannulated dorsal aorta, II. A - the common iliac artery, B - the femoral artery

The microangiography study of the vascularized bone segments (femur)

Through the cannulated internal iliac artery, the

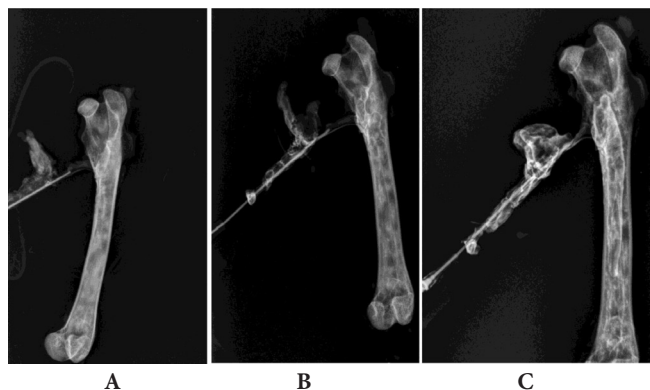


Fig. 5. A - the radiological examination at 1 min, B - the radiological examination at 3 min, C - the radiological examination at 3 min

Urografin® 30% was introduced under pressure. The radiological examination was performed at 1 min, 3 min and 5 minutes after the start of the introduction of the contrast substance (fig. 5).

The morphological study of the dorsal aorta, the internal iliac artery, and the vascularized bone segments (femur)

Histological sections of the dorsal aorta (fig. 6 A), the internal iliac artery (fig. 6 B), and the proximal femur (fig. 6 C) of rabbits, were stained with hematoxylin-eosin showing.

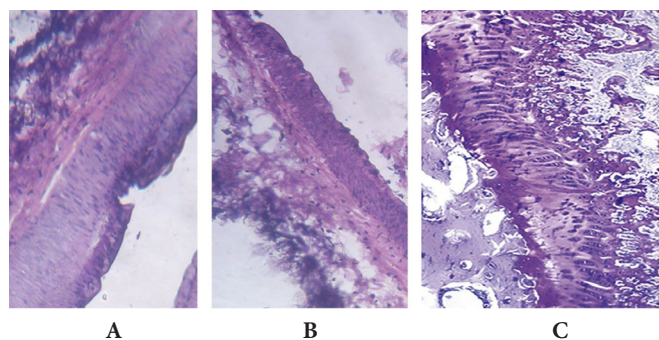


Fig. 6. A – the histological sections of the dorsal aorta, B – the histological sections of the internal iliac artery, C – the histological sections of the proximal femur

Results

The macroscopic study of the vascularization of the posterior limb in the rabbit model

The arterial supply of femur in a rabbit model begins at the dorsal aorta then divides into two common iliac arteries and a median caudal artery to the tail (fig. 7). Each common iliac artery gives a small ilio-lumbar artery that supplies the dorsal body wall. The common iliac artery divides into the internal iliac artery which supplies the organs of the pelvis and external iliac artery that supplies the hind limb. The external iliac terminates as a femoral artery in each hind limb. It has branches the – lateral and medial circumflex femoral which passes around on the hip joint to terminate as a contribution to the trochanteric anastomosis. From it, anterior cervical arteries descend into the femoral neck. Another branch of the same artery concerned in the nutrition of the femur is the artery of the trochanteric fossa. In one specimen, it sprang directly from the femoral, distal to the lateral circumflex femoral artery. It passes downwards for 2 cm before disappearing in the nutrient foramen situated on the medial surface of the shaft just below the lesser trochanter. So, the principal nutrient artery of the rabbit femur springs from the lateral circumflex femoral artery. In the distal part from the femoral artery begins the arteria suprema genu. Then the femoral artery continues as the popliteal artery, giving origin to the supracondylar (genicular) arteries, which pass outwards, supplying fine nutrient twigs to the posterior face of the inferior metaphysis, and the condyles. They join the medial and lateral condylar loops. From the popliteal begins the anterior tibial artery, a sizeable middle genicular

artery arises, which pierces the joint capsule, passes above the point of crossing of the cruciate ligament, and sinks into a foramen in the anterior wall of the intercondylar notch. The principal nutrient artery of the tibia, derived from the anterior tibial artery descends on the posterior surface of the bone before reaching the nutrient canal situated 5 mm above the level of the tibiofibular synostosis. The second principal nutrient artery given off by the anterior tibial at the synostosis sinks into the bone anteriorly just below the level of fusion. The shaft of the fibular portion of the bone has no nutrient artery of its own. The saphenous artery divides into the medial and lateral plantar arteries.

Venous drainage

A single vena comitans accompanies each artery. A simple circulus venosus is formed on the superficial surface of each condyle. The femoral intercondylar vein joins the tibial intercondylar veins to drain into the anterior tibial vein. The veins of the tibiofibular segment show those general features which have been described for the femur. The following individual points are to be noted. A vein issues from the fibular border of the shaft below the synostosis and drains into the peroneal vein, on the posterior surface of the tibia, two and occasionally three large veins issue from the bone. Veins from the intercondylar ridge join those draining the inferior femoral epiphysis and pass ultimately into the anterior tibial vein.

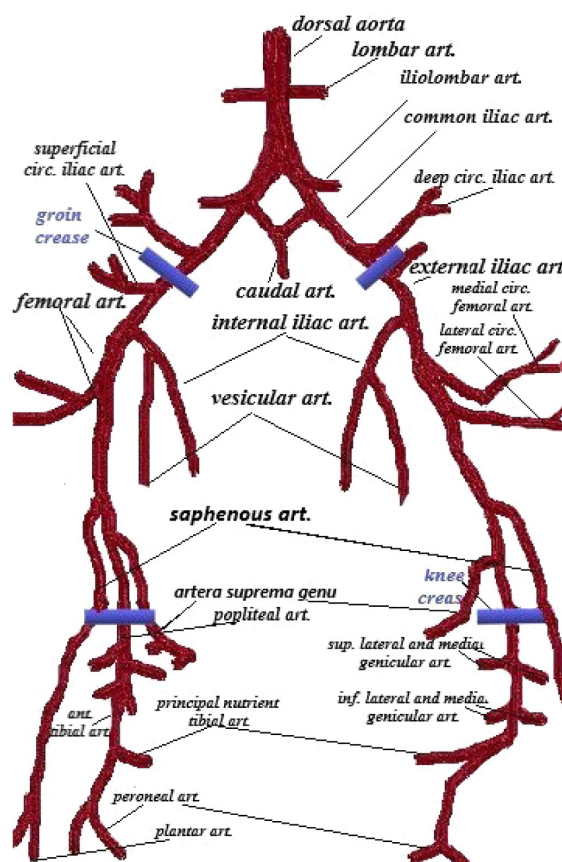


Fig. 7. The sketchy representation of the arterial supply of the posterior limb in the rabbit model.

The angiographic study of the vascularization in the hind limb in the rabbit model

The contrast substance (Urografin® 30%) was introduced into the abdominal aorta under pressure. The gross arterial supply of the hindlimb was determined, and the visualization of the anatomical correlation with the femoral bone after a standard radiological examination.

The microangiography study of the vascularized bone segments (femur) in the rabbit model

The internal vascularization of bone as revealed by radiography is presented at 1 min, 3 min and 5 minutes after the start of the introduction of the contrast substance (Urografin® 30%). The rate of blood flow through the principal nutrient artery of the femur indicates that it contributes at the 50-80 percent of the surface to the femur (depending on the epiphyseal, metaphyseal or diaphyseal region). The epiphyseal and metaphyseal arteries, and the periosteal arteries also have a significant contribution to blood arterial flow.

The morphological study

The histologic examination was done on the dorsal aorta, the internal iliac artery, and the vascularized bone segments (proximal femur). It demonstrates that the content of the extracellular matrix of the vessel is optimal up to the level of the internal iliac artery, for a next microsurgical inclusion in the host blood circulation. The grafts were stored at -84.4°C to be subsequently decellularized by the combined method. The next *in vivo* step will involve the orthotopic inclusion of the decellularized graft in the host circuit (fig. 8).

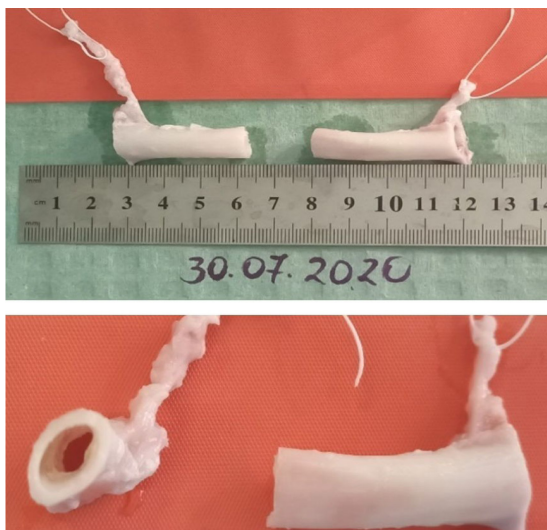


Fig. 8. The external appearance of the bone vascularized grafts

Discussion

Bone regeneration is a well-orchestrated physiological process. It is sufficient when the vascularization of the segment remains optimal. Performed by the intramedullary arteries, periosteal vessels, and the arteria nutricia, artery nutrition plays an essential role in strengthening throughout

the whole bone consolidation process [21, 22]. The success after bone vascularized allografting is ensured by keeping the circulation on nutrient artery and microcirculation of blood. The microsurgical anastomosis of the allograft pedicle would admit the creation of optimal conditions for sufficient revascularization. That ended in consolidation, resistance, and increased rigidity of the segment [14, 23-25]. Thus, vascularized bone grafting is considered superior to the non-vascularized one. Its task is not only to structurally replace the defect but also to biologically engage in the formation of new bone. Because the bone allografts not only replace the missing bone but also help the reconstruction of the lost bone by acting as a scaffold for osteoconduction and as a source of osteogenic and osteoinductive molecules for bone formation. To increase bone healing it is essential to provide a suitable vascularization and excellent mechanical stability [26]. The interaction of immunocompetent blood cells with the graft's vascular endothelium is the first stage in the cascade that induces ischemia, reperfusion disorder, and rejection. Stopping the microcirculation through the allograft is considered the principal cause of graft failure [27, 28]. Immunosuppression marks the progress in contemporary transplantology. It was shown that vascularized bone grafts are superior, especially for the reconstruction of large defects, because they retain the property of osteogenesis. But rest the morbidity of the donor site, and the source of autografts is limited. In this context, the research of vascularized bone allografts is imperative [29-32]. The dilemma required by vascularized bone allografts means the necessity of an after-graft immunosuppression and immunomodulation. Grafting of limbs, joints, bone tissue is not similar to the transplantation of vital organs, such as the heart, liver, which require long-term immunosuppression to omit systemic complications. And in the case of musculoskeletal tissue, the need for medication is 2-3 times higher than in the case of organ transplantation. On a large scale, long-term immunosuppression doesn't argue, and the risk induced by organic toxicity, malignancy, or other complications, does not justify it in these vitally uncritical situations [26, 31, 33].

The vascularized living allogeneic bone, without the need of the immunosuppression, would be a perfect alternative in the treatment of the massive bone defects. In other words, the research into vascularized bone allografts to omit their immunogenic potential by decellularization has increasing importance. Current decellularization methods of the vessel preserve vascular stiffness [34]. In this context, the *in vivo* experiment of including in the host blood circuit the orthotopically decellularized vascularized bone allograft will permit the description of both the vascular and the bony aspects.

Conclusions

The orthobiologic ability of the transplanted (living) bone to form new bone and the addition of new blood supply to the recipient is the crucial element of the "diamond concept". The significant benefits of vascularized bone grafts

are more rapid and complete incorporation of the graft, which provides immediate structural support.

The principal nutrient artery of the rabbit femur springs from the lateral circumflex femoral artery. Graft, able for the subsequent inclusion in the host blood circulation, without immunosuppression by decellularization, is the proximal third of the femur with the vascular pedicle to the internal iliac artery.

The further evaluation of the decellularization methods of the tissue, organs by preserving vascular stiffness, represents the reason to continue research in this field.

Transplantation of native allogeneic vascularized bone can be a potential perfect solution, only if significant and unjustified risks of long-term immunosuppression can be avoided.

References

- Pan Z, Jiang P, Xue S, Wang T, Li H, Wang J. Repair of a critical-size segmental rabbit femur defect using bioglass- β -TCP monoblock, a vascularized periosteal flap and BMP-2. *J Biomed Mater Res B Appl Biomater*. 2018;106(6):2148-2156. doi: 10.1002/jbm.b.34018.
- Vidal L, Kamplaitner C, Brennan M \acute{A} , Hoornaert A, Layrolle P. Reconstruction of large skeletal defects: current clinical therapeutic strategies and future directions using 3D printing. *Front Bioeng Biotechnol*. 2020;8:61. doi: 10.3389/fbioe.2020.00061.
- Mauffrey C, Barlow BT, Smith W. Management of segmental bone defects. *J Am Acad Orthop Surg*. 2015;23(3):143-153. doi: 10.5435/JAAOS-D-14-00018.
- Grosso A, Burger MG, Lunger A, Schaefer DJ, Banfi A, Di Maggio N. It takes two to tango: coupling of angiogenesis and osteogenesis for bone regeneration. *Front Bioeng Biotechnol*. 2017;5:68. doi: 10.3389/fbioe.2017.00068.
- Locker PH, Arthur J, Edmiston T, Puri R, Levine BR. Management of bone defects in orthopedic trauma. *Bull Hosp Jt Dis*. 2018;76:278-284.
- Nacu V. Optimizarea regenerării osoase posttraumatice dereglate [Optimization of disordered post-traumatic bone regeneration]. Chişinău: Sirius; 2010. 188 p. Romanian.
- Johnson RW Jr. A physiological study of the blood supply of the diaphysis. *J Bone Joint Surg*. 1927;9(1):153-184
- Science direct. Veterinary science and veterinary medicine. Nutrient canal. Amsterdam: Elsevier; 2020 [cited 2020 Aug 9]. Available from: <https://www.sciencedirect.com/topics/veterinary-science-and-veterinary-medicine/nutrient-canal>
- Grüneboom A, Hawwari I, Weidner D, Culemann S, Müller S, Henneberg S, et al. A network of trans-cortical capillaries as mainstay for blood circulation in long bones. *Nat Metab*. 2019;1(2):236-250. doi: 10.1038/s42255-018-0016-5.
- Shim SS, Copp DH, Patterson FP. Measurement of the rate and distribution of the nutrient and other arterial blood supply in long bones of the rabbit. A study of the relative contribution of the three arterial systems. *J Bone Joint Surg Br*. 1968;50:178-183.
- Andrzejowski P, Giannoudis PV. The "diamond concept" for long bone non-union management. *J Orthop Traumatol*. 2019;20(1):21. doi: 10.1186/s10195-019-0528-0.
- Hung NN. Basic knowledge of bone grafting. In: Zorzi AR. Bone grafting. London: IntechOpen; 2012. p. 11-38 [cited 2020 Aug 9]. Available from: <https://www.intechopen.com/books/bone-grafting/basic-knowledge-of-bone-grafting>
- Khan SN, Cammisa FP Jr, Sandhu HS, Diwan AD, Girardi FP, Lane JM. The biology of bone grafting. *J Am Acad Orthop Surg*. 2005;13(1):77-86.
- Houben RH, Kotsougiani D, Friedrich PF, Shin AY, Bishop AT. Outcomes of vascularized bone allotransplantation with surgically induced autogenous angiogenesis in a large animal model: bone healing, remodeling, and material properties. *J Reconstr Microsurg*. 2020;36(2):82-92. doi: 10.1055/s-0039-1695052.
- Pirela-Cruz MA, DeCoster TA. Vascularized bone grafts. *Orthopedics*. 1994;17(5):407-412.
- Schmidmaier G, Schwabe P, Strobel C, Wildemann B. Carrier systems and application of growth factors in orthopaedics. *Injury*. 2008;39 Suppl 2:S37-43. doi: 10.1016/S0020-1383(08)70014-7.
- Țîmbalari T, Lozan O, Nacu V. Istoricul dezvoltării transplantului de țesuturi și celule = History of tissue and cell transplantation's development. *Mold J Health Sci*. 2017;14:108-122. Romanian, English. [cited 2020 Aug 9]. Available from: https://ibn.idsi.md/ro/vizualizare_articol/59538
- Willems WF. Bone graft revascularization strategies [Internet]. Amsterdam: University of Amsterdam; 2014 [cited 2020 Jul 19]. Available from: <https://dare.uva.nl/document/2/139364>
- Kotsougiani D, Hundepool CA, Bulstra LF, Friedrich PF, Shin AY, Bishop AT. Bone vascularized composite allotransplantation model in swine tibial defect: Evaluation of surgical angiogenesis and transplant viability. *Microsurgery*. 2019;39(2):160-166. doi: 10.1002/micr.30310.
- Brookes M, Harrison RG. The vascularization of the rabbit femur and tibiofibula. *J Anat*. 1957 Jan;91(1):61-72.
- Shin AY, Dekutoski MB. The role of vascularized bone grafts in spine surgery. *Orthop Clin North Am*. 2007;38(1): 61-72, vi. doi: 10.1016/j.ocl.2006.10.011.
- Schindeler A, McDonald MM, Bokko P, Little DG. Bone remodeling during fracture repair: The cellular picture. *Semin Cell Dev Biol*. 2008;19(5):459-466. doi: 10.1016/j.semcdb.2008.07.004.
- Chen J, Zhang D, Zhang T, Chen C, Song Y, Liu S, et al. Effect of the vascularized bone components on the survival of vascularized composite allografts. *J Surg Res*. 2018;224:132-138. doi: 10.1016/j.jss.2017.03.050.
- Aebi M, Regazzoni P. Bone transplantation. Heidelberg: Springer Science & Business Media; 2012 [cited 2020 Jul 19]. Available from: <https://play.google.com/store/books/details?id=oqh3BQAAQBAJ>
- Leonard DA, Cetrulo CL Jr, McGrouther DA, Sachs DH. Induction of tolerance of vascularized composite allografts. *Transplantation*. 2013;95(3):403-409. doi: 10.1097/TP.0b013e31826d886d.
- Goorah S, Hindocha S. Therapeutic use of vascularized bone transfer for bone reconstruction. *Asian J Biomed Pharm Sci*. 2013;3(22):39-44. [cited 2020 Aug 10]. Available from: https://www.researchgate.net/profile/Smita_Goorah/publication/255721233_Therapeutic_use_of_vascularized_bone_transfer_for_bone_reconstruction/links/00b495207d3c5dd0fe000000/Therapeutic-use-of-vascularized-bone-transfer-for-bone-reconstruction.pdf
- Menger MD, Vollmar B. Role of microcirculation in transplantation. *Microcirculation*. 2000;7(5):291-306 [cited 2020 Aug 10]. Available from: <https://www.ncbi.nlm.nih.gov/pubmed/11079248>
- Korompilias AV, Paschos NK, Lykissas MG, Kostas-Agnantis I, Vekris MD, Beris AE. Recent updates of surgical techniques and applications of free vascularized fibular graft in extremity and trunk reconstruction. *Microsurgery*. 2011;31(3):171-175. doi: 10.1002/micr.20848.
- Hofmann GO, Kirschner MH. Clinical experience in allogeneic vascularized bone and joint allografting. *Microsurgery*. 2000;20(8):375-383. doi: 10.1002/1098-2752(2000)20:8<375::aid-micr6>3.0.co;2-0.
- Randolph MA, Yaremchuk MJ, Moore JR, Robinson RA, Weiland AJ. Experimental vascularized bone allografting. *Microsurgery*. 1987;8(4):210-217. doi: 10.1002/micr.1920080409.
- Shigetomi M, Doi K, Kuwata N, Muramatsu K, Yamamoto H, Kawai S. Experimental study on vascularized bone allografts for reconstruction of massive bone defects. *Microsurgery*. 1994;15(9):663-670. doi: 10.1002/micr.1920150913.
- Kotsougiani D, Hundepool CA, Bulstra LF, Friedrich PF, Shin AY, Bishop AT. Recipient-derived angiogenesis with short-term immunosuppression increases bone remodeling in bone vascularized composite allotransplantation: A pilot study in a swine tibial defect model. *J Orthop Res*. 2017;35(6):1242-1249. doi: 10.1002/jor.23378.
- Kremer T, Giessler GA, Friedrich PF, Willems WF, Giusti G, Bishop AT. Surgical angiogenesis with short-term immunosuppression maintains bone viability in rabbit allogeneic knee joint transplantation. *Plast Reconstr Surg*. 2013;131(2):148e-157e. doi: 10.1097/PRS.0b013e3182789ad4.
- Jian M, Cobzac V, Moghildea I, Popescu V, Nacu V. Techniques of liver decellularization. *Mold Med J*. 2018;61(4):21-24. doi: 10.5281/zenodo.2222303.

Authors' ORCID iDs and academic degrees

Elena Pavlovschi, MD, PhD Applicant – <https://orcid.org/0000-0001-5563-3815>

Alina Stoian, MD, PhD Applicant – <https://orcid.org/0000-0002-6138-5579>

Grigore Verega, MD, PhD, Professor – <https://orcid.org/0000-0003-0509-0765>

Viorel Nacu, MD, PhD, Professor – <https://orcid.org/0000-0003-2274-9912>

Authors' contribution

PE and SA designed the study, collected, processed, and interpreted the data and drafted the manuscript; GV and NV designed the trial and revised the manuscript critically. All the authors revised and approved the final version of the manuscript.

Funding

The research was supported by *Nicolae Testemitanu* State University of Medicine and Pharmacy, and the research project “Nanoarchitecture in base of GaN and tridimensional matrix from biologic material for application in microfluids and tissue engineering” – 20.80009.5007.20 offered by the National Agency for Research and Development of the Government of the Republic of Moldova. The authors are independent and take responsibility for the integrity of the data and accuracy of the data analysis.

Ethics approval and consent to participate

The research was approved by the Research Ethics Committee of *Nicolae Testemitanu* State University of Medicine and Pharmacy (protocol No 70/75 of 21.05.2018).

Conflict of Interests

Nothing to disclose.