

<https://doi.org/10.52418/moldovan-med-j.64-5.21.04>
UDC: 616.127-005.4+616.132.2-004.6



Correlations of myocardial bridges with left ventricle myocardial hypertrophy and prepointin coronary atherosclerosis

¹Mihail Tasnic, ²Valeriu Revenco, ³Ilia Catereniuc

¹Department of Cardiology and Interventional Cardiology, International Hospital *Medpark*

²Discipline of Cardiology, Department of Internal Medicine, ³Department of Anatomy and Clinical Anatomy
Nicolae Testemitanu State University of Medicine and Pharmacy, Chisinau, the Republic of Moldova

Authors' ORCID iDs, academic degrees and contribution are available at the end of the article

*Corresponding author – Mihail Tasnic, e-mail: mihaitasnic@gmail.com

Manuscript received August 20, 2021; revised manuscript November 10, 2021; published online November 26, 2021

Abstract

Background: Of particular interest are the studies researching the correlations of myocardial bridges with hypertrophic cardiomyopathy and correlations of thick myocardial bridges with the development of coronary atherosclerosis in the proximal to the bridge arterial part.

Material and methods: Assessment of the correlation between myocardial bridges, coronary atherosclerosis, and the degree of hypertrophy of the left ventricle was performed by retrospective analysis of 6168 coronary angiography protocols (2012-2019) and echocardiographic data from patients' clinical records.

Results: Moderate systolic compression predominated, and the number of patients detected with severe under the bridge systolic coronary stenosis was double as in patients with nonsignificant coronary atherosclerosis. From the total number, patients with myocardial hypertrophy and myocardial bridges were twice less when compared with the patients with the normal myocardial thickness. The comparative research did not show any interdependence between the degree of vascular compression and the degree of left ventricular myocardial hypertrophy. Proximal to the bridges atherosclerosis was detected in 32% of cases without correlation with the force of the myocardial bridge.

Conclusions: The study showed the absence of the correlation between the degree of arterial stenosis caused by the bridge and the degree of hypertrophy of the ventricular myocardium as well as the degree of proximal to the bridge atherosclerosis. Important finding was that the degree of coronary systolic compression is higher in patients with moderate and severe proximal to the bridge atherosclerosis.

Key words: myocardial ischemia, coronary angiography, myocardial bridge.

Cite this article

Tasnic M, Revenco V, Catereniuc I. Correlations of myocardial bridges with left ventricle myocardial hypertrophy and prepointine coronary atherosclerosis. *Mold Med J.* 2021;64(5):21-26. <https://doi.org/10.52418/moldovan-med-j.64-5.21.04>.

Introduction

The term myocardial bridge means the situation when a portion of the coronary artery with a typical subepicardial trajectory is covered, over a certain length, by a myocardial band, being included into variants of the intramural trajectory of the heart arteries [1, 2].

In patients without obstructive atherosclerotic lesions, in 50% of cases, the cause of myocardial ischemia is the myocardial bridge [3].

A myocardial bridge is a congenital anomaly, which is developing in a close correlation with adjacent vessels [4] and can cause local systolic compression of varying degrees of the subpointine vascular segment [5].

Of particular interest are the studies researching the involvement and impact of thick myocardial bridges in the occurrence of acute cardiac events without associated obstructive coronary artery disease (MINOKA), in myocardial infarction caused by under the bridge or distal to the bridge coronary thrombosis or prolonged coronary spasm [6, 7], sudden death of young people caused by major physical ex-

ertion [8], with an intact coronary arteries – especially in case of high-performance athletes [9] or hypertrophic cardiomyopathy [10].

Despite of multiple hypotheses regarding pontine etiopathogenesis, Li J. ed. (2008) stated that the ways in which myocardial bridges cause clinical manifestations are still unknown, as well as the optimal methods of their detection and treatment [11].

Myocardial bridges can have an evident impact on the patient's quality of life, considering the angina pectoris they may induce [10].

Proximal to bridge atherosclerosis [12], vasospasm [8, 13], thrombosis [14], are important etiopathogenetic links of the genesis of acute coronary syndrome.

Another specific feature of the intramural trajectory of the large coronary arteries, which is the subject of controversy, is the protective role of the myocardial bridge in preventing atherosclerosis of the under the bridge vascular segment [15].

In contrast to the subpointine antiatherogenic effect, the

frequency of atherosclerotic lesions in prepointontine vascular segment is increased [16].

Material and methods

Assessment of the correlation between myocardial bridges and the degree of hypertrophy of the left ventricular myocardium, correlation between myocardial bridges and coronary atherosclerosis was performed by retrospective analysis of 6168 coronary angiography protocols performed between 2012 and 2019 at Medpark International Hospital, Department of Cardiology and Interventional Cardiology.

The myocardial bridges were detected in 331 of the 6168 evaluated reports, representing 5.3% of the total number of cases.

Results

In 96.4% of cases the myocardial bridges were detected on the left anterior descending (LAD) artery; on the rest of coronary arteries, myocardial bridges were described in 3.6% of cases: the right coronary artery – 0.6%, the circumflex branch – 0.3%, the diagonal branches – 1.8 %, the marginal branches – 0.6%, the posterolateral branch – 0.3%. The existence of several myocardial bridges in the same patient was detected in 1.8% of cases.

The degree of subpontine arterial systolic stenosis varied within 10-95%. Of the total described myocardial bridges, in 50% of cases, they caused an insignificant systolic compression of the artery, reducing the lumen of the vessel up to 50% of the initial value (visually appreciated) and only in 16% of cases the degree of compression exceeded 75%.

In patients with coronary arteries not severely affected by atherosclerotic pathology, insignificant systolic stenosis caused by myocardial bridge of the subpontine arterial segment predominated, while in the second group of research (patients with moderate and severe atherosclerotic lesions), moderate systolic compression predominated and the

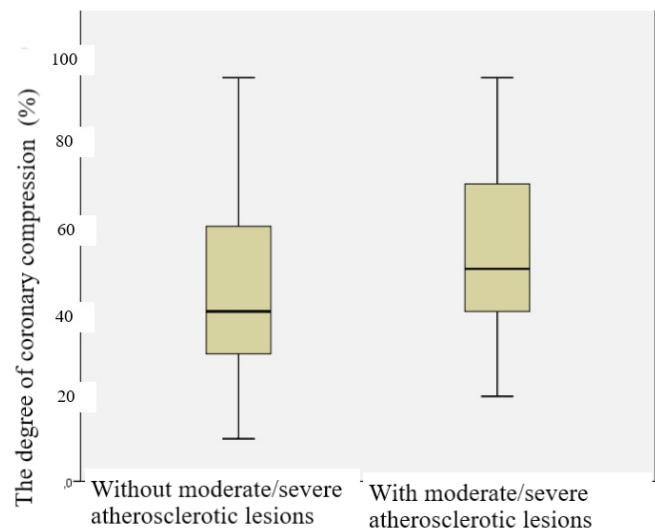


Fig. 1. The degree of the arterial systolic compression variation in the group of patients without atherosclerotic lesions and with moderate and severe coronary lesions

number of patients detected with severe subpontine systolic stenosis was double as in the first group of study (fig. 1)

Another aspect, widely discussed in the scientific literature, and thoroughly analysed, is the interdependence of the degree of systolic stenosis of the anterior interventricular branch and the degree of hypertrophy of the ventricular myocardium.

In this study, patients were divided into: the group of patients with myocardial bridges and left ventricular myocardial hypertrophy, and the group with myocardial bridges without left ventricular myocardial hypertrophy.

From the total number, patients with myocardial hypertrophy and myocardial bridges were twice less when compared with the patients with the normal myocardial thickness.

The comparative research did not show any interdependence between the degree of vascular compression caused by myocardial bridge and the degree of left ventricular myocardial hypertrophy excepting the category of patients with myocardial hypertrophy and systolic stenosis lower than 50% (fig. 2). Thereby, in patients with myocardial hypertrophy, were determined 10% more cases of vascular systolic stenosis under 50% of the vessel lumen than in patients with the same degree of vascular compression but without myocardial hypertrophy (fig. 3).

The analysis of the dependence between the myocardial bridges and proximal to the bridge coronary atherosclerotic lesions, showed in 32% of cases atherosclerotic plaques at various distances to the bridge and only in one case (0.5%) – atherosclerotic plaques with location immediately after the bridge.

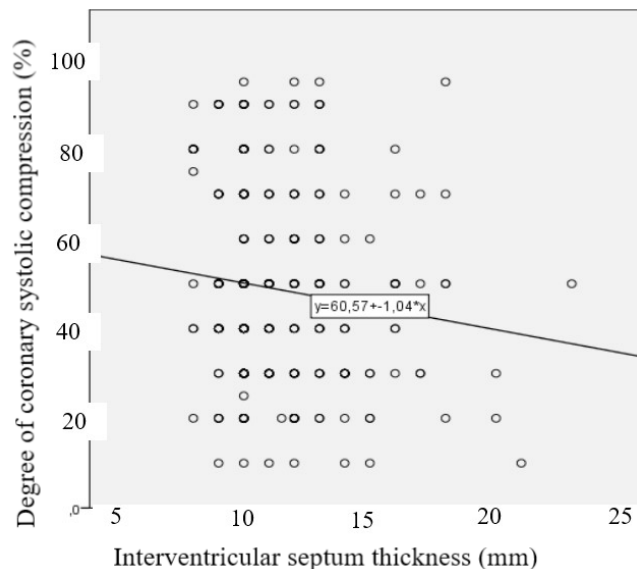


Fig. 2. Lack of direct correlation between the degree of left ventricular myocardial hypertrophy and the degree of compression of the subpontine coronary segment in the general group of research

No cases with under the bridge coronary atherosclerosis were detected.

The research did not determine the interdependence between the degree of dynamic coronary stenosis caused by bridge and the degree of proximal to the bridge atherosclerosis (fig. 4).

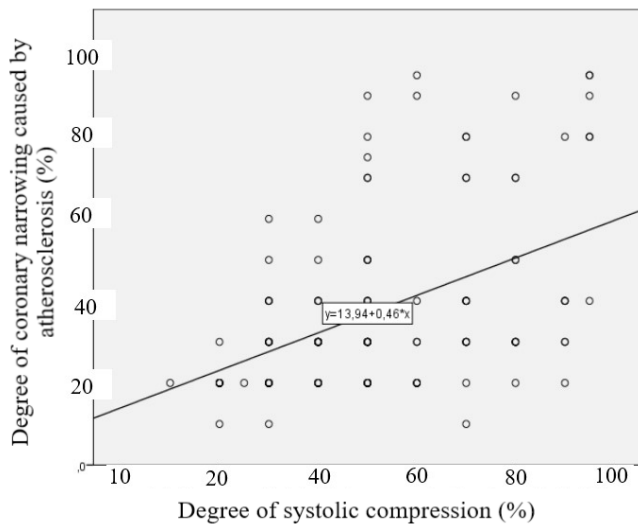


Fig. 4. Lack of direct correlation between the degree of prepointine atherosclerotic lesion and the degree of subpointine systolic stenosis

Discussion

Within the performed research, no cases were detected with atherosclerotic lesions under the myocardial bridge. The obtained data is consistent with the reports published in the medical literature. Thus, some authors attribute to myocardial bridges antiatherogenic functions [17], while the others claim the possibility of forming, in their presence, atherosclerotic plaques under the bridge in 6.7% of cases [18], thus denying the antiatherosclerotic role of the bridges [19].

Therefore, the opinions promote the idea that the association of the myocardial bridge with the atherosclerosis under the bridge is very rare [20] or that this association presents a major risk in the occurrence of acute myocardial infarction [12]. Other authors mention that if the atherosclerosis is detected under the myocardial bridge, its degree of lesion is clearly lower than the proximal to the bridge [21].

As to the protective antiatherosclerotic mechanisms, both are described, the morphological features specific to the subpointine endothelial layer, resistant to atherosclerotic lesions, and the pulsating character of the coronary vessel under the bridge [22]. In this aspect, the essential endothelial changes were highlighted, which allowed the authors to assume that they play a protective role against atherosclerosis [23]. In contrast to the subpointine antiatherogenic effect, in the proximal to the bridge vascular segment, the incidence of atherosclerotic lesions is increased [16].

Within the performed study, the atherosclerotic lesions

visualized on angiography in the proximal to the bridge arterial portion were detected in 32% of cases. However, a correlation between the degree of coronary systolic stenosis and the of plaques, and the degree of proximal to the bridge atherosclerotic stenosis, was not found.

The obtained results did not show a definite correlation between the presence of myocardial bridge and prepointine coronary atherosclerosis.

In the recent publications of Dr. Ishikawa, he affirms that myocardial bridges can be considered as risk factors for the development of atherosclerosis in certain segments of the coronary arteries, especially the proximal to the bridge ones, and in the genesis of myocardial infarction [9].

The incidence of prepointine stenosis is lower in this study than in other published data. Thus, multiple studies denote the predisposition, in 50% up to 90% of cases, of the respective segment in the formation of atherosclerotic plaques [24], increasing thereby the risk of acute coronary syndrome [25]. In this context, cases of complications of proximal to the bridge coronary atherosclerotic plaques by rupture of the fibrous capsule and acute thrombosis are reported [1].

Though, no correlation was detected between the degree of myocardial bridge compression and the incidence of atherosclerotic coronary lesions and their degree. Some authors used IVUS (intravascular ultrasonography) during the diagnostic coronary angiography and established the direct correlation between the degree of pontine compression of the vessel and the development of atherosclerotic plaque in the proximal to the bridge part of coronary artery, the degree of systolic compression being a more influential factor in the development of atherosclerotic plaque than the length, thickness and location of complete myocardial bridges [4]. Therefore, the degree of prepointine coronary damage can serve as an indicator of the severity of the myocardial bridges and the choice of the optimal treatment tactics [26].

The use of intravascular imaging methods is much more sensitive in detecting of minimal atherosclerotic lesions in the prepointine coronary segment than the conventional angiography used in the study.

As well as the dependence between the degree of coronary artery disease and the degree of coronary systolic stenosis, the causes of atherosclerotic prepointine lesions remain unclear. Some authors assume the multifactorial influence of the local, proximal to the bridge action of the blood flow, of the parietal stress, which leads to the mechanical lesion of the vascular wall [1].

This mechanical factor is caused by a retrograde blood flow, the result of the systolic expulsion of blood column from the intramural portion of the vessel.

The intima lesions resulted from the meeting of retrograde blood flow with the anterograde one, facilitate the rupture of atherosclerotic plaque and the appearance of acute coronary syndromes [1].

However, it is mentioned the existence of differences in proximal to the bridge and intramural parietal stress forces.

Thus, under the myocardial bridge the parietal stress is higher than in the proximal to the bridge coronary segment, leading to increased transendothelial distribution of lipids [1].

The mentioned effects are aggravated by the turbulent circulation of blood in the proximal to the bridge portion, at the place of meeting of the anterograde blood flow with the retrograde one [28].

These processes are confirmed by intracoronary studies by Doppler investigations [27].

A particular feature, found in the current study, is the predominance of moderate and severe systolic stenosis caused by bridges in case of proximal to the bridge atherosclerotic plaques that reduced the coronary lumen more than 50%, and the number of patients with severe subpontine systolic stenosis was double compared to the group of patients without moderate and / or severe prepontine coronary atherosclerotic lesions.

The obtained results could be explained by the intracoronary pressure and the lower intracoronary resistance in case of coronary bed severely affected by atherosclerosis plaques located proximal to the bridge with the reduction of the coronary flow proximal to the bridge and increasing compressive effect of the bridge. Consequently, it could explain why myocardial bridges bring ischemic suffering in older people and not from childhood or youth. At the same time, this peculiarity would strengthen the idea of the existence of anti-compressive mechanisms at the level of arteries and myocardial bridges, which could prevent arterial systolic stenosis, but with the progression of atherosclerosis of the coronary artery the effect of these mechanisms could be annihilated. In this case, the intracoronary pressure decreases because of proximal to the bridge coronary lesions that diminish the coronary flow.

A second explanation, hypothesis, which could explain the predominance of a more pronounced degree of under the bridge arterial compression in the group of patients with moderate and severe coronary atherosclerotic lesions, would be the medication that patients with severe ischemic heart disease are taking as chronic treatment, including nitrates, which is increasing the degree of systolic arterial stenosis reducing the intracoronary pressure [19].

The above-mentioned explanations resonate with the concepts identified in the literature, as well as the idea that nitrates could accentuate the degree of systolic stenosis of the under the bridge vascular segment by reduction the intracoronary pressure [27].

Although, some authors consider that the bridge is also protecting the distal to the bridge vascular segment from atherosclerosis [28], the results of some studies denote the possibility of atherosclerotic lesion of this segment [29]. In 25%-30% of cases, atherosclerosis can affect the postpon-

tine portion of the vessel [30]. Within the present study, these kinds of lesions were detected in only one case.

Another aspect, widely discussed in the literature and analysed in this study, is the interdependence between the degree of systolic stenosis of the anterior interventricular branch and the degree of myocardial hypertrophy [30].

Thereby, it is mentioned that the myocardial bridges are more common (up to 30%) in patients with myocardial hypertrophy [31].

At the same time, in the literature were found discrepancies regarding the influence of myocardial bridges in patients with hypertrophic cardiomyopathy and the severity of clinical manifestations.

According to some studies [30], the myocardial bridges in people with hypertrophic cardiomyopathy are worsening the clinical picture and can lead to angina pectoris, ventricular tachycardia, cardiac arrest. However, according to other authors, there is no correlation between myocardial bridges, hypertrophic cardiomyopathy, and the severity of the clinical picture [32]. There is evidence that in patients with hypertrophic cardiomyopathy, the degree of compression is increased by the myocardial bridge [30]. The importance of this correlation could explain why in certain periods of life the myocardial bridges, which are present from birth, could cause myocardial ischemia [30].

From the total number, patients with myocardial hypertrophy and myocardial bridges were twice less, in comparison to patients with normal myocardial thickness. The results contradict the literature references that myocardial bridges are more common in people with myocardial hypertrophy, assuming that hypertrophy increases the compressive effect on the vessel of the myocardial bridge. The comparative research did not highlight any relationship between the degree of under the bridge vascular compression and the degree of left ventricular myocardial hypertrophy in the general study group, except for the category of patients with myocardial hypertrophy and systolic stenosis lower than 50%.

Thus, in patients with myocardial hypertrophy, were detected 10% more cases of vascular systolic stenosis below 50% of the vessel lumen, than in patients with the same degree of vascular compression, but without myocardial hypertrophy.

It should be noted that in the performed study there were no patients with diagnosed hypertrophic cardiomyopathy. Patients from the researched group, in most cases had myocardial hypertrophy up to 15 mm, assessed by echocardiography.

This phenomenon could be explained by the fact that in case of hypertrophy below 15-20 mm, possibly, the myocardial bridge does not always have enough force to overcome the intracoronary pressure, opposed to the degree of myocardial hypertrophy encountered in hypertrophic cardiomyopathy [33].

Conclusions

1. Active systolic myocardial bridges, with potential to induce myocardial ischemia, are detected in 5.3% of patients.

2. There is no correlation between the degree of stenosis caused by the bridge and the degree of hypertrophy of the ventricular myocardium in patients without hypertrophic cardiomyopathy, as well as the degree of stenosis caused by the bridge and the degree of proximal to the bridge atherosclerotic stenosis.

3. Important finding was that the degree of coronary systolic compression is higher in patients with moderate and severe proximal to the bridge atherosclerosis.

References

1. Perl L, Daniels D, Schwartz J, Tanaka S, Yeung A, Tremmel JA, et al. Myocardial bridge and acute plaque rupture. *J Investig Med High Impact Case Reports*. 2016;4(4):1-5. <https://doi.org/10.1177/2324709616680227>.
2. Loukas M, Curry B, Bowers M, Louis RG, Bartczak A, Kiedrowski M, et al. The relationship of myocardial bridges to coronary artery dominance in the adult human heart. *J Anat*. 2006;209(1):43-50. doi: 10.1111/j.1469-7580.2006.00590.x.
3. Lee BK, Lim HS, Fearon WF, Yong AS, Yamada R, Tanaka S, et al. Invasive evaluation of patients with angina in the absence of obstructive coronary artery disease. *Circulation*. 2015;131(12):1054-60. <https://doi.org/10.1161/CIRCULATIONAHA.114.012636>.
4. Takamura K, Fujimoto S, Nanjo S, Nakanishi R, Hisatake S, Namiki A, et al. Anatomical characteristics of myocardial bridge in patients with myocardial infarction by multi-detector computed tomography. *Circ J*. 2011;75:642-648. <https://doi.org/10.1253/circj.CJ-10-0679>.
5. Qian JY, Zhang F, Dong M, Ma JY, Ge L, Liu XB, et al. Prevalence and characteristics of myocardial bridging in coronary angiogram – data from consecutive 5525 patients. *Chin Med J (Engl)*. 2009;122(6):632-5.
6. Bauters C, Chmait A, Tricot O, Lamblin N, Van Belle E, Lablanche JM. Coronary thrombosis and myocardial bridging. *Circulation*. 2002;105(1):130-130. <https://doi.org/10.1161/hc0102.100421>.
7. Sciahbasi A, Summaria F, Patrizi R, Lioy E. Cardiac arrest and myocardial bridging. *Ital Heart J*. 2004;5(11):869-71.
8. Ki YJ. Myocardial bridging presenting as myocardial ischaemia-induced cardiac arrest: a case report. *BMC Cardiovasc Disord*. 2021;21(1):1-6. <https://doi.org/10.1186/s12872-021-01975-x>.
9. Yu M, Zhou L, Chen T, Yi K, Zeng C, Tan X. Myocardia ischemia associated with a myocardial bridge with no significant atherosclerotic stenosis. *BMC Cardiovasc Disord*. 2015;15:165. <https://doi.org/10.1186/s12872-015-0158-2>.
10. Abuarqoub A, Naranjo M, Shamoan F. Myocardial bridging with left ventricular hypertrophy presenting as Wellens pattern. *Ann Transl Med*. 2017;5(20):401. doi: 10.21037/atm.2017.07.25.
11. Li J, Shang Z, Yao M, Li J, Yang Y, Chen J, et al. Angiographic prevalence of myocardial bridging in a defined very large number of Chinese patients with chest pain. *Chin Med J (Engl)*. 2008;121(5):405-8.
12. de Winter RJ, Kok WE, Piek JJ. Coronary atherosclerosis within a myocardial bridge, not a benign condition. *Heart*. 1998;80(1):91-3. doi: 10.1136/hrt.80.1.91.
13. Montone RA, Gurgoglione F, Del Buono MG, et al. The interplay between myocardial bridging and coronary spasm in patients with myocardial infarction and non-obstructive coronary arteries: pathogenic and prognostic implications. *Eur Heart J*. 2021;10(Suppl 1). <https://doi.org/10.1093/ehjacc/zuab020.139>.
14. Mays AE, McHale PA, Greenfield JC. Transmural myocardial blood flow in a canine model of coronary artery bridging. *Circ Res*. 1981;49(3):726-32. doi: 10.1161/01.res.49.3.726.
15. Wu Q, Xu Z. Surgical treatment of myocardial bridging: report of 31 cases. *Chin Med J (Engl)*. 2007;120(19):1689-93.
16. Akishima-Fukasawa Y, Ishikawa Y, Mikami T, Akasaka Y, Ishii T. Settlement of stenotic site and enhancement of risk factor load for atherosclerosis in left anterior descending coronary artery by myocardial bridge. *Arterioscler Thromb Vasc Biol*. 2018;38(6):1407-14. doi: 10.1161/ATVBAHA.118.310933.
17. Ishikawa Y, Ishii T, Asuwa N, Masuda S. Absence of atherosclerosis evolution in the coronary arterial segment covered by myocardial tissue in cholesterol-fed rabbits. *Virchows Arch*. 1997;430(2):163-71. doi: 10.1007/BF01008038.
18. Chen Y-D, Wu M-H, Sheu M-H, Chang C-Y. Myocardial bridging in Taiwan: depiction by multidetector computed tomography coronary angiography. *J Formos Med Assoc*. 2009;108(6):469-74. doi: 10.1016/S0929-6646(09)60094-2.
19. Edwards JC, Burnsides C, Swarm RL, Lansing AI. Arteriosclerosis in the intramural and extramural portions of coronary arteries in the human heart. *Circulation*. 1956;13(2):235-41. doi: 10.1161/01.cir.13.2.235.
20. Endo M, Lee YW, Hayashi H, Wada J. Angiographic evidence of myocardial squeezing accompanying tachyarrhythmia as a possible cause of myocardial infarction. *Chest*. 1978;73(3):431-3. doi: 10.1378/chest.73.3.431.
21. Belov IuV, Bogopolskaia OM. Miokardial'nyi mostik – vrozhdennaia anomaliiia koronarnogo rusla [Myocardial bridge - congenital anomaly of coronary vasculature]. [*Kardiologiiia*]. 2004;44(12):89-94. Russian.
22. Lozano I, Baz JA, López Palop R, Pinar E, Picó F, Valdés M, et al. [Long-term prognosis of patients with myocardial bridge and angiographic milking of the left anterior descending coronary artery]. *Rev Esp Cardiol*. 2002;55(4):359-64. Spanish. doi: 10.1016/s0300-8932(02)76615-3.
23. Wasilewski J, Roleder M, Niedziela J, Nowakowski A, Osadnik T, Głowacki J, et al. The role of septal perforators and “myocardial bridging effect” in atherosclerotic plaque distribution in the coronary artery disease. *Polish J Radiol*. 2015;80:195-201. doi: 10.12659/PJR.893227.
24. Duygu H, Zoghi M, Nalbantgil S, Kirilmaz B, Türk U, Ozerkan F, et al. Myocardial bridge: a bridge to atherosclerosis. *Anadolu Kardiyol Derg*. 2007;7(1):12-6.
25. Derkacz A, Nowak T, Gorawski M, Bezubka J, Szelemej R. Zakrzep w obszarze mostka mięśniowego jako przyczyna zawału serca [Thrombosis within the area of muscle bridge as a cause of myocardial infarction]. *Kardiol Pol*. 2011;69(3):291-2. Polish.
26. Yamada R, Tremmel JA, Tanaka S, Lin S, Kobayashi Y, Hollak MB, et al. Functional versus anatomic assessment of myocardial bridging by intravascular ultrasound: Impact of arterial compression on proximal atherosclerotic plaque. *J Am Heart Assoc*. 2016;5(4):e001735. doi: 10.1161/JAHA.114.001735.
27. Bourassa MG, Butnaru A, Lespérance J, Tardif JC. Symptomatic myocardial bridges: overview of ischemic mechanisms and current diagnostic and treatment strategies. *J Am Coll Cardiol*. 2003;41(3):351-9. doi: 10.1016/s0735-1097(02)02768-7.
28. Saidi H, Ongeti WK, Ogeng'o J. Morphology of human myocardial bridges and association with coronary artery disease. *Afr Health Sci*. 2010;10(3):242-7.
29. Berry JF, von Mering GO, Schmalfuss C, Hill JA, Kerensky RA. Systolic compression of the left anterior descending coronary artery: A case series, review of the literature, and therapeutic options including stenting. *Catheter Cardiovasc Interv*. 2002;56(1):58-63. doi: 10.1002/ccd.10151.
30. Sharzehee M, Chang Y, Song JB, Han HC. Hemodynamic effects of myocardial bridging in patients with hypertrophic cardiomyopathy. *Am J Physiol Hear Circ Physiol*. 2019;317(6):H1282-91. doi: 10.1152/ajpheart.00466.2019.

31. Murtaza G, Mukherjee D, Gharacholou SM, Nanjundappa A, Lavie CJ, Khan AA, et al. An updated review on myocardial bridging. *Cardiovasc Revasc Med.* 2020;21(9):1169-79. <https://doi.org/10.1016/j.carrev.2020.02.014>.
32. Basso C, Thiene G, Mackey-Bojack S, Frigo AC, Corrado D, Maron BJ. Myocardial bridging, a frequent component of the hypertrophic cardiomyopathy phenotype, lacks systematic association with sudden cardiac death. *Eur Heart J.* 2009;30(13):1627-34. doi: 10.1093/eurheartj/ehp121.
33. Zhai SS, Fan CM, An SY, Hang F, Yang YJ, Yan LR, et al. Clinical outcomes of myocardial bridging versus no myocardial bridging in patients with apical hypertrophic cardiomyopathy. *Cardiology.* 2018;139(3):161-8. doi: 10.1159/000486276.

Authors' ORCID iDs and academic degrees

Mihail Tasnic, MD, PhD Applicant – <https://orcid.org/0000-0001-7004-4402>

Valeriu Revenco, MD, PhD, Professor of Cardiology – <https://orcid.org/0000-0002-9419-025X>

Iliia Catereniuc, MD, PhD, Professor of Anatomy – <https://orcid.org/0000-0002-5479-4198>

Authors' contributions

MT conceptualized the idea, conducted literature review, wrote the manuscript, revised, and approved the final text; VR added clinical relevance; IC designed the research and revised the manuscript critically. All the authors revised and approved the final version of the manuscript.

Funding

This study was supported by *Nicolae Testemitanu* State University of Medicine and Pharmacy. It was the authors' initiative. The authors are independent and take responsibility for the integrity of the data and accuracy of the data analysis.

Ethics approval and consent to participate

The project was approved by the Research Ethics Committee of *Nicolae Testemitanu* State University of Medicine and Pharmacy (protocol No 55 of 03.06.2016).

Conflict of Interests

No competing interests were disclosed.

