

<https://doi.org/10.52418/moldovan-med-j.64-4.21.06>  
UDC: 618.19-006.6-074



## Mast cells in luminal vs non-luminal breast cancers

\*<sup>1,2</sup>Ecaterina Carpenco, <sup>1,2</sup>Veaceslav Fulga, <sup>1,2</sup>Valeriu David, <sup>1</sup>Ecaterina Foca, <sup>1,2</sup>Lilian Saptefrati

<sup>1</sup>Department of Histology, Cytology and Embryology

<sup>2</sup>Laboratory of Morphology, Nicolae Testemitanu State University of Medicine and Pharmacy  
Chisinau, the Republic of Moldova

Authors' ORCID iDs, academic degrees and contributions are available at the end of the article

\*Corresponding author – Ecaterina Carpenco, e-mail: [ecaterina.carpenco@usmf.md](mailto:ecaterina.carpenco@usmf.md)

Manuscript received July 29; revised manuscript October 05, 2021; published online October 12, 2021

### Abstract

**Background:** Tumor growth and development is determined by the mutual interaction between the cancer cells themselves and the microenvironment. It contains various elements, including immune cells. Of all, mast cells have one of the most controversial roles. The aim of the present study was to evaluate the expression of mast cell tryptase in the luminal and non-luminal subtypes of breast cancer and establish a possible link between infiltration with MCs and expression of hormone receptors.

**Material and methods:** The experimental study included 80 cases of breast carcinomas that were analyzed immunohistochemically in order to establish the molecular profile and the expression of tryptase, a specific marker of mast cells. The data were processed using the SPSS program. Pearson's coefficient ( $r$ ) and the other values were considered statistically significant in case of  $p \leq 0.05$ .

**Results:** Both intratumoral mast cells (MCit) and peritumoral mast cells (MCpt) correlated with the expression of hormone receptors for estrogen (ER) and progesterone (PR). Thus, the following relations were established: MCit and ER ( $r=0.343$ ,  $p=0.002$ ), MCpt and ER ( $r=0.394$ ,  $p=0.000295$ ) and MCpt and PR ( $r=0.386$ ,  $p=0.000409$ ). Statistically significant correlations between HER2 expression and mast cells content have not been established.

**Conclusions:** Mast cells invasion, peri- and intratumoral, is strongly influenced by the expression of hormone receptors. The luminal subtypes of breast cancer are characterized by a higher density of mast cells.

**Key words:** breast carcinoma, tryptase, mast cells, molecular subtypes

### Cite this article

Carpenco E, Fulga V, David V, Foca E, Saptefrati L. Mast cells in luminal vs non-luminal breast cancers. *Mold Med J.* 2021;64(4):35-38. <https://doi.org/10.52418/moldovan-med-j.64-4.21.06>.

### Introduction

Mast cells (MCs) are bone marrow derived cells characterized by their sensitivity to IgE-dependent stimulation and unique cytoplasmic granule contents, such as histamine, tryptase, chymase. MCs intricately associate with blood vessels and nerves in most vertebrates. They are frequent at sites that interface with the external environment such as the skin, respiratory and gastrointestinal tracts. As front-line cells at the host-environment interfaces, MCs promote host defense against pathogens by facilitating the initiation of appropriate immune responses. MCs are renowned contributors to hypersensitivity reactions and participate in tissue remodeling events and are considered pro-angiogenic, promoting vessel formation through both constitutive and immunologically mediated release of angiogenic substances [1].

The contribution of MCs to tumor development and progression has proven to be a controversial area of research. Clinical studies have suggested a link between elevated IgE or the presence of allergic disease and reduced development of melanoma, breast cancer, and some types of brain tumor [2]. The ability of MCs to promote angiogenesis is viewed as a key process in promoting tumor development [3].

MCs infiltrations have been described in a variety of human cancers, including non-small-cell lung cancer and pulmonary adenocarcinoma [4], breast cancer [5], colorectal cancer [6], and basal cell carcinoma [7]. Several studies have reported links between disease progression and survival and MC density [1, 8]. It has been proposed that MCs could display a protective effect before tumor onset, but sustain its development at later stages [9]. Tryptase, the most abundant secretory granule-derived neutral serine proteinase contained in MCs, can degrade components of the extracellular matrix and has been used as a specific marker for MCs [10]. Tryptase+ MCs are often observed in peritumoral areas in early-stage breast cancers without evidence of degranulation [1]. Historically, MC tryptase is renowned for its pro-tumorigenic role via enhancement of angiogenesis [11].

Some MCs proteases are stored in complexes with heparin. Heparin suppresses proliferation and reduces the number of breast cancer cell colonies. It was hypothesized that heparin might interrupt interactions between tumor-associated fibroblasts and cancer cells, thus impairing tumor development. Some scholars noticed that MCs are enriched in the tumor bed and invasive margin of late-stage breast cancers, especially in case of luminal subtypes [12]. In breast

cancer, as in cutaneous human tumors, the local impact of MCs on tissue remodeling and cell recruitment events, and their effect on draining lymph nodes/systemic immunity need to both be carefully considered and may not have similar disease impacts [1].

The aim: Evaluation of the expression of mast cell tryptase in the luminal and non-luminal subtypes of breast cancer and establishing a possible link between infiltration with MCs and expression of hormone receptors.

### Material and methods

This study included patients with breast carcinomas who were treated by surgery at Arad Clinical Hospital, Romania during 2013-2016. The patients did not undergo chemo- or radiotherapy before surgery.

The histological technique was described in the previous work which also regarded MCs [13]. All samples were routinely processed: fixed in 10% formalin and embedded in paraffin (Paraplast High Melt, Leica Biosystems). The blocks were then used to create tissue microarrays by TMA Grand Master (3DHISTECH Ltd., Budapest, Hungary) and cut into 4- $\mu$ m-thick sections which were placed on glass slides (Surgipath X-tra Adhesive, Leica Biosystems, Newcastle UponTyne, UK). The sections were automatically colored using Mayer's hematoxylin (Merck, Germany), aqueous eosin (Merck, Germany) and analyzed by 3 independent pathologists. The appropriate cases were selected for immunohistochemical staining.

Immunohistochemistry for estrogen receptor (ER), progesterone receptor (PR), HER2 and tryptase was performed automatically by Leica Bond-Max (Leica Biosystems, Newcastle UponTyne, UK) in order to establish the molecular subtype and to detect the MCs. Antigen retrieval was performed by incubating the slides in the Bond Epitope Retrieval Solution 1 (pH 6) and 2 (pH 9) (Leica Biosystems, Newcastle UponTyne, UK). Primary antibodies used in this study were the following: PR (clone 16), ER (clone 6F11), mast cell tryptase (10D11) and HER2 (clone CB11), all from Leica Biosystems (Newcastle UponTyne, UK), and all ready-to-use. The Bond Epitope Retrieval Solution 2, pH9, Leica Biosystems (Newcastle UponTyne, UK) was applied for 20 minutes and time of incubation was 30 minutes. The system of detection was Bond Polymer Refine Detection System. Mayer's hematoxylin was used for counterstaining (5 minutes).

ER, PR and HER2 scoring was done by standard method (according to Allred score and according to the recommendations of the American Society of Clinical Oncology, respectively) [14, 15]. The cut-off for ER and PR was 10%. The cases were classified into molecular subtypes as follows: luminal A (ER+ and/or PR+, HER2-), luminal B/HER2- (ER+, HER2- with PR <20%/or PR-), luminal B/HER2+ (ER+ and/or PR+, HER2+), HER2+ (ER- and PR-/HER2+), and triple-negative breast cancer (ER-/PR-/HER2-) [12].

The slides stained for tryptase were scanned on Axio Imager A2 microscope (Carl Zeiss, Germany) at low magnification ( $\times 100$ ), and the areas with the highest number of

positive cells were chosen. The number of MCs located in the tumor and peritumoral stroma was counted. Mast cells were subdivided into intratumoral (MCit) and peritumoral (MCpt). There were analyzed 3 microscopic fields for each type of localization, at  $\times 400$  magnification.

Data was stored in a MS Excel 2010 database and analyzed statistically by the SPSS statistical software package (SPSS Statistics 23.0; IBM, Chicago, IL, USA). Pearson's coefficient and other values were considered statistically significant in case of  $p \leq 0.05$ .

### Results

80 cases of breast carcinomas were analyzed. The mean age of patients was 66.04, ranging from 37 to 84. Most tumors were moderately differentiated (45 cases). There was found only one well differentiated case and 34 were poorly differentiated. According to the histological type, 74 cases (92.5%) were ductal invasive, 3 cases (3.8%) – lobular invasive, 2 cases (2.5%) – lobular *in situ* and 1 case (1.3%) – ductal *in situ*. The most frequent molecular subtype was luminal B/HER2+ (fig. 1).

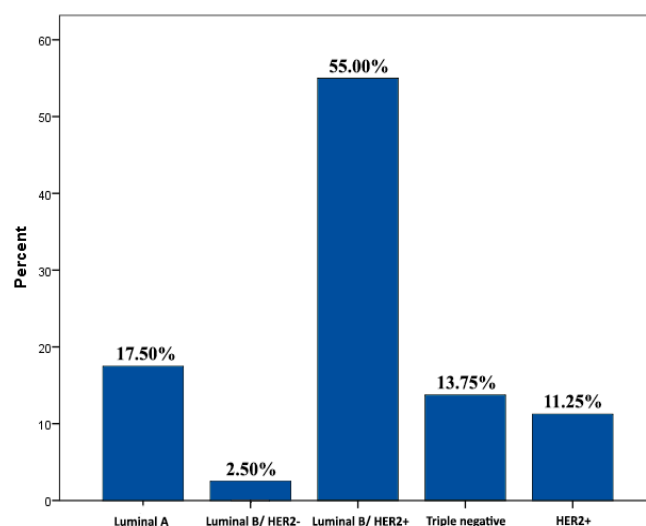


Fig.1. The distribution of molecular subtypes, n=80

Then was analyzed the distribution of MCs in different molecular subtypes. Higher numerical values of both MCit and MCpt were determined in luminal subtypes (tab. 1).

Table 1. The distribution of mast cells

Molecular subtype	Maximum numerical values	
	MCit	MCpt
Luminal B/HER2+	27.6	65.0
Luminal A	20.0	27.6
HER2+	6.0	11.3
Triple-negative	2.3	16.6

These data were also supported by statistically significant correlations. Both MCit and MCpt correlated with the expression of hormone receptors for estrogen and progester-

one. Thus, the following relations were established: MCit and ER ( $r=0.343$ ,  $p=0.002$ ), MCpt and ER ( $r=0.394$ ,  $p=0.000295$ ) and MCpt and PR ( $r=0.386$ ,  $p=0.000409$ ). Moreover, statistically significant correlations between HER2+ expression and MCs have not been established (MCit and HER2+:  $r=-0.026$ ,  $p=0.820$ ; MCpt and HER2+:  $r=0.199$ ,  $p=0.077$ ).

Mann-Whitney U test was done to compare MCit and MCpt in luminal and non-luminal subtypes. Its results supported the previous findings (tab. 2 and 3).

**Table 2. The differences between MCit and MCpt in luminal and non-luminal breast carcinomas**

	Subtype	N	Mean Rank	Sum of Ranks
MCit	Luminal	60	43.99	2639.50
	Non-luminal	20	30.03	600.50
	Total	80		
MCpt	Luminal	60	44.48	2669.00
	Non-luminal	20	28.55	571.00
	Total	80		

**Table 3. The statistics of Mann-Whitney U test**

	MCit	MCpt
Mann-Whitney U	390.500	361.000
Wilcoxon W	600.500	571.000
Z	-2.340	-2.657
Asymp.Sig. (2-tailed)	0.019	0.008

## Discussion

Tumor growth and development are determined by both, cancer cell-autonomous and microenvironmental mechanisms, including the contribution of infiltrating immune cells and the complexity of these phenomena is well recognized [4, 8, 9]. Of all, MCs have one of the most controversial roles.

Thus, several lines of evidence suggest that MCs are responsible for mediating angiogenesis [1, 16, 17]. Imada A. et al. compared survivals in the low and high MC count groups in patients with stage I lung adenocarcinoma. The members in the high MC count group had significantly worse prognosis than those in the low mast cell count group ( $p<0.05$ ). In the well- and moderate-differentiation subgroups of lung adenocarcinoma, members in the high MC count group had extremely significantly worse prognosis than those in the low MC count group ( $p<0.01$ ) [4]. Suzuki S. et al. concluded that high peritumoral MCs infiltration predicts poor prognosis in patients who underwent hepatectomy for colorectal liver metastases. The number of MCs in metastatic lesions is important for predicting the prognosis of colorectal liver metastases patients and as an indication of therapy [11]. Hu G. et al. showed in a meta-analysis including 28 published studies with 4224 patients identified from PubMed and EBSCO that tryptase+ MC infiltration significantly decreased overall survival and disease-free survival in all types of solid tumors and significantly correlated with lymph node metastasis of solid tumor [10].

However, elevated MCs at tumor sites or within draining lymph nodes have also been connected with improved outcomes [1]. Rajput AB. et al. conducted a study on tissue microarrays containing 4.444 cases and showed that the presence of stromal MCs was a favorable prognostic factor in the training set ( $p=0.001$ ) [18]. Similar to our findings, Majorini MT. et al. proved that MCs influence the phenotype of breast cancer cells by stimulating a luminal phenotype which has a better outcome. They increased expression of ER, PGR, BCL2, and CK8. Simultaneously, MCs reduce the activation of HER2 and basal drivers such as EGFR, and prevent the expression of the basal marker CK5, thus potentially affecting the behavior of neighboring cancer cells [9].

## Conclusions

Mast cells invasion, peri- and intratumoral, is strongly influenced by the expression of hormone receptors. The luminal subtypes of breast cancer are characterized by a higher density of mast cells.

## References

- Hanes MR, Giacomantonio CA, Marshall JS. Mast cells and skin and breast cancers: a complicated and microenvironment-dependent role. *Cells*. 2021;10(5):1-21. doi: 10.3390/cells10050986.
- Wulaningsih W, Holmberg L, Garmo H, et al. Investigating the association between allergen-specific immunoglobulin E, cancer risk and survival. *Oncoimmunology*. 2016;5(6):e1154250. doi: 10.1080/2162402X.2016.1154250.
- Ribatti D, Finato N, Crivellato E, et al. Angiogenesis and mast cells in human breast cancer sentinel lymph nodes with and without micrometastases. *Histopathology*. 2007;51(6):837-842. doi: 10.1111/j.1365-2559.2007.02869.x.
- Imada A, Shijubo N, Kojima H, Abe S. Mast cells correlate angiogenesis and poor outcome in stage I lung adenocarcinoma. *Eur Respir J*. 2000;15(6):1087-1093. doi: 10.1034/j.1399-3003.2000.01517.x.
- Aponte-López A, Fuentes-Panana EM, Cortes-Muñoz D, Muñoz-Cruz S. Mast cells, the neglected member of the tumor microenvironment: role in breast cancer. *J Immunol Res*. 2018;2018:2584243. doi: 10.1155/2018/2584243.
- Malfettone A, Silvestris N, Saponaro C, et al. High density of tryptase-positive mast cells in human colorectal cancer: a poor prognostic factor related to protease-activated receptor 2 expression. *J Cell Mol Med*. 2013;17(8):1025-1037. doi: 10.1111/jcmm.12073.
- Varricchi G, Galdiero MR, Marone G, Granata F, Borriello F, Marone G. Controversial role of mast cells in skin cancers. *Exp Dermatol*. 2017;26(1):11-17. doi: 10.1111/exd.13107.
- Rigoni A, Bongiovanni L, Burocchi A, et al. Mast cells infiltrating inflamed or transformed gut alternatively sustain mucosal healing or tumor growth. *Cancer Res*. 2015;75(18):3760-3770. doi: 10.1158/0008-5472.CAN-14-3767.
- Majorini MT, Cancila V, Rigoni A, et al. Infiltrating mast cell-mediated stimulation of estrogen receptor activity in breast cancer cells promotes the luminal phenotype. *Cancer Res*. 2020;80(11):2311-2324. doi: 10.1158/0008-5472.CAN-19-3596.
- Hu G, Wang S, Cheng P. Tumor-infiltrating tryptase+ mast cells predict unfavorable clinical outcome in solid tumors. *Int J Cancer*. 2018;142(4):813-821. doi: 10.1002/ijc.31099.
- Suzuki S, Ichikawa Y, Nakagawa K, et al. High infiltration of mast cells positive to tryptase predicts worse outcome following resection of colorectal liver metastases. *BMC Cancer*. 2015;15:840. doi: 10.1186/s12885-015-1863-z.
- Glajcar A, Szpor J, Pacek A, et al. The relationship between breast cancer molecular subtypes and mast cell populations in tumor microenvironment. *Virchows Arch*. 2017;470(5):505-515. doi: 10.1007/s00428-017-2103-5.

13. Carpenco E, Ceaușu RA, Cimpean AM, et al. Mast cells as an indicator and prognostic marker in molecular subtypes of breast cancer. *In Vivo* (Brooklyn). 2019;33(3):743-748. doi: 10.21873/invivo.11534.
14. Allred DC, Harvey JM, Berardo M, Clark GM. Prognostic and predictive factors in breast cancer by immunohistochemical analysis. *Mod Pathol*. 1998;11(2):155-168.
15. Wolff AC, Hammond MEH, Allison KH, et al., Human epidermal growth factor receptor 2 testing in breast cancer : American Society of Clinical Oncology / College of American Pathologists Clinical Practice Guideline Focused Update. *J Clin Oncol*. 2019;36(20):2105-2122. doi: 10.1200/JCO.2018.77.8738.
16. Raica M, Cimpean AM, Ceausu R, Ribatti D. Lymphatic microvessel density , VEGF-C , and VEGFR-3 expression in different molecular types of breast cancer. *Anticancer Res*. 2011;31(5):1757-1764.
17. Raica M, Cimpean AM, Ceaușu R, Ribatti D, Gaje P. Interplay between mast cells and lymphatic vessels in different molecular types of breast cancer. *Anticancer Res*. 2013;33(3):957-964.
18. Rajput AB, Turbin DA, Cheang MC, et al. Stromal mast cells in invasive breast cancer are a marker of favourable prognosis: a study of 4444 cases. *Breast Cancer Res Treat*. 2008;107(2):249-257. doi: 10.1007/s10549-007-9546-3.

#### Authors' ORCID iDs and academic degrees

Ecaterina Carpenco, MD, PhD Applicant, Assistance Professor – <https://orcid.org/0000-0003-1464-3149>

Veaceslav Fulga, MD, PhD, Associate Professor – <https://orcid.org/0000-0002-7589-7188>

Valeriu David, MD, PhD, Associate Professor – <https://orcid.org/0000-0001-9799-7369>

Ecaterina Foca, MD, PhD, Associate Professor – <https://orcid.org/0000-0001-7629-4875>

Lilian Saptefrati, MD, PhD, Professor – <https://orcid.org/0000-0003-2779-718X>

#### Authors' contribution

EC designed the research, collected the data, performed statistics study and interpreted the data, drafted the manuscript; VF conducted the laboratory work, revised the manuscript critically; VD conducted/performed the laboratory work; EF interpreted the data; LS conceptualized the project and designed the research, revised the manuscript critically. All the authors revised and approved the final version of the manuscript.

#### Funding

This work was supported by CNFIS-FDI-2018-0459 grant offered by Romanian Ministry of Education and Research. Special thanks to the Department of Microscopic Morphology/ Histology, Angiogenesis Research Center, *Victor Babes* University of Medicine and Pharmacy, Timisoara, Romania.

#### Ethics approval and consent to participate

This study was approved by the Research Ethics Committee of *Nicolae Testemitanu* State University of Medicine and Pharmacy, Chisinau, the Republic of Moldova (No 33/37, 12.02.2018).

#### Conflict of interests

No competing interests were disclosed.

