

## Letter to Editor

## Asian Pacific Journal of Tropical Medicine

apjtm.org



doi: 10.4103/1995-7645.312515

Impact Factor: 1.94

Isolation of *Kytococcus schroeteri* from the brown rat *Rattus norvegicus*

Shih Keng Loong<sup>1</sup>, Nurul Asma Anati Che–Mat–Seri<sup>1</sup>, Kim–Kee Tan<sup>1</sup>, Noor–Syahida Azizan<sup>1</sup>, Siti Noraisah Ahmad–Nasrah<sup>2</sup>, Siti Nursheena Mohd–Zain<sup>3</sup>, Sazaly AbuBakar<sup>1,2✉</sup>

<sup>1</sup>Tropical Infectious Diseases Research & Education Centre, High Impact Research Building, University of Malaya, 50603 Kuala Lumpur, Malaysia

<sup>2</sup>Department of Medical Microbiology, Faculty of Medicine, University of Malaya, 50603 Kuala Lumpur, Malaysia

<sup>3</sup>Institute of Biological Sciences, Faculty of Science, University of Malaya, 50603 Kuala Lumpur, Malaysia

Rodents such as *Rattus rattus* and *Rattus norvegicus* have adapted to living close to human settlements[1]. This presents a public health challenge as these rodents are considered as pests that can transmit a number of zoonotic diseases to humans[1,2]. A rodent surveillance programme was initiated between the years 2014 and 2015, focusing on rodents captured at wet markets where there is abundant food and considerable human traffic. The present study was conducted in several wet markets in Kuala Terengganu, Malaysia (5.333 3 °N, 103.150 0 °E).

Rodents were trapped alive using collapsible metal cage traps. After euthanization of the captured rodents ( $n=58$ ), selected organs (kidney, liver, lung and spleen) were aseptically harvested and homogenized. The tissue suspensions were inoculated onto Columbia agar supplemented with 5% sheep blood. The agar plates were incubated at 37 °C under ambient condition for 24–48 h. Plates with poly-microbial growth were sub-cultured until pure colonies were obtained. Bacteria from the pure colonies were Gram stained and those with atypical visual morphological characteristics were subjected to *16S* rDNA sequencing[2]. Isolate TRE153902 originating from the lung tissues of a female *Rattus norvegicus* grew small (1.0–1.5 mm in diameter), Gram-positive, mucoid, non-hemolytic, yellow-pigmented colonies after 48 h incubation (Figure 1A). Analysis of the *16S* rDNA sequences resulted in the identification of *Kytococcus* (*K.*) *schroeteri* (accession no. LR812102). The ability to hydrolyse Tween 80[3], further affirmed the isolate as *K. schroeteri* TRE153902. Inspection of the bacteria cellular structures via transmission electron microscopy revealed spherical cells in tetrads (Figure 1B), typical of the *Kytococcus* genus[4]. Assessment of the antimicrobial susceptibility using the minimum inhibitory concentration interpretive standards for *Staphylococcus* sp.[5] found that the isolate was resistant to cefuroxime, ciprofloxacin and clindamycin, oxacillin and penicillin. *K. schroeteri* TRE153902 was however, sensitive to co-trimoxazole, erythromycin, gentamicin, rifampicin and vancomycin.

While *K. schroeteri* is usually found on the human skin as harmless commensal[6,7], the originally described isolates were obtained from a 34-year-old woman with endocarditis[3]. Since then, there were numerous reports implicating *K. schroeteri* as the causative agent

causing infections in humans[3,4,6–10]. No reports of infection in animals however, has been reported. Isolation of the bacteria from lung tissues of a wild brown rat suggests infection of animals. It is not likely that the isolation was due to cross contamination as this was prevented by using adequate personal protective equipment and the washing of surgical tools in between surgical procedures. Furthermore, we would expect more than one *K. schroeteri* isolate in the event of cross contamination[2]. It was possible that *K. schroeteri* has been largely misidentified and dismissed as a contaminant in many clinical cases[6,7,9]. This was compounded by the lack of reliable automated identification systems in the clinical microbiology laboratories and the difficulty in the identification of *Kytococcus* sp. using conventional biochemical assays[6,9]. In this study, accurate identification was achieved using *16S* rDNA sequencing, complemented by Tween 80 hydrolysis. It was demonstrated that sequence-based identification remains the most practical and reliable method for the identification of emerging zoonotic bacterial pathogens[2,7].

Review of the current literature showed that reports of *K. schroeteri* in humans were predominantly associated with immunocompromised patients and those with silicone graft, prosthetic valve or shunt implantations[6–9]. Additionally, the isolation of *K. schroeteri* from the bronchoalveolar lavage fluid in a patient with pneumonia strongly implicated this pathogen as the cause of respiratory infection[10]. The finding here that *K. schroeteri* was recovered from the rat's lung tissues, raised the possibility that

✉To whom correspondence may be addressed. E-mail: sazaly@um.edu.my

This is an open access journal, and articles are distributed under the terms of the Creative Commons Attribution-Non Commercial-ShareAlike 4.0 License, which allows others to remix, tweak, and build upon the work non-commercially, as long as appropriate credit is given and the new creations are licensed under the identical terms.

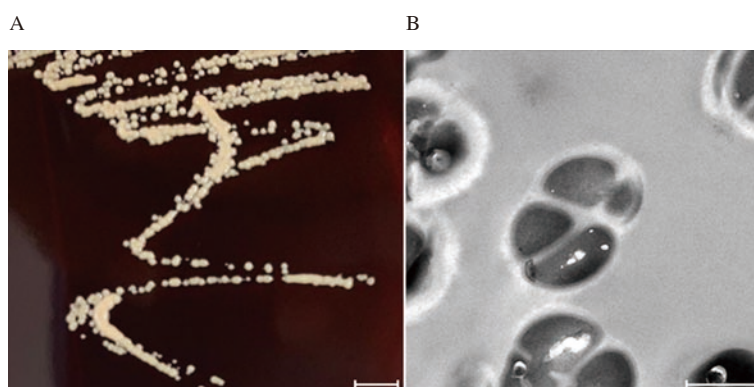
For reprints contact: reprints@medknow.com

©2021 Asian Pacific Journal of Tropical Medicine Produced by Wolters Kluwer-Medknow. All rights reserved.

How to cite this article: Loong SK, Che-Mat-Seri NAA, Tan KK, Azizan NS, Ahmad-Nasrah SN, Mohd-Zain SN, et al. Isolation of *Kytococcus schroeteri* from the brown rat *Rattus norvegicus*. Asian Pac J Trop Med 2021; 14(4): 191–192.

Article history: Received 28 November 2020  
Accepted 5 February 2021

Revision 31 December 2020  
Available online 12 April 2021



**Figure 1.** Images of *Kytococcus schroeteri* TRE153902 isolated from the lung tissues of a female *Rattus norvegicus*. (A) Culture of *Kytococcus schroeteri* TRE153902 on Columbia agar supplemented with 5% sheep blood after 48 h incubation. Scale bar=5 mm. (B) Transmission electron microscopy imaging of *Kytococcus schroeteri* TRE153902. Scale bar=500 nm.

the bacterium has a predilection towards the mammalian respiratory system. The strong expression of the adhesion-associated genes possibly aided the anchoring of bacteria onto respiratory tissues in the case of *K. schroeteri*-related pneumonia[10]. It is also possible that the strong adhesion trait of *K. schroeteri* supported its attachment onto medical implants such as prosthetic valves[7].

Even though clinicians are divided in deciding the best antimicrobial treatment for *K. schroeteri* human infections, they all agree that this species is intrinsically resistant to penicillin and oxacillin[3,7–10]. While it appears that *K. schroeteri* TRE153902 is sensitive to erythromycin, others have reported a resistant phenotype[3]. The *K. schroeteri* TRE153902 unlike other previously reported clinical isolates, was found resistant to cefuroxime[9] and ciprofloxacin[4]. This suggests that treatment of infection with *K. schroeteri* TRE153902 has to be guided by the antimicrobial susceptibility test results, though gentamicin and rifampicin would be effective in general[3,4,7–10].

The finding of *K. schroeteri* in a common brown rat highlights the potential of zoonotic spillover to humans. Further studies are required to determine the prevalence of *K. schroeteri* in the rodent population. This is especially important since emerging bacterial pathogens may be harboring resistant and virulent genes that are harmful to humans and easily transferable to other bacteria species.

This study received approval from the University of Malaya Institutional Animal Care and Use Committee (Reference no. ISB/31/01/2013/SNMZ (R)) and did not involve any endangered or protected animal species.

### Conflict of interest statement

The authors declare that there are no competing interests.

### Funding

This study was supported in parts by the research grants from the Ministry of Higher Education, Malaysia for niche area research (Vector: rodents) under the Higher Institution Centre of Excellence (HiCoE) program (MO002-2019), and the University of Malaya, under the Research University grants (RU005-2020 and RU002-2019) and the UMCoE Top 100 Research Grant (UM.00000188/HGA.GV).

### Authors' contributions

S.K.L., N.A.A.C.M.S., K.K.T., N.S.A. and S.N.A.N performed the experiments. S.N.M.Z. managed the field collection of rodents. S.K.L. wrote the manuscript together with S.A., who obtained funding for the study.

### References

- [1] Mohd-Taib FS, Mohd Sham RA, Hassan H, Aqma WS. Identification of bacteria from oral and rectal swabs from different species of rodents in Kemasul Forest Reserve, Pahang. *J Wildl & Parks* 2018; **33**: 75-93.
- [2] Loong SK, Johari J, Che Mat Seri NAA, AbdulRazak O, Douadi B, Ahmad Nasrah SN, et al. Isolation and identification of an emerging pathogen, *Kocuria marina*, from *Rattus rattus diardii*. *Trop Biomed* 2016; **33**: 589-593.
- [3] Becker K, Schumann P, Wüllenweber J, Schulte M, Weil HP, Stackebrandt E, et al. *Kytococcus schroeteri* sp. nov., a novel Gram-positive actinobacterium isolated from a human clinical source. *Int J Syst Evol Microbiol* 2002; **52**: 1609-1614.
- [4] Ha J, Kim KH, Kim JO, Hong JS, Jeong SH, Lee K. Bacteraemia caused by *Kytococcus schroeteri* in a pneumonia patient. *J Med Microb Diagn* 2015; **4**: 1000199.
- [5] Clinical and Laboratory Standards Institute. M100S. *Performance standards for antimicrobial susceptibility testing*. 26th edition. Wayne: Clinical and Laboratory Standards Institute; 2016.
- [6] Bayraktar B, Dalgic N, Duman N, Petmezci E. First case of bacteremia caused by *Kytococcus schroeteri* in a child with congenital adrenal hyperplasia. *Pediatr Infect Dis J* 2018; **37**: e304-e305.
- [7] Al Tamtami WN, Al Yaqubi F, Al Jardani A, Al Riyami M, Cormican M. First report of *Kytococcus schroeteri* prosthetic valve endocarditis in Oman. *J Microbiol Exp* 2019; **7**: 247-248.
- [8] Chan JFW, Wong SSY, Leung SSM, Fan RYY, Ngan AHY, To KKW, et al. First report of chronic implant-related septic arthritis and osteomyelitis due to *Kytococcus schroeteri* and a review of human *K. schroeteri* infections. *Infection* 2012; **40**: 567-573.
- [9] Schaumburg F, Schmalstieg C, Fiedler B, Brentrop A, Omran H, Becker K. A bumpy road to the diagnosis of a *Kytococcus schroeteri* shunt infection. *J Med Microbiol* 2013; **62**: 165-168.
- [10] Mohammadi I, Berchiche C, Becker K, Belkhouja K, Robert D, Von Eiff C, et al. Fatal *Kytococcus schroeteri* bacteremic pneumonia. *J Infect* 2005; **51**: e11-e13.