


Primary Care Doctors' Role in Antenatal Detection and Management of Fetal Bilateral Pleural Effusions: A Report of 2 Cases

Chai Li Tay ¹, Noor Afiqah AW ²

1. Simpang Health Clinic, District of Larut, Matang and Selama, Taiping, Perak, Ministry of Health Malaysia
2. Changkat Jering Health Clinic, District of Larut, Matang and Selama, Taiping, Perak, Ministry of Health Malaysia

ARTICLE INFO

Case Report

Received: 10 April 2021

Accepted: 2 June 2021



Corresponding Author:

Chai Li Tay

chailitay.research@gmail.com

ABSTRACT

Introduction: Fetal pleural effusion is rarely seen in primary care setting. It is more commonly diagnosed among women with diabetes mellitus in pregnancy.

Method: This report illustrates two patients with fetal bilateral pleural effusions, detected at 18-week and 24-week period of amenorrhea (POA) during routine antenatal scans by primary care doctors.

Result: These two pregnancies were complicated with hydrops fetalis and resulted in fresh stillbirth and intra-uterine death.

Conclusion: Primary healthcare providers play an important role in the early diagnosis of fetal congenital anomaly, counseling regarding the ultrasonography findings, neonatal outcome, and referral to obstetrician for further management and monitoring for maternal complications, such as polyhydramnios, preeclampsia, mirror syndrome, and depression as a result of hydrops fetalis.

Key Words: Antenatal, Fetal Bilateral Pleural Effusions, Primary Care Clinic

How to cite this paper:

Chai Li Tay, Noor Afiqah AW. Primary Care Doctors' Role in Antenatal Detection and Management of Fetal Bilateral Pleural Effusions: A Report of 2 Cases. J Community Health Research 2021; 10(2): 112-116.

Introduction

Fetal pleural effusions is a rare condition affecting 1 in 15,000 pregnancies and is associated with chromosomal abnormalities (1, 2). Pleural effusions are most commonly detected in the second or early third trimester of pregnancy (3). In order to detect fetal anomaly early, sonography is performed at 18-20 weeks period of amenorrhea (POA) in primary care setting in addition to the compulsory scans at every trimester. Antenatal ultrasonography is essential to help the diagnosis of fetal growth anomaly. Primary care doctors should be equipped with ultrasonographic skills to identify fetal congenital anomaly for early intervention by the obstetricians.

There is no concrete evidence to suggest the association among diabetes mellitus, parity, and fetal pleural effusions. However, within a year in the studied health clinic, two patients, who similarly had gestational diabetes mellitus (GDM) and grandmultiparity, were diagnosed to have fetal pleural effusions. Subsequently, timely referral to obstetrician and close monitoring for maternal complications, such as polyhydramnios, preeclampsia, and psychosocial well-being were carried out.

Case Report 1

Madam N, 40-year-old, Gravida 6 Para 5, had her booking done at 9-week POA with date verified via dating scan. Her BMI was 21kg/m². She was diagnosed to have GDM at 18-weeks POA with her modified glucose tolerance test (MGTT) of 5.2/8.0mmol/L. Throughout the pregnancy; she had good glycaemic control on diet control and normal haemoglobin. She was normotensive and non-proteinuria throughout her pregnancy.

Antenatal scan at 18-week 3-day reviewed the fetus and had bilateral pleural effusion (Figure 1) and referral to fetomaternal team of obstetrics and gynaecology (O&G) was made. First, detailed scan at 20 weeks by fetomaternal specialist showed bilateral pleural effusion, without pericardial effusion, skin oedema, and ascites. Second detailed scan at 23-week POA noted skin oedema over scalp apart from bilateral pleural effusion. Amniocentesis

showed normal result, indicating that the condition is not inherited as absence of chromosomal abnormality. Madam N and her husband decided to continue the pregnancy. Toxoplasmosis, rubella, cytomegalovirus, herpes simplex (TORCHES), and parvovirus screening were negative. At 28-week POA, the patient perceived absence of fetal movement. Ultrasound showed absent fetal cardiac activity, ascites, and thick abdominal wall (Figure 2) except for scalp oedema and pleural effusion. She delivered a fresh stillbirth weighing 900g after inducing labour and she currently has an intrauterine contraceptive device (IUCD).

Case Report 2

Madam S, 34-year old, Gravida 6 Para 2+3, had her booking done at 14-week POA. She had a history of 3 consecutive spontaneous miscarriages without a specific cause. At 5th pregnancy, she had premature delivery via emergency lower segmental caesarean section due to fetal distress at 34-week POA, and GDM on diet control. At current pregnancy, she was underweight with BMI of 17.1 kg/m². She had subclinical hyperthyroidism and GDM on diet control (MGTT 4.2/8.5mmol/L). Otherwise, she was normotensive, non-proteinuric and non-anaemic throughout her pregnancy.

Her antenatal sonography at 24-week POA indicated fetal bilateral pleural effusion, left more than right side, where left massive pleural effusion pushing left lobe of lung and the heart to the right thoracic cavity, no pericardial effusion, both lungs hypoplasia (Figure 3), fetal scalp oedema (Figure 4), and ascites (Figure 5). Subsequently, the ultrasound findings were confirmed by O&G specialist and explained to Madam S. She was counselled regarding the poor prognosis of fetal outcome in view of early onset of hydrops fetalis and bilateral lungs hypoplasia. TORCHES and Parvovirus screening were negative. Madam S refused for amniocentesis and opted for conservative management. At 32-week POA, she perceived contraction pain with no fetal movement. Intrauterine death was confirmed and a fresh stillbirth weighing 1.1kg was delivered. Currently,

she gets 150mg intramuscular Medroxyprogesterone every 3-month as family planning.

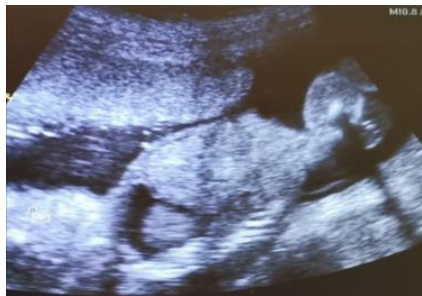

Figure 1. Obstetrical ultrasonography indicates bilateral pleural effusion at 18-week 3-day POA

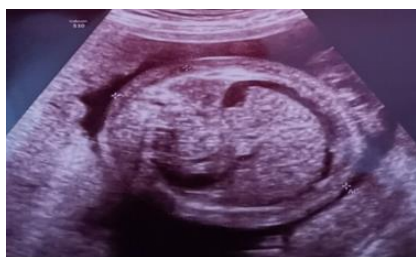

Figure 2. Obstetrical ultrasonography indicates fetal ascites and thick abdominal wall at 28 weeks POA

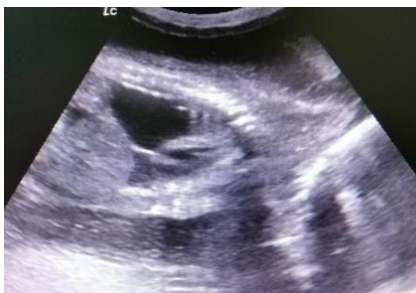

Figure 3. Obstetrical ultrasonography indicates fetal bilateral pleural effusion, left more than right side, where left massive pleural effusion pushing left lobe of lung and the heart to the right thoracic cavity, no pericardial effusion, both lungs hypoplasia at 24 weeks POA

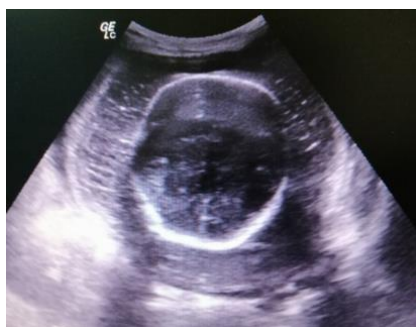

Figure 4. Obstetrical ultrasonography indicates fetal scalp oedema at 24 weeks POA

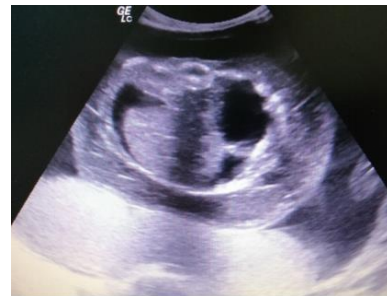

Figure 5. Obstetrical ultrasonography indicates fetal ascites at 24 weeks POA

Discussion

Both grand-multiparous patients, over the age of 25 years and without overweight, had GDM. This is not surprising as the prevalence of GDM in Asia is 11.5% (4). However, there was no evidence to support the association between GDM and fetal pleural effusion. A study showed that 35% of 246 fetuses with pleural effusions were aneuploidy in genetic analysis (5). The most commonly associated chromosomal abnormalities include trisomy 21 and 45,X (5, 6). Increased risk of genetic abnormalities associated with pleural effusions results in invasive genetic testing with amniocentesis, chorionic villus sampling, or pleural fluid aspiration (5). Determining the karyotype prenatally may help in prognosticating the fetal outcome and shared-decision making between doctors and couples in the management plan for current and future pregnancies. Madam N and her husband decided to continue the pregnancy after knowing that the amniocentesis was normal. On the other hand, madam S insisted to continue the pregnancy regardless of the result of amniocentesis, thus she refused to perform the invasive procedure.

Sonographically, pleural effusions appear as anechoic fluid surrounding one or both lungs (Figures 1 and 3) and should be distinguished from pericardial effusion by the typical “bat wing” appearance of the freely floating lungs within the surrounding fluid (7). Antenatal sonographic poor prognostic indicators include associated malformations (8), hydrops (3), diagnosis before 33 weeks (2), bilaterality of effusions (2, 8), unilateral effusions with mediastinal shift (2), and prematurity

(2, 9). Both of the fetuses were diagnosed to have bilateral pleural effusions before 33-week POA and developed hydrops fetalis. Hydrops fetalis is diagnosed when there is accumulation of fluid in at least two fetal compartments, such as pleural effusions and ascites in the patients (10). The main cause of neonatal death was respiratory distress due to pulmonary hypoplasia and pleural effusion (11). Therefore, counseling on the fetal outcome must be done comprehensively by the doctors to allay patients' anxiety and prevent unmet expectations.

The primary healthcare providers also need to monitor the maternal weight, blood pressure, symphysis-fundal height, urine protein, and legs swelling more frequently compared to usual practice. This is because polyhydramnios and preeclampsia were the commonest prenatal maternal complications (12). Moreover, rare but potentially life-threatening obstetric complications, mirror syndrome, maternal edema, hypertension, and proteinuria in association with fetal hydrops need to be ruled out when preeclampsia is suspected (13). Close intrapartum and postnatal care is required; since postpartum hemorrhage or difficulty with

placental delivery may occur due to placental swelling (12).

Conclusion

Antenatal ultrasonography during 18 to 20 weeks POA enables primary care doctors to detect fetal pleural effusions especially for those pregnant grand-multiparous with diabetes mellitus. Early diagnosis is paramount for further investigation of chromosomal abnormalities and intervention by the O&G team. Monitoring of the potentially obstetric and psychosocial complications derived from fetal pleural effusions is also imperative.

Authors' contribution

CLT and NAAW contributed to the patients' diagnosis and management, to the case reports and CLT wrote the manuscript.

Conflict of Interest

The authors declare that there is no conflict of interest.

Acknowledgement

Thanks are owed to the patients who permitted to publish their case reports.

References

1. Hidaka N, Chiba Y. Fetal hydrothorax resolving completely after a single thoracentesis: A report of 2 cases. *The Journal of Reproductive Medicine*. 2007;52(9):843-8.
2. Longaker MT, Laberge J-M, Dansereau J, et al. Primary fetal hydrothorax: natural history and management. *Journal of Pediatric Surgery*. 1989; 24(6):573-6.
3. Rustico MA, Lanna M, Coviello D, et al. Fetal pleural effusion. *Prenatal Diagnosis: Published in Affiliation With the International Society for Prenatal Diagnosis*. 2007;27(9):793-9.
4. Lee KW, Ching SM, Ramachandran V, et al. Prevalence and risk factors of gestational diabetes mellitus in Asia: a systematic review and meta-analysis. *BMC Pregnancy and Childbirth*. 2018;18(1):1-20.
5. Waller K, Chaithongwongwatthana S, Yamasmit W, et al. Chromosomal abnormalities among 246 fetuses with pleural effusions detected on prenatal ultrasound examination: factors associated with an increased risk of aneuploidy. *Genetics in Medicine*. 2005;7(6):417-21.
6. Yinon Y, Grisaru-Granovsky S, Chaddha V, et al. Perinatal outcome following fetal chest shunt insertion for pleural effusion. *Ultrasound in obstetrics & gynecology*. 2010;36(1):58-64.
7. Yinon Y, Kelly E, Ryan G. Fetal pleural effusions. *Best Practice & Research Clinical Obstetrics & Gynaecology*. 2008;22(1):77-96.
8. Nicolaidis K, Azar G. Thoraco-amniotic shunting. *Fetal Diagnosis and Therapy*. 1990;5(3-4):153-64.
9. Weber AM, Philipson EH. Fetal pleural effusion: a review and meta-analysis for prognostic indicators. *Obstetrics and gynecology*. 1992;79(2):281-6.
10. Langlois S, Wilson RD, Pandya PP, et al. 36 - Fetal Hydrops. *Fetal Medicine (Third Edition)*. London: Content Repository; 2020. p. 427-42.e2.

11. Okai T, Baba K, Kohzuma S, et al. [Nonimmunologic hydrops fetalis: a review of 30 cases]. *Nihon Sanka Fujinka Gakkai Zasshi*.1984;36(10):1813-21.
12. Hutchison AA, Drew JH, Yu VY, et al. Nonimmunologic hydrops fetalis: a review of 61 cases. *Obstetrics and gynecology*.1982;59(3):347-52.
13. Kaiser IH. Ballantyne and triple edema. *American Journal of Obstetrics & Gynecology*.1971;110(1):115-20.