

Evaluation of apical foramen position and distance from the anatomical apex of roots in anterior maxillary teeth by cone-beam computed tomography (CBCT) in a selected Iranian population

Fereshteh Arsari¹, Farida Abesi², Hemmat Gholinia³, Ali Soleymani^{4*}

1. Dental Student, Student Research Committee, Babol University of Medical Sciences, Babol, Iran.
2. Associate Professor, Dental Materials Research, Health Research Institute, Babol University of Medical Sciences, Babol, Iran.
3. Msc in Statistics, Health Research Institute, Babol University of Medical Sciences, Babol, Iran.
4. Assistant Professor, Oral Health Research Center, Health Research Institute, Babol University of Medical Sciences, Babol, Iran.

Article Type

ABSTRACT

Research Paper

Introduction: Enough knowledge of the internal anatomy and apical foramen of a tooth has always been a fundamental prerequisite for root canal therapy. The current study aimed to determine the position and distance of apical foramen to anatomical apex in maxillary anterior teeth in cone-beam computed tomography (CBCT) in the Iranian population.

Materials & Methods: In this retrospective cross-sectional study, CBCT scans of 250 patients referred to a dental clinic in the city of Babol, Mazandaran province, are investigated. The inclusion criteria were being aged 18 to 70 years, and having maxillary teeth from right canine to left canine. The exclusion criteria were history of trauma in the anterior of maxilla, the openness of the apex, not finding the apex, endodontically treated tooth, surgery in the apical area, and dental anomalies. Maxillary anterior teeth were examined for apical foramen position and radiographic foramen-apex distance by CBCT in coronal and sagittal planes. Age, gender, and quadrant of teeth were recorded, and their association with radiographic foramen-apex distance was investigated. Finally, data were analyzed using ANOVA and Independent T-test with $P \leq 0.05$ was considered significant.

Results: The mean foramen-apex distance in central incisor teeth was 0.53 ± 0.28 mm, in lateral incisor teeth was 0.56 ± 0.31 mm, and in canine teeth was 0.76 ± 0.39 mm. The frequency of apical foramen position in central and lateral teeth was 34.1% and 22.6% centrally, and in canine teeth was 20% distally, respectively. Age and quadrant had no effect on foramen-apex distance. The radiographic foramen-apex distance was higher in men than women, which was statistically significant (P -value=0.003).

Conclusion: Based on the findings, it seems that in the treatment of the root of the anterior teeth of the maxilla, if the working length is considered to be 1 mm shorter than the radiographic apex, it will be better.

Received: 21 Dec 2020

Keywords: Tooth Apex, Maxilla, Cone-Beam Computed Tomography

Accepted: 12 Sept 2021

Cite this article: Arsari F, Abesi F, Gholinia H, Soleymani A. Evaluation of apical foramen position and distance from the anatomical apex of roots in anterior maxillary teeth by cone-beam computed tomography (CBCT) in a selected Iranian population. *Caspian J Dent Res* 2021; 10: 20-9.



© The Author(s).

Publisher: Babol University of Medical Sciences

* **Corresponding Author:** Ali Soleymani, Department of Endodontics, Faculty of Dentistry, Babol University of Medical Sciences, Babol, Iran.

Tel: +981132291408

E-mail: soleymani_ali@yahoo.com

Introduction

The success of endodontic treatment is closely related to anatomical knowledge of the dental anatomy and its variations ^[1] because sufficient debridement and 3D filling are based on this information. In addition to removing pulp tissue and pathogenic microorganisms, root canal formation intends to create a cone shape that is appropriate for filling the teeth. ^[2] The apical terminal of the tooth has an important landmark, indicating the extent of the damage for preparation and filling the root canal. The apical foramen is the main opening to the apical of the root canal and is the position of endodontic filling in endo-treatment. ^[3] In most cases, apex and apical foramen are used interchangeably. The anatomical apex is the anatomical end of the root observed in radiography, while the apical foramen is the main opening of the root canal as well as the anatomical apex is different from the radiographic apex. ^[4]

Several studies have investigated the association between apical foramen and apex root. These studies reported that although apical foramen and root apex are anatomically close, they are rarely matched. ^[4] For the first time, Kuttler in a study concluded that this adaptation decreases with age, and the apical foramen and apex root distance can increase to 607-495 microns. ^[5] During root formation, the apical foramen is usually located at the anatomical end of the root, but simultaneous with the completion of the root and eruption of the foramen apical tooth, it becomes smaller, and the distance from the center increases. Anatomically, relative to the apex, apical foramen can be placed in mesial, distal, buccal, and lingual positions. ^[6] Wu et al. reported that in more than 60% of canals, the apical foramen is not positioned in the apex, and the distance between apical foramen and radiographic decay varies from 0 to 3 mm. ^[7] This apical deviation of the foramen is due to aging and cement deposition. Besides, the degree of deviation varies by tooth type. ^[8] During the past three decades, different methods such as clearing, modeling, histologic, and radiographic have been used to evaluate the root canal structure. ^[9] Recently, the application of cone-beam computed tomography (CBCT) has increased significantly, as it can provide 3D observation of anatomical structures and pathological conditions. ^[10] Estrela et al. have used CBCT to investigate the position of apical foramen compared to the anatomical apex in the anterior teeth of maxillary and mandibular. ^[11] The CBCT has provided the possibility of 3D evaluation of root canal with high quality and without degradation of dental structure ^[12,13] because foramen deviation from the apex is common in different species. Therefore, the aim of the current study was to determine the position and distance of apical foramen compared to the anatomical apex of roots in anterior maxillary teeth by CBCT in a selected population of Iran.

Materials & Methods

In this cross-sectional retrospective study, the CBCT scans of 250 patients (Power of the test=80%, Std deviation=0.17, $\alpha=0.05$) referred to a dental clinic in the city of Babol, Mazandaran province were investigated. The youngest and oldest participants were 18 and 70 years old, respectively. Those with a history of trauma in the anterior maxillary, openness of the apex, not finding the apex, endodontically treated tooth, surgery in the apical area, and dental anomalies were excluded. The study was confirmed by the Ethics Committee of the Deputy for Research Affairs of the Babol University of Medical Sciences (Code: IR.MUBABOL.HRI.REC.1398.027). Samples were selected from patients (male and female) in private Oral and Maxillofacial Radiology clinic during a year. CBCT images provided by Giano (NewTom, Verona, Italy); operated at 90 kVp and 10mA. The field of the view was 8×8cm, and the voxel size was 75 μm . Images in sections of 0.5 mm with intervals of 1 mm in coronal and sagittal plans in terms of the tenth millimeter were prepared by NNT software (Figure 1). Therefore, for a more accurate and appropriate examination of the teeth in the axial view, only lower one-third of the roots of the upper anterior teeth was investigated. Then, in the axial view, the roots were examined horizontally (parallel to the occlusal surface) so that they passed through the upper sections of the teeth and parallel to the sagittal plane. In the first mode, images were cross-sectional or on sagittal mode (Figure 2,3), in which Bucco and Lingual surfaces were examined. In the second mode, the coronal view of mesiodistal teeth was investigated (Figure 4,5). It is worth noting that apical foramen may be mesiodistal or buccolingual compared to the outer surface of the tooth. Hence, in both coronal and

sagittal views, the distance between apical foramen and perpendicular and tangential line on radiographic apex (in 10 mm) was measured by NNT software. This size was evaluated in the coronal view and confirmed in the sagittal view.

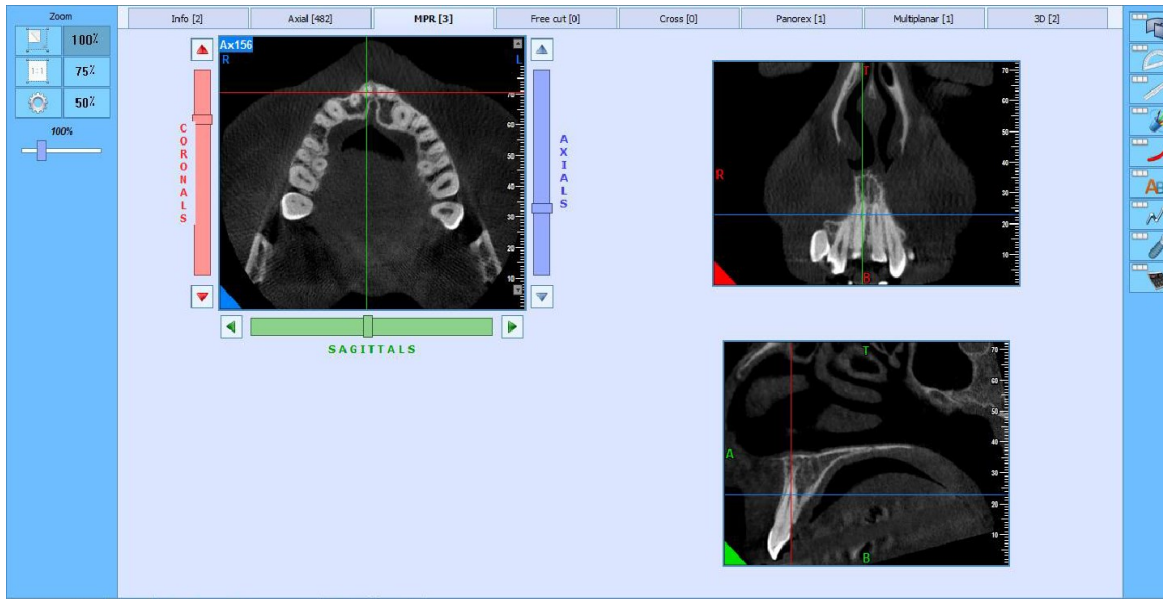

Figure 1. Evaluation of the right central tooth of the maxillary in the coronal and sagittal planes using NNT software

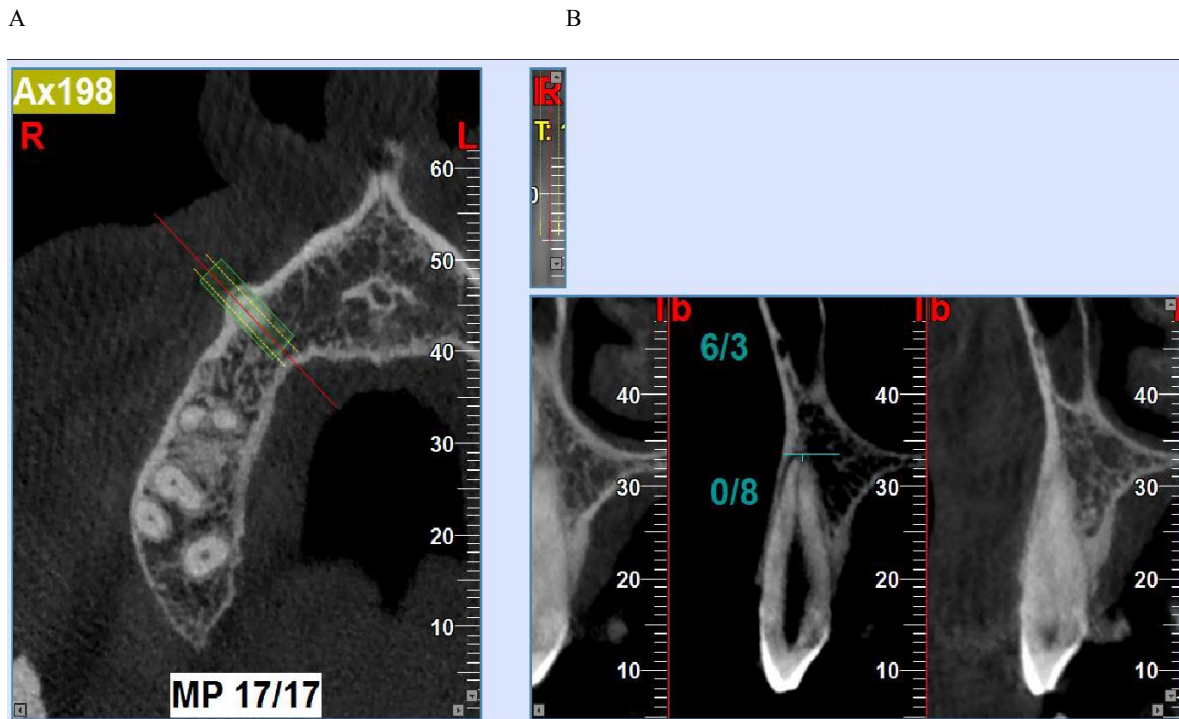


Figure 2. (A) The axial view of the right canine tooth and the manual incision lines; (B) The modified sagittal cross-sectional view of the same tooth to measure the distance from apical foramen to the anatomical apex of the root using a ruler in the NNT software

A

B

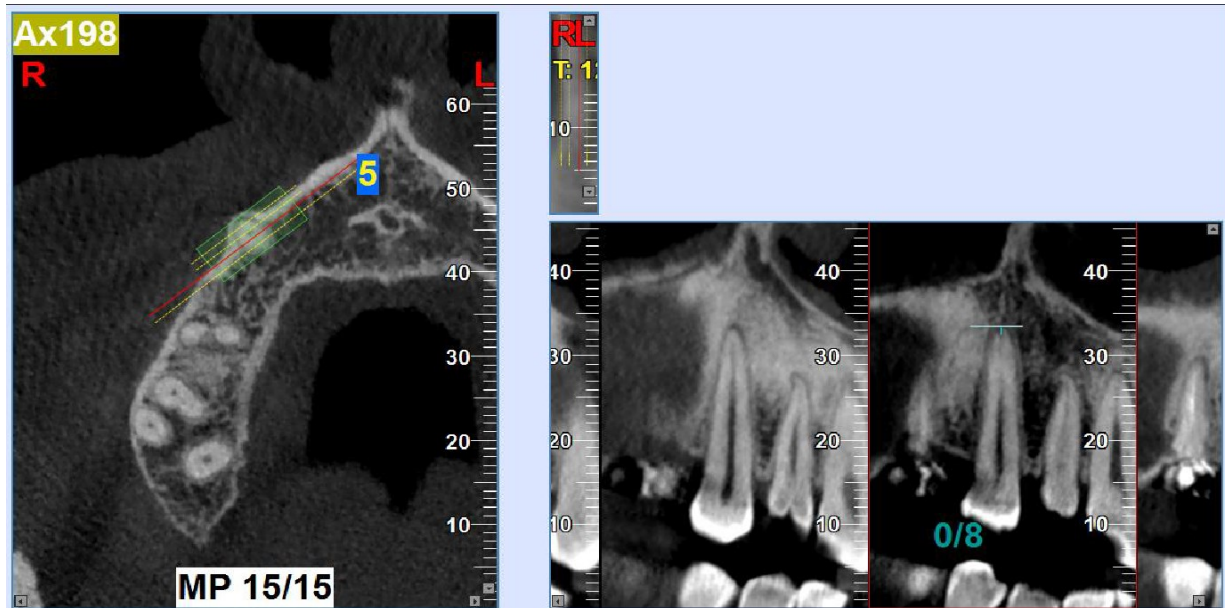


Figure 3. (a) The axial view of the right maxillary canine and lines of the incision perpendicular to the long axis of the tooth ;(B) The coronal view of the right maxillary canine to measure the distance from apical foramen to the anatomical apex of the root using a ruler in NNT software

A

B

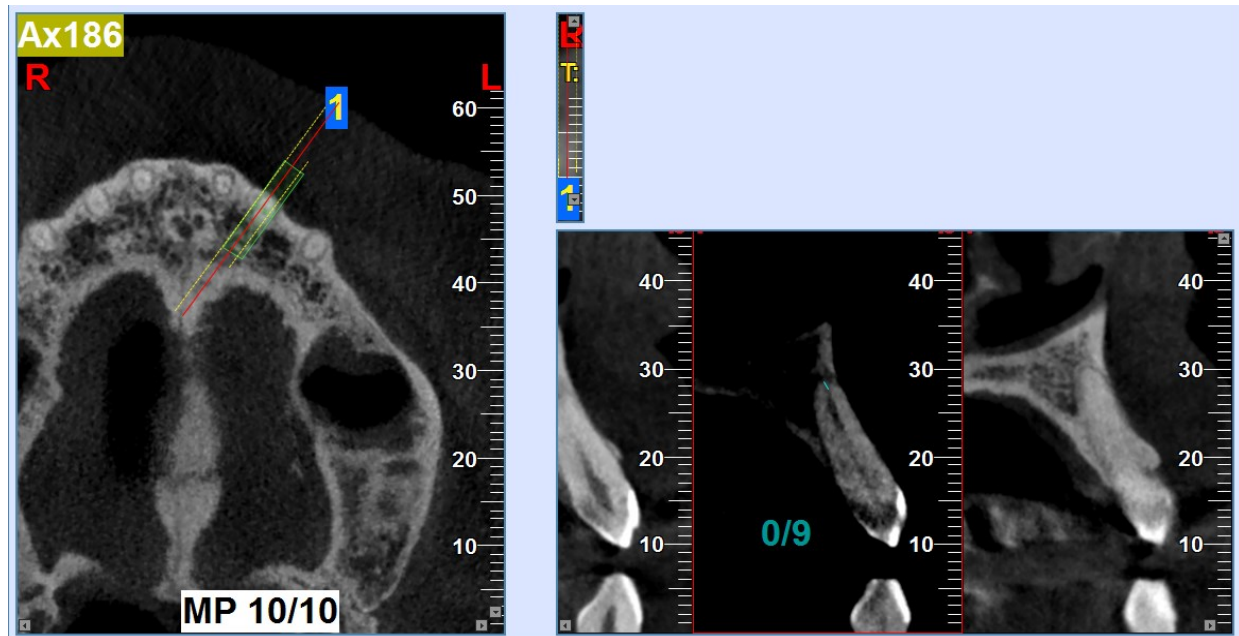


Figure 4. (A)The axial view of the left maxillary lateral; (B) The modified sagittal cross-sectional view of the same tooth to measure the distance from apical foramen to the anatomical apex of the root using a ruler in the NNT software

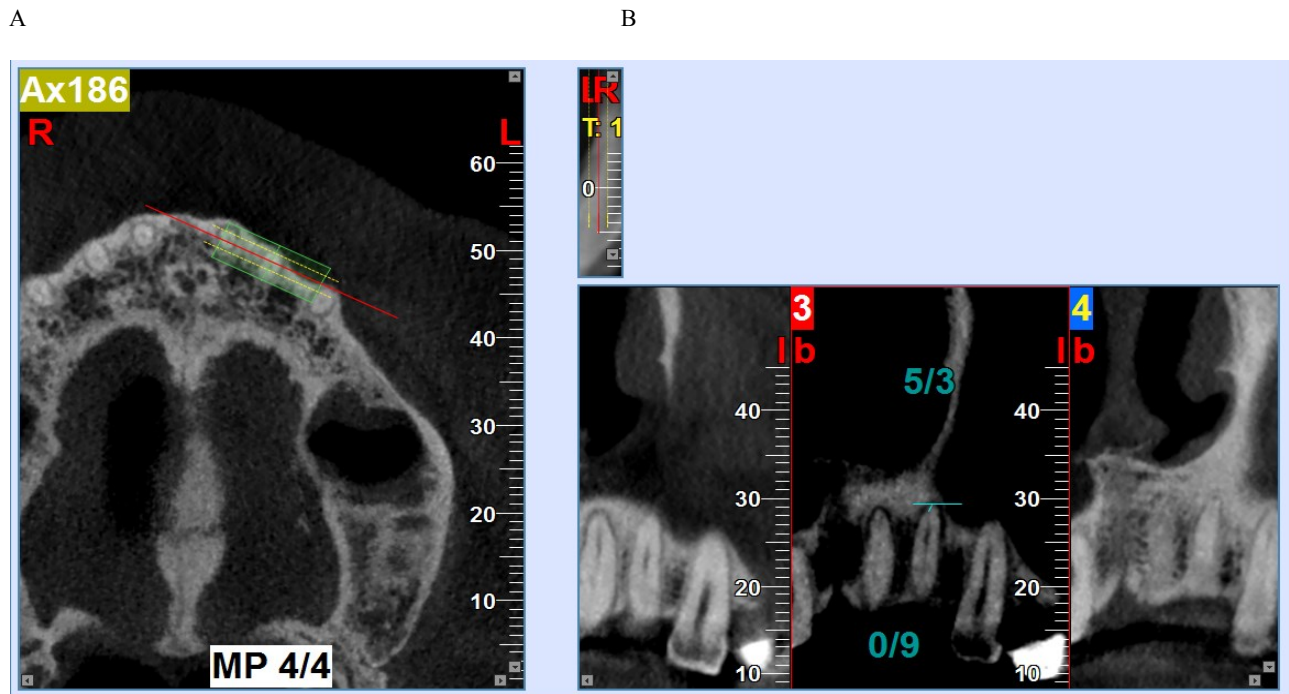


Figure 5. (A)The axial view of the left maxillary lateral and the lines of the incision perpendicular to the long axis of the tooth ;(B) The coronal view of the left maxillary lateral to measure the distance from apical foramen to the anatomical apex of the root using a ruler in NNT software

All images were evaluated by an endodontist and a radiologist. Besides, a third person investigated the final results. Reviewed items were as follows:

- 1- Apical foramen position compared to anatomical apex in maxillary anterior teeth in left and right quadrants;
- 2- Apical foramen distance from the anatomical apex in maxillary anterior teeth in left and right quadrants.

Data were analyzed by SPSS 22 using descriptive statistics (mean, frequency, and standard deviation). Besides, ANOVA, Chi-square, and Independent t-tests were used to determine the association among various variables. P-value<0.05 was statistically considered as significant level.

Results

The mean apical foramen distance to the anatomical apex in central incisor teeth was 0.53 ± 0.28 mm. The highest position of the apical foramen was central to the anatomical apex (34.1%). The mean apical foramen distance to the anatomical apex in lateral teeth was 0.56 ± 0.31 mm, and the highest position of apical foramen was central to the anatomical apex (22.6%). The mean apical foramen distance to anatomical apex in canine teeth was 0.74 ± 0.39 mm, and the highest position of apical foramen was distal buccal compared to the anatomical apex (20%) (Table1).

Table 1. Apical foramen distance and position compared to anatomical apex in anterior maxillary teeth

Tooth		N	Mean	Std.Deviation	P-value
Central incisor	Mesiopalatal	13	0.68	0.40	
	Mesiobuccal	28	0.60	0.30	
	Mesial	46	0.63	0.28	
	Distopalatal	23	0.60	0.36	
	Distobuccal	36	0.68	0.39	
	Distal	54	0.69	0.29	
	palatal	30	0.45	0.17	<0.001
	buccal	73	0.44	0.18	
	center	157	0.45	0.22	
	total	460	0.53	0.28	
Lateral incisor	Mesiopalatal	36	0.64	0.30	
	Mesiobuccal	77	0.59	0.27	
	Mesial	32	0.77	0.42	
	Distopalatal	36	0.71	0.35	
	Distobuccal	99	0.65	0.30	
	distal	12	0.51	0.27	
	palatal	33	0.33	0.12	<0.001
	buccal	100	0.38	0.15	
	center	442	0.56	0.31	
	total	36	0.64	0.30	
Canine	Mesiopalatal	22	0.85	0.55	
	Mesiobuccal	48	0.71	0.35	
	Mesial	59	0.77	0.37	
	Distopalatal	21	0.86	0.46	
	Distobuccal	74	0.78	0.38	
	distal	8	0.86	0.42	<0.001
	palatal	9	0.60	0.35	
	buccal	35	0.54	0.27	
	center	62	0.57	0.29	
	total	413	0.74	0.39	

The mean apical foramen distance to anatomical apex in anterior maxillary teeth in men and women was 0.64 ± 0.36 and 0.58 ± 0.32 mm, respectively (p -value=0.003), this difference was statistically significant according to the independent t-test. Again, according to the results of the t-test, the mean distance between apical foramen and anatomical apex in central incisor and canine teeth was not significant in men and women (P -value=0.06,0.25 respectively), but there was a significant difference concerning the mean interval between apical foramen and lateral apex in lateral incisor teeth of men and women (P -value=0.02) (Table2).

Table 2. Apical foramen distance to anatomical apex in maxillary anterior teeth based on gender

Tooth	Sex	N	Mean	Std.Deviation	P-Value
Central incisor	Male	200	0.56	0.29	0.06
	Female	260	0.51	0.27	
Lateral incisor	Male	201	0.60	0.33	0.02
	Female	241	0.53	0.28	
Canine	Male	186	0.76	0.42	0.25
	Female	227	0.72	0.36	
Total	Male	587	0.64	0.36	0.003
	Female	728	0.58	0.32	

Concerning the effect of quadrant direction on apical foramen to apex distance, the t-test showed no significant difference between distances from apical foramen to the anatomical apex in maxillary anterior teeth in the right and left quadrants (P-value=0.02) (Table3). Regarding the influence of age on apical foramen distance from the apex, the ANOVA test indicated no significant difference between distances from apical foramen to anatomical apex in maxillary anterior teeth at different ages (Table4).

Table 3. Apical foramen distance to anatomical apex in anterior maxillary teeth based on quadrants

Tooth	Side	N	Mean	Std.Deviation	P-Value
Central incisor	Right	228	0.55	0.30	0.12
	Left	232	0.51	0.26	
Lateral incisor	Right	227	0.56	0.30	0.63
	Left	215	0.57	0.31	
Canine	Right	216	0.75	0.41	0.37
	Left	197	0.72	0.37	
Total	Right	671	0.62	0.35	0.2
	Left	644	0.60	0.32	

Table 4. Apical foramen distance to anatomical apex in anterior maxillary teeth based on age

Tooth	Age	N	Mean	Std.Deviation	P-Value
Central incisor	30>	54	0.52	0.29	0.40
	30-50	269	0.52	0.27	
	50<	137	0.56	0.30	
	Total	460	0.53	0.28	
Lateral incisor	30>	54	0.53	0.30	0.62
	30-50	259	0.57	0.30	
	50<	129	0.58	0.32	
	Total	442	0.56	0.31	
Canine	30>	53	0.76	0.43	0.70
	30-50	250	0.72	0.38	
	50<	110	0.75	0.40	
	Total	413	0.74	0.39	
Total	30>	161	0.61	0.36	0.63
	30-50	778	0.60	0.33	
	50<	376	0.62	0.35	
	Total	1315	0.61	0.34	

Discussion

In the current study, the mean distances in central incisor, lateral incisor, and canine positions were 0.53, 0.56, and 0.74 mm, respectively. The highest position of apical foramen was central, followed by central and distal, respectively. In the study by Abdullah et al., who studied apical and lateral foramen in permanent anterior teeth by stereomicroscope staining, the mean distance between foramen and apex was 0.35, 0.28 and 0.58 mm in the central incisor, lateral incisor and canine teeth of maxilla, respectively,^[14] which are different from those of the present study. Teo et al. studied on maxillary incisor teeth and reported a mean foramen distance from the apex of 0.35 mm, ranging from 0.1 to 1.2,^[15] which are disagreement with the findings of the current study. This difference can be attributed to factors such as study population. In the study by Mizutani et al., on apex anatomy of roots in maxillary anterior teeth drawn by sectioning method, the apical distance from foramen to root apex was 450, 0.440 and 0.510 mm, in the central incisor, lateral incisor and canine teeth, respectively,^[16] which are inconsistent with the findings of

the ongoing study. This difference can be attributed to factors such as methodology and study population. Estrela et al. used the CBCT to investigate the position of maxillary anterior teeth and suggested that most of the teeth were in the central position^[11], which is dissimilar to that of the current study. This difference might occur due to factors such as the study population.

Jain et al. investigated maxillary anterior teeth in the Indian population using the dental operating microscope (DOM).^[3] In their study, the most frequent positions were centrals and laterals, which are consistent with the findings of the current study. Moreover, they reported that lateral position was the most frequent exit path^[3], which are in line with the results of the ongoing study.

In the present study, there was a significant difference concerning the mean distance between foramen and apex in anterior maxillary teeth in men and women. However, this difference was not significant for canine teeth. In the present study, for all teeth in both directions, the mean foramen apex distance was less than 1 mm. There was no significant difference between the two sides (right and left quadrants) concerning the foramen-apex distance in anterior teeth. We could not find any similar study on the effects of gender and quadrants on foramen-apex distance in maxillary anterior teeth.

Concerning the association between age and apical foramen distance from the apex, there was no significant difference between apical foramen and anatomical apex in anterior maxillary teeth in various age groups. In the study by Haghanifar et al. who studied the morphology of mandibular anterior teeth root canal using CBCT, there was no significant difference between apical foramen and anatomical apex in anterior mandibular teeth in various age groups which are similar to the findings of the ongoing study.^[17] In general, aging was associated with increased distance of foramen-apex, which clinically was not important. Over the past 30 years, different methods have been used to evaluate the structure of the root canal of teeth in humans^[8] including suctioning, clarification, tooth staining, conventional radiographs and micro-computed tomography (CT).^[6] The CBCT has been very useful for evaluating the morphology of root canals.^[18] Many of these methods have their shortcomings or provide a two-dimensional assessment of the root canal structure, which is not enough to effectively evaluate the canal.^[9]

Clarification and micro-CT evaluation which are commonly used in internal pattern anatomy are the gold standard for dental morphology analysis. Although clarification is a high-precision technique for investigating morphological variations of drawn teeth, its application is limited in clinical settings.^[19,6] Among 3-D CT imaging techniques, the CT is less clinically applicable than CBCT due to limitations such as exposure to high radiation, expensiveness, and more artifacts.^[20] The CBCT images produced by the CBCT technique are in sagittal, coronal, and axial planes and can reduce the overlap of adjacent tissues. In addition, patients are less exposed to radiation in this technique. Besides, unlike the clarification technique, it can be used in-vivo environment.^[21]

Furthermore, Sadri et al.^[22] Haghanifar et al.^[17] Harandi et al.^[23] and Estrela et al.^[11] used CBCT to investigate the position and distance of apical foramen compared to anatomical apex in different teeth. Therefore, this technique was applied in the present study to determine the location and distance from apical foramen to the anatomical apex in maxillary anterior teeth.

One of the limitations of this study was that due to the use of archival CBCT specimens, the periapical region and canal path were not clearly defined in all specimens. Higher resolution can provide more precise details of the apical area so that the tooth apex and apical foramen will be more accurately identified. It is recommended to use higher resolution CBCTs in studies.

Conclusion

According to the findings, in the endodontic treatment of anterior maxillary teeth, the operation length indicated by the radiographic apex should be reduced by 1 mm to increase the quality of the treatment.

Funding

This study was a research project (Grant no: 9707253), supported and funded by Babol University of Medical Sciences.

Conflicts of Interest

We declare no conflict of interest.

Authors' Contribution

The study was designed by Ali Soleymani and Farida Abesi. The study data were collected by Fereshteh Arsari. Analysis and interpretation of data were performed by Hemmat Gholinia. Study supervision was performed by Ali Soleymani.

References

1. de Brito IF, Sá Nogueira SJ, Maniglia-Ferreira C, Almeida FCL, de Sousa BC. Prevalence of major apical foramen mismatching the root apex in root canals of human permanent teeth. *RSBO* 2016;13:188.
2. Abarca J, Zaror C, Monardes H, Hermosilla V, Muñoz C, Cantin M. Morphology of the Physiological Apical Foramen in Maxillary and Mandibular First Molars. *Int J Morphol* 2014;32:671-7.
3. Jain P, Balasubramanian S, Sundaramurthy J, Natanasabapathy V. Position of apical foramina in permanent maxillary anterior teeth representative of an Indian population: An in vitro Study. *J Int Oral Health* 2017;9:279.
4. Versiani MA, Ahmed HM, Sousa-Neto MD, De-Deus G, Dummer PM. Unusual Deviation of the Main Foramen from the Root Apex. *Braz Dent J* 2016;27:589-91.
5. Kuttler Y. Microscopic investigation of root apexes. *J Am Dent Assoc* 1955;50:544-52.
6. Naseri M, Safi Y, Akbarzadeh Baghban A, Khayat A, Eftekhari L. Survey of Anatomy and Root Canal Morphology of Maxillary First Molars Regarding Age and Gender in an Iranian Population Using Cone-Beam Computed Tomography. *Iran Endod J* 2016;11:298-303.
7. Wu MK, Wesselink PR, Walton RE. Apical terminus location of root canal treatment procedures. *Oral Surg Oral Med Oral Pathol Oral Radiol Endod* 2000;89:99-103.
8. Allothmani OS, Chandler NP, Friedlander LT. The anatomy of the root apex: A review and clinical considerations in endodontics. *Saudi Endod J* 2013;3:1.
9. Ahmed HMA, Versiani MA, De-Deus G, Dummer PMH. A new system for classifying root and root canal morphology. *Int Endod J* 2017;50:761-70.
10. Blattner TC, George N, Lee CC, Kumar V, Yelton CD. Efficacy of cone-beam computed tomography as a modality to accurately identify the presence of second mesiobuccal canals in maxillary first and second molars: a pilot study. *J Endod* 2010;36:867-70.
11. Estrela C, Couto GS, Bueno MR, Bueno KG, Estrela LRA, Porto OCL, et al. Apical Foramen Position in Relation to Proximal Root Surfaces of Human Permanent Teeth Determined by Using a New Cone-beam Computed Tomographic Software. *J Endod* 2018;44:1741-8.
12. Kerkfeld V, Meyer U. Higher Resolution in Cone Beam Computed Tomography Is Accompanied by Improved Bone Detection in Peri-implant Bone Despite Metal Artifact Presence. *Int J Oral Maxillofac Implants* 2018;33:1331-8.
13. Tepedino M, Cornelis MA, Chimenti C, Cattaneo PM. Correlation between tooth size-arch length discrepancy and interradicular distances measured on CBCT and panoramic radiograph: an evaluation for miniscrew insertion. *Dental Press J Orthod* 2018;23:39.e1-e13.

14. Abdullah D, Kanagasigam S, Luke DA. Frequency, Size and Location of Apical and Lateral Foramina in Anterior Permanent Teeth. *Sains Malays* 2013;42:81-4.
15. Teo CS, Chan NC, Loh HS. The position of the apical foramen of the permanent incisors. *Aust Dent J* 1988;33:51-5.
16. Mizutani T, Ohno N, Nakamura H. Anatomical study of the root apex in the maxillary anterior teeth. *J Endod* 1992;18:344-7.
17. Haghanifar S, Moudi E, Bijani A, Ghanbarabadi MK. Morphologic assessment of mandibular anterior teeth root canal using CBCT. *Acta Med Acad.* 2017;46:85-93.
18. Caputo BV, NoroFilho GA, de Andrade Salgado DM, Moura-Netto C, Giovani EM, Costa C. Evaluation of the Root Canal Morphology of Molars by Using Cone-beam Computed Tomography in a Brazilian Population: Part I. *J Endod.* 2016;42:1604-7.
19. Omer OE, Al Shalabi RM, Jennings M, Glennon J, Claffey NM. A comparison between clearing and radiographic techniques in the study of the root-canal anatomy of maxillary first and second molars. *IntEndod J* 2004;37:291-6.
20. Moshfeghi M, Amintavakoli M, Ghaznavi D, Ghaznavi A. Effect of Slice Thickness on the Accuracy of Linear Measurements Made on Cone Beam Computed Tomography Images (InVitro). *J Dent SchShahidBeheshtiUniv Med Sci* 2019;34:100-8.
21. Khademi A, Mehdizadeh M, Sanei M, Sadeqnejad H, Khazaei S. Comparative evaluation of root canal morphology of mandibular premolars using clearing and cone beam computed tomography. *Dent Res J (Isfahan)* 2017;14:321-5.
22. Sadri A, Moudi E, Khafri S, Soleymani A. Evaluation of apical foramen distance in relation to the anatomical apex of mandibular molars by cone-beam computed tomography (CBCT) in a selected Iranian population. *Caspian J Dent Res* 2019; 8: 55-9.
23. Harandi A, Moudi E, Gholinia H, Akbarnezhad M. A cone-beam computed tomography study of apical and mental foramen's location in mandibular premolars. *Caspian J Dent Res* 2018;7:27-36.