Albanian Journal of Trauma and Emergency Surgery (2020) 4/2: 724 - 726
DOI: 10.32391/ajtes.v4i2.95

CASE REPORTS

Systemic Dego`s Disease. Our Approach to the Diagnosis and the Follow-Up. A Case reports

Fadil GRADICA[1*], Daniela XHEMALAJ[1]

Received: 5 February 2020 / *Accepted:* 15 March 2020 / *Published online:* 20 July 2020

Abstract

Degos' disease, also known as "malignant atrophic papulosis" is a rare vasculopathy characterized by typical cutaneous lesions with an unknown etiology which was first described by Dego in 1942 (1), but another case, reported in 1941 by Köhlmeier, who interpreted it as thromboangiitis obliterans of the mesenteric vessels (2).

It is an occlusive arteriopathy involving small-caliber vessels. Specifically, it is a progressive, small- and medium-size arterial occluding disease, leading to tissue infarction and initially involving the skin. Degos disease occurs both in a limited benign, cutaneous form and in a potentially lethal multiorgan, systemic variant.

The disease has a male predominance (3:1), and sporadic cases of familial involvement have been recorded. (3-7). The involvement of the gastrointestinal tract and other organs has been noted in approximately 60% of reported cases (8).

There are fewer than 50 living patients presently known worldwide, and fewer than 200 reported in medical literature. However, many individuals may go undiagnosed due to rarity of the disease (9,10).

Most individuals develop symptoms between the ages of 20-50; however, cases outside of this age range have been reported as well, even as early as 8 months (1,6).

Key words: Degos' disease, malignant atrophic papulosis, pleural effusion.

Case report

A 58 -year-old man was presented to the hospital with productive cough, dyspnea, chest wall pain, and in chest x-ray examination was observed left pleural effusion. Five months ago, the patient was diagnosed with Degos disease which was manifested by more than 50 remittent eruptions of small papules with white centers surrounded by erythematous telangiectatic borders, 5-8 mm in diameter, nonpruritic and painless, which were wide-spread but located principally on trunk antero-posterior position ,that started one year ago without the complete disappearance of older ones (Figure 1, 2) The soles, mucosae and face were not affected. The patient was also taking medication for hypertension.

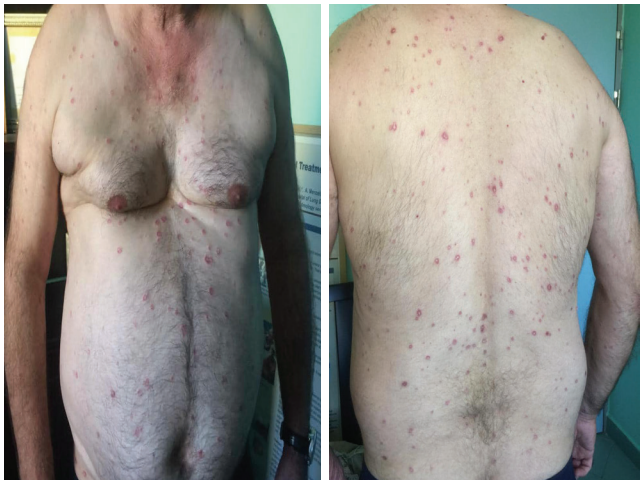

Figure 1: Skin photograph showing white to pink papules, 5–10mm in diameter, with central, porcelain-white atrophic center surrounded by a peripheral telangiectatic rim

Original article, no submission or publication in advance or in parallel

* ***Corresponding author:***
Asc. Prof. Dr. Fadil GRADICA MD, PhD
✉ *fadilgradica68@hotmail.com*

1 *University Hospital "Shefqet Ndroqi" Tirana, ALBANIA.*

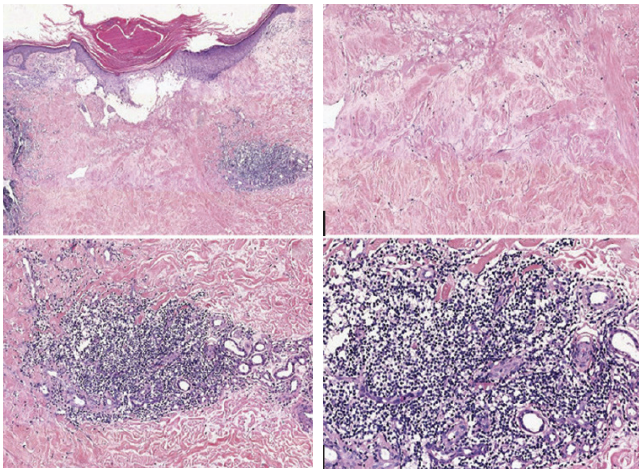

Figure 2 Histopathology of the skin biopsy by hematoxylin and eosin staining: Epidermal atrophy, hyperkeratosis, and wedge-shaped dermo epidermal necrosis were visible the panels demonstrated occlusion of blood vessels in the corium and perivascular lymphocytic infiltration.

During the hospitalization were performed a series of examination to find the cause of pleural fluid. A therapeutic thoracentesis was performed and 1L of green exudative fluid was removed with pH 7.26, WBC 260 cells/mm3 (PMN 16%), LDH 746 IU/L, triglycerides 30 mg/dL, and total protein 5.2 g/dL, cholesterol 60mg/dl, neutrophils 3%, lymphocytes 27 %, macrophages 70 %. G-expert was negative for TB infection.

Other analyses results were: erythrocytes sedimentation 7, fibrinogen 442, PT 13.5, PT/INR1, APTT 28.5, CRP 2.9.

Hepatic panel was normal, mineral panel normal, LDH 230, BNP 54, total protein 7.9, RPR nonactive, urine analysis wit microscopy was normal.

In the condition of the persistence of pleural fluid even with the wide specter of antibiotic therapy was decided, in the multidisciplinary team for diagnostic and therapeutic VATS (Video Assisted Thoracoscopy).

With lidocaine 2%- 40 ml diluted, in 4-5-th space, linea axillaries anterior and media, we opened pleural cavity, aspirated the pleural fluid and taken some pieces from parietal pleura for histopathological examination.

The patients were in good condition after VATS with medication. Pleural biopsy resulted with fibrosis and chronic inflammation perivascular lymphocytic mononuclearis, no granulomatous process, wich reveals a systemic Dego disease.

Three months later the patient came again to the hospital with pleural fluid and a drainage and medication was done.

Discussion

Degos' disease, also known as malignant atrophic papulosis (MAP), is a rare condition with reportedly stereotypical skin lesions on the trunk and proximal portion of the extremities, but the palms, soles and face tend to be spared, as in our case, consisting of largely asymptomatic, porcelain-white, atrophic papules, with surrounding erythema and telangiectasias.

The disease has been reported to be purely cutaneous in 37% of patients (11).

Degos disease occurs both in a limited benign, cutaneous form and in a potentially lethal multiorgan, systemic variant (12,13).

The disease is characterized by endothelial proliferation and swelling of small and medium-sized vessels.

The etiology of the disease remains controversial. Some believe that Degos' disease is a thrombotic rather than an autoimmune disease, because no circulating immune complexes, anti-endothelial cell antibodies, or anticardiolipin antibodies are isolated, even there a a few cases, where antiphospholipid antibodies are identified.

The internal organs most commonly involved in the order of decreasing frequency are the GI tract, CNS, thoracic organs and kidney.

The involvement of the gastrointestinal tract and other organs has been noted in approximately 60% of reported cases (3).

The lesions affect the bowel in approximately 47% of cases. Intestinal symptoms are variable, although any portion of the intestinal system (from the oral cavity to the anus) may be involved, and the small bowel is predominantly affected (9).

The course of the disease may be as long as 20 years but once intestinal lesions, especially perforation have appeared, death usually occurs within a few months (6).

Neurologic manifestations occur in around 19 % of patients, including cerebral hemorrhage, subdural hematoma, thrombosis of cerebral arteries, venous sinus thrombosis, encephalitis, meningitis, polyradiculoneuropathy, cranial neuropathy, and myopathy (14,15).

There have been very few published reports of cardiopulmonary and pleural complications related to DD.

There are very few reported cases of pleuritis and pericarditis, most diagnosed as incidental findings at autopsy. Another case by Notash et al. mentioned that severe restrictive cardiopulmonary insufficiency led to death of a patient with Degos disease. Another case with cardiopulmonary involvement was reported in 1996. An infant case of Degos disease in which the patient died due to disseminated myocardial infarct was presented by Cabre et al. Also, two cases of constrictive pericarditis have been described.

The other case, described by Pierce and Smith, died due to heart failure and respiratory disorder three months

after a left lung decortication. Histology of the heart of both cases indicated myocardial impairment. Pierce and Smith suggested that the myocardial impairment was present with no evidence of associated lesions. Pleuritis and pericarditis were reported as symptoms of Degos Disease by Voigt et al.

Our patient had no gastrointestinal, or neurological findings and based on literature review, we recommend medical treatment for MAP, whether cutaneous or systemic, remains to be defined. Antiplatelet drugs (Aspirin, Dipyridamole) may have a role in the treatment of all variants of MAP, according to dramatic improvement in their general condition and disease symptoms shortly after treatment in some cases, suggesting that increased platelet aggregation may play a role in the pathogenesis of MAP [9]. Our patient was treat-ed medically with Aspirin and Dipyridamole, improving his general condition mildly, confirming previous recommendations.

A publication from Japan in January 2013 showed the expression of stromal cell-derived factor (SDF)-1/CXCL12 in Degos disease. Secretory activity by stromal and endothelial cells of the bone marrow activates SDF-1/CXCL12 of megakaryocyte precursors and is responsible for the co-stimulation of platelet activation. Patients with Degos disease demonstrated a high level of secretion of SDF-1/CXCL12 inflammatory cells. This cell type was located in the perivascular, intravascular, and perineural tissue. These results support the theory that Degos disease is an endothelial disease (16,17).

In conclusion, the features of our case highlight the importance of considering systemic Degos disease in case of pleural effusion especially when there is skin involvement.

Skin biopsy is essential for the diagnosis of this entity. Platelet antiaggregant as well as anticoagulants seemed effective to the control of the disease.

COI Statement: This paper has not been submitted in parallel. It has not been presented fully or partially at a meeting or podium or congress. It has not been published nor submitted for consideration beforehand.

All authors declare that there is no conflict of interest. **This research received no specific grant from any funding agency in the public, commercial, or nonprofit sectors.** There are no relevant or minor financial relationships from authors, their relatives or next of kin with external companies.

Disclosure: The authors declared no conflict of interest. No funding was received for this study.

References

1. Degos R, Delort J, Tricot R. [Dermatite papular atrophicans]. Dermatite papulo-squameuse atrophiante. Bull Soc Fr Dermatol Syphiligr. 1942; 49: 148–281.
2. Köhlmeier W. [Multiple skin necrosis in thromboangiitis obliterans]. Multiple Hautnekrosen bei Thromboangiitis obliterans. Arch Dermatol Syphilol. 1941; 181: 792–793.
3. Degos R. Malignant atrophic papulosis. Br J Dermatol. 1979; 100: 21–35.
4. González JA, Noguer S, Cabré J. Papulosis atrofiante maligna de Degos (observacion de um caso afectando a um lactante). [Degos' malignant atrophic papulosis (observation of a case in an infant)] Actas Drmosifiliogr. 1975;66(5–6):317–319.
5. Habbema L, Kisch LS, Starink TM. Familial malignant atrophic papulosis (Degos' disease) – additional evidence for heredity and a benign course. Br J Dermatol. 1986; 114: 134–135.
6. Kisch LS, Bruynzeel DP. Six cases of malignant atrophic papulosis (Degos' disease) occurring in one family. Br J Dermatol. 1984; 111: 469–471.
7. Newton JA, Black MM. Familial malignant atrophic papulosis. Clin Exp Dermatol. 1984; 9: 298–299.
8. Vicktor C, Schultz-Ehrenburg U. Papulosis maligna atrophicans (Köhlmeier–Degos): Diagnose, Therapie, Verlauf. [Malignant atrophic papulosis (Köhlmeier-Degos): diagnosis, therapy and course] Hautarzt. 2001; 52: 734–737.
9. Schwaiger T, van den Brandt C, Fitzner B, et al. Autoimmune pancreatitis in MRL/Mp mice is a T-cell-mediated disease responsive to cyclosporine A and rapamycin treatment. Gut. 2014;63(3):494–505.
10. Moulin G. Les formes benignes de la papulose atrophiante maligna de Degos. [Benign forms of Degos' malignant atrophic papulosis] Ann Dermatol Venereol. 1988; 115: 1289–1290.
11. Burg G, Vieluf D, Stolz W, et al. Malignant atrophic papulosis. Hautarzt. 1989; 40: 480–485.
12. Magrinat G, Kerwin KS, Gabriel DA. The clinical manifestations of Degos' syndrome. Arch Pathol Lab Med. 1989; 113: 354–362.
13. Winkelmann RK, Howard FM, Perry HO, et al. Malignant papulosis of skin and cerebrum. Arch Dermatol. 1963; 87: 54–62.
14. Subbiah P, Wijdicks E, Muenter M. *et al* Skin lesion with a fatal neurologic outcome (Degos' disease). Neurology 199646636–640
15. Rosemberg S, Lopes MB, Sotto MN, Graudenz MS. Childhood Degos' disease with prominent neurological symptoms: report of a clinicopathological case. J Child Neurol. 1988; 3: 42–46
16. Scheinfeld N. Commentary on 'Degos disease: a C5b-9/interferon-α-mediated endotheliopathy syndrome' by Magro et al: a reconsideration of Degos disease as hematologic or endothelial genetic disease. Dermatol Online J. 2011;17(8):6.
17. Meephansan J, Komine S, Hosoda S, et al. Possible involvement of SDF-1/CXCL 12 in the pathogenesis of Degos disease. J Am Acad Dermatol. 2013;68(1):138–143.