

## ***Don't Lose Your Heart to a Car. Extracorporeal Ejection of the Heart by Forceful Upward Thoracoabdominal Blunt Trauma in Human and Animal***

Doll D MD, PhD,<sup>1\*</sup>, Vänni V.<sup>1,2,3</sup>, Handolin L<sup>1,3</sup>, Fortounis K<sup>4,5</sup>, Fyntanidou B<sup>6</sup>, Monzon B<sup>7</sup>

Received: 23 April 2020 / Accepted: 20 May 2020 / Published online: 20 July 2020

© The Author(s) 2020. This article is published with open access at <https://journal.astes.org.al>

### ***Abstract***

The traumatic extracorporeal ejection of a beating heart has not been witnessed and reported in the literature previously, to our knowledge. Here we present two cases of vehicle accidents leading to this fatal injury, both in a rabbit and a human.

One late evening in June, in the land of the midnight sun, a young man was driving to his favourite fishing river for a spot of trout fishing in a remote part of Eastern Finland. While driving his aged Nissan Almera at 60 km/h down a dusty gravel road on this dusky night, suddenly a young male rabbit jumped onto the road and appeared in the beam of his headlights. Despite the man's evasive manoeuvres, the rabbit was struck by the left front corner of the car. After hitting the brakes and the car eventually coming to a standstill, the young man went to inspect the animal he had hit....

In conclusion, we present that in a very rare constellation of forceful blunt trauma to the chest, the heart can be completely avulsed and ejected from the body in human as in animals. Larger prospective and randomised studies are probably not needed to confirm these findings. Just be careful – it is possible to lose your heart to a car.

**Key word:** extracorporeal ejection, avulsion, heart, blunt thoracoabdominal trauma, rupture, aorta, IVC/SVC, rabbit, human.

### ***Introduction***

The traumatic extracorporeal ejection of a beating heart has not been witnessed and reported in the literature previously, to our knowledge. Here we present two cases of vehicle accidents leading to this fatal injury, both in a rabbit and a human.

### ***Case report 1***

One late evening in June, in the land of the midnight sun, a young man was driving to his favourite fishing river for a spot of trout fishing in a remote part of Eastern Finland. While driving his aged Nissan Almera at 60 km/h down a dusty gravel road on this dusky night, suddenly a young male rabbit jumped onto the road and appeared in the beam of his headlights. Despite the man's evasive manoeuvres, the rabbit was struck by the left front corner of the car. After hitting the brakes and the car eventually coming to a standstill, the young man went to inspect the animal he had hit. About 20 m from the car, the male rabbit, which was not mangled or flattened by the car was lying motionless on its right side. There was an open wound at the base of the rabbit's neck at the level of the jugular groove (thoraco-cervical junction anteriorly). This gaping 2 x 6 cm transverse wound, resembling an irregular low collar incision, was surrounded by blood wetted fur. Apart from the wound, the rabbit seemed unharmed, but dead. A trail of blood drops on the road lead away from the rabbit corpse and ended a meter and a half away at a red spherical 5 x 5 cm structure that was still moving... in fact fibrillating. After a few seconds, the spherical structure stopped moving. Once prodded by the man's finger, it started fibrillating again, but this quickly

Original article, no submission or publication in advance or in parallel

#### **\* Corresponding author:**

Prof. Dr. Dietrich Doll

✉ [ddoll@gmx.de](mailto:ddoll@gmx.de)

- 1 Department of Surgery, Chris Hani Baragwanath Academic Hospital, University of Witwatersrand Medical School, Johannesburg, Republic of SOUTH AFRICA
- 2 Dept. Surgery, North Karelia Central Hospital, Tikkamäentie 16, 80210 Joensuu, FINLAND
- 3 Dept. Trauma, Helsinki University Hospital, Helsinki, FINLAND
- 4 Dept. Surgery, Papageorgiou Hospital, Thessaloniki, GREECE
- 5 EMS, Thessaloniki, GREECE
- 6 Dept. Anaesthesiology, AHEPA University Hospital, Thessaloniki, GREECE
- 7 Trauma Unit, Dept. Surgery, Charlotte Maxeke Johannesburg Academic Hospital, Johannesburg SOUTH AFRICA

got weaker and faded away into stillness within the next minutes. A closer look revealed this was the rabbit's heart, which had been torn out of its chest and ruptured from its junction to the aortic root and the inferior and superior vena cava (ICV/SVC). The right atrium was ruptured at its opening with a 3–4 mm tear.

The young man being a passionate hunter, opened the demised rabbit's abdomen and removed the normal looking unbruised intraabdominal contents and skilfully removed the diaphragm to inspect the chest cavity. While the lungs and major vessels were in their rightful places, the aortic arch seemed to be present, but dislocated. The anatomic location of the heart was empty and the heart was missing.

Multiple fractures in the front and back of the chest meant the forequarters had to be discarded, but the hind legs were still edible.

### Case report 2

In October 2014, an EMS ambulance was dispatched at 07:00 in the morning because of a traffic accident on the highway ring road of Thessaloniki, Greece. A male pedestrian in his mid-sixties had been hit by the right front side of a car traveling at more than 160 km/h (Figure 1). The driver of the vehicle was uninjured, but the victim was found 150 m from the car. There were no signs of life. The victim suffered a traumatic amputation of his right foot from the level of the ankle. There was an 8 x 12 cm open wound at the jugulo-sternal base of the neck (zone 1) with no active bleeding, but longitudinal structures were found hanging out of the wound (Figure 2). More than 20 m from the victim, a bloody spherical structure which was not moving was found. On closer inspection, the paramedics realised that this structure was the victim's heart (Figure 3). They retrieved the foot and heart and brought them along with the victim to the local hospital.

The patient was declared dead on arrival in the Emergency Room. An autopsy revealed multiple fractures to the chest and C-spine, a largely torn - now empty - pericardial sac with an apical opening and a missing heart. Ruptured stumps of aorta, vena cava and pulmonary vessels were also observed.

### Discussion

The ejection of a beating heart due to sudden massive blunt force trauma sounds impossible. However, these two cases prove otherwise. We are not able to fully explain the exact mechanism by which this ejection happens, but have a logical proposal for the series of events that enable it. We suggest, that only a fully filled heart with closed valves, preventing the heart losing its ventricular filling and being compressed to a smaller volume, could be ejected. At the same time, it would seem plausible that both lungs need to be filled with air and the glottis closed, permitting no air escape during very rapid and forceful compression of the chest. Both these

elements, a fully filled heart and uncompressible lungs, will result in a tremendous peak increase in the intrathoracic pressure. This pressure peak would then be high enough to be able to push the heart out of the chest.

In theory, the most likely direction for the heart to dislocate in such circumstances would be downwards, since the diaphragm is known to rupture from blunt force trauma and the thoracic inlet is much smaller in size compared to the inferior thoracic aperture (the thoracic outlet). However, in these two cases the heart was pushed upwards through the thoracic inlet. Thus, we speculate that the thoracic outlet must have been "blocked", due to a simultaneous rapid compression of the abdomen, resulting in a peak increase of the intra-abdominal "counter pressure" preventing the heart moving downwards. Thus, the only direction for pressure relief was the upper chest opening at the base of the anterior neck.

In rabbits, the thoracic inlet is relatively larger due to the lack of collar bones and this, in theory, would make them potentially more vulnerable to heart ejection. Also, dorsal extension of the head may even enlarge the aperture. Despite a relatively narrow upper thoraco-cervical anterior opening in humans, this injury can also be seen in humans, as described in the second case presented.

Ruptures of valvular structures of the heart with forceful blunt trauma have been described in human for both the tricuspid [1, 3] and the bicuspid valve [4] as well as for the aortic valve [5]. Avulsions of the aortic root [6,7] as well as detachments of IVC and SVC [6, 7] and rupture of a right ventricle due to blunt force trauma have been previously reported.[8] Brathwaite found three patients with biventricular rupture in the series of 32 blunt cardiac trauma patients.[9] Fulda published a trauma registry study, showing an overall mortality of 75% in cardiac rupture cases. In this study, patients with cardiac ruptures arriving at the emergency department with vital signs, still carried a 52% mortality.[10] Partial rupture or avulsion of the IVC/SVC area is possible, though only described in a single case report. [11] Rupture of the auricle of the right atrium with consequent pericardial tamponade can occur through massive abdominal trauma, as described by Degiannis and Doll. [12,13] Pericardial rupture with luxation of the heart, although rare, is possible following blunt force chest trauma [14,16] as well as falls from buildings exceeding 15 m in heights.[17]

Intrathoracic displacement of the heart has been proven by MRI by Fonseca- Pinto 2017 in a dog overrun by a car. [18]

Complete cardiac avulsion with jugular groove skin rupture and extracorporeal heart ejection has not been published so far. This extremely rare injury most likely results from the precisely timed interplay of a complex trauma mechanism paired with particular physiological conditions that enable the forceful ejection of the heart cranially out of the thoracic inlet. The autopsy report from the second case, demonstrates that major mechanical forces

had to be applied to lead to this major structural disruption. In the end, one human and one rabbit heart were ejected from their bodies and lost on the street. In the case of the rabbit, the injury was so immediately observed that the heart was found still beating despite laying on the road.

In conclusion, we present that in a very rare constellation of forceful blunt trauma to the chest, the heart can be completely avulsed and ejected from the body in human as in animals. Larger prospective and randomised studies are probably not needed to confirm these findings. Just be careful – it is possible to lose your heart to a car.

**COI Statement:** This paper has not been submitted in parallel. It has not been presented fully or partially at a meeting or podium or congress. It has not been published nor submitted for consideration beforehand.


All authors declare that there is no conflict of interest. **This research received no specific grant from any funding agency in the public, commercial, or nonprofit sectors.** There are no relevant or minor financial relationships from authors, their relatives or next of kin with external companies.

**Disclosure:** The authors declared no conflict of interest. No funding was received for this study.

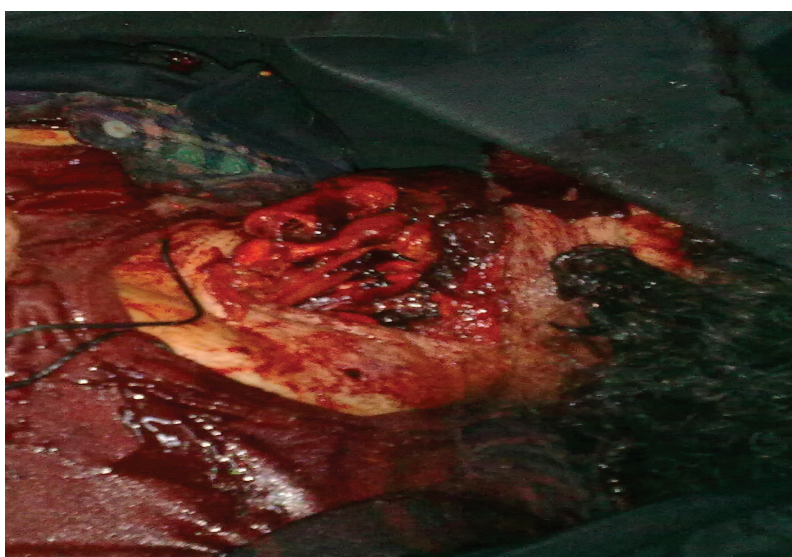**Acknowledgements:** We thank Dr. Tomi Simons, MD, for revising the language of the manuscript.

## References

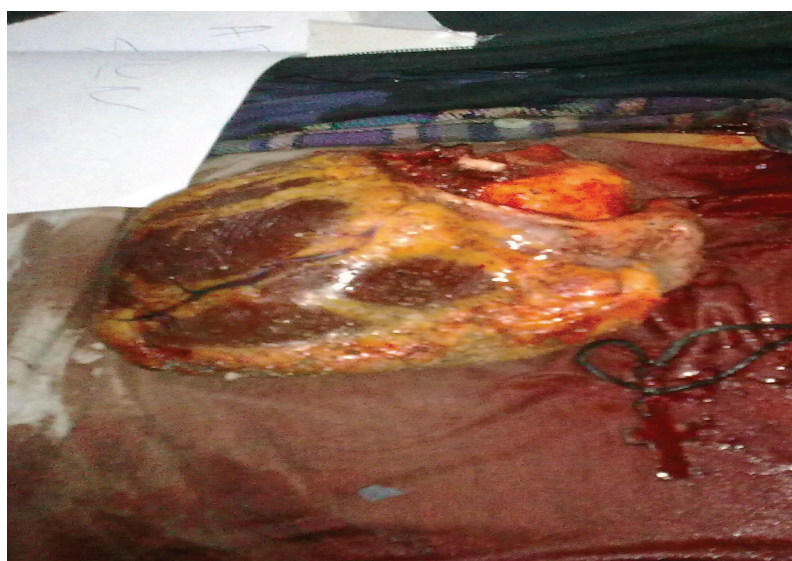1. Mehrotra D, Dalley P, Mahon B. Tricuspid valve avulsion after blunt chest trauma. *Tex Heart Inst J* 2012;39:668-70.
2. Stahl RD, Liu JC, Walsh JF. Blunt cardiac trauma: atrioventricular valve disruption and ventricular septal defect. *Ann Thorac Surg* 1997;64:1466-8.
3. Trotter TH, Knott-Craig CJ, Ward KE. Blunt injury rupture of tricuspid valve and right coronary artery. *Ann Thorac Surg* 1998;66:1814-6.
4. Singh H, Ali S, Luni FK, Hashmi F, Taleb M. Isolated rupture of bicuspid aortic valve following blunt chest trauma: a case report and systematic review of literature. *Cardiovasc Diagn Ther* 2017;7:89-91.
5. Esmaeilzadeh M, Alimi H, Maleki M, Hosseini S. Aortic valve injury following blunt chest trauma. *Res Cardiovasc Med* 2014;3:e17319.
6. Devineni R, McKenzie FN. Avulsion of a normal aortic valve cusp due to blunt chest injury. *J Trauma* 1984;24:910-2.
7. Yang S, Wang C, Chen H. Partial aortic annulus avulsion and formation of aortic-left ventricle tunnel through interventricular septum after blunt cardiac trauma. *Eur J Cardiothorac Surg* 2011;40:255-6.
8. Gorman R, Nuttall SM. Traumatic right ventricular rupture following a horse kick. *BMJ Case Rep*. Nov 2012 ed: BMJ Publishing Group Ltd.; 2012:1-2.
9. Brathwaite CE, Rodriguez A, Turney SZ, Dunham CM, Cowley R. Blunt traumatic cardiac rupture. A 5-year experience. *Ann Surg* 1990;212:701-4.
10. Fulda G, Brathwaite CE, Rodriguez A, Turney SZ, Dunham CM, Cowley RA. Blunt traumatic rupture of the heart and pericardium: a ten-year experience (1979-1989). *J Trauma* 1991;31:167-72; discussion 72-3.
11. Chaumoitre K, Zappa M, Portier F, Paniel M. Rupture of the right atrium-superior vena cava junction from blunt thoracic trauma: helical CT diagnosis. *AJR Am J Roentgenol* 1997;169:1753.
12. Degiannis E, Brink J, Haagensen M, Williams P, Boffard K. Rupture of the auricle of the right atrium of the heart and pericardium after blunt trauma. *Eur J Surg* 2001;167:472-4.
13. Doll D, Glapa M, Bonanno F, Smith MD, Dusel W, Degiannis E. [Traumatic rupture of the cardiac auricle after forceful blunt abdominal trauma]. *Unfallchirurg* 2007;110:637-9.
14. Aghayev E, Jackowski C, Thali MJ, Yen K, Dirnhofer R, Sonnenschein M. Heart luxation and myocardium rupture in postmortem multislice computed tomography and magnetic resonance imaging. *Am J Forensic Med Pathol* 2008;29:86-8.
15. Aho AJ, Vanttinen EA, Nelimarkka OI. Rupture of the pericardium with luxation of the heart after blunt trauma. *J Trauma* 1987;27:560-3.
16. Assing M, Dragicevic N, Hazelton TR, Nallamshetty L. Delayed levorotation of the heart in traumatic pericardial rupture. *Emerg Radiol* 2011;18:257-61.
17. Turk EE, Tsokos M. Blunt cardiac trauma caused by fatal falls from height: an autopsy-based assessment of the injury pattern. *J Trauma* 2004;57:301-4.
18. De Campos Fonseca Pinto A, Massad M, Ribas L, et al. Complete cardiac and bronchial avulsion in a dog: Post-mortem computed tomography and forensic necropsy analysis. *Journal of Forensic Radiology and Imaging* 2017;8:45-7.



*Figure 1: Car damage showing the ferocity of impact.*



*Figure 2: 12 cm open wound at the jugulo-sternal base of the neck (zone 1) with no active bleeding.*



*Figure 3: More than 20 m from the victim apart, a motionless bloody spherical structure which was found – the patient's heart.*