

Application of the Monti procedure in Adult Continent Cutaneous Urinary Diversion

Gëzim GALIQI ^{*1,2}, Luan BAJRI ¹, Albert PESHA ², Artan KONI ², Bledar SHEGA ¹

Received: 7 May 2020 / Accepted: 9 June 2020 / Published online: 20 July 2020

© The Author(s) 2020. This article is published with open access at <https://journal.astes.org.al>

Abstract

Introduction: Monti and co. described in 1997 is a continent catheterizable conduit using short segments of the ileum (1). The use of this technique allows us to obtain 2 to 2.5 cm segment of the ileum to achieve a tabularized segment of 7-8 cm. The 15 cm of terminal ileum was not routinely used for this type of procedure. After the reconstruction of a tunnel, anastomosis was performed on the superior part of the postero-lateral junction of the bladder.

Objectives: To report 6 cases using the Monti procedure with ileum for adult continent cutaneous urinary diversion, from different etiologies.

Materials and Methods: From 2007 to 2020 we treated 6 patients with different conditions with this procedure. First case was a middle-aged woman with a big vesico-vaginal fistula (fig.3) It was unappropriated to be closed with satisfactory functional results in terms of continence, because a part of the sphincter was destroyed also. The reason of damage was auto mutilation as a result of borderline personality.

Discussion: Monti procedure associating Mitrofanoff principle was mainly used in pediatric patients (1,2,3) That's because of the relatively easy execution of the "Mitrofanoff principle" and the high degree of continence obtained with its use (4). But can we use the same principle to resolve some difficult cases in adult urology also?

Conclusion: The Monti tunnel is a valid option for continent intermittent catheterisation. It's also an alternative to be adjunct with Mitrofanoff procedure when needed. We used it when the appendix was not appropriate to be used as a tunnel or when it was missing. It has a good continent percentage and it can be done rather easily. Of course, ours is a small series of cases to represent more important conclusions.

Keywords: Monti procedure, Catheterization; Ileum; Urinary Bladder; Urinary Diversion

Introduction

Monti and co. described in 1997 is a continent catheterizable conduit using short segments of the ileum(1). The use of this technique allows us to obtain 2 to 2.5 cm segment of the ileum to achieve a tabularized segment of 7-8 cm. The 15 cm of terminal ileum was not routinely used for this type of procedure. After the reconstruction of a tunnel, anastomosis

was performed on the superior part of the postero-lateral junction of the bladder. The caliber of such a tube allows catheterization with a 16F to 18F catheter.). The stoma was made at a level which was located proximally relative to the bladder in order for gravity to help with the patient's continence. The mucosal folds of the ileum were aligned with its longitudinal axis and in this way facilitating the catheterization.

The Monti technique is convenient when the appendix is too short or is surgically absent. When creating simultaneous catheterizable channels for the bladder and for the Malone antegrade continence enema (M-ACE) procedure, the appendix is used for the M-ACE and a Monti tube can be used for the catheterizable bladder channel.

We can use Monti even in such cases as when simultaneous augmentation of ileal enterocystoplasty is being performed, where Monti tube is harvested from the bowel adjacent to that which will be used in the augment, allowing for a single small bowel anastomosis.

Original article, no submission or publication in advance or in parallel

* **Corresponding author:**
Gëzim GALIQI MD, PhD.
✉ gezimgaliqi@yahoo.com

¹ Regional Hospital of Shkodër, ALBANIA.

² American Hospital of Tirana, ALBANIA.

Surgical Technique

As first described, a 2-cm segment of ileum is isolated, detubularized and then retubularized transversely along the antimesenteric border to create a smaller caliber but longer intestinal tube (Fig 1). When increased channel length is needed, 4 cm of ileum can be removed and two side-by-side Yang-Monti channels can be anastomosed. This is commonly called a double Monti (fig 2).

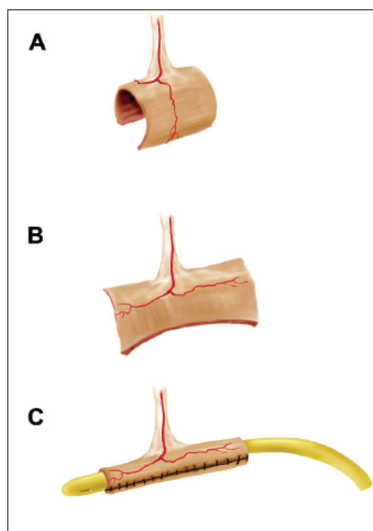


Fig. 1 Classical Monti procedure

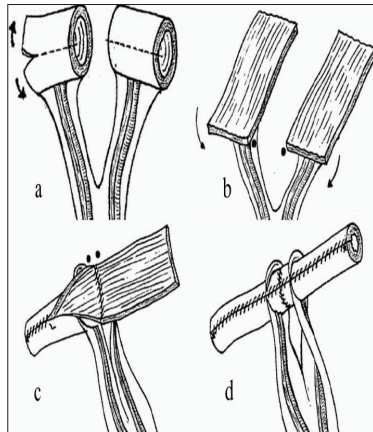


Fig. 2 Double Monti procedure

The diversion catheter was removed 3 weeks post-operatively. All patients were put on a clean intermittent catheterization (CIC) regimen using a 14 or 16 Fr nelaton catheter every 3 hours. In our limited number of cases we were never obliged to use the double Monti procedure.

Objectives

To report 6 cases using the Monti procedure with ileum for adult continent cutaneous urinary diversion, from different etiologies.

To represent Monti diversion as a valid alternative for continent urinary diversion when urethra has been removed

or is not valid, or as in the case of myelomeningoceles when we use augmentation, showing that the appendix is not the only valuable option for diversion and we can use Monti also.

To evaluate complications related with this type of diversion like stomal stenosis and difficulty to catheterize the bladder, or incontinence related with derivation.

Materials and Methods

From 2007 to 2020 we treated 6 patients with different conditions with this procedure. First case was a middle-aged woman with a big vesico-vaginal fistula (fig.3). It was unappropriated to be closed with satisfactory functional results in terms of continence, because a part of the sphincter was destroyed also. The reason of damage was auto mutilation as a result of borderline personality. With good counselling and medication by the psychiatric, the patient was treated and she was motivated to undergo the surgery to close the bladder neck and to divert with continent procedure urine. The appendix was removed a long time ago so we decided to do a Monti procedure. The bladder was suitable also.

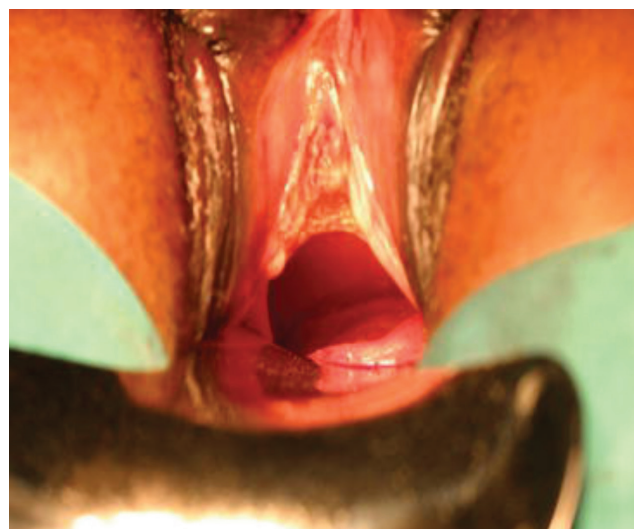


Fig.3. Vesico –vaginal fistula with destruction of bladder-neck.

The second case was a posterior urethral stricture due to pelvic fracture in a 60-year-old patient unwilling to redo a urethroplasty after the failed first attempt to do a successful anastomosis of urethra with the apex of prostate (Fig. 4). The stricture developed again and the patient was suffering for a long period of time. He was proposed the cutaneous continent diversion and he chose this procedure as the most guaranteed one, compared to a second attempt to achieve a successful anastomosis of urethra.

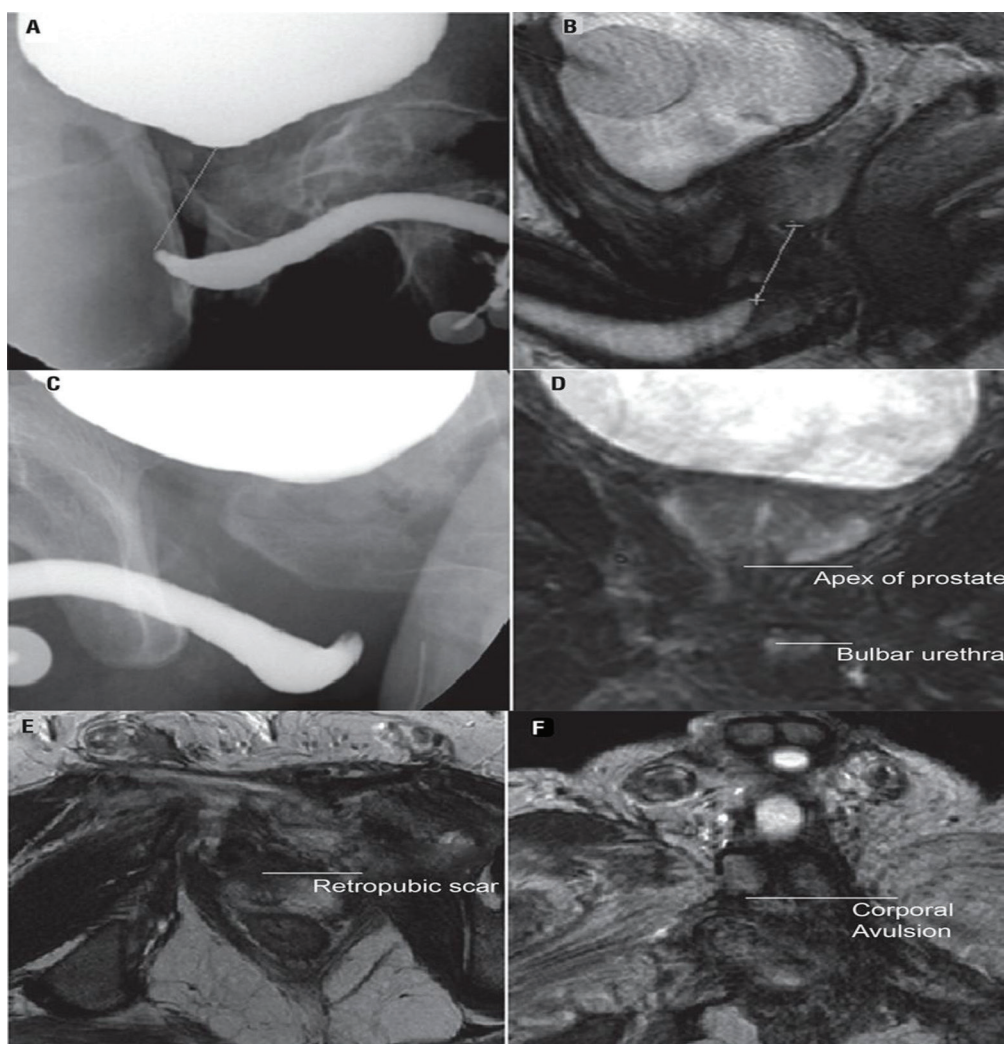


Fig. 3. Image data about our anastomosis of urethra with the apex of prostate.

Two cases of primary urethral distal tumour in women (Fig. 5,6) where excision of whole urethra was performed with bladder neck closure and subsequent Monti procedure. The patients were later referred for multimodal therapies, radio and chemotherapies.

The fifth case was a 20 year old boy with Spina

bifida where an augmentation bladder procedure (2) was performed with a urinary continent Monti diversion. The patient was suffering from an afunctional left kidney and was keeping a suprapubic urinary tube to drain urine. This came from the fact that we were not doing anymore intermittent catheterisation because of urethral stricture and difficulties

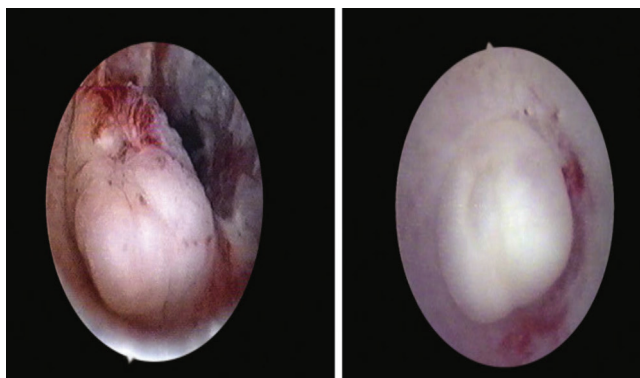


Fig 5: Cystoscopy reveals at the entrance of urethra a tumor

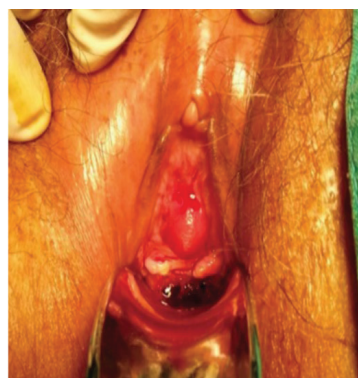

Fig 6: A tumor protrude at the entrance of urethra

to do intermittent self catheterisation. We performed a bladder augmentation (fig.7,8) which was needed years ago and a Monti diversion.

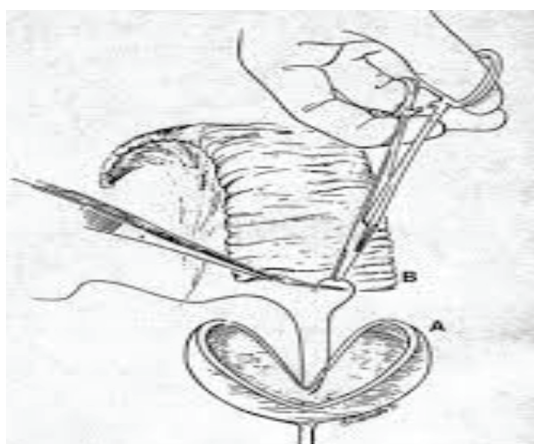
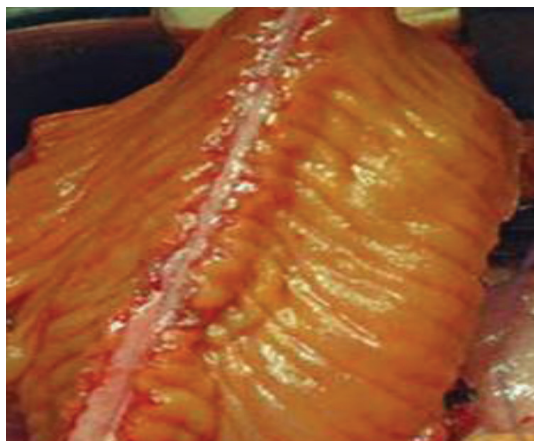


Fig. 7,8. Ileal detubulisation for bladder augmentation

The sixth patient was a male patient of 48 years old, with a spinal cord injury, doing for years intermittent selfcatheterisation. Because of urethral stricture he had an internal urethrotomy two years ago. A urethroplasty was proposed to him, but he refused it. So we proposed a continent diversion and he accepted.

The patients were regularly followed-up at 3,6,18 and 24 months postoperatively, with special attention to any problems with catheterization and incontinence. The follow-up plan consisted of physical examination including stoma evaluation; upper urinary tract sonography and determining of post catheterization urine residue; and serum creatinine level and catheter size assessment.

We monitored the patients for several years, to see how capable they were to do the catheterisation and also to evaluate the continence.

Also we took note if any patient was having any complication with the stoma or difficulties to catheterise the Monti channel.

Results

The patients were monitored for a long follow up depending on time when the Monti procedure was performed. The follow up for some of them went even up to 10 years.

In terms of continence all had satisfactory results. When they were asked, the satisfactory rate was around 85%. Only one patient with bladder augmentation and Monti diversion was having incontinence from Monti stoma with 3 pads per day, while with time he ameliorated to 1 pad per day trying to stick closely to intervals of catheterisations.

After several years, two patients had difficulty in catheterizing the bladder due to stomal stenosis. We used dilatation on both of them which helped to pass the difficulty in catheterisation.

The woman with Monti procedure and bladder closure as a result of vesico-vaginal fistula was later operated twice for bladder stone. But we managed to treat them with endoscopic lithotripsy through Monti tunnel. She was treated for bladder stones with alkalinizing agent and she did routine urine test to check for infection and was treated if there was any.

No patient was obliged to revise the Monti chimney as a need for a second procedure.

Discussion

Monti procedure associating Mitrofanoff principle was mainly used in pediatric patients (1,2,3) That's because of the relatively easy execution of the "Mitrofanoff principle" and the high degree of continence obtained with its use (4). But can we use the same principle to resolve some difficult cases in adult urology also?

The answer is yes. There are a lot of authors who expressed their experience using Mitrofanoff principle with Monti procedures diversion for the same reason that this procedure is used in pediatric patients.

We have used in our series of 6 patients the Monti procedure in cases where we removed the urethra for distal stage 1, or 2 cancer as part of multimodal treatment. Primary urethral carcinomas are very aggressive diseases but in our two cases we managed to treat them in early stages and to perform bladder conservative surgery which allowed us to propose a continent cutaneous drainage to both women. Urethral strictures especially after pelvic fracture are a big challenge to have successful results after surgery. So after failed attempts from the first surgery to realigned urethra in the patient over 60 years old, we proposed the surgery of closing the bladder neck and execute a continent diversion.

Based on literature. Monti's procedure seems to be a valuable technique in patients with very long complicated urethral defects who cannot be treated with routine urethroplastic techniques.

The patient on which we accomplished the bladder augmentation and Monti procedure was 20 years old and he needed this procedure to be done long before, to conserve

the kidney function. Time was of essence because the left kidney was having a poor function. It is in these cases with mielomeningoceles where the Mitrofanoff works perfectly and needs to be done on time (2).

The last patient was having a big urethral stricture due to false passage after intermittent catheterization. He was not willing to undergo a urethroplasty so we proposed the Monti deviations.

In terms of functional results we can say that 85% of patients were continent except one who was having leakage of urine from stoma while he was supine. In two other patients the stoma stenosis was treated with dilatation. No patient needed revision of the chimney of Monti. Even in the case of revision of continent catheterizable channels for channel obstruction, surgery can be performed with acceptable rates of durable patency and incontinence (7). The bladder stone could be treated through the chimney with the endoscope.

Conclusion

The Monti tunnel is a valid option for continent intermittent catheterisation. It's also an alternative to be adjunct with Mitrofanoff procedure when needed. We used it when the appendix was not appropriate to be used as a tunnel or when it was missing. It has a good continent percentage and it can be done rather easily. Of course ours is a small series of cases to represent more important conclusions.

COI Statement: This paper has not been submitted in parallel. It has not been presented fully or partially at a meeting or podium or congress. It has not been published nor submitted for consideration beforehand.

All authors declare that there is no conflict of interest.

This research received no specific grant from any funding agency in the public, commercial, or nonprofit sectors. There are no relevant or minor financial relationships from authors, their relatives or next of kin with external companies.

Disclosure: The authors declared no conflict of interest. No funding was received for this study.

References

1. Monti P.R. New techniques for construction of efferent conduits based on the Mitrofanoff principle. *Urology*. 1997; 49: 112-115
2. Mitrofanoff P. Cystostomie continente trans-appendiculaire dans le traitement des vessies neurologiques. *ChirPediatri*. 1980; 21: 297-305
3. Duckett J. Use of the Mitrofanoff principle in urinary reconstruction. *Urol Clin North Am*. 1986; 13: 271-274
4. Sumfest J.M. The Mitrofanoff principle in urinary reconstruction. *J Urol*. 1993; 150: 1875-1878
5. Hadley D1, Anderson K1, Knopick CR2, Shah K2, Flynn BJ3. Creation of a continent urinary channel in adults with neurogenic bladder: long-term results with the Monti and Casale (Spiral Monti) procedures. *Urology*. 2014 May; 83(5):1176-80.
6. Hosseini J1, Kaviani A, Mazloomfard MM, Golshan AR. Monti's procedure as an alternative technique in complex urethral distraction defect. *Int Braz J Urol*. 2010 May-Jun; 36(3):317-26.
7. Travis J, Pagliara Ronak A. University of Minnesota Outcomes of revision surgery for difficult to catheterize continent channels in a multi-institutional cohort of adults. : <https://doi.org/10.5489/cuaj.4656>