

ORIGINAL RESEARCHES

DOI: 10.5281/zenodo.4016800
UDC: 618.145-007.415-091.8



Immunoexpression of matrix metalloproteinases MMP-1, MMP-2, MMP-9 and MMP-14 in extragenital endometriosis and eutopic endometrium

¹Eugeniu Cazacu, ¹Eremai Zota, ²Claudiu Margaritescu, ¹Radu Niguleanu, ¹Ruslan Pretula

¹Department of Morphopathology, Nicolae Testemitanu State University of Medicine and Pharmacy
Chisinau, the Republic of Moldova

²Department of Pathology, University of Medicine and Pharmacy, Craiova, Romania

Authors' ORCID iDs, academic degrees and contributions are available at the end of the article

*Corresponding author: eugeniu.cazacu@usmf.md

Manuscript received August 5, 2020; revised manuscript August 28, 2020; published online September 15, 2020

Abstract

Background: Matrix metalloproteinases are proteolytic enzymes responsible for the disorder of extracellular matrix modeling in endometriosis and their involvement in the invasion process. The aim of this study was to evaluate the immunohistochemical expression of matrix-metalloproteinases MMP-1, MMP-2, MMP-9 and MMP-14 in surgical excision specimens, collected from women with extragenital endometriosis compared to their expression in the normal endometrium.

Material and methods: The study included 40 female patients diagnosed with extragenital endometriosis. The used methods consisted in processing the specimens by classical histological technique with paraffin inclusion and enzymatic immunohistochemical technique for the detection of metalloproteinases MMP-1, MMP-2, MMP-9 and MMP-14.

Results: The expression of matrix metalloproteinases MMP-2, MMP-14 was significant in glandular cells from endometriotic lesions, while MMP-9 was evident in both stromal and glandular cells in these lesions. The expression MMP-1 was not present. Normal endometrial tissue showed high reactivity for MMP-14 and low reactivity for MMP-2 and MMP-9.

Conclusions: This study reveals some aspects related to the morphological and clinical features of extragenital endometriosis with different locations and the correlation between the clinical evolution and some immunohistochemical markers with potential prognosis regarding the aggressiveness of such lesions.

Key words: endometriosis, matrix metalloproteinases, invasiveness potential.

Cite this article

Cazacu E, Zota E, Margaritescu C, Niguleanu R, Pretula R. Immunoexpression of matrix metalloproteinases MMP-1, MMP-2, MMP-9 and MMP-14 in extragenital endometriosis and eutopic endometrium. *Mold Med J.* 2020;63(4):6-11. doi: 10.5281/zenodo.4016800.

Introduction

Endometriosis is a common, benign, inflammatory pathology, represented by the ectopic location of functional endometrial glands and stroma outside the uterine cavity [1, 2].

Most sites of implantation involve the ovaries and Fallopian tubes, as well as the zones between the uterus and the anterior and posterior cul-de-sacs, the uterine ligaments and the pelvic wall. In other patients, the endometriotic implants spread beyond the inner genital organs and involve other organs in the peritoneal cavity, such as the intestines, the bladder or the lower parts of the ureters. Implants of ectopic endometrium have also been found in extragenital sites, such as surgical scars, the lungs or even the brain [3, 4].

The prevalence rate of symptomatic endometriosis is estimated to be 10% with an incidence of about 2-7/1000 women per year and a further 11% of undiagnosed cases, although there are only a few studies with well-estimated prevalence and incidence of endometriosis in the gen-

eral population and some suggesting that many, if not all, women have endometriosis as a transient phenomenon [5]. Endometriosis is associated with a range of symptoms, including chronic pelvic pain, dysmenorrhea and infertility, all of which can have a strong adverse effect on the physical and mental health of the patient. While endometriosis is assumed to be a benign disease from histological standpoint, it bears a certain resemblance to malignant tumors due to the characteristic of infiltration. While the development of endometriosis has been shown to be a complex process involving interaction between genetic and environmental factors, the etiology and pathology of endometriosis remain poorly understood [6].

Numerous theories were proposed to explain etiology of endometriosis.

Matrix metalloproteinase (MMP) represents a large family zinc-dependent endopeptidases, involved in the degradation of the extracellular matrix in the process of en-

ometrial cell implantation and are classified by their substrate specificity [7, 8]. Several subtypes of MMPs are distinguished, depending on their substrate-specificity and localization: collagenases, gelatinases, stromelysins, matrilysins and membrane-type metalloproteinases. MMPs play a crucial role in numerous physiological processes, for instance: bone remodeling, angiogenesis, inflammation, ovulation and embryogenesis. What is more, MMPs are involved in cyclic changes of endometrium structure and thickness in the steroid hormones concentration levels. MMPs are expressed in both epithelial and stromal cells.

Numerous MMPs are additionally involved in many pathological processes, such as: fibrosis, weakening of matrix (e.g., in aortic aneurysm or dilated cardiomyopathy) or tissue destruction (e.g., cancer invasiveness, also endometrial carcinoma invasiveness, and ability to metastasize) [9].

Matrix metalloproteinases (MMPs) are essential in orchestrating proper physiological functioning of the endometrium; hence, alteration of MMP activities is considered as a critical factor for the development of endometriosis. MMPs are involved in the cellular event of epithelial-mesenchymal transition [10, 11].

Objective of the research was to determine the activity of MMP-1, MMP-2, MMP-9 and MMP-14 in endometriotic lesions of women with endometriosis and compare with normal endometrium.

Material and methods

The study group included 40 female patients diagnosed with extragenital endometriosis from 2010–2017, diagnosed and surgically treated at the Department of Surgery, Obstetrics and Gynecology of *Gherghe Paladi* Municipal Clinical Hospital, *Sfantul Arhanghel Mihail* Municipal Clinical Hospital (Chisinau, the Republic of Moldova) and Emergency County Hospital (Craiova, Romania). Endometrial samples of normal proliferative endometrium from women who underwent hysterectomy for benign conditions were also included for comparison. The investigation was performed by using the archival paraffin-embedded tissue blocks corresponding to these cases, preserved at the Morphopathology Departments of hospitals. Hematoxylin and eosin slides were reviewed by 3 pathologists to confirm

the diagnosis. Pertinent clinical and demographic information was recorded for all study cases.

The research protocols were approved by the Ethics Committee of *Nicolae Testemitanu* State University of Medicine and Pharmacy, based on the patients informed written consent for the usage of the biologic material for research.

For immunohistochemistry, we used the paraffin blocks archived in the Laboratory of Pathology of the same Hospital. From these, 4 µm thick seriate sections were cut, which were further dewaxed, clarified and hydrated. Then, endogenous peroxidase was blocked with hydrogen peroxide (0.3%) for 15 minutes, at room temperature, and as antigen retrieval, we used microwaving for 20 minutes in 0.1 M citrate buffer of pH 6 (with the exception of fibronectin for which we used enzymatic retrieval with proteinase K, for 15 minutes, at 37°C). To avoid the nonspecific binding, the slides were covered with 2% bovine serum albumin (BSA) for one hour, at room temperature. Subsequently, the slides were incubated overnight, at 4°C, with the primary antibodies whose characteristics are presented in Table 1. Then, we used an amplification based on labeled Strep-tavidin–Biotin 2 (LSAB2) enzyme detection system and the correspondent Dako kit (Redox, Romania – K0675).

As chromogen, we used the 3,3'- Diaminobenzidine (DAB, Dako, K3468) and the Mayer's Hematoxylin kit (Tunic, Bio-Optica, Romania – M06002) for counter-staining. As negative internal controls, we used the same slides and procedures, but omitting the primary antibody.

The interpretation of the immunohistochemical reactions aimed first of all at highlighting the chromogen at the level of the antigenic targets and then at quantifying both the intensity of this signal and the proportion of the immunoreactive cells. The intensity of the reactions was graded using a scale with 4 degrees: 0 – for the absence of reactivity; 1 – for a light intensity; 2 – for moderate intensity and 3 – for high intensity (intense reaction). The reactivity of the inflammatory infiltrate (neutrophils, macrophages) was used as internal control to evaluate the intensity of these markers, this being considered the maximum reactivity.

A personalized score has been used to evaluate MMP-1, MMP-2, MMP-9 and MMP-14 expression: the percentage

Table 1

Antibodies used in immunohistochemical study

Antibody	Type	Clone	Producer	Catalog number	Dilution	Antigen retrieval	External positive control
MMP-1	Mouse monoclonal	6A5	Acris	AM06648SU-N	1:200	0.1 M Citrate, pH 6	Granulation tissue
MMP-2	Mouse monoclonal	OT14A11	OriGene	TA806846	1:100	1mM EDTA in 10mM Tris buffer (pH8.5)	Granulation tissue
MMP-9	Mouse monoclonal	5G3	OriGene	AM06662SU-N	1:200	0.1 M Citrate, pH 6	Granulation tissue
MMP-14	Mouse monoclonal	113-5B7	OriGene	AF8410	1:100	0.1 M Citrate, pH6	Granulation tissue

of tumoral positive cells (P) and the intensity of staining (I), obtaining a P×I final score.

The proportion of positive cells was also estimated on a 4-degree scale: 0 – no positive cells in any microscopic field; 1 – <10% of positive cells; 2– between 10-50% of positive cells and 3 – > 50% of positive cells (the examination being done at the x10 objective, respectively on 10 fields). The final score (SIHC) was obtained by multiplying the 2 scores, respectively the qualitative one (intensity) and the semiquantitative one (the proportion of reactive cells) and was graded as follows: negative (-) for 0; weakly positive (+) for 1; moderately positive (++) for 2; and intensely positive (+++) for scores 3. In positive immunochemistry, the maximum score was 9 and minimum – 1. In our score system, we established a threshold value of 4, considering a value >4 as a high score, and a value ≤4 as a low score.

Results

The patients’ group consisted of 42 women with endometriosis, age range of 21-63 years (median 40). Location included: the anterior abdominal wall after caesarean operation – 20, inguinal hernia – 7, umbilical hernia – 4, perineal region – 1, appendix – 4, colon – 5, and ileum – 1case. The classical histopatological examination of the general expression of MMP-1, MMP-2, MMP-9 and MMP-14 revealed a diverse variability. For MMP-2, MMP-9, MMP-14 markers, the reaction positivity was variable not only from one

case to another but also within each case, the latter being characterized by the identification of different areas within endometriosis. Consequently, the complex staining patterns were homogenous and heterogenous, as a reflection of the endometriotic cells equal and variable reaction capacity in different neighboring territories. We should also note that the glandular cell deposit in the center expressed the investigated molecules compared to a weak expression in the peripheral focus of endometriosis.

Our data resulting from the immunohistochemical evaluation of MMP-1, MMP-2, MMP-9, MMP-14 respectively, based on the quantification of immunopositive tumoral cells count and staining intensity, and expressed as individual scores, are summarized in tab. 2.

The expression of matrix metalloproteinases MMP-2, MMP-14 was significant in glandular cells from endometriotic lesions, while MMP-9 was evident in both stromal and glandular cells in these lesions. The expression MMP-1 was absent in wall cases of endometriosis and in normal tissue. Normal endometrial tissue showed high reactivity for MMP-14 and MMP-9 and low reactivity for MMP-2.

The reactivity of MMP-2, MMP-9 and MMP-14 metalloproteinase in endometriotic lesions was higher than in eutopic endometrium. MMP-2 and MMP-9 IHC staining was performed, and endometriosis-associated fibrosis and lymphocytic infiltrate were evaluated with MMP-1. Nuclear staining of MMP-2 for glands and both membranous and

Table 2

Characteristics of MMP-1, MMP-2, MMP-9 and MMP-14 immunoexpression of endometriotic tissue and eutopic endometrium

Location	MMP-1					MMP-2					MMP-9					MMP-14				
	% of positive cells	P score	Staining intensity	I score	Final score	% of positive cells	P score	Staining intensity	I score	Final score	% of positive cells	P score	Staining intensity	I score	Final score	% of positive cells	P score	Staining intensity	I score	Final score
Anterior abdominal wall after caesarean operation	0%	0	0	0	0	10%	1	+	1	1	80%	3	+++	2	6	90%	3	+++	3	9
Inguinal hernia	0%	0	0	0	0	15%	2	+	1	2	60%	2	+++	2	4	75%	3	+++	3	9
Umbilical hernia	0%	0	0	0	0	10%	1	+	1	1	55%	2	+++	2	4	60%	3	+++	3	9
Perineal region	0%	0	0	0	0	0	0	-	0	0	20%	2	++	1	2	15%	2	+++	3	6
Gastrointestinal tract	0%	0	0	0	0	20%	2	+	2	4	90%	3	+++	3	9	95%	3	+++	3	9
Endometrium (proliferative phase)	0%	0	0	0	0	10%	1	+	2	2	80%	3	+++	3	9	90%	3	+++	3	9

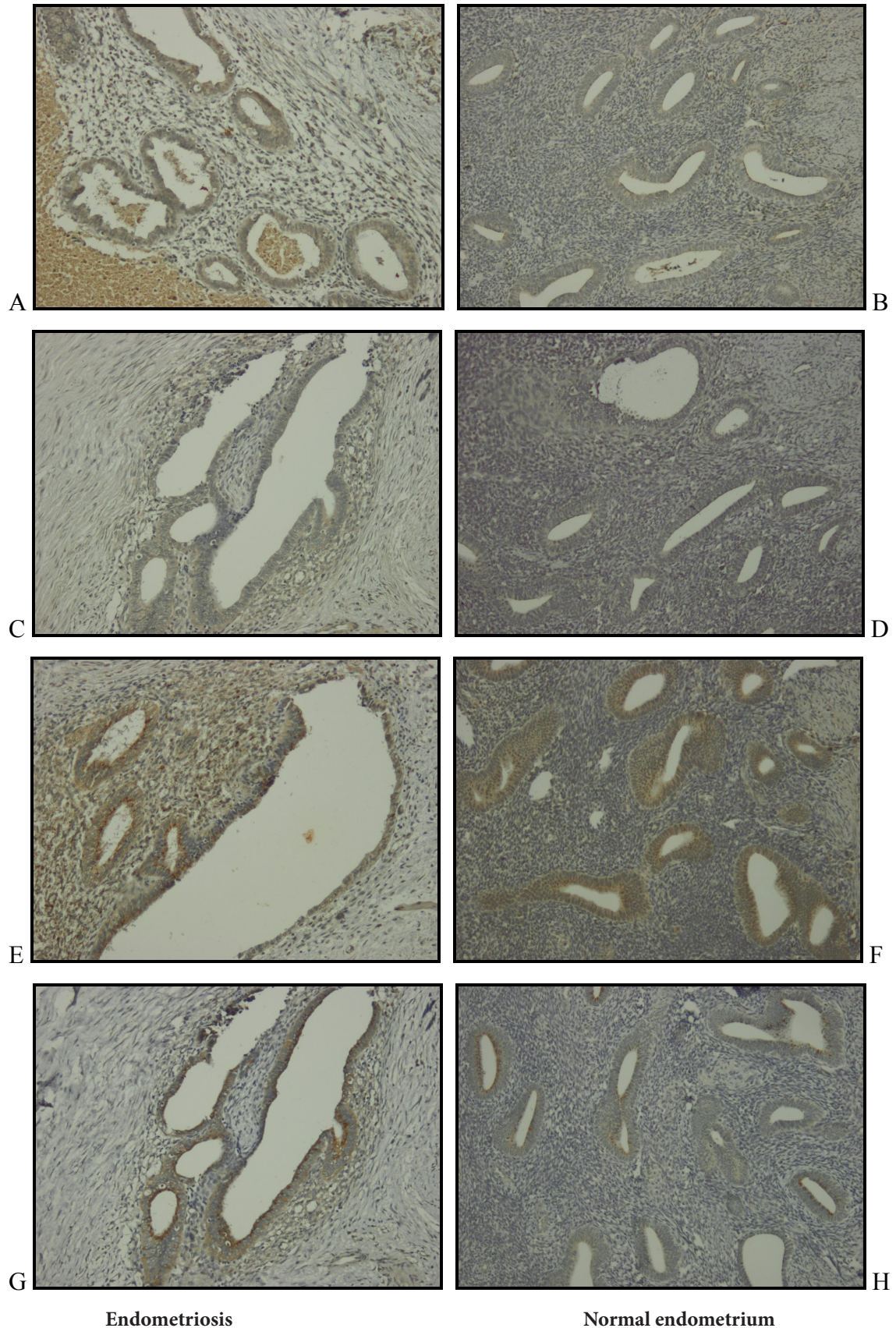


Fig. 1. Immunohistochemical reaction interpretation.

Negative reaction for MMP-1 in (A, B), moderate positive reaction for MMP-2 in (C, D), strong positive reaction for MMP-9 in (E,F) and MMP-14 in (G, H). IHC, objective $10 \times / 0.30$.

cytoplasmic staining of MMP-9 for stroma were considered positive. In cases with intestinal endometriosis staining was diffuse and intensity was strong (3+), in abdominal wall endometriosis intensity was moderate (2+) while eutopic endometrium staining was diffuse and intensity was weak to moderate (1-2+) in all cases. MMP-14 was positive and intensity was moderate in both cases. The expression of MMP-1 on the examined tissues, was absent in endometriosis and in cases of eutopic tissue.

Immunohistochemical analysis has demonstrated the significant enhance of MMP-9 and MMP-14 expressions in endometriosis and in endometrium. The distinctive feature of MMP-9 and MMP-14 expression in endometriosis was considerable increase of its activity precisely on the border of endometriotic lesion and the peritoneum. Elevation of MMP-9 and MMP-14 activity was also observed in the stroma of the ectopic endometrium bordering on the underlying stroma (fig. 1, E, F, G, H). Enhanced activity of MMP-9 in the stroma of the ectopic endometrium bordering on the underlying stroma was accompanied by the formation of macrophage-lymphocyte infiltrates, (fig. 1, E), that evidenced the implication of immune cellular components into the inflammation zone. Thereby, the obtained research findings allow to suggest, that elevation of MMP-9 activity in the sites of endometriotic lesion on the border with the underlying stroma promotes the invasiveness of ectopic endometrium by remodeling of the underlying stroma and infiltration of endometrial cells into the peritoneum. Increased activity of MMP-2 was observed in stroma of the ectopic endometrium bordering on the underlying stroma as well (fig. 1, C). The intensified MMP-9 expression in normal endometrium was found to prevail in outer membranes of endometrial cells (fig. 1, F) while the expression of MMP-14 was found in intern. Thus, the obtained findings are indicative of the increased MMP-9 and MMP-14 activity in the sites of endometriotic lesion.

Discussion

Endometriosis is one of the most common diseases affecting women of reproductive age. So far, the pathogenesis of this disease remains poorly understood. Endometriosis is considered a benign disease that nonetheless has the property of tissue invasion [6].

Metalloproteinases, enzymes that are important for extracellular matrix turnover, have recently been implicated in invasion and development of endometriosis. MMPs appear to be overexpressed in endometriotic lesions and contribute to establishment of endometrial glands and stroma at ectopic sites [12, 13].

MMP-1 (interstitial or fibroblast collagenase or collagenase-1) is the major collagenase able to degrade native fibrillar collagens type III, I, and II, at a specific site three fourths from the N-terminus. MMP-1 is produced by various types of cells: fibroblasts, keratinocytes, endothelial cells, macrophages, hepatocytes, chondrocytes and osteoblasts [14].

MMP-2 (gelatinase-A, 72-kDa type IV collagenase) cleaves collagen type IV, the major BM constituent, as well as degraded collagen and some noncollagenous ECM glycoproteins. MMP-2 also degrades native type I collagen. TNF- α and β stimulate MMP-2 production and early conceptus (blastocytes) and IFN- τ repress MMP-2 production. MMP-2 is expressed by various cell types, including fibroblasts, keratinocytes, osteoblasts, and monocytes [15].

MMP-9 (gelatinase-B, 92-kDa gelatinase) cleaves N-terminal telopeptide of type I collagen in an acidic environment, playing a role in the remodeling of collagenous ECM. MMP-9 is produced by normal alveolar macrophages, polymorphonuclear leukocytes, osteoclasts, keratinocytes, and invading trophoblasts [16].

MMP-14 is a trans-membrane type-1 protease capable of degrading different extracellular matrix components, such as collagen type I, II, and III as well as fibronectin and laminin. The main interest in this enzyme is due to its ability to activate different proteases, particularly MMP-2, MMP-9 and MMP-13 at the cell membrane. MMP-14 plays an important role in angiogenesis and is expressed by dermal fibroblasts, and osteoclasts [21].

The presence and role of MMPs in endometriosis is unquestionable, however the exact sequence of events is unclear. It remains obscure, whether changes in their activity occur primarily in uterine cavity, that due to cellular memory allows endometrium fragments implantation into peritoneum, or whether specific conditions in peritoneal cavity (inflammation or other immunological processes) change MMPs activity in endometrial cells discarded from uterus during retrograde menstruation. Moreover, some balance switches in matrix remodeling in eutopic endometrium can be periodic or temporal and vanish just after lesion constitution on ectopic site. What is more, changes of MMPs, demonstrated in uterine endometrium at women with endometriosis may also occur after implantation of ectopic lesions, under the influence of processes taking place in peritoneum. Solution of this riddle seems to be hard to find, as it would require prospective study based on endometriotic biopsies in asymptomatic population of women and long-term observation for endometriosis onset [9, 17].

In the literature, there is no agreement on differences in the expression of MMP-2 among endometriotic tissues and eutopic endometrium at women affected or unaffected by endometriosis. However, endometriotic tissues seem to express more MMP-2 than eutopic endometrium [18-21].

Conclusions

The MMP-9 and MMP-14 activity significant elevation is established on ectopic endometrium of women with endometriosis. Study of MMP-1, MMP-2, MMP-9 and MMP-14 activities in endometriotic lesions at women with endometriosis is perspective for further investigation in order to determine a possible role of matrix metalloproteinases in the development of invasiveness process in case of extra-genital endometriosis.

References

- Cazacu E, Zota E, Mărgărețescu C. Procesul de tranziție epitelio-mezenchimală în endometrioză extragenitală [Epithelial-mesenchymal transition process in extragenital endometriosis]. Sănătate Publică, Economie și Management în Medicină [Public Health Econ Manag Med] (Chisinau). 2019;(2/80):66-70. Romanian.
- Brătilă E, Ionescu OM, Badiu DC, Berceanu C, Vlădescu S, Pop DM, Mehedințu C. Umbilical hernia masking primary umbilical endometriosis—case report endometriosis. Rom J Morphol Embryol. 2016;57(2 Suppl):825-829.
- Istrate-Oțiferu AM, Pirici D, Niculescu M, Berceanu C, Berceanu S, Voicu NL, Piringă GD, Roșu GC, Iovan L, Căpitănescu RG, Dițescu D, Sava A, Mogoantă L, Neacșu A. Clinical, morphological and immunohistochemical survey in different types of endometriosis. Rom J Morphol Embryol. 2018;59(4):1133-1153.
- Schorge JO, Schaefer JJ, et al. Endometriosis. In: Schorge JO, et al., editors. Williams gynecology. New York: McGraw Hill Medical; 2008. p. 225-43.
- Lagana AS, Garzon S, Götte M, Vigano P, Franchi M, Ghezzi F and Martin Dan C. The pathogenesis of endometriosis: Molecular and cell biology insights. Int J Mol Sci. 2019;20(22):5615. doi: 10.3390/ijms20225615.
- Lingli Xin, Qingxiang Hou, Qi Xiong and Xiaoping Ding. Association between matrix metalloproteinase-2 and matrix metalloproteinase-9 polymorphisms and endometriosis: a systematic review and meta-analysis. Biomed Rep. 2015;3(4):559-565. doi: 10.3892/br.2015.447.
- Avădanei R, Căruntu ID, Amălinei C, Lozneau L, Balan R, Grigoraș A, Apostol DC, Giușca SE. High variability in MMP2/TIMP2 and MMP9/TIMP1 expression in secondary liver tumors. Rom J Morphol Embryol. 2013;54(3):479-485.
- Madjid TH, Ardiansyah DF, Permadi W, Hernowo B. Expression of matrix metalloproteinase-9 and tissue inhibitor of metalloproteinase-1 in endometriosis menstrual blood. Diagnostics (Basel). 2020;10(6):364. doi: 10.3390/diagnostics10060364.
- Balkowiec M, Radoslaw BM, Wlodarski PK. The bimodal role of matrix metalloproteinases and their inhibitors in etiology and pathogenesis of endometriosis (Review). Mol Med Rep. 2018;18(3):3123-3136. doi: 10.3892/mmr.2018.9303.
- Sayantan J, Kasturi Ch, Amlan KR, Pramathes D, Snehasikta S. Regulation of matrix metalloproteinase-2 activity by COCS-2-PGE2-pAKT Axis promotes angiogenesis in endometriosis. PLoS One. 2016;11(10):e0163540. doi: 10.1371/journal.pone.0163540.
- Rivneac V, Gudumac V, Rivneac E, Pretula R, Grecikina E. Localizarea electron-histochimică a colagenazei în ficat [Electrochemical localization of collagenase in the liver]. In: [Scientific Annals of Nicolae Testemitanu State University of Medicine and Pharmacy. 9th ed. Vol. 1]. Chisinau: Medicina; 2008. p. 53-55. Romanian.
- Ueda M, Yamashita Y, Takehara M, Terai Y, Kumagai K, Ueki K, Kanda K, Yamaguchi H, Akise D, Hung YC, Ueki M. Surviving gene expression in endometriosis. J Clin Endocrinol Metab. 2002;87(7):3452-3459. doi: 10.1210/jcem.87.7.8682.
- Ye H, He Y, Wang J, Song T, Lan Z, Zhao Y, Xi M. Effect of matrix metalloproteinase promoter polymorphisms on endometriosis and adenomyosis risk: evidence from a meta-analysis. J Genet. 2016;95(3):611-619. doi: 10.1007/s12041-016-0675-5.
- Amălinei C, Căruntu ID, Bălan RA. Biology of metalloproteinases. Rom J Morphol Embriol. 2007;48(4):323-334.
- Patterson ML, Atkinson SJ, Knäuper V, Murphy G. Specific collagenolysis by gelatinase A, MMP-2, is determined by the hemopexin domain and not the fibronectin-like domain. FEBS Letters. 2001;503(2-3):158-162. doi: 10.1016/s0014-5793(01)02723-5.
- Hashizume K. Analysis of utero-placental-specific molecules and their functions during implantation and placentation in the bovine. J Reprod Dev. 2007;53(1):1-11. doi: 10.1262/jrd.18123.
- Sotnikova NY, Antsiferova YS, Posiseeva LV, Shishkov DN, Posiseev DV, Filippova ES. Mechanisms regulating invasiveness and growth of endometriosis lesions in rat experimental model and in humans. Fertil Steril. 2010;93(8):2701-2705. doi: 10.1016/j.fertnstert.2009.11.024.
- Gaide Chevronnay HP, Selvais C, Emonard H, Galant C, Marbaix E, Henriot P. Regulation of matrix metalloproteinases activity studied in human endometrium as a paradigm of cyclic tissue breakdown and regeneration. Biochim Biophys Acta. 2012;1824(1):146-156. doi: 10.1016/j.bbapap.2011.09.003.
- Di Carlo C, Bonifacio M, Tommaselli GA, Bifulco G, Guerra G, Nappi C. Metalloproteinases, vascular endothelial growth factor, and angiopoietin 1 and 2 in eutopic and ectopic endometrium. Fertil Steril. 2009;91(6):2315-2323. doi: 10.1016/j.fertnstert.2008.03.079.
- Chung HW, Lee JY, Moon HS, Hur SE, Park MH, Wen Y, Polan ML. Matrix metalloproteinase-2, membranous type 1 matrix metalloproteinase, and tissue inhibitor of metalloproteinase-2 expression in ectopic and eutopic endometrium. Fertil Steril. 2002;78(4):787-795. doi: 10.1016/s0015-0282(02)03322-8.
- Uzan C, Cortez A, Dufournet C, Fauvet R, Siffroi JP, Darai E. Eutopic endometrium and peritoneal, ovarian and bowel endometriotic tissues express a different profile of matrix metalloproteinases-2, -3 and -11, and of tissue inhibitor metalloproteinases-1 and -2. Virchows Arch. 2004;445(6):603-609. doi: 10.1007/s00428-004-1117-y.

Authors' ORCID iDs and academic degrees

Eugeniu Cazacu, MD, PhD Applicant – <https://orcid.org/0000-0003-2893-6401>.

Eremai Zota, MD, PhD, Associate Professor – <https://orcid.org/0000-0003-1365-2633>.

Claudiu Margaritescu, MD, PhD, Professor – <https://orcid.org/0000-0002-4937-5589>.

Radu Niguleanu, MD, PhD, Associate Professor – <https://orcid.org/0000-0002-6797-6142>.

Ruslan Pretula, MD, PhD, Associate Professor – <https://orcid.org/0000-0002-4785-3647>.

Authors' contribution

EC designed the trial, interpreted the data, wrote the manuscript, revised and approved the final version of the manuscript; EZ conducted and conceptualized the project; CM conducted the laboratory work, revised the manuscript critically; RP collected material and performed the laboratory work; RN collected material and performed the laboratory work. All the authors revised the final version of the manuscript.

Funding

The study was supported by Nicolae Testemitanu State University of Medicine and Pharmacy. No grants were involved in supporting this work. The authors are independent and take responsibility for the integrity of the data and accuracy of the data analysis.

Ethics approval and consent to participate

The study protocol was approved by the Research Ethics Committee of Nicolae Testemitanu State University of Medicine and Pharmacy of the Republic of Moldova (proceeding No 63/58, 16.03.2017). Written informed consent was obtained from all participants in the study.

Conflict of Interests

There is no known conflict of interests and financial or non-financial support associated with this publication.