

REVIEW ARTICLES

DOI: 10.5281/zenodo.1050972
UDC: 616.617-007.272-072.1



Infravesical urinary tract obstruction and transurethral endoscopic approach of treatment

Ghicavii Vitalii

Department of Urology and Surgical Nephrology, Nicolae Testemitsanu State University of Medicine and Pharmacy
Chisinau, the Republic of Moldova

Corresponding author: vghicavii@gmail.com. Received December 26, 2016; accepted February 10, 2017

Abstract

Background: The results of scientific progress in recent years have contributed to the development of transurethral endoscopic surgery, with the implementation of new methods, less invasive, for the treatment of the lower urinary tract diseases of different genesis. Laser surgery, transurethral electorezection, electrovaporization, bipolar surgery (plasmakinetic rezection and vaporization) and the combination of these methods have a number of advantages over traditional open interventions and contribute to a significant change in the treatment approach of most urological diseases, including those causing infravesical obstruction (IVO).

Conclusions: The implementation of personalized medicine with correct selecting and pathogenetic motivation of the methods of treatment in management of the IVO have been made in several directions: prophylactics, diagnosis and treatment. Medical and social importance, variety of clinic manifestations and evolution, evident alternation of quality of life, high cost of diagnostic, conservative management and of surgical treatment determine the status of infravesical obstruction as a current problem from scientific and practical point of view and motivates the need of a deep study of disorders manifested through IVO, minimizing complications and the rate of their relapse.

Key words: infravesical obstruction, stricture, hyperplasia.

Introduction

Infravesical obstruction (IVO) is a polyetiological and pathological condition caused by a number of urological diseases, which lead to an impaired urinary elimination from the bladder because of an obstruction in the bladder neck or urethral region.

According to statistical data, infravesical obstruction occurs in 50% of men aged 60 years and 90% of those who reached the age 85. Among men with infravesical urodynamic disorders, obstructive uropathy occurs in 20-35% of cases, and hydronephrosis, as a complication, – in 3.8% of cases [1]. In 23.9% of cases, infravesical obstruction in older men is conditioned by the development of prostate sclerosis, whereas benign prostate hyperplasia (BPH) associated with sclerotic changes is the commonest one [2]. Obstructive uropathy, caused by prostate disorder occurs in 5% of new cases of hemodialysis, in population aged over 65 years [3].

Any kind of micturition disorders may significantly reduce quality of life, develop psychological problems, which can affect family and employment relationships, and lead to social isolation. Besides the life-threatening conditions patients may experience, micturition disorders can lead to serious physical and moral sufferings, caused by deep psychological trauma, sexual conflict, the onset of neurosis and neurasthenia. From the psychological perspective, IVO is often associated with depressive disorders and is the most difficult pathology to diagnose. The long-lasting evolution, persistent dysuria and frequent recurrences may sometimes

arise a feeling of hopelessness among patients regarding their treatment.

Infravesical obstruction is caused by urological diseases, which lead to the impairment of urinary evacuation, micturition difficulties, retention of urine and other types of dysuria. Infravesical obstruction is a characteristic symptom related to the following diseases like (fig. 1): adenoma of the prostate or benign prostatic hyperplasia, prostate cancer, bladder cancer (particularly located in the bladder neck), prostate and bladder neck sclerosis, urethral stricture and obliteration etc. [1,4]. The urodynamic reconstructure of urinary tract and the remodeling of regional renal and pelvic blood flow occur in infravesical obstruction [5, 6].

Subvesical obstruction, which causes the impairment of urinary evacuation, leads to urinary infection of both lower and upper tracts, and may commonly develop into cystitis and pyelonephritis. The obstacle in the urinary passage causes disturbance of micturition, which may eventually become worse viz. stranguria; pollakiuria; urinary incontinence (paradoxical ischuria) and the presence of residual urine, which is a polyetiological and pathological process, characterized by symptoms of lower urinary tract, which still remains a difficult problem for fundamental and practical medicine [7, 8].

Recently, there have been made a number of scientific researches in order to determine the causes of infravesical obstruction and optimize the best-corrected medical and surgical methods of treatment [9, 10].

The latest scientific clinical trials and technical progress have changed considerably the traditional urological treatment approach for many urinary diseases (fig. 1), which may result in infravesical obstruction i.e. benign prostatic hyperplasia, strictures and extended obliterations of the urethra, bladder neck and prostate sclerosis etc. [11].

Infravesical obstruction is most commonly met in old age and, in most cases, is caused by the development of a hyperplastic process in the prostate [12,13,14]. Benign prostatic hyperplasia is one of the most widespread polyetiologi- cal diseases in men of elderly and senile age, which occurs due to the proliferation of the transitional zone of the pros- tate, and paraurethral glands and lead to lower urinary tract obstruction [2, 15, 16, 17].

In this regard, according to the epidemiologic data, HBP was detected in 40% of men aged between 50 and 60 years, in 50% of men over 60 and in 90%-100% – after 80 years [2, 9, 18, 19]. It is considered that most men, over the age of 50, show certain symptoms caused by BPH [19], whereas the high life expectancy rates of aging men lead to an increased number of patients suffering from this disease [15]. Lately, some authors [20] mention the growth of BPH morbidity rates in population amongst most of countries.

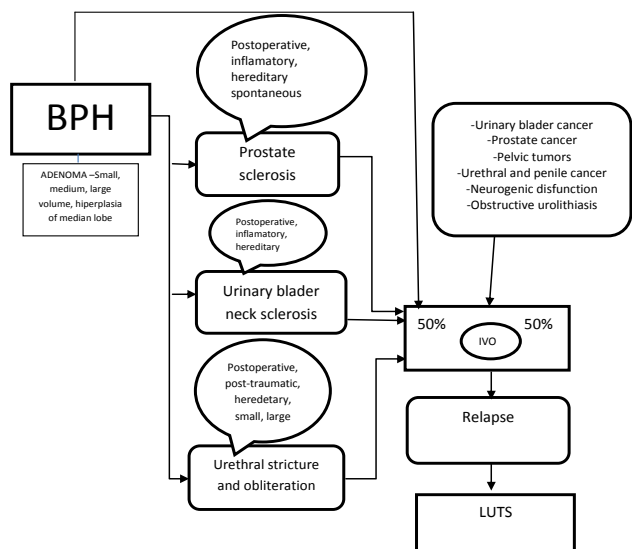


Fig 1. Urological disorders leading to infravesical obstruction. Infravesical obstruction caused by benign prostatic hyperplasia

The widespread BPH in men identifies the acute problem of timely diagnosis and well-reasoned treatment in the pathogenesis of this disease. It is extremely important, while choosing a reliable method of treatment for patients with BPH, to perform an accurate diagnosis of the disease and consider the shape of the prostate hyperplasia, degree of infravesical obstruction, prostate volume, as well [8, 21].

According to F. Schroder and I. Altwein [158], J.D. Mc Connell et al. [22], the clinical manifestations of BPH are detected in 34% of men aged 40-50 years, 67% of men aged 51-60 years, 77% of cases aged 61-70 years and 83% of men older than 70 years. Similar data were presented by other authors [23, 24].

In terms of clinical studies, the disease shows various symptoms related to the impairment of the urine passage through the lower urinary tract [25]. The causes of micturition disorder are infravesical urethral obstruction and underactive detrusor. The obstruction is caused by the enlargement of prostate with the gradual narrowing of the urethral lumen (mechanical component) and the hypertonus of smooth muscle fibres of the prostate and posterior urethra (dynamic component) (Fig. 2). On the basis of secondary changes of the detrusor with obstructed genesis, the stressors (direct influence of catecholamines) and ischemic (vasospasm) lesions of the smooth muscle elements of the bladder are of great importance. In these cases the bladder supports a large influence of catecholamines and, as a result of this process, disorders in bioenergetics and detrusor function occur [26, 27].

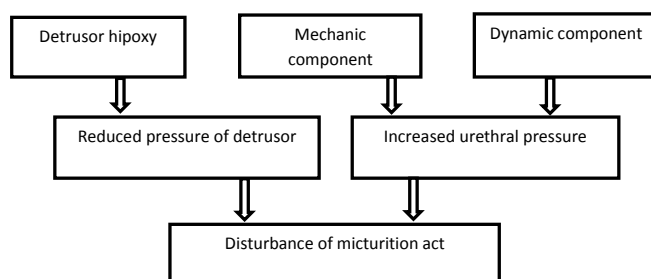


Fig. 2. The pathogenesis of impaired micturition in patients with BPH (A. Sivkov and co., 2009) [86].

Both theoretical and practical knowledge of the pathogenetic mechanisms present great importance in the development of obstructive uropathies. The research results of multilateral mechanisms of the pathogenesis of infravesical obstruction facilitate the detection of obstructive uropathies at the early stages, which enables the optimization of treatment methods in patients from the perspective of modern concepts, regarding the pathogenesis of this disorder, and allows the monitoring and timely performing of necessary changes in the selected treatment schemes.

Nowadays, the problem of benign prostatic hyperplasia treatment remains a current issue [17, 28, 29, 30]. Over the past 20 years, there has been an opportunity to treat patients at early stages of the disease using pathogenetically substantiated drug therapies [8]. The successful obtained results, in the study of the pathogenesis of prostatic hyperplasia and the use of medicinal treatment with pathogenetic oriented mechanism, made the drug therapy possible and truly effective for certain categories of patients, affected by this disease. However, drug therapy does not relieve completely the patient's condition with prostatic hyperplasia, since pharmacotherapeutical methods show short-acting effectiveness and are applied to a limited number of patients with BPH (with Ist stage), therefore about 30-40% of men suffering from BPH, at present, remain subjects to surgical therapy [31, 32].

Unfavorable criteria characteristic for progression of prostatic hyperplasia are as follows:

- Prostate-specific antigen (PSA) is increased over 4 ng / ml in blood serum;
- Prostatic hyperplasia volume over 45 cm³ (the possibility of a prostate edema in acute inflammatory process should be considered);
- IPSS scoring more than 7;
- Low urinary maximum flow rate (less than 10 ml/s).

Additionally, the patient's age and associated diseases play a significant role in choosing the treatment techniques, especially in surgical treatment.

Modern urology provides many methods of treatment of this disease [9,15,33], but the most radical procedures are considered the surgical methods only, which include open adenectomy and transurethral resection of BPH [31,34,35]. Modern Urological clinics perform TURP in 98.2% of cases and open interventions in 1.7-2.1% of cases [36].

In the treatment of large benign prostatic hyperplasia, transvesical adenectomy has long been considered as main surgical method [28]. But despite its high efficiency, the rate of postoperative complications shows higher indices compared to endoscopic interventions. Thus, the total number of complications after a transvesical adenectomy is between 12.5% – 23.02%, and according to C. G. Roehrborn data [37], this indicator reaches 38.5%. After transurethral resection, the postoperative complication rates range from 14.95% [22] to 18% [28,39]. Complications differ by structure as well; thus in late postoperative adenectomy the incidence of bladder neck sclerosis ranges from 2.9% to 7.1% of cases [39,40], and stricture of the urethra – up to 5.1% [41]; while after transurethral resection, these parameters vary between 0.77% and 1.7% [25] and from 2.6% to 7, 14% of cases, respectively [28].

Therefore, a major issue of modern surgery today, is the choice of surgical methods of treatment for patients with late obstructive complications of transvesical adenectomy [42]. Obstructive complications (bladder neck sclerosis and posterior urethral stricture), which are detected in 1.5% -9.2% of cases [43] may lead to the sudden worsening of the micturition and usually require extra special treatment, a correction performed by endoscopic therapy exclusively [38].

Transurethral prostatectomy or transurethral resection of the prostate is the second generation of surgical methods for the treatment of obstructive uropathies caused by benign prostatic hyperplasia

[44]. In fact, according to data of international meetings (American and European Association of Urology) for the treatment of prostatic hyperplasia, as well as different authors' opinions, transurethral resection of the prostate (TURP) is considered the "gold standard" treatment of BPH [29,33,38].

This method of treatment substituted open adenectomy, and is applied in 70% -95% of patients as an alternative method to the surgical treatment procedures of BPH and infravesical obstruction caused by it [33,45,46] and also repre-

sents from 63.7 to 98.3% of all invasive procedures for treatment of prostatic hyperplasia [21,34]. Actually, this method is equally efficient compared to an open surgery and simultaneously, it shows a number of advantages like less trauma, lower risk of recurrence in patients, fewer complications, reduced hospital stays, shorter rehabilitation period, low postoperative mortality rate, etc. [15,17]. TURP implementation has contributed to considerable broadening of indications to surgical treatment for patients with BPH and pronounced recurrent diseases, who until recently were doomed to a life-long elimination of urine through cystostomy [33,47,48].

However, it is worth mentioning, that in addition to its high efficiency, surgical treatment entails some risks of developing intra- and postoperative complications, which may occur in 8-22% of patients [9,12,49]. Additionally, in case of some categories of patients with BPH, open prostatectomy (adenectomy) or TURP are life-threatening or contraindicated procedures, whereas drug therapy is inefficient due to the pronounced symptoms of infravesical obstruction [38]. Such patients are often bound to live with cystostomy, which seriously reduces their quality of life and leads to social inadequacy of the patient.

Despite its high clinical efficiency, TURP has a number of complications, which are detected in 25.67% of operated patients [9,17,50]. These include false and true recurrences of BPH, intra- and postoperative bleeding, TUR syndrome, urinary incontinence, bladder neck sclerosis, urethral stricture, retrograde ejaculation, etc.

Thus, according to A. Martov et al. [18] and N. Sergienko et al. [14], patients with BPH, following TURP presented early intraoperative and postoperative bleeding in 11.5% of patients, acute urethritis – 5.8%, acute epididymitis – 29%, acute urinary retention – 5.4%, maintainance of irritative symptoms in the late postoperative period – 10.6%, bladder neck sclerosis – 4.2%, urethral stricture – 6.9%, incontinence of urine – 1.6% of cases.

Complications of transurethral resection are divided into early and late intraoperative and postoperative ones [9,17,18]. During intraoperative and early postoperative periods, the following complications may occur: profuse hemorrhage, signs of water intoxication (TURP syndrome), urinary tracts injury, acute urinary retention, infections and inflammatory complications; whereas during late postoperative period, complications like maintainance of irritative symptoms, urethral stricture, bladder neck sclerosis, incontinence of urine, disease recurrence, retrograde ejaculation may commonly occur. Many of these complications require repeated surgery [9,25].

Retrospective analysis of TURP complications [51] showed that the occurrence of intraoperative and early postoperative complications is related to the level of training of TURP techniques (it has been reduced from 21 to 4.2%). In this regard, a considerable attention is paid to the peculiarities of form and morphological structure of BPH, since the inflammatory complications occurred on the already pre-existing diseases (chronic prostatitis and chronic

pyelonephritis). According to the authors, scarce results of endoscopic interventions characterized by persistent irritative symptoms were determined, in most cases by dynamic components, simultaneously with detrusor dysfunction. In this case, incorrect indications and unjustified surgical treatment play an important role in the development of complications and require further scientific and practical research.

The highest percentage of all postoperative complications refers to infravesical obstruction recurrence. According to M. Trapeznikova et al. [52], the recurrent postoperative IVO may be early (immediate) and late. In fact, early postoperative IVO recurrence has technical aspects of interventions, whereas late postoperative IVO is caused by scarring of the urethra and vesico-urethral portion (strictures and obliterations) and the continuous growth of adenomatous tissue (true or false recurrence of BPH) [9,25].

The existing scientific studies, regarding the problem of postoperative complications of transvesical adenomectomy and transurethral resection, as well as the measures used to prevent them, do not clarify a number of issues, such as: causes of complications in the postoperative period; their relation to the morphological structure of the prostate; the dependence of the late complications development on the early postoperative period development. Until nowadays, there is no clear picture of the recurrent causes of infravesical obstruction after BPH, mechanisms of its development, methods of treatment and prophylaxis.

According to A. Martov et al. analysis [17,18,53], the incidence of postoperative complications following the new endoscopic interventions of prostatic hyperplasia showed, that the major problem in the early period of standard TURP, is still a relatively high frequency of bleeding complications, especially in cases when blood transfusions were required. In the later periods of rotoresction and „vaporized“ resection, there was a higher incidence of bladder neck sclerosis (10%) and urethral stricture after TURP in 6.9% cases. Therefore, minimally invasive alternative methods, such as TURP will successfully solve the problem of infravesical obstruction, whereas a number of complications restrict their use in clinical practice. According to the same group of authors [17], new transurethral endoscopic interventions highly reduce the number of intraoperative complications.

Despite the continuous improvement of surgical treatment, postoperative complications still remain at a high level of incidence and do not tend to decrease. There have not been sufficiently studied the particularities of clinical progression of large BPH [54], nor the development of it, as well as identification and treatment of infravesical obstruction in patients with median lobe hyperplasia of BPH.

Clinical manifestations of BPH are largely dependent upon the patterns of nodular hyperplasia growth and volume, which eventually lead to infravesical obstruction. It is a well-known fact that in patients with BPH, hyperplasia may occur in the lateral lobes, median lobe or all three lobes of the gland simultaneously [43].

There has been already established the role of so-called

median lobe hyperplasia (MLH) of the prostate in the development of infravesical obstruction [55]. Some authors [56,57] consider the specific feature of median lobe of BPH, is inefficiency in treatment of this disease via different drug therapies.

Up to now, we have little information on the peculiarities of diagnosis and treatment of patients with BPH median lobe hyperplasia [58]. There are known only basic criteria that would contribute to an objective assessment of the participation degree of the median lobe hyperplasia, concurrently with the lateral lobes, in the evolution of infravesical obstruction in patients with BPH.

Complex research data on urodynamics (pressure-flow) also confirm the presence, characteristics and expressiveness of infravesical obstruction. It is also important to determine the role of an enlarged median lobe of BPH, which acts as a valve in the development of infravesical obstruction, and as a risk factor of possible complications following surgical interventions, as well as its effect on late treatment outcomes in such patients.

Traditionally, TURP treatment was applied to a relatively small prostate volume – up to 80 cm³. But along with the improvement of transurethral surgery, this method has been used to remove the large prostate gland, as well, about 100-120 cm³ (the mandatory requirement is sufficient experience of the surgeon). Larger BPH (over 80 cm³) were detected in 10-20% of patients with this pathology. The removal of adenoma of such dimensions is possible through various means, including: transvesical and retropubic adenomectomy, transurethral resection, laser enucleation of the prostate, transurethral bipolar enucleation (TURBE). There have already been developed various techniques of transurethral interventions according to the size of gland hyperplasia. Thus, prostate vaporization is applied to a prostate gland volume of 30 cm³, TURis BPH in 35-80 cm³ volume, TURBE – 90-250 cm³. According to A. Martov et al. (2014), transurethral enucleation in larger BPH (over 100 cm³) is an alternative method to open adenomectomy or transurethral resection of the prostate (TURP). The method combines the minimally invasive TURP and radical pattern of open surgery. No doubt, minimally invasive interventions are more preferable compared to open adenomectomy. The removal of enucleated nodes can be performed via morcellators, by a common resection loop for TURP procedure and by cystoscopic access for large bladder gallstones [54,59]. Due to the obtained results following transurethral electroenucleation procedures using morcellators in HBP of various sizes, a number of authors were able to conclude [54,59] that transurethral electroenucleation of prostate (TURBE) by morcellation is an effective method to treat large BPH. The high speed of morcellator enables to reduce the time of intervention, and the obtained material is completely useful for histological research in terms of ensuring adequate irrigation and hemostasis quality.

However, TURP is not applied on a prostate gland volume of 150 cm³ and larger, because of the high incidence

of intraoperative complications (bleeding, TUR syndrome, etc.), which will increase in number along with the hyperplasia tissue growth following an electroresection [12,19,49].

Moreover, complications after standard transurethral resection are more likely to occur i.e. the intraoperative and postoperative hemorrhage (in 0.9 to 10% of patients) and “water intoxication” syndrome (0.1-1% of patients) have led to the onset of minimally invasive alternative technologies, including endoscopic treatment of patients with HBP – methods that show efficiency and are comparable to TURP and would decrease the number of complications and failures [12,25,49].

The list of alternative technologies has expanded considerably in recent years and includes drug therapy, stenting, balloon dilatation, hyperthermia and thermotherapy, ultrasound and needle ablation, interstitial clotting, transurethral microwave therapy (TUMT), as well as administration of ethyl alcohol (ethanol) and Botox, etc. Although, these techniques decrease the number of complications, they still cannot be compared to transurethral resection in terms of efficiency, both clinically and economically [60]. These methods have not been widely used either due to their inefficiency or because of the unfavorable complications [15,60].

The current, third period in the treatment of BPH is characterized by the rapid development of new endoscopic technological methods, which do compete with TURP in BPH treatment, being considered as the basic method of treatment during the last decades.

Bipolar transurethral resection of the prostate [30], Holmium laser (HoLEP) ablation (enucleation) [54,61,62,63,64,65] and transurethral vaporization of the prostate (TUVRP) show new means of BPH treatment [61,63,66].

Each of the methods has its own advantages and disadvantages. Availability of instruments, surgical skills and the indications for one or another method may largely determine the successful outcome. TURP of the prostate can be monopolar or bipolar; using the thin or thick loop [29,67]. Bipolar TUR of the prostate is associated with less bleeding and low risk of developing dilutional hyponatremia.

In the early 90s, the development of endoscopic electrosurgical technologies of prostate has led to the onset of a new method: Transurethral electrovaporization. Electrovaporization combines the advantages of the standard transurethral resection (immediate tissue removal, optical control of intervention, clinical and economical effectiveness) and a considerable decrease of intra- and postoperative bleeding, as well as prevention “of water intoxication” of the body [42,49]. Transurethral vaporization, which uses thick cuneiform loop, causes vaporization and resection of the prostatic tissue, which is followed by a less hemorrhage and characterized by a shorter duration of intervention [42,68].

However, the practice shows that electrovaporization of prostate has its own disadvantages, too. Thus, e.g. “roller vaporization,” which is the easiest technique to learn from the entire spectrum of electrosurgical methodologies used in treatment of BPH (simple technical management, good

endoscopic visibility, no bleeding), has a lower capacity for removal (ablation) of hyperplasia tissue compared to monopolar transurethral resection. This is due to the fact that, firstly, roller vaporization may remove (evaporate) less tissue per time unit than in resection; and, secondly, the vaporization of the tissue is much more durable and lasting, since the carbonized layer that is formed slows the process down and a rehydration of tissue is required to resume the effect of vaporization. All of these require the application of roller vaporization in terms of a monotherapy for adenomas volume not exceeding 40 cm³ [69]. Vaporized resection, on the contrary, can be compared to standard transurethral resection in terms of efficiency and time of performance, but still it is as hard to be learned, because of the haemostatic effect of vaporizing loop, which is not as pronounced as the “roller vaportrode” whereas the technique performed on sections and the removal of adenomas requires considerable experience and training [31].

In order to overcome these deficiencies and reduce the number of complications mentioned above, as well as to improve the treatment outcomes of BPH and expand indications for surgical treatment in patients with somatic symptoms, a new direction in endoscopy has been required. Bipolar surgery, which has developed new technologies – resection and plasmakinetic vaporization (Plasma Kinetic TM Gyros), uses saline solutions as irrigation fluid; no electric current flow is needed through the patient's body due to the placement of 2 electrodes directly into the instrument, compared to standard monopolar resection, where the passive electrode is placed on the patient's lower limb [70,71,72].

It is worth mentioning, there has been little research reported on this issue, so far. The clinical effectiveness, indications and contraindications for this technique have not been fully described. There is a lack of knowledge regarding specific complications of this method. A high interest is paid to the comparative study of clinical characteristics of postoperative period and distant treatment outcomes in patients after a standard monopolar transurethral resection with a loop electrode and plasmakinetic transurethral resection. These describe the actuality of the subject, both from a scientific and practical point of view, as well as the need for a comparative study of the effectiveness of this endoscopic technique.

The number of patients with BPH is increasing continuously, due to the growth of elderly population, development of diagnostic techniques, higher average life expectancy and men's need to improve their quality of life. In the surgical treatment of BPH, transurethral resection shows a percentage range from 63.7 to 98.3% of all invasive treatment techniques of prostatic hyperplasia. It took almost 50 years for TURP to replace open prostatectomy and become a predetermined intervention. However, complications like bleeding, retrograde ejaculation and TUR syndrome limit the use of this method in a number of patients [68]. Currently, transurethral resection of the prostate (TURP), which is considered the “gold standard” for treatment of urinary obstruction caused by benign prostatic hyperplasia, is entailing a

real threat. New minimally invasive endoscopic laser methods are being implemented in patients with IVO, caused by prostatic hyperplasia (BPH), specifically laser enucleation [10,62,73,74,75], which allows to reduce the number of complications and patient's hospital stay.

Laser technologies have been successfully applied in medicine worldwide for more than 35 years. In the last 25 years, laser treatment has been used in the most specific medical specialties, and presents an ideal combination of cutting and coagulation properties.

For the first time, neodymium laser was applied to the coagulation of prostatic tissue in 1979 by R. Bowering et al. Since 1990-1994, there appeared first international scientific works [10,62,63, 76,77], including Russian scientists [54,59,61], regarding the successful use of laser radiation and, particularly, the neodymium laser with a wavelength of 1064 nm in the treatment of patients suffering from BPH.

At present, both contact or non-contact laser methods are being used for coagulation and vaporization of hyperplasia tissue of the prostate in order to decrease its volume and provide a proper flow of urine from the bladder [78].

Holmium YAG laser treatment of the prostate has developed from simple ablation, resection to the modern technique of enucleation. Holmium laser ablation of the prostate (HoLAP) is a painstaking process because of slow tissue ablation rate and is indicated only for small glands. HoLRP involves a partial enucleation of each prostatic lobe, which is then divided into small pieces of the lobe, still attached to the capsule. Although HoLRP was faster than HoLAP, it still has a longer duration than TURP. The use of morcellator led to the onset of HoLEP technique – Holmium laser enucleation of the prostate [76].

Holmium YAG laser resection is usually applied in cases when the prostate volume does not exceed 60 cm³; enucleation is performed in larger prostate. It is known that laser surgery of BPH has both advantages and disadvantages. The advantages of this method include lack of intraoperative and postoperative bleeding and “TUR syndrome”, reduced invasive and traumatic features, and a very important fact, the possibility to be performed in patients with high surgical and anesthesiological risks. The disadvantages of laser method are the prolonged postoperative urine discharge, longer duration of intervention, the relatively non-radical character of treatment, the late onset of deobstruction, considerable postoperative dysuria. Recently, some authors [54,79] have been studying perspectives of mutual combination of these laser methodologies in surgical treatment of patients with BPH. The laser surgery of BPH, like other less invasive methods of surgical treatment of this disease, ensures a successful surgical outcome by reducing life-threatening complications [62,80]. However, despite the successful results, many issues of laser surgery of BPH, still remain uncertain.

Lower urinary tract obstruction caused by sclerosis of the bladder neck and prostate

Infravesical obstruction caused by bladder neck sclerosis is the result of the scarring process of the connective tissue

subjected to inflammation in the region of bladder neck and which partially affects the muscular wall; or a result of excessive electrocautery in that area during TURP procedure, as well as excessive suturing of the BPH lodge following a classic adenomectomy.

Bladder neck sclerosis according to N. Lopatkin and A. Pugaciov [81] affects 65% of patients, A. Liuliko and T. Kodiri [12] recorded 77.4% of cases, whereas G. Bakiev [82] stated 80.9%. In its turn secondary BNS is one of the complications of late postoperative period in patients with benign prostatic hyperplasia, which occurs in 0.4 to 24.8% of cases, thus secondary BNS remains a serious problem in modern urology. In the study conducted by Ying-Huei Lee et al. [83] on a lot of 1.135 patients who underwent standard transurethral resection (TURP), 9.7% of patients developed BNS during the mean postoperative follow-up of 37 months. Small prostates were initially diagnosed in most of these cases [83]. Another study conducted by W. Al-Singary et al. [84] on a lot of 900 patients during a follow-up of 4 years after monopolar TURP procedure, showed that 3.4% of patients developed BNS with a mean resected prostatic tissue weight of 11 ± 3.7 g. One of the causes of BNS development after the surgical treatment for BPH is the concomitant chronic prostatitis [15], whereas the onset of the sclerotic process starts in the postoperative period, following a trauma or acute inflammatory process in the bladder neck region [11]. Sclerotic processes most actively evolve in conditions of hypoxia, whilst inflammatory process will only worsen the situation [70,85].

The pathological condition may develop through the stricture or complete obliteration of the bladder neck and is characterized by IVO progression to full retention of the micturition, which further will require bladder drainage (cystostomy). In the latter case, the condition is associated with social inadequacy of the patient, development of chronic pyelonephritis, chronic cystitis and eventually bladder sclerosis.

The incidence of developing bladder sclerosis is different, according to the types of surgical interventions. Thus, there were recorded 1.7% to 3.9% of cases following transvesical adenomectomy, 2-10% of patients after TURP, 1.28% of patients treated with bipolar plasmakinetic resection, 0.5% to 3.8% of cases occurred after Holmium laser TURP. According to EAU Guidelines, the risk of developing this pathology is 4% in patients treated by TURP, 1.8% after an open surgery for BPH and 0.5% to 14.6% after radical prostatectomy for prostate cancer [86,87,88].

Therefore, secondary bladder neck sclerosis is one of the most common chronic complications following a surgical treatment of the prostate.

According to N. Nashivocnikova, [29,89], the incidence of bladder neck sclerosis after a surgical treatment of BPH is 15.5% and does not depend upon the surgical method, prostate size and patient's age, but it depends on the recurrence of hemodynamic disorders in the pelvis and the presence of inflammation in the prostate.

The presence of microcirculatory disorders in the blad-

der neck in patients with BPH is a pathogenetic factor in the development of basic sclerosis. It is detected in patients at already preoperative stage, lasts throughout the postoperative period and as a result of a chronic inflammation may lead to pathological scarring [85]. The improvement of microcirculatory parameters in bladder neck region in patients with BPH, prior to surgery and during the immediate postoperative periods, can prevent the developing of bladder neck sclerosis, whilst in patients with BNS help reduce the recurrence rate from 7.9% to 0.82 % [70,85].

The severity of BNS and other chronic disorders of urodynamics of the lower urinary tract is determined not only by changes in LUT, but also by the urodynamics of upper urinary tract (UUT). UUT changes are often decisive in assessing the severity of the disease and the choice for surgical indications [90]. For this reason the study of disease severity in selecting indications for surgery is an important step in the treatment of bladder neck sclerosis [91].

According to bibliographical data, the diagnosis and treatment tactics of bladder neck sclerosis entail some difficulties, since many tests that determine the type of disorder, also may refer to other causes of infravesical obstruction, as well. Diagnosis is particularly difficult in the early stages, when there is no clear image of the degree of clinical characteristics and radiological data [4;50].

Detection of bladder neck sclerosis is based on patient's complaints regarding difficulties in urination or inability to empty the bladder in a natural way; on the information about previous surgeries and complicated evolution of immediate postoperative period. The disease is diagnosed via radiological examination and endoscopic methods.

Therefore, in BNS, the findings of ascending urethrograms may determine the free permeability of the urethra up till the bladder neck; whilst in the urethra stricture, it is detected in the distal region of the urethra (in relation to the bladder neck). In case of "Prevesical space", there is an extra cavity between the bladder neck stenosis and the constricted portion of the urethra, which is shown on the urethrogram. In order to determine the degree of manifestation and location of IVO, the ascending urethrography of contrast is performed; and if micturition is still present, then – uroflowmetry and ureteroscopy. The differential diagnosis of patients with other obstructive complications after previous surgeries is carried out in: urethral stricture, false urethral channels, "Prevesical space" and sclerosis of the prostate. Common symptoms for these conditions are difficulties in urination or its complete retention.

An important issue in contemporary urology is the treatment of bladder neck sclerosis, since it is being widespread, especially in men of older and senile age [92]. Postoperative bladder neck sclerosis is a complication of TURP or radical prostatectomy, which still remains an unsolved problem [93,94]; although, a number of surgical treatment methods are known for both primary and secondary BNS.

The purpose of treatment of bladder neck sclerosis is to restore the permeability of vesicourethral segment through

various methods of interventions. There were submitted various proposals to solve this problem. Therapeutic options range from regular dilation with balloon with about 50% of recurrences, to cold loop resection, TURP of bladder neck in order to place the stent and others. The indication for intervention is the sign of IVO.

The choice of the surgical type is largely determined by the degree of the bladder and kidneys disorder [86,90,95].

Until recently, the most of old aged and senile patients have undergone open resection for bladder neck sclerosis. This surgery, despite its effectiveness, was quite traumatic and led to development of complications [92].

Transurethral resection of scar tissue (TURP of bladder neck), originally described by Sachse in 1974 remains the standard method of treatment for bladder neck obstruction in men with postoperative bladder neck sclerosis [92], which compared to the open surgical intervention is described as being highly effective in treatment of infravesical obstruction and symptoms caused by it. It is considered less traumatic, gives chances for being repeated without any significantly increased risk for the patients and it obviously provides a shorter rehabilitation period etc. However, the proposed surgical treatment methods are complex, multi-level and often ineffective. The existing treatment methods can cause hemorrhage, hematomas and scar formation with subsequent recurrent relapses and may require repeated interventions. The above listed surgical interventions are considered inefficient since there is no assessment of the manifestation degree of the scarring process on the bladder wall, of the conditions of trigonal-urethral and vesicourethral regions, in terms of infravesical obstruction treatment.

There are several poorly highlighted aspects. These concerns include: a complex of necessary diagnostic methods, more accurately assessed indications and contraindications for transurethral and "open" resection for the bladder neck in patients with BNS, technical peculiarities of endoscopic and open surgeries to patients of this category, the study of intraoperative and postoperative complications of transurethral and transvesical resection of the bladder neck and their preventive measures, peculiarities of pre- and postoperative management of elderly and senile patients.

Since, the surgical intervention is considered the basic method in the treatment of BPH and complications are inevitable, the number of postoperative patients with prostate and bladder neck sclerosis, obviously increases [92]. Thus, M. J. Bader et al. assessed the obstructive complications rate from 1.1% to 24.8% of cases, after an adenectomy; whilst according to T. Bach et al. [93], bladder neck sclerosis is observed in 3.6 to 17.9% of patients after radical prostatectomy or TURP.

Therefore, a further research and development of less traumatic alternative treatment options are required to be learned and implemented, as well as the improvement of already existing methods such as bipolar plasma vaporization [86,94], using various laser treatments with good results, including neodymium, argon and holmium (YAG laser) [64,93,96].

Prostate sclerosis is a disease, where the sclerosis parenchyma of the gland constricts the prostatic urethra, narrows the bladder neck and vesical sections of ureters, compresses the deferens channels, causes dysfunction during micturition and urinary stasis, causes a decrease in kidney function and disruption of various phases of the copulative cycle. Prostate sclerosis does not refer to the category of widely spread urological diseases. It raised the interest among urologists, since the infravesical obstruction caused by the prostate sclerosis is found in 52.8% of younger men (up to 59 years) and if left untreated ends up with the end-stage kidney failure. Comparative studies of the prostate sclerosis and BPH incidence have established a ratio of 1: 5 of these conditions in 1970-80 and 1: 3.2, in 1986-1995, which shows an increasing tendency of cases. Particularities of the prostate sclerosis process have been established. In younger men (up to 50 years) prostate sclerosis is often associated with focal hyperplasia of parenchyma and develops on the background of chronic inflammation. In patients older than 50 years, modified atrophic parenchyma, with cystic changes are detected [97].

According to the unanimous opinion of scientists, the prostate sclerosis is genetically related to prostatitis [98]. The inflammatory process in the gland is found in 62% of cases. Chronic Prostatitis leads to BPH in 40-100% of cases [99].

Prostate sclerosis (73%) is one of the end- stages of the chronic inflammatory process in the prostate (chronic prostatitis) [92,99]. This stage is characterized, as a rule, by a decrease in the inflammatory process activity; simultaneously, the organ is considerably replaced by a scar connective tissue [92]. Additionally, prostate sclerosis is a complication of the late period in patients who underwent adenectomy (6%) or TURP (21%) related to BPH. In some patients, prostate sclerosis causes infravesical obstruction. It was determined that in 23.9% of elderly men, infravesical obstruction is conditioned by the development of prostate sclerosis and, that small BPH are most commonly associated with sclerotic changes in the prostate [92].

The treatment of prostate sclerosis is an important issue of the modern Urology regarding the widespread nature of this disease, especially in men of older and senile age [92]. Simultaneously, the increase in average life expectancy considerably raises the number of patients of elderly and senile age, who also present intercurrent conditions, thus increasing the risk for surgical interventions [40]. Intercurrent conditions of other organs and systems complicate evolution and basic treatment in 35.8% of patients. Since high-risk surgical patients are reported in 13% to 17% of cases, they do not undergo a radical surgery; cystostomy is performed instead, which leads to social inadequacy of the patient. Since the surgical intervention is considered the major method of treatment of BPH and the presence of obstructive complications is inevitable, the number of patients with prostate sclerosis increases, as well. Obstructive complications after adenectomy are reported by V. Bazaev and A. Morozov [100] in 1.1% to 24.8% of cases. Thus, according to bibliographic sources, prostate sclerosis and benign prostatic hyperplasia

are mostly prevalent among male urological in-patients, and therefore the effectiveness of treatment of these diseases is of great economic and social importance [2]. Currently, TURP is considered the most effective method of treatment of prostate sclerosis in order to remove the infravesical obstruction, [101; 102].

Analysis of surgical outcomes based on a lot of 165 prostate sclerosis patients and further improvement of urodynamic parameters, allowed L. Gorilovskii and M. Dobrotov [92] to conclude that transurethral resection is an effective method to treat infravesical obstruction and restore the micturition, especially in patients of older age and senile, while improving the quality of life, as well. Beneficial results, regarding the improvement of symptoms after the surgical treatment of prostate sclerosis, were determined in patients with obstructive symptoms of the disease rather than irritative ones. From the morphological point of view it has been proved that the prostate sclerosis is a result of the so-called stromal hyperplasia, being one of the types of prostate hyperplasia. [92]. It is based on the proliferation of stromal elements, although in some cases lax muscle fibre type stromae forms a nodule of muscle fibre- type, so-called spheroids. The prostate in this case is rather consistent and slow-growing.

The main task in the surgical treatment of prostate sclerosis is to reduce the number of intraoperative complications, early and late postoperative complications and morbidity rate. In order to achieve this goal, it is necessary to reduce the number of open surgeries and increase interest for endoscopic treatment methods, specifically TURP, laser, and plasmakinetics.

However, despite the good results and the efficiency of TURP, it still does not lack complications like bleeding during and after surgery (arising in 0.9 to 10% of patients), as well as the body water intoxication syndrome – “TUR syndrome” (0.1 – 1% of patients), which sometimes lead to unfavorable results.

The mortality rate, even if it is lower than for open surgery, it still remains quite high, which is particularly important in elderly and senile patients [2]. All these aspects facilitate the search for optimized treatment technologies [92].

Subvesical obstruction caused by stricture and obliteration of the urethra

Urethral stricture is one of the most complicated urological diseases. The incidence of the stricture of the urogenital system diseases constitutes about 6% of cases [12]. It is actually thought, that the incidence of urethral strictures is much higher, since quite often patients, who complain of disorders in urination, are incorrectly diagnosed (i.e. atony of bladder, prostate adenoma, chronic prostatitis, chronic cystitis etc.). But the real disease, namely urethral stricture, is detected only during a further deep investigation, whereas in a number of cases, it remains undiagnosed [103].

Urethral stricture is the second most common cause of obstructive micturition disorders in men regarding the pros-

tate diseases [104,105]. In the last two decades, the incidence of urethral strictures significantly increased. This is due to several factors: on the one hand, the increased number of severe damages of pelvic organs [106,107]; and on the other hand, as a result of the largely implemented endoscopic methods and transurethral resection [107]. The incidence of posterior urethral stricture and bladder neck sclerosis is particularly high [23,105,108].

Until the widespread practical implementation in urology of endoscopic treatment methods, mostly, transurethral resection of the prostate in patients with urethral stricture, the major part was represented by patients who suffered a trauma. In this case, 47.7% of the patients were aged between 21 to 40 years. Traumatic stricture was found in 84.7% of patients, including 9.6% of cases, caused by adenomectomy and medical manipulations [31]. Over 10 years, the last figure rose to 14.7% [109]. The iatrogenic cause of stricture occurrence is found in 24% of cases, whereas adenomectomy and TURP were the causes of stricture development in 13.6% and 10.5% of cases, respectively. A slightly different situation is noticed in case analysis of urethral obliteration. In 40.7% of cases, obliteration is caused by traumas; 39.53% of cases showed an iatrogenic cause (transvesical adenomectomy – 33.72%, TUR of the prostate – 5.81%); obliteration arising after a previous plastic interventions in the urethra – 19.77% [89,110]. Patients with posterior urethral and bladder neck obliteration are the most difficult category of patients with urethral obstruction [82].

Urethral stricture is a condition characterized by various symptoms of lower urinary tract that are and depend on the cause, location and severity of the strictures [23]. The symptoms of urethral strictures (the urinary stream is characterized by a weak, thin, forceless, sometimes “dripping” flow) and possible complications (incomplete or complete retention of urine, fully distention of urinary tract and, even renal failure) may lead to confusion in the diagnosis of obstructive urinary diseases. Basic causes are commonly benign (infectious, ischemic, iatrogenic, traumatic, congenital, undetermined) or rarely, neoplastic (not examined in this study). The etiology of scar is characterized by traumatic, inflammatory and congenital causes. According to their location, they can be prostatic, membranous, bulbar, penile; according to their size (expansion) short (≤ 2 cm), long (≥ 2 cm); with subtotal damage in 75-90% of the spongy urethra, total spongy (total damage of spongy urethra) and total (total damage of the urethra); by number – single and multiple; according to the degree of narrowing of the urethra: mild – lumen is narrowed up to 50%; moderate – lumen is narrowed to 75%; severe – lumen is narrowed more than 75%; obliteration – no lumen.

Male urethral stricture is an obstructive polyetiologic disease, which involves urethral epithelium, spongy body, and in some cases paraurethral tissues. Due to the changes of scar tissue in the urethral walls, the progressive narrowing of the lumen diameter (in one or more places) occurs.

In elderly and senile men, a previous surgery is often the

cause of urethral stricture or obliteration [82,105,106]. The list of interventions which lead to urethral strictures, most often includes the surgeries associated with benign prostatic hyperplasia: transvesical adenomectomy, transurethral resection of the prostate.

In recent years, it is complemented by radical prostatectomy performed in prostate cancer. Urethral stricture following such type of surgery, obviously, occurs in patients of advanced or senile age [16,23]. There is a high risk for a considerable number of patients to undergo urologic surgery, which is determined by a number of factors: increasing age of patients who undergo surgical treatment, along with elderly (61-74 years) and senile (75-90 years), often applied to long-lived patients (90 years and over); most patients with associated diseases are often subjected to surgical treatment i.e. lung diseases, chronic hypertensive disease, ischemic disease of the heart, anterior myocardial infarction with development of cardiosclerosis, disease of peripheral vessels, blood-vascular failure, consequences of impaired cerebral circulation, metabolic disorders such as diabetes, obesity, hormonal deficiency, drug intolerance [111].

Urethral trauma is ranked on the first place among the most male urogenital injuries [23,105,106]. One of the complications of severe urethral trauma, which leads to prolonged loss in work capacity and often to disability, is its narrowed scarring.

The increasing number of traumatic disorders of the urethra leads to the steady growth of number of patients with stricture scarring, in most countries [112,113]. Meanwhile, there is an increasing number of recurrent strictures, which proves the low efficiency of surgical treatment methods [23, 106,114,113,115]. Native authors [116,117,118] investigated the efficacy of treatment methods in open urethral strictures, especially the posttraumatic [116,118] and analyzed the outcomes after an endourologic treatment of acquired urethral stricture, specifically iatrogenic and post inflammatory urethral stricture, the peculiarities of urodynamic exam findings in patients with primary and recurrent acquired urethral strictures [118].

Even if urethral strictures have a relatively small share in urological pathology (3.7 to 6%), the issue of their treatment refers to the most current situations in modern urology [119]. This is due to the large number of complications and high recurrence rate (10-50%), which often lead to social inadequacy of this category of patients [120]. One of the current problems of urology is the treatment of urethral strictures of different genesis, including postoperative strictures with different locations, following an adenomectomy [23,109].

The successful interventions in the urethra depend on the choice of optimal surgical method while taking into account the location, length and complication of stricture; the appropriate use of intervention techniques; the postoperative treatment of patient; the overall condition of the body; the presence of recurrent diseases and complications [23,114,115,120].

Patients with urethral strictures require a specialized and prolonged treatment. Surgery is a radical treatment method performed by means of open or endoscopic technique. The choice of a surgical method is based upon specific indications and contraindications, some of which are still considered controversial and largely discussed in related literature. As for example, the choice for optical urethrotomy in extended urethral strictures and its complete obliteration [23,34].

Until recently, the main methods of treatment of patients with urethral strictures were open and complex surgeries (i.e. urethroplasty, urethral reconstruction) as Holtsov-Marion, Solovov, Rusakov, Mikhailovsky etc. [23] most of which does not guarantee a full recovery. Unsatisfactory results of treatment in patients with urethral strictures are commonly met and reach up to 16-25% of cases. The open surgeries also include: different methods of anastomosis, urethral plastic surgery, displacement of grafts [23]. The efficiency rate of listed above treatment methods constitutes about 80-95% and are applied mainly in extended urethral strictures [25], and the overall rate of recurrence is about 5-20% [102,106]. Besides its traumatic and long rehabilitation period, the most common complications following open surgery are: postoperative suppuration, incidence of urinary fistulas, stricture recurrence, urethral obliteration, urinary incontinence. The following side effects of surgery of the urethra should be reported: shortage of penis, erectile dysfunction and impotence associated with inevitable trauma of muscles, vessels and nerve endings of the perineum during the intervention as well as urethral resection [82]. All this leads to social inadequacy or disability of this category of patients.

Recently, great importance is paid to the development and implementation of modern technologies, especially minimally invasive methods of treatment of urological diseases. Various endoscopic surgical methods are widely applied, which enable the efficient restoring of urethral permeability in the early follow-up period; endoscopic surgery is performed in urethral obliteration [89,121]. Currently, transurethral methods are widely used in treatment of this disorder, which are divided into cold knife urethrotomy, electroresection and laser urethrotomy. These include mainly internal visual urethrotomy; visual dilation of the stricture and insertion of the endoscope during transurethral intervention of lower urinary tract; Otis urethrotomy, transurethral resection of the urethral sclerotic scar tissue [89,122].

Endoscopic treatment methods include internal optical urethrotomy; urethral endoscopic disobliteration; combined endoscopic interventions, which present the following advantages: minimum operational trauma; minimal duration of intervention; no significant intra- and postoperative complications. A number of authors have extensive experience of endoscopic treatment of urethral strictures, which allowed them to avoid complex open procedures, in some cases [89,122].

A palliative method to restore the micturition is internal visual urethrotomy – a minimally invasive endoscopic method of treatment, which actually consists of an incision per-

formed on the narrowed portion of the urethra and stroma lumen by means of special instruments [120,123]; thereby a normal urethral lumen is obtained. This surgical technique is performed via a visual management, where intraurethral longitudinal incisions are made on the stenotic segment using an optical urethrotome [88,124]. The success rate of this surgical procedure is 30 – 40% within a year, whilst failures are considered secondary effects of this apparently simple endoscopic technique. The main purpose of this method is the cure, viz. obtaining a steady functional urethral lumen without a need for further investigation, therefore cases of strictures less than 1 cm will be selected, with moderate spongiosal- fibrous process, located at level of bulbar urethra.

Visual urethrotomy enables to perform a selective and precise incision, which prevents the emergence of many complications. The disadvantages of this method are: the prolonged follow-up period of patients, whereas its success depends on the intellectual level and readiness of the patient [125,103,126].

In order to improve a relatively modest success rate (up to 30-40%) on a long- term period, urethral stents (prostheses) can also be placed endoscopically at the level of stenotic urethral segment aiming to maintain the proper function of the urethral lumen. Except for its high price, this method does not decrease the recurrence rate of stenosis, and it is extremely difficult to treat a prosthetic and recurrent stricture.

During recent years, there have appeared a series of scientific works regarding the benefits of this method (visual internal urethrotomy) [25,110,126,127] in the treatment of post-traumatic urethral strictures [128] and postinflammatory ones [119,128]; as about the treatment of postoperative urethral strictures the results are more diverse and specific [129], according to reported data. Perhaps this is due to some characteristics of stricture location following an adenomectomy, as a rule, placed in the proximal segment of the urethra and on the bladder neck region, or after a urethroplasty [130], as well as to the difficulties of surgical access, a fact which complicates considerably the choice for surgical technique. Finally, the main idea of all these communications was that visual internal urethrotomy is an effective method of treatment of urethral stricture, which is characterized by less traumatic and better results. IVO is the surgical approach selected in less expanded urethral strictures; it may prevent the patient from undergoing repeated open plastic surgeries or reduce post urethroplasty recurrence [126,131]. If associated with appropriate anti-scar treatment during the postoperative period, it may significantly reduce the number of recurrence and improve treatment outcomes [128,132,134].

In specialized literature, there is no unanimous opinion regarding the indications for IVO. M. Trapeznikova et al. [52,136] thinks that this method can be applied to all strictures, regardless of their etiology, level of manifestation or impairment. The purpose of these procedures is the formation of the tunnel, as well as localization of a preserved portion of the urethra. Some authors [134], made attempts to

use retrograde visual urethrotomy in treatment of urethral obliteration, but due to high trauma rate and probability of false paths onset (false urethra), this method has not been widely applied in practice. Surgical intervention is indicated only in cases of short urethral deficiency, the bladder neck is competent and there is a minimum displacement of the prostate and bulbar proximal urethra [119]. Although, the restoring of continuity is somewhat simple and potency is not affected by the procedure, still urethral dilatation, repeated visual urethrotomy and transurethral resection of stricture are very commonly used in 82% of patients. Most repeated urethrotomies are made in the first-year of follow-up. It should be noted that in case if initial urethrotomy fails, alternative methods of treatment are applied, since repeated urethrotomy leads to only temporary improvement. Besides a false urethral path, a rectal perforation may often occur.

According to bibliographic data, recurrences following IVO occur in about 80% of cases; after Frank M. [41], V. Bazaev, S. Urenkov [82] – in 15-50%, and according to A.M. Naude [124] Giannakopoulos, et al. [135] – in 50% of patients. A number of authors [126; 136] reported about the high incidence of remote recurrence in treatment of patients with urethral stricture of inflammatory etiology by means of endoscopic urethrotomy.

Some authors [119] convincingly demonstrate that visual internal urethrotomy is an operation of urethral stricture selection and the treatment of each patient must be initiated with visual urethrotomy. VIU is now a simple, accessible and technically easy to perform procedure. But this intervention can not be considered pathogenically argued. Urethrotomy is a palliative surgery [122]. Any induced and unstitched wound, heals by scarring by *secundam* and formation of scars, therefore stricture recurrence is inevitable.

Therefore it is not surprising that the supporters of visual internal urethrotomy recommend the mandatory long-time survey, sometimes for life, while admitting however multiple repeated urethrotomies. According to several authors [122], the strictures recurrence in visual internal urethrotomy ranges from 30.8 to 58.2%. D. Pushkari et al. [120,137] reported stricture recurrence after internal visual urethrotomy in 20-80% of patients.

Additionally, cold knife urethrotomy and diathermo-coagulation are used in stricture incision along with laser irradiation has been positively assessed by several authors [72,138]. In opinion of I. Karpuhin et al. [119]; A. Martov et al. 103; 110 V. Voinescu et al. [139]; C. Moldoveanu [86]; M. Lucan et al. [140], urethral strictures laser therapy is an alternative approach to classical cold knife urethrotomy. The best results are obtained in non-recurrent strictures of less than 1 cm long. In cases of recurrent strictures longer than 1 cm long, the alternative to open surgery should be considered. In severe cases with multiple recurrences, the method does not provide satisfactory results, whereas urethroplasty is considered the best indication for these patients [139,141].

Thus, according to some authors [58,103,142], the use of the holmium laser in the treatment of extended urethral

strictures showed good results in 80.9% of cases, whilst the recurrence rate of the disease being of 5.5%; while in the treatment of complete urethral obliteration following repeated surgical interventions, this method of treatment may be the only alternative procedure. The advantages of laser surgery, compared to other methods of correction of urethral strictures, are: the formation of soft, small sized scars (mild impaired elasticity), and a reduced activity of fibroblasts during epithelialization. Moreover, bloodless dissection of the laser has the advantage to limit the use of the urethral catheter in the postoperative period.

Surgical treatment methods of urethral strictures do solve out satisfactorily all the problems related to this disease. Thus, the open surgical treatment outcomes still remain low: recurrence of urethral strictures are found in 5 to 37.4% of cases, impotence development in 34.9 to 80.0%, shortening of the penis in 24% of patients, operative wound suppuration from 10.4 to 16.8% of the cases [53,102,122].

Endourological methods of treatment in urethral strictures, in many cases, replaced complex open surgeries, thus significantly reducing the rate of postoperative complication [105]. However, the recurrence rate of urethral strictures after a primary endoscopic recovery of urethra (visual internal urethrotomy) is 8-23% [119,128]. Endoscopic reconstruction efficiency remains low at 30-50% [23], which leads to incapacity to work, disability and social inadequacy of the patient.

Despite the reported diversity of minimally invasive procedures, the results still remain unsatisfactory in treatment of long strictures and somewhat doubtful for medium length of stricture. Thus, for example, the use of electroresection may generate a deeper scar process, due to a serious electrical injury of the peristrictural tissue, which does not guarantee getting good results [141,143]. There is also an opinion that urethroplasty is indicated in the treatment of long strictures, complicated by false channels, or in complete urethral obliteration [141,144].

Low efficiency of endoscopic correction is, in fact, related to inadequate radicalism of resection of the sclerotic urethral tissue, inadequate management of pre- and postoperative period, the presence of microcirculatory and trophic disorders in the region of the urethral stricture [25].

Therefore, besides the surgical procedures, the pathogenetic therapy must be applied in the treatment of urethral strictures, in order to eliminate edema, inflammation and improve the trophic of the urethral tissue [53,131].

Hitherto, native and foreign researchers have proposed a series of conservative and surgical methods of treatment of urethral strictures in men [109,116,133,145]. However, the indicators of treatment efficiency remain at a fairly low level. Thus, postoperative stricture recurrence is reported in 30-75% of cases, which requires repeated surgical interventions and has an extremely negative impact on quality of life. Additionally, the irrational use of surgical possibilities leads to an increased number of patients with extended urethral strictures, who may need reconstructive surgery [88].

Therefore, treatment of urethral strictures is one of the most acute and contradictory issues in modern urologic surgery. Specialized literature describes the comparative characteristics of different methods of treatment related to this disorder. It is important to note that outcomes in the treatment of urethral strictures, performed by means of the same method, vary from author to author. Yet, there is no unique opinion regarding the optimal choice in surgical treatment of scarred urethral stricture.

Data related to the recurrence and complication rate, surgical methods efficiency, as well as the role of incision and laser coagulation of strictures are quite contradictory [28,119,144]. Also, there have not been set strict guidelines for the use of laser, depending on the size and location of the scarred stricture; there have not been studied the results of late treatment of strictures; and, most importantly, the recurrence rate after procedures performed by means of surgical laser [123,139]. Despite many studies and published scientific researches, which contributed to the improvement of methods of diagnosis and treatment of urethral strictures in men, there are a number of issues which still require being revised [146].

Thus, there is no single solution of this problem regarding the treatment of urethral stricture and obliteration. After hundreds of years, there are still three directions in solving it viz. endoscopic correction, surgical treatment and electrode dilation of the urethra both as independent method or additional to the previous ones. It is currently problematic to create a single perfect method in treatment of both stricture and obliteration of the urethra. Accurate indications for a certain method, in order to restore the urethral permeability, depending on location and length, as well as to improve methods of treatment, would reduce the invasive risks without decreasing the efficiency and may lead to success in each case.

A special place in clinical practice is reported to treatment of postoperative urethral strictures and obliteration of elderly and senile patients [92]. Based on the statistical analysis in recent years, we can conclude indirectly about the number of patients of a certain age. We can mention that about 50% of patients with urethral stricture are over 60. Moreover, due to different associated diseases, prolonged urinary infections after previous interventions involving the urinary tract, this category of patients shows less positive outcomes to any reconstructive intervention. In addition to that, this group of people presents higher complication and postoperative mortality rates. However, there are few rehabilitation activities in people of advanced and senile age, depending on the method applied and postoperative urethral stricture treatment.

Hence, the development of endoscopic surgery has provided new, minimally invasive methods in treatment of infravesical obstruction of different genesis. The choice of method in treatment of infravesical obstruction is determined mainly by two mutually exclusive circumstances: the risk of surgical intervention and restoration of micturition. Often, the selected method must be less offensive compared to the results.

Laser surgery, plasmakinetic, transurethral resection and their combination present a number of advantages compared to open conservative interventions viz. fewer complications, the possibility to apply these methods to patients with severe associated diseases, short-term hospital stay, economic efficiency.

However, despite the listed above advantages, endoscopic interventions, like any other surgeries are associated with complications in 15-30% of cases [63,149,150].

Native and international scientific sources describe actually the method and technique of endoscopic treatment for infravesical obstruction, while there are fewer studies regarding its complications. One of the perspective directions that contribute to improvement of the treatment quality for infravesical obstruction is the combination of these methods (TURP and Ho Laser; TURP and Vaporization). According to their opinion, in this case, the benefits of one method will compensate the disadvantages for another. Nevertheless, the associated application of minimally invasive procedures does not prevent the incidence of various complications, which are less studied nowadays [119,129,147,148].

The most works of recent years, little or insufficiently describe different types of complications after endoscopic interventions, as well as their criteria of prognosis.

Hitherto, the problem of surgical treatment of infravesical obstruction in endourology has not been highlighted or synthesized by any helpful studies from the Republic of Moldova.

Conclusions

The literature analysis showed that prostate adenoma, sclerosis of bladder neck and prostate, urethral stricture and obliteration can be associated to the disorders that show signs of IVO, characterized by impairment of bladder emptying, difficulties in micturition, retention of the urine and other types of dysuria.

IVO of urinary tract is a polyetiologic and pathological process, characterized by symptoms of lower urinary tract, which despite profound and multilateral study, still remains a serious problem of modern urology. It is a major health and social problem due to its high occurrence in working aged patients, as well as limited preventive measures and progression to severe and fatal complications if no proper treatment is applied.

Recurrence of IVO is the most severe and late postoperative complication due to the scarring process in the urethra and vesico-urethral segment (strictures and obliterations) and the continuous growth of adenomatous tissue mass (real or false BPH recurrence).

The latest results in this field, as well as the scientific and technical progress have changed considerably the traditional methods used in the treatment of many urological diseases causing infravesical obstruction. Modern urology provides plenty of treatment methods for these diseases, particularly, new endoscopic approaches (transurethral and plasmakinetic vaporization, laser Holmium enucleation) and a variety of

their combinations, which display both advantages and disadvantages and compete with traditional ones, considered as basic methods over the past few decades; thus, creating opportunities for an individual approach to ensure a final success of a medical intervention.

A deeper and more complex comparative study is required in terms of application and effectiveness of the techniques and endoscopic transurethral approaches used in the treatment of disorders manifested by IVO, such as BPH, BNS and PS, US and UO, aiming to broaden the range of indications for the implementation of new minimally invasive transurethral methods into practice.

Optimization of problems, related to endoscopic treatment of infravesical obstructive disorders, will help reduce unwanted symptoms of lower urinary tract, fight off complications, including prevention of IVO recurrences, facilitate recovery and improve patient's quality of life after treatment.

References

1. Policastro MA. Urinary obstruction treatment and management. Available at <http://www.emedicine.medscape.com/article/778456-treatment>. Accessed August 11, 2011.
2. Gorilovskiy L.M. Epidemiologiya i faktory riska razvitiya dobrokachestvennoy giperplazii predstatelnoy zhelezy. V kn.: Dobrokachestvennaya giperplaziya predstatelnoy zhelezy. Pod red. akad. RAMN H.A. Lopatkina. M., 1999, s. 12-20.
3. US Renal Data System USRDS 2013 Annual Data Report: Atlas of chronic kidney disease and end-stage renal disease in The United States. Vol. 2, National Institutes of Health, National Institute of Diabetes and Digestive and Kidney Diseases: Bethesda, MD, USA.
4. Abrams P. et al. International Scientific Committee. Evaluation and treatment of lower urinary tract symptoms in older men. *J. Urol.* 2009 Apr, 181(4), p. 1779-1787.
5. Solovov D.A. Mehanizmy razvitiya rasstroystv urodinamiki i narusheniya funktsii pochk na raznykh stadiyakh infravezikalnoy obstruktsii mochevidelitelnoy sistemy. Avtoref. dissertatsii kand. med. nauk. M., 2010.
6. Abdi H. et al. Imaging in benign prostatic hyperplasia: what is new? *Curr Opin Urol.* 2013 Jan; 23(1):11-16.
7. Al-Shukri S.H. i dr. Urodinamicheskie issledovaniya v diagnostike infravezikalnoy obstruktsii u muzhchin. // *Urol. i nefrol.* 1998. # 6. s. 27-29.
8. Souverein P. et al. Drug treatment of BPH and hospital admission for BPH-related surgery. *Eur. Urol.* 2003, 43, p. 528-534.
9. Sergienko N. F. i dr. Oshibki i oslozhneniya transuretralnoy rezektsii predstatelnoy zhelezy pri adenome (2-e izdanie) Binom, Labor. znaniy. 2013.
10. Montorsi F. et al. Holmium laser enucleation versus transurethral resection of the prostate: results from a 2-center, prospective, randomized trial in patients with obstructive benign prostatic hyperplasia. *J. Urol.* 2007, vol. 172, Nr. 5, p. 1926-1929.
11. Rajesh Taneja. Soft Tissue Applications of Holmium Laser in Urology. *JIMSA July-September 2011*, vol. 24, № 3, p. 135-136.
12. Lopatkin N.A. Oslozhneniya adenomektomii i TUR predstatelnoy zhelezy. V kn.: Dobrokachestvennaya giperplaziya predstatelnoy zhelezy. M., 1999, s. 210-215.
13. Sevryukov F.A. Sorokin D.A. i dr. Transuretralnaya enukleatsiya prostaty – metod vyibora pri operativnom lechenii DGPZh bolshogo ob'yoma. Materialy kongressa, Rostov-na-Donu, 13-15 iyunya 2012, s. 69-70.
14. Rosette J.J.M.C.H. et al. EAU Guidelines on Benign Prostatic Hyperplasia (BPH). *Eur Urol* 2001; (40): 256-263.
15. Alyaev Yu.G., Vinarov A.Z., Lokshin K.L. i dr. Vyibor metoda lecheniya bolnykh giperplaziy predstatelnoy zhelezy: monografiya. M., 2005, s. 176
16. Karpin S. P. Sochetanie endohirurgicheskikh i fizioterapevticheskikh metodov v lechenii bolnykh so strikturami zadnego otdela uretry. Avt. dissertatsii. M., 2004.
17. Martov A.G. i dr. Intraoperatsionnyie urologicheskie oslozhneniya transuretralnykh elektrohirurgicheskikh vmeshatelstv po povodu adenomyi predstatelnoy zhelezy. Materialy I Rossiyskogo kongr. po endourologii. M., 2008, s. 66-67.
18. Martov A.G., Merinov D.S. i dr. Posleoperatsionnyie urologicheskie oslozhneniya transuretralnykh elektrohirurgicheskikh vmeshatelstv na predstatelnoy zheleze po povodu adenomyi. *Urologiya.* 2006, c. 25-31.
19. Neill M.G. et al. Randomized trial comparing holmium laser enucleation of prostate with plasmakinetic enucleation of prostate for treatment of BPH. *Urology*, 2006, 68:1020-4.
20. Schroeck F.R., Hollingsworth J.M., Kaufman S.R. Population based trends in the surgical treatment of benign prostatic hyperplasia. *J. Urol.* 2012 Nov, vol. 188 (5), p. 1837-1841.
21. Rosette I., Perachino M., Thomas D. Rekomendatsii po diagnostike i lecheniyu dobrokachestvennoy giperplazii predstatelnoy zhelezy (Rekomendatsii EAU, Zheneva, 2001). *Perevod Apolihina O.I. i dr. // Urologiya*, 2003. # 5, c. 4-71.
22. McConnell J.D. et al. Clinical Practice Guideline: Benign Prostatic Hyperplasia: Diagnosis and Treatment. Rockville, Maryland: Agency for Health Care Policy and Research, 1994. Publication Nr. 94 – 0582.
23. Kogan M.I. Sovremennyye metody lecheniya striktury uretry // Materialy plenuma pravleniya Rossiyskogo obschestva urologov. Ekaterinburg, 2006. c. 271-281.
24. Kuo R.L. et al. Holmium laser enucleation of the prostate (HoLEP): a technical update. *World J. Surg. Oncol.* 2003, vol. 1, Nr. 1, p. 6.
25. Kan Ya.D., Tedeev V.V., Kochetov M.M. Analiz otdalennykh oslozhneniy transuretralnoy rezektsii prostaty (TURP). Materialy I Rossiyskogo kongressa po endourologii. M., 4-6 iyunya 2008, s. 52-53.
26. Pushkar D.Yu. Rasner P.I. Narushenie mocheispuskaniya i seksualnoy funktsii u bolnykh dobrokachestvennoy giperplaziy predstatelnoy zhelezy. *Vrach.* 2003, # 6, s. 34-38.
27. Sivkov A.V. i dr. Adenoma predstatelnoy zhelezy i giperaktivnyiy mochevoy puzyr: otsenka simptomov i vyibor terapii // *Urologiya: nauchno-prakticheskii zhurnal.* 2009, # 2, c. 78-84.
28. Belyaev A.I. i dr. Preimuschestva transuretralnoy rezektsii predstatelnoy zhelezy pozhilogo i starchykh vozrasta. *Mater. I Ross. kongp. po endourol.* M., 2008, s. 26-27.
29. Sevryukov F.A. Semenychev D.V. i dr. Sravnitel'naya otsenka monopolyarnoy i biopolyarnoy rezektsii pri lechenii DGPZh. Materialy kongressa, Rostov-na-Donu, 13-15 iyunya 2012, s. 67-69.
30. Shkodkin S., Idashkin Yu., Fentisov V. Opyit primeneniya bipolyarnoy rezektsii prostaty. *Mater. I Rocs. kongr. po endourol.* M., 2008, s. 115-116.
31. Petrov S.B. Vyibor ratsionalnogo endoskopicheskogo metoda lecheniya bolnykh dobrokachestvennoy giperplaziy predstatelnoy zhelezy. Avtoref. dis. dokt. med. nauk. SPb., 1998. s. 37.
32. Patel A. et al. Transurethral electrovaporization and vapour-resection of the prostate: an appraisal of possible electro-surgical alternatives to regular loop resection. *BJU Int.* 2000 Jan; 85(2):202-10.
33. Kirilov S. A. Sravnitel'naya otsenka razlichnykh modifikatsiy transuretralnykh rezektsiy pri lechenii dobrokachestvennoy giperplazii prostaty. Avt. diss. kand. med. nauk, 2004.
34. Abrahamov B., Golubkin. E., Lyisenko. A. Opyit endoskopicheskogo lecheniya dobrokachestvennoy giperplazii predstatelnoy zhelezy. Materialy I Rosciyskogo kongressa po endourologii. Moskva, iyunya 2008, s. 13-14
35. Seki N. et al. Holmium laser enucleation for prostatic adenoma: analysis of learning curve over the course of 70 consecutive cases. *J.Urol.* 2003 Nov; 170(5):1847-50.
36. Steg A. Transurethral versus open prostatectomy: do these procedures apply to the same patients and the same disease? *Eur Urol.* 1991; 20(3):173-4.

37. Roehrborn C.G. et al. Effect of dutasteride on prostate biopsy rates and the diagnosis of prostate cancer in men with lower urinary tract symptoms and enlarged prostates in the Combination of Avodart and Tamsulosin trial. *Eur Urol.* 2011 Feb; 59(2):244-9.
38. Zabrodina N.B. Sravnitelnyy analiz effektivnosti otkrytoy chrespuzyrnoy prostatektomii i transuretralnoy elektrozeksii u bolnykh dobrokachestvennoy giperplazii prostaty. Avtoref. diss. kand. med. nauk. M., 2001, s. 24.
39. Bratchikov O. I., Shumakova E. A., Tistsov D. A. Profilaktika posleoperatsionnykh oslozhneniy prostatektomii u bolnykh giperplaziey predstatelnoy zhelezy. // *Matepialy 10 Rossiyskogo sezda urologov.* M., 2002. c. 77-78.
40. Gorilovskiy M.L. Transuretralnaya endoskopicheskaya intsiyaziya v lechenii bolnykh dobrokachestvennoy giperplaziey predstatelnoy zhelezy i sklerozom sheyki mochevogo puzyrya. *Urologiya i nefrologiya*, 1996. # 3, s. 47-51.
41. Sitdyikov E.N., Zubkov A.Yu., Zubkov E.A. Endohirurgicheskiy sposob (metod) profilaktiki strikturyi uretryi posle transvezikalnoy adenomektomii. *Mater. I Rocsiyskogo kongressa po endourologii.* M., 4-6 iyunya 2008, c. 99.
42. Semenychev D.V. i dr. Opyit primeneniya bipolyarnoy vaporezeksii predstatelnoy zhelezy (TUVRB) v lechenii DGPZh. *Eksper. i klin. urologiya*, 2014, # 2, s. 49-52.
43. Tiktinskiy O.L. Hirurgicheskoe lechenie adenomyi predstatelnoy zhelezy i posleoperatsionnykh oslozhneniy // 8-y Vseross. sezda urologov: Tez. dokl. Sverdlovsk, 1998. c. 229-236.
44. Sitdyikov E.N., Zubkov A.Yu., Zubkov E.A. Vybor metoda operativnogo lecheniya bolnykh s adenomoy predstatelnoy zhelezy. *Kazanskiy meditsinskiy zhurnal*, 2004, # 5, c. 356-359.
45. Alyaev Yu.G. i dr. Faktoryi riska razvitiya striktur peredney uretryi posle transuretralnoy rezeksii predstatelnoy zhelezy. *Urologiya*, 2015, # 1.
46. Vavassori I. et al. Three-Year Outcome following Holmium Laser Enucleation of the Prostate Combined with Mechanical Morcellation in 330 Consecutive Patients. *European urology* 53 (2008) 599-606.
47. Djavan B. Treatment & Management Benign prostatic hyperplasia: Current clinical practice. *Prim Care.* 01 Sep2010, 37(3), p. 583-597.
48. Kabalin J.N. Invasive therapies for benign prostatic hyperplasia. *Monographs in Urology.* 1997, vol. 18, N 2, p. 19-24.
49. Tsarichenko D.G. Profilaktika, diagnostika i lechenie oslozhneniy transuretralnogo elektrovyparivaniya dobrokachestvennoy giperplazii predstatelnoy zhelezy: dissertatsiya kand. med. nauk. M., 2000, s. 223.
50. Ahunzyanov M. i dr. Infravezikalnaya obstruktsiya, kak prichina narusheniya akta moche-ispukaniya u malchikov. *Praktika hirurgii detskogo vozrasta.* Kazan, 2001. c. 18-24.
51. Gorlenko V.N. i dr. Oslozhneniya transuretralnoy rezeksii predstatelnoy zhelezy po povodu eyo giperplazii i puti ih ustraneniya. *Materialy XI sezda urologov Rossii.* M., 2007, s. 435-436.
52. Trapeznikova M.F., Bazaev V.V., Tibilov A.S. Patogenez retsidivnoy infravezikalnoy obstruktsii u bolnykh posle adenomektomii i TUR prostaty // *Matep. 2-oy Vserossiyskoy konferentsii „Muzhskoe zdorov’e”.* M., 2005. c. 134.
53. Martov A.G. i dr. Sindrom vodnoy intoksikatsii organizma (TUR-sindrom). *Urologiya*, 1999, # 4, s. 44-49.
54. Merinov D.S. i dr. Opyit transuretralnoy lazernoy golmievoy i bipolyarnoy enukleatsii adenomyi prostaty bolshih razmerov. IV Ross. kongress po endourologii i novym tehnologiyam. Batumi, 2014, s. 44-46.
55. Schroder F., Altwein I. Benign Prostatic Hyperplasia. A Diagnosis and Treatment Primer. Oxford, 1992. – P. 31-50.
56. Sivkov A.V., Tolstova S.S. Urodynamiccheskie issledovaniya v diagnostike obstruktsii pri dobrokachestvennoy giperplazii predstatelnoy zhelezy. *Dobrokachestvennaya giperplaziya predstatelnoy zhelezy.* Pod red. N.A. Lopatkina. M., 1999. c. 70-83.
57. Bush I.M. et al. The evolution of transurethral vaporization of the prostate (TVP): A 120-year history of progress. *J. Urol.* 1996, vol. 155, p. 445.
58. Mazo E.B., Chepurov A.K. i dr. Diagnostika «klappannogo efekta» dobrokachestvennoy giperplazii prostaty za schet sredney doli i vybor metoda eyo lecheniya // *Urologiya i nefrologiya.* 1998, # 3. c. 8-11.
59. Martov A. G., Ergakov D.V. i dr. Transuretralnaya elektroenukleatsiya dobrokachestvennoy giperplazii predstatelnoy zhelezy. *Urologiya* # 5, 2014.
60. Apolihin O.I. Termalnye metody v lechenii dobrokachestvennoy giperplazii predstatelnoy zhelezy. *Dobrokachestvennaya giperplaziya predstatelnoy zhelezy (pod red. N.A. Lopatkina).* Moskva, 1997, s. 51-61.
61. Mazo E.B., Chepurov A.K., Kozdoba L.S. Golmievyiy lazer v lechenii urologicheskikh zabolevaniy: metod. rekom. MZ RF. Tver, 2003, s. 48.
62. Aho T. F. et al. Holmium laser bladder neck incision versus Ho laser enucleation of the prostates less than 40 grams a randomized trial. *J. Urol.* 2005, vol. 174, Nr. 1, p. 210-214.
63. Elzayat E. et al. Holmium laser enucleation of the prostate in patients on anticoagulant therapy or with bleeding disorders. *J.Urol.* 2006, vol. 175, Nr. 4, p. 1428-1432.
64. Gilling P. J. et al. Holmium Laser Enucleation of the Prostate: Results at 6 Years. *European Urology.* 2008, 53 (4), p. 744-749.
65. Kuntz R.M., Lehrich K., Ahyai S.A. Holmium laser enucleation of the prostate versus open prostatectomy for prostates greater than 100 grams: 5-year follow-up results of a randomised clinical trial. *Eur Urol* 2008; 53:160-8.
66. Geavlete B. et al. Bipolar plasma vaporization versus standard transurethral resection in secondary bladder neck sclerosis: a prospective, medium-term, randomized comparison. *Ther Adv Urol.* 2013 Apr; 5(2):75-83.
67. Anup Kumar et al. A prospective randomized comparative study of monopolar and bipolar transurethral resection of the prostate and photoselective vaporization of the prostate in patients who present with benign prostatic obstruction: a single center experience. *Journal of endourology*, 18 Dec. 2013.
68. Krapivin A.A. i dr. Sravnitelnaya otsenka vliyaniya razlichnykh metodov transuretralnoy rezeksii na sistemu gemostaza v posleoperatsionnom periode. IV Ross. kongress po endourologii i novym tehnologiyam. Batumi, 2014, s. 37-38.
69. Stewart S. C. et al. Electrovaporization of the prostate: New technique for treatment of benign prostatic hyperplasia. *J. Endourol.* 1995, vol. 9, p. 413.
70. Neymark B.A., Torbik D.V. Metod «bipolyarnaya plazmokinicheskaya transuretralnaya rezeksiya prostaty» v lechenii bolnykh dobrokachestvennoy giperplaziey predstatelnoy zhelezy bolshih razmerov. IV Rossiyskiy kongress po endourologii i novym tehnologiyam. Batumi, 2014, s. 46-47.
71. Dincel C. et al. Plasma Kinetic vaporization of the prostate: clinical evaluation of a new tehnieue. *J.Endourol.* 2004, vol. 18, Nr. 3, p. 293-298.
72. Razaghi M. R. et al. Direct vision internal urethrotomy with application of holmium: YAG laser: *J Lasers Med Sci* 2011; 2(3):126-8.
73. Aboyan I.A. i dr. Golmievaya lazernaya enukleatsiya pri giperplazii predstatelnoy zhelezy. Odnotsentrovoy opyt. IV Rossiyskiy kongress po endourologii i novym tehnologiyam. Batumi, 2014, s. 19-20.
74. Bazhenov I.V. i dr. Perviy opyt primeneniya diodnogo lazera v kombinatsii s bipolyarnoy TUR prostaty pri lechenii patsientov s DGBZh. IV Ross. kongress po endourologii i novym tehnologiyam. Batumi, 2014, s. 29-31..
75. Wilson L.C. et al. A randomised trial comparing holmium laser enucleation versus trans-urethral resection in the treatment of prostates larger than 40 grams: results at 2 years. *Eur Urol* 2006; 50:569-73.
76. Kuntz R.M., Lehrich K. Transurethral holmium laser enucleation versus transvesical open enucleation for prostate adenoma greater than 100 gm: a randomized prospective trial of 120 patiens. *J. Urol.* 2002, vol. 168, Nr. 4, p. 1465-1469.
77. Kuo R.L. et al. Holmium Laser enucleation of prostate (HoLEP): the Methodist Hospital experience with greater than 75 grams enucleations. *J Urol* 2003; 170: 149-52.
78. Martov A.G., Kamalov A.A. Maloinvazivnyie endoskopicheskie metody lecheniya dobrokachestvennoy giperplazii predstatelnoy zhelezy. V kn.: «Dobrokachestvennaya giperplaziya predstatelnoy zhelezy». M., 1999, s. 210-212.

79. Toohar R. et al. A systematic review of holmium laser prostatectomy for benign prostatic hyperplasia. *J. Urol.* 2004, vol. 171, Nr. 5, p. 1773-1781.
80. Kamalov A.A., Osmolovskiy B.E., Ohobotov D.A. Pervyy opyt vapoenukleatsii adenomyi prostaty s ispolzovaniem lazera. IV Rossiyskiy kongress po endourologii i novym teh. Batumi, 2014, s. 35-36.
81. Lopatkin N.A., Pugachev A.G. Infravezikalnaya obstruktsiya i PMR. V: Puzyirno-mochetochnikoviy refluks / Rukovodstvo. M.: Meditsina, 1990. c. 108-162.
82. Bazaev V.V., Urenkov S.B. Endoskopicheskoe lechenie zadney uretry i sheyki mochevogo puzyrya. Otdalennyye rezultaty. Materialy I Rossiyskogo kongressa po endourologii. M., 2008, s. 23-25.
83. Lee Y.H., Chiu A.W., Huang J.K. Comprehensive study of bladder neck contracture after transurethral resection of prostate. *J. Urology.* 2004; 10.083, 498-503.
84. Mebust W.K. Transurethral surgery. In: Campbell's Urology, 7th edn. Walsh P. C. et al. (eds). St. Louis, USA: W.B. Saunders, 1997, p. 1511-1558.
85. Nashivochnikova N.A. Patogenez skleroza sheyki mochevogo puzyrya. Osobennosti profilaktiki v posleoperatsionnyim periode. Avtoref. kand. med. nauk. M., 2012.
86. Moldoveanu C. "Tips and tricks" in secondary bladder neck sclerosis' bipolar plasma vaporization approach. *Journal of Medicine and Life.* 2013, V. 6, Issue 3, p. 272-277.
87. Geavlete B. Continuous plasma vaporisation. A new step forward in BPH endoscopic treatment. *European Urology Today*, June/July 2012, 24(3):31.
88. Mundy A.R. Adjuncts to visual internal urethrotomy to reduce the recurrence rate of anterior urethral strictures // *Eur. Urol.* 2007. vol. 51, № 4, p. 1089-1092.
89. Martov A.G., Kamalov A.A., Guschin B.L. Endoskopicheskoe lechenie obliteratsii uretry i sheyki mochevogo puzyrya. Posobie dlya vrachev. M., 2001, s. 174-175.
90. Pereverzev A.S. Sovremennyye napravleniya v diagnostike i lechenii dobrokachestvennoy obstruktsii predstatelnoy zhelezyi // *Zdorove muzhchiny*, 2004. # 1(8) – s. 87-93
91. Murat Alran et al. Histological response to injected glutaraldehyde cross-linked bovine collagen based implant in a rat model // *Bio Med-Central Urol.* 2006, p. 3-6.
92. Gorilovskiy L.M., Dobrohotov M.M. Transuretralnaya rezektsiya v lechenii skleroza predstatelnoy zhelezyi u bolnykh pozhilogo i starcheskogo vozrasta. Materialy XI sezda urologov Rossii. M., 2007, s. 436-437.
93. Bach T. et al. Bladder neck incision using a 70 W 2 micron continuous wave laser (RevoLix). *World J Urol.* 2007; Jun. 25(3):263-7.
94. Geavlete B. et al. Transurethral resection (TUR) in saline plasma vaporization of the prostate vs standard TUR of the prostate: 'the better choice' in benign prostatic hyperplasia? *BJU Int.* 2010 Dec; 106(11):1695-9.
95. Shkuratov S.I. Nekotorye aspekty lecheniya infravezikalnoy obstruktsii // *Mat. nauchn. praktich. konf. Novosibirsk*, 1999. c. 150-152.
96. Farzaneh Shariaghadas et al. Efficacy of Transurethral Bladder Neck Incision with 2-Micron Continuous Wave Laser (RevoLix) for the Management of Bladder Outlet Stricture. 791 vol. 10 No. 1, Winter 2013, *Urology journal*.
97. Yatsenko O.K. Diagnostika i lechenie hronicheskogo abakterialnogo prostatita: Avtoref. diss. kand. med. nauk. SPb., 1996. s. 21.
98. Irani J., Levillain P. et al. Inflammation in benign prostatic hyperplasia: correlation with prostate specific antigen value. *J Urol.* 1997; 157:1301-1303.
99. Sciarra A. Lower urinary tract symptoms (LUTS) and sexual dysfunction (SD): new targets for new combination therapies? *Eur Urol.* 2007 Jun; 51(6):1485-7.
100. Bazaev V.V., Morozov A.P. Oslozhneniya endoskopicheskikh elektrohirurgicheskikh metodov lecheniya dobrokachestvennoy giperplazii prostaty. Materialy X Rossiyskogo sezda urologov: M., 2002. c. 74-75.
101. Gomberg V.G. Transuretralnaya lazernaya koagulyatsiya pri dobrokachestvennoy giperplazii predstatelnoy zhelezyi: Avtoref. dic. kand. med. nauk. SPb., 1997. c. 16.
102. Gorelov S.I., Kagan O.F. Lazernaya endoskopicheskaya hirurgiya retsidivnykh striktur zadney uretry. Materialy I Rossiyskogo kongressa po endourologii. M., 4-6 iyunya 2008, s. 36.
103. Martov A.G., Fahredinov G.A., Yarovoy S.Yu. Goltievaya lazernaya uretrotomiya v lechenii striktur mocheispuskatel'nogo kanala. Trudy II Rossiyskogo kongressa po endourologii i novym tehnologiyam. M., 2010, c. 158-159.
104. Abrahamov B., Golubkin E. i dr. Preimushchestva endoskopicheskogo lecheniya striktur uretry. Mater. I Ross. kongr. po endourologii. Moskva, 2008, s. 12-13.
105. Dyusyubaev A.A., Kovalev S.V. Endoskopicheskie operatsii pri strikturakh i obliteratsiyah uretry. Materialy I Rossiyskogo kongressa po endourologii. M., 4-6 iyunya 2008, s. 42.
106. Kazihinurov R.A. Optimizatsiya rezultatov hirurgicheskogo lecheniya protyazhennykh striktur uretry (kliniko-eksperim. issledovanie). Avtoref. diss. kand. med. nauk. M., 2009.
107. Frank M. A. Endoskopicheskoe lechenie posleoperatsionnykh striktur uretry u muzhchin pozhilogo i starcheskogo vozrasta. Avtor. diss. med. nauk. M., 2004.
108. Bazaev V.V. Endoskopicheskoe lechenie obliteratsiy zadney uretry i sheyki mochevogo puzyrya u muzhchin. Diss. dok. med. nauk. M. 2002. c. 230.
109. Rusakov V.I. Hirurgiya mocheispuskatel'nogo kanala. Rostov-na-Donu: Feniks, 1998.
110. Martov A.G., Fahredinov G.A., Ergakov D.V. Endoskopicheskie metody lecheniya striktur uretry. Izbrannyye lektsii po urologii. Pod redaktsiyey N.A. Lopatkina, A.G. Martova. M., «MIA», 2008, g. 38, c. 488-500.
111. Apolihin O.I. i dr. Analiz urologicheskoy zabolevaemosti v Rossiyskoy Federatsii v 2002-2009 godakh po dannym ofitsialnoy statistiki. Eksperimentalnaya i klinicheskaya urologiya. 2011, # 1, s. 4-10.
112. Al-Ali M., Al-Shukry M. Endoscopic repair in 154 cases of urethral occlusion: the promise of guided optical urethral reconstruction. In *J. Urol.* 1997. 157:129-131.
113. Brandes S. Initial management of anterior and posterior urethral injuries. In *Urol. Clin. North. Am.* 2008 Feb;33(1):87-95.
114. Loran O.B. Otkryitaya hirurgicheskaya tehnika v lechenii striktur uretry. Mater. plen. pravl. Rossiyskogo obschestva urologov. Ekaterinburg, 2006. c. 281.
115. Scheplev P.A. i dr. Analiz alternativnykh tehnologiy po lecheniyu striktur peredney uretry s ispolzovaniem metodiki kompleksnoy sravnitel'noy otsenki. *Andrologiya i genitalnaya hirurgiya*, 2006. # 4, c. 30-35.
116. Lupaşco C. et al. Experienţa noastră în tratamentul chirurgical al stricturilor de uretră. Culegere de lucrări – Conf. a III-a de Urologie şi Conf. a II-a de Nefrologie, Dializă şi Transplant renal. Chişinău, 2002, p. 247-249.
117. Scutelnic Gh. ş.a. Tratamentul chirurgical al stricturilor uretrale. *Arta Medica, Conferinţa aniversară a Spitalului Clinic Republican.* Chişinău, 2007, p. 101-102.
118. Scutelnic Gh., Ghicavii V., Tănase D. ş.a. Tratamentul chirurgical al stricturilor uretrale. Conf. aniver. "190 de ani ai Spitalului Clinic Republican". Chişinău, 2007, p. 14 3-144.
119. Karpuhin I. V. i dr. Transuretralnaya enukleatsiya predstatelnoy zhelezyi (TUEB) – novyy metod bipolyarnoy endoskopicheskoy hirurgii DGPZh *Urologiya.* # 2, 2012
120. Pushkar D.Yu., Zhivov A.V., Loran O.B. i dr. Sravnitel'naya chastota i faktory riska retsidiva striktury pri razlichnykh metodah operativnogo lecheniya. *Andrologiya i genitalnaya hirurgiya.* 2012, # 4, c. 37-44.
121. Martov A.G., Andronov A.S. i dr. Eyakulyatornoprotektivnaya transuretralnaya rezektsiya predstatelnoy zhelezyi *Urologiya.* 2014, # 4.
122. Saidov I.R. Endoskopicheskoe lechenie obliteratsiy uretry u muzhchin // Avtoreferat diss. kand. med. nauk. M., 2000. c. 24
123. Zehri A.A. et al. Predictors of recurrence of urethral stricture disease following optical urethrotomy. *A Internat. journal of surgery.* London, England, 07.2009, 7(4), p. 361-364.

124. Naude A.M., Heyns C.F. What is the place of internal urethrotomy in the treatment of urethral stricture disease? *Nat ClinPract Urol* 2005; 2(11):538-45.
125. Calomfirescu N., Voinescu V. *Tratamentul endoscopic al stricturilor uretrale masculine*. București, Ed. Academiei Române, 2001.
126. Martov A.G. i dr. Otdalennyye rezultaty vnutrenney opticheskoy uretrotomii. *Materialy Rossiyskogo kongressa po endourologii*. M., 2008, s. 65-66.
127. Shkodkin S.V., Idashkin Yu.B., Fentisov V.V. Opticheskaya uretrotomiya v lechenii suzheniy mocheispuskatelnogo kanala. *Materialy I Rocs kongressa po endourologii*. M., 4-6 iyunya 2008, s. 116-117
128. Nazarov T.N. i dr. Optimizatsiya metodov diagnostiki i lecheniya hronicheskogo obstruktivnogo prostatita. XII sezhd Ross. obsch. urol. Mater. M.: Dipak, 2012, s. 43-44.
129. Dmitriev B.V. i dr. Palliativnaya transuretralnaya rezektsiya (TUR) dobrokachestvennoy giperplazii predstatelnoy zhelezy (DGPZh) u bolnykh s interkurrentnoy patologiyey. *Mater. I Rossiyskogo kongr. po endourologii*. M., 2008, s. 40-41.
130. Martov A.G., Maksimov V.A. i dr. Vaporizatsiya dobrokachestvennoy giperplazii predstatelnoy zhelezy s pomoschyu diodnogo lazera. *Mater. kongr., Rostov-na-Donu*, 2012, s. 55-56.
131. Martov A.G., Fahredinov G.A., Maksimov V.A. i dr. Oslozhneniya i neudachi transuretralnykh operatsiy na mocheispuskatelnom kanale. *Vestnik Rossiyskogo nauchnogo tsentra rentgenoradiologii Minzdrava Rossii (elekt. zhurnal)*. 2011.
132. Ghicavii V. Recanalizarea endoscopică în stricturi și obliterații uretrale. *Arta Medica*. 2015, nr. 4 (57), p. 61-63.
133. Ghicavii V. *Tratamentul endoscopic al stricturilor de uretră la bărbați*. *Buletinul Academiei de Științe a Moldovei. Științe Medicale*. 2015, nr. 1 (46), p. 407-414.
134. Ying-Hao S. et al. Urethroscopic realignment of ruptured bulbar urethra. *J Urol*. 2000 164:1543-5.
135. Giannakopoulos X. et al. Sachse urethrotomy versus endoscopic urethrotomy plus trans-urethral resection of the fibrous callus (Guillemin's technique) in the treatment of urethral stricture. *Urology*. 1997 Feb; 49(2):243-7.
136. Trapeznikova M.F., Urenkov S.B., Bazaev V.V. Sravnitelnyy analiz rezultatov otkrytyykh i endoskopicheskikh operatsiy pri obliteratsiyah zadney uretry i muzhchin. *Urologiya*, 2004, # 1, c. 47-54.
137. Pushkar D.Yu., Zhivov A.V. i dr. Kachestvo zhizni muzhchin posle razlichnykh operatsiy po povodu striktury uretry. *Ekspirim. i klinich. urologiya*. 2012. # 4, c. 48-52.
138. Wade Robert. *Stricture of the urethra; its complications and effects, a practical treatise on the nature and treatment*. Aug 31 2012.
139. Voinescu V. ș.a. Uretroplastii la bărbat: Experiența a 5-a plus 6 ani. Al XXVI-lea Congres Național al Asociației Române de Urologie. București. *Rev. Rom. Uro*. 2010, 9(2), p. 76.
140. Lucan M. et al. Bipolar plasma vaporization of the prostate vs. Laser vaporization. Annual EAU congress, Milan, Italy, 2008.
141. Ghicavii V., Tănase A., Josan A., Pleșacov A. Vaporizarea Laser Thuleum (Thu Vap.). Prima experiență clinică. *Revista Română de Urologie*. Al XXXII-lea Congres al Asociației Române de Urologie. București, 2016, vol.15, nr. 2, p. 111. ISSN: 1223-0650.
142. Dogra P.N., Ansari MS., Gupta NP. *Urethral Strictures In: Holmium Laser-Endourological application*. Edited by Gupata NP and Kumar R. B. Publications Pvt Ltd. New Delhi, India, 2004; p. 29-36.
143. Al-Quadah H.S., Santucci R.A. Extended complications of urethroplasty. *Int. Braz. J. Urol*. 2005, 31 (4), p. 315-323.
144. Maddick Edmund Distin. *Stricture of the Urethra: Its Diagnosis and Treatment Facilitated By the Use of New and Simple Instruments*. 2012.
145. Ghicavii V. Particularitățile tratamentului sclerozei de prostată. *Arta Medica*. 2015, nr. 4 (57), p. 57-60.
146. Kizer W.S. et al. Simplified reconstruction of posterior urethral disruption defects: limited role of supracrural rerouting. *J. Urol*. April 2007, 177 (4), p. 1378-1381.
147. Izmaylov R.I. Optimizatsiya lecheniya bolnykh dobrokachestvennoy giperplaziey predstatelnoy zhelezy bolshih razmerov. *Avtor. diss. kand. med. nauk*. Chelyabinsk, 2010.
148. Kabardakov A.H. Diagnostika i lechenie infravezikalnoy obstruktsii obuslovennoy giperplazirovannoy sredney doli prostaty. *Avt. dis. kand. med. nauk*. M., 1999.
149. Alyaev Yu.G. i dr. Prichiny erektilnoy disfunktsii posle transuretralnoy rezektsii giperplazirovannoy predstatelnoy zhelezy i ee profilaktika. // *Urologiya*, 2005, # 3. c. 28-32
150. Futao S. Application of endoscopic Ho: YAG laser incision technique treating urethral strictures and urethral atresias in adults and pediatric patients. *Urethral reconstructive surgery*. 2008. p.514-518.

