

## Methodology of computed tomography of maxillofacial and craniocerebral regions by means of vertical fixation of the examined objects

Oshurko Anatolii<sup>1</sup>, \*Oliinyk Ihor<sup>2</sup>, Tsyhykalo Oleksandr<sup>1</sup>

<sup>1</sup>Department of Histology, Cytology and Embryology, <sup>2</sup>Department of Pathological Anatomy  
Bukovinian State Medical University, Chernivtsi, Ukraine

\*Corresponding author: olijnyk1961@gmail.com. Received July 01, 2017; accepted October 01, 2017

### Abstract

**Background:** The research aims at identifying new methodological approaches to the study of morphological patterns of prenatal development of the human upper jaw.

**Material and methods:** A working model has been developed and a device has been proposed, reasonable to be used for fixation of the examined object in a vertical position during computed tomography of maxillofacial and craniocerebral regions. For proper operation of the device there was introduced a method of vertical fixation of the examined objects during computed tomography of maxillofacial and craniocerebral regions.

**Results:** In the basis of the useful model lies the task to develop a method of vertical fixation of objects under study during the computed tomography of maxillofacial and craniocerebral regions by holding the examined object of up to 540 mm in size; the object is fixed to the planetable using the right and left retainers that are fixed in vertical openings; the height is regulated with the help of the rack, connecting the planetable with the tripod; swivel mounting is led to the facial part of the examined object and the chin is fixed on the table; then the vertical and horizontal position of the chin is regulated by means of sliding vertical and horizontal mounting; the fixed examined object is then moved to the CT scanner with the help of mobile tripod supports.

**Conclusions:** The proposed method is effective for vertical fixation of examined objects during the computed tomography of maxillofacial and craniocerebral regions in the desired position, that contributes to getting qualitative indicators of the examination and can be used during the spot-film radiography in direct and lateral projections in stable and desired position of the head and at the correct distance without imposing additional densities (shades) to provide accurate diagnostic results.

Key words: human fetus, maxillofacial and craniocerebral regions, vertical fixation, CT examination, upper jaw.

### Introduction

Currently human anatomy deals with the shape and structure of organs, systems and human body in general as a product of heredity, which changes depending on certain conditions of biological and social environment and activities performed by the body, both in time (phylo- and ontogenesis) and in space (different geographical areas), synthesizes data of allied and related disciplines – histology, cytology, embryology, biochemistry, comparative anatomy, physiology, biophysics, etc. [1, 2, 12, 18]. The study of developmental peculiarities of anatomical structure of the teeth-jaw system in prenatal period of human ontogenesis is a topical direction in morphological investigations, which contributes to the solution of the important medical and social problem – improvement of preventive methods, early diagnostics and effective correction of congenital defects and treatment of acquired diseases of the upper jaw in man [10, 14, 16, 17]. Under the influence of a number of external factors certain malformations are observed in children even if they do not have obvious dental disorders, those are variations in terms of the teeth eruption and second dentition, the duration of their mineralization and roots formation compared to the terms and duration of these processes, presented by the researchers of the second half of the last century and therefore they need to be reviewed and refined [4, 5, 6, 7, 8, 9]. Data present in classical literature on embryology and meaningful publications are based on general biological foundation. Being steadfast, they do not disclose in detail a number of specific issues that are being discussed and the topic continues

to attract researchers' attention in both general-theoretical and applied aspects [12, 15, 19]. Search for new methodological approaches to the study of morphological patterns of prenatal development of the upper jaw in man constitutes the objective of the study.

### Material and methods

We have developed a working model and proposed the invention "Device for vertical fixation of examined objects during the computed tomography of maxillofacial and craniocerebral regions" for which priority of applications for invention was received [11], it refers to medicine, namely to anatomy, topographical anatomy and operative surgery, dentistry, pathological anatomy, morphology, forensic medicine, radiology, and can be used during the computed tomography of maxillofacial and craniocerebral regions to fix the examined object in the vertical position. It is for proper operation of the device [11] that we have developed a method of vertical fixation of the examined objects during the computed tomography of maxillofacial and craniocerebral regions [13].

The method was developed in the framework of the planned complex research work "Morphogenesis patterns and structural and functional properties of tissues and organs in human ontogenesis" of the department of histology, cytology and embryology; department of pathological anatomy of Higher State Educational Institution of Ukraine "Bukovinian State Medical University" (state registration № 0116U002938).

## Results

It is known that the possibility of computed tomography (CT) is characterized by the hardware-controlled reconstruction of one-time received images in different anatomical planes (projection) as well as by the three-dimensional reconstruction and provides the opportunity not only to assess the size, but also to study their structural features in detail and even some physiological characteristics based on the X-ray density [5, 6, 11].

The examined objects are usually placed horizontally on standard rail tables during the computed tomography. However, such examination of the objects is not ergonomic. We proposed to use dental scanners for this purpose, but they do not provide the placement of the examined object in the desired position with vertical fixation.

An important condition for ensuring dental CT is the motionless position of the examined object because movements during the study result in the occurrence of targeting artifacts: dark colored stripes from the formations with low air absorption coefficient and white stripes from the structures with high contrast index (bone, metal clips), which also reduce the diagnostic capacities, because receiving the image of the examined object by dental CT is achieved using a circular movement of the X-ray tube (240°).

Consequently, the urgent task is a versatile and convenient in operation fixation of the examined object in a vertical position with the regulation of distances in a stable and desired position, without impeding the scanning of examined areas and without imposing additional densities (shade) that provide accurate results.

The useful model analogue is a method of fixation [3] by means of the apparatus "RAYSCAN Symphony M", producing company DENNIME Bundang Technopark 3-408, KOREA, in which the face is fixed motionless, namely the jaw and the nose, in a standard vertical retainer of the dental tomograph of seated type. The prototype of the utility model is a method of fixing the corpses of fetuses and newborns in a normal anatomic position for morphological studies [20], in which the corpses of fetuses and newborns are fixed in a rectangular wooden frame, 30×50 cm in size, with a cross bar in the middle using 12 loops in-built into the inlets made in the upper and lower walls of the frame at a 7.5 cm distance, in the side walls of the frame at a distance of 12.5 cm from its outer edge, in the cross bar of the frame they are made at a distance of 5.5 cm from its inner edge, and 8 clamps.

In the basis of the useful model [13] lies the task to develop a method of vertical fixation of objects under study during the computed tomography of maxillofacial and craniocerebral regions by holding the examined object of up to 540 mm in size; the object is fixed to the planetable using the right and left retainers that are fixed in vertical openings; the height is regulated with the help of a rack, connecting the planetable with the tripod, for this reason it is fixed with the coupling inside the tripod tube; swivel mounting is led to the facial part of the examined object and the chin is fixed on the table; then the position of the chin in the vertical direction is

regulated by means of sliding vertical mounting that is fixed by a plate of vertical mounting, and in the horizontal direction by means of sliding horizontal mounting that is fixed by a plate of horizontal mounting; the fixed examined object is then moved to the CT scanner with the help of wheels attached to the tripod supports.

**Theoretical background of the utility model development.** Computer methods of diagnostics have recently become extensively developed, in particular computed tomography, which provides highly accurate images of osseous tissues.

CT solves the problem of accuracy, high reliability and objectivity and reduces the time of the examination.

The use of CT reduces signal distortion and radiation exposure, providing high contrast and sharpness of images, convenience and reliability while storing the information.

The advantage is that CT allows performing the examination of animal carcasses, human fetuses and newborns without autopsy. But such objects are specific due to their size and condition. Thus, the most productive for their study is the use of mobile dental scanners, for which the necessary prerequisite is a vertical fixation of the examined object.

Currently there are no specialized convenient ways of fixing such objects, the main task of which is to maintain normal anatomical position of the corpse. To solve this problem fixation should be carried out by adjusting the distances in both vertical and horizontal directions. One of the essential tasks is also to exclude the imposition of additional density (shade) to obtain clear images and accurate research results.

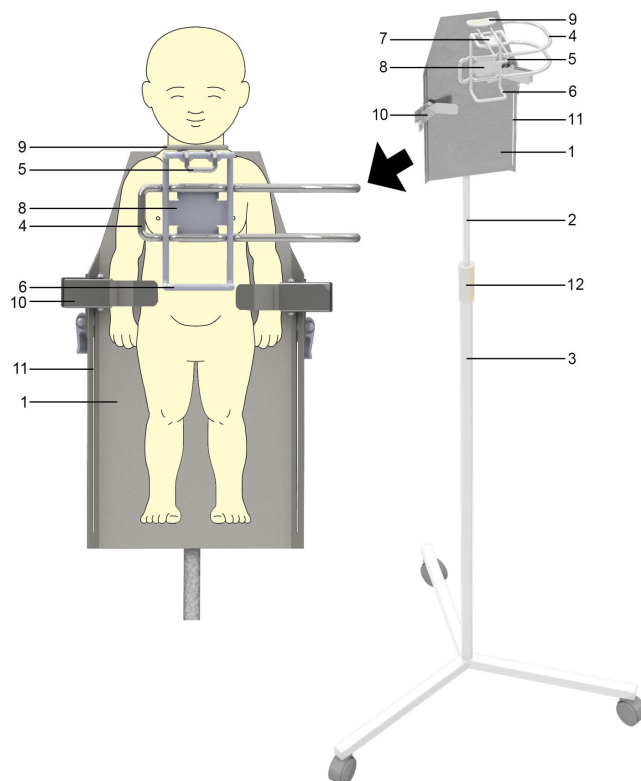


Fig. 1. Demonstration of the method of vertical fixation of the examined object for performing computed tomography of maxillofacial and craniocerebral regions (scheme).





tion, that contributes to getting qualitative indicators of the examination and can be used during the spot-film radiography in direct and lateral projections in stable and desired position of the head and at the correct distance without imposing additional densities (shades) to provide accurate diagnostic results.

### References

- Achtemiichuk Yu.T., Tsyhykalo O.V., Oliinyk I.Yu., Nahirnyak V.M. Development of the sphincteric apparatus of the extrahepatic bile ducts in the prenatal period of human ontogenesis. *European International Journal of Science and Technology*. 2013; 2(10): 9–18.
- Achtemiichuk Yu.T., Tsyhykalo O.V., Oliinyk I.Yu., Nahirnyak V.M. Spatio-temporal characteristic of the sphincters of the extrahepatic bile ducts during prenatal period of human ontogenesis. *Clinical and experimental pathology*. 2013; 12(4): 24–30.
- Dadabaev V.K., Strel'nikov V.N., Tischenko V.N., Shemonaev Yu.V. The method of personality identification using computed tomography (CT). Patent 2510239 (Russia), IPC A61B 5/117, A61B 6/03, G06K 9/00. Applicant Tver State Medical Academy. Application № 2012119004/14; applied on 11.05.2012; published on 27.03.2014. – Bulletin № 9.
- Dahno L.O., Krynytskyi R.P., Pavliv H.I., Masna Z.Z., Masna-Chala O.Z. Features of rearrangement of collar processes of the jaws and their correlation with the roots of permanent teeth in the age aspect. *Herald on Biology and Medicine*. 2014; 2(1): 136–139. Access mode: [http://nbuv.gov.ua/UJRN/Vpbm\\_2014\\_2%281%29\\_35](http://nbuv.gov.ua/UJRN/Vpbm_2014_2%281%29_35) (in Ukrainian).
- From CT Numbers to Hounsfield Units in Cone Beam Volumetric Imaging: the effect of artifacts by Dr. Roberto Molteni // URL: [http://cymcdn.com/sites/www.aaomr.org/resource/resmgr/2012\\_Uploads/AAOMR2011\\_medium.pdf](http://cymcdn.com/sites/www.aaomr.org/resource/resmgr/2012_Uploads/AAOMR2011_medium.pdf) (date of withdrawal of information: 28.06.2017).
- Hounsfield scale // [wikipedia.org](http://en.wikipedia.org/wiki/Hounsfield_scale) URL: [http://en.wikipedia.org/wiki/Hounsfield\\_scale](http://en.wikipedia.org/wiki/Hounsfield_scale) (date of withdrawal of information: 25.05.2017).
- Krynytskyi R.P. Age and gender related peculiarities of structure and mineral composition of the osseous tissue of the alveolar part of the lower jaw in patients of a mature age: abstract of a thesis for the academic degree of a Candidate of Medical Sciences in speciality 14.03.01 "Normal anatomy". – Ministry of Public Health of Ukraine, HSEI of Ukraine "Bukovinian State Medical University" – Chernivtsi. 2016; 24 p.
- Krynytskyi R.P., Masna Z.Z. Age and sexual features of the mineral composition of bone tissue in the cellular part of the mandible in adults. *Scientific and Practical Conference "Morphological Research – Challenges of Modernity"* (Sumy, April 23-24, 2015). – Sumy: SSU. 2015; 30–32.
- Krynytskyi R.P., Masna Z.Z. Analysis of the bone tissue density in the main and cellular parts of the mandible in the age dynamics for different sex individuals. *Papers of the Shevchenko Scientific Society. Medical sciences. Collected Medical Articles*. 2015; 41(26): 73–83. Access mode: [http://nbuv.gov.ua/UJRN/pntsh\\_lik\\_2015\\_41\\_26\\_9](http://nbuv.gov.ua/UJRN/pntsh_lik_2015_41_26_9).
- Masna Z.Z., Masna-Chala O.Z., Pavliv Kh.I., Stupnytskyi I.R. Frequency of different kinds of occlusion in combination with anomalies of teeth position in teenagers in Lviv. *Experimental and Clinical Medicine*. 2014; 3(64): 95–97.
- MLA style: "Godfrey N. Hounsfield – Nobel Lecture: Computed Medical Imaging". [Nobelprize.org](http://Nobelprize.org). Nobel Media AB 2014. Web. 7 Jan 2015.
- Oliinyk I.Yu., Martseniak I.V. Sexual, age and constitutional features of the buccal region of human fetuses in the second trimester of their development. *Journal of Anatomy and Histopathology*. 2013; 4(8): 51–54.
- Oshurko A.P. Methodology of morphological studies of the upper jaw in man at the stages of prenatal development. *Khyst. All-Ukrainian Medical Journal of young scientists*. 2017; 19(1): 247.
- Oshurko A.P., Oliinyk I.Yu., Tsyhykalo O.V. Device for vertical fixation of the examined objects during computed tomography of maxillofacial and craniocerebral regions: Application for invention; applicant and patentee HSEI "Bukovinian State Medical University". Conclusion on date setting for making an Application for invention of 02.02.2017, registration № a 2016 12078.
- Oshurko A.P., Oliinyk I.Yu., Tsyhykalo O.V. Innovation in the organization of the study of structure peculiarities of the upper jaw in man in the dynamics of prenatal ontogenesis. 98<sup>th</sup> Scientific Conference of the teaching personnel of HSEI of Ukraine "Bukovinian State Medical University" (Chernivtsi, February 13, 15, 20, 2017). – Chernivtsi: Medical University. 2017; 19–20.
- Oshurko A.P., Oliinyk I.Yu., Tsyhykalo O.V. Method of vertical fixation of the examined objects during computed tomography of maxillofacial and craniocerebral regions. Patent on a useful model № 115422 (Ukraine), IPC (2017.01); A61B 6/00; A61B 6/03 (2006/01); A61B 6/04 (2006/01). Applicant and patentee HSEI "Bukovinian State Medical University". Application № u2016 12076; applied on 28.11.2016; published on 10.04.2017. – Bulletin № 7.
- Oshurko A.P., Oliinyk I.Yu. Morphogenesis of the maxilla and some structures of the maxillofacial area in the embryonic period of human prenatal ontogenesis. *Clinical and experimental pathology*. 2017; XVI. 2(60). Part 2: 137–144.
- Railean S. Cranial deformities as a risk factor in the harmonious development of oral and maxillofacial region. *The Moldovan Medical Journal*. April 2017; 60(2): 13–17. Access mode: <http://curierulmedical.org/wp-content/uploads/2017/02/60-2-2017-v2.pdf>.
- Slobodian O.M., Kuzniak N.B., Lavriv L.P. Features of perinatal organometric parameters of head sections and structures. *Herald on Biology and Medicine*. 2016; 2(129): 314–317.
- Slobodian O.M., Korchyńska N.S. Radioanatomy and morphometry of the maxilla in the second trimester of the intrauterine growth. *Ukrainian Journal of clinical and laboratory medicine*. 2013; 8(3): 98–101.
- Stoliar D.B., Oshurko A.P., Zhupnyk I.M. Perinatal radioanatomy of the temporomandibular joint. IX International Scientific Conference of Students and Young Scientists "The First Step in Science - 2012" (Vinnytsya, March 20-21, 2012). – Vinnytsya: Medical University. 2012; 79–80.
- Tabachniuk N.V., Oliinyk I.Yu. Changes in morphological and anthropometric characteristics of the submandibular salivary glands of human fetuses. *Herald on Biology and Medicine*. 2014; 1(113): 296–301.
- Tsyhykalo O.V., Nazymok Ye.V., Oliinyk I.Yu., Skoreiko P.M., Martseniak I.V. Retainer for fixation of fetuses and newborns corpses in a normal anatomical position for morphological studies. Patent 99524 (Ukraine), IPC A61J 1/00, A01N 1/00. Applicant and patentee Bukovinian State Medical University. Application № u 2014 13792; applied on 22.12.2014; published on 10.06.2015. – Bulletin № 11.

### Compliance with ethical standards.

**Conflict of interest:** The authors declare that they have no conflict of interest.