

Evolution of the toxocariasis monoinvasion in comparison with the toxocariasis associated with other parasites in children

*Placinta Gheorghe^{1,2}, MD, PhD, Associate Professor;
Stirbu Tatiana^{1,3}, MD, Assistant Professor; Tovba Lidia⁴, MD, Assistant Professor

¹Department of Infectious Diseases, ⁴Department of Infectious, Tropical Diseases and Medical Parasitology
Nicolae Testemitsanu State University of Medicine and Pharmacy

²Consultation and Diagnostic Center of Medical Parasitology and Tropical Diseases
Toma Ciorba Republican Hospital of Infectious Diseases

³Clinical Municipal Hospital of Infectious Diseases in Children, Chisinau, Republic of Moldova

*Corresponding author: gheorghe.placinta@usmf.md. Received January 11, 2018; accepted February 26, 2018

Abstract

Background: Toxocariasis is a parasitic infection with a major risk to children, especially because of their incompletely developed immune system, high risk of infection or frequent re-infection, all correlated with living standards and personal hygiene. Toxocariasis occurs most frequently occult. However, evident clinical manifestations may be found, due to the migration of larvae in the second stage of development, the degree of toxocara invasion and the immune system of the child.

Material and methods: The study presents the evolution peculiarities in a group of 94 children with toxocara monoinvasion compared to a group of 73 children with the presence of two or more parasitoses. Clinical particularities, representative laboratory indices, treatment and its influence on clinical and paraclinical indices were examined.

Results: The presented article compared the most common clinical signs and paraclinic changes in both studied groups. Was examined the specific treatment for each group of patients and its action on the laboratory indices and especially the influence of treatment on the antibody titer to *T. canis*.

Conclusions: The most common clinical signs were asthenia, weight loss. An increase in eosinophil level is recorded only in the 13.5% in the cases of Toxocara monoinvasion and in 15.1% of the cases with Toxocariasis associated with other parasites. Anti-toxocara specific therapy proved to be much superior to other medications with a significant reduction in the percentage of eosinophils and total IgE.

Key words: toxocariasis in children, larva migrans visceralis.

Introduction

The term Larva Migrans Visceralis (LMV) was first used by Beaver et al. [1] in 1952, when the authors reported the clinical picture of three children with chronic marked eosinophilia, hepatomegaly, pulmonary damage, fever, and cough, all those listed being produced by larval migration in lungs with subsequent migration to other organs. Beaver et al. [1] used the term LMV to define larval migration in the second phase of development in the organs of the intermediate host (humans) [2].

T. canis and *T. cati* are found throughout the globe with a higher frequency in developing countries with a poor sanitation system. The human genetic tendency to be surrounded by pets (dogs and cats) also has a decisive factor in the spread of this infection [3].

Toxocara genus belongs to the class Nematoda, order Ascaridoidea, family and subfamily Ascarinae and includes 21 species. The species *T. canis*, *T. cati*, and *T. leonina* are most commonly implicated in LMV syndrome [4], in humans this syndrome is caused by *T. canis* and *T. cati* [3].

Mature worms live an average of four months, after six months almost all are eliminated spontaneously from the body [4]. The *T. canis* female produces almost 200,000 eggs [5], which are sufficiently resistant and can survive for a long time in soil [4]. The eggs are not embryonated in faeces

so they are not infectious. Only temperatures of 15-30 °C plus humidity are necessary conditions for the eggs to be embryonated and become infectious within 2-5 weeks after elimination [6].

The definitive host for *T. canis*, is the domestic dog, where the adult worm populates the animal's intestinal small intestine [3]. The elimination of faeces in public spaces by dogs contributes to the zoonotic spread of parasitosis [5].

Infection in children occurs through the ingestion of *T. canis* embryonated eggs [6] by direct contamination of the hands, especially from the contact with puppies aged between 2 weeks and 6 months and by indirect contact with contaminated objects inside or outside the house.

LMV is a syndrome caused by the ingestion of soil infected with *T. canis* eggs [7-9]. Various studies have attempted to make a statistical link between the high risk of developing toxocariasis in children and various poor childhood habits. Some authors have reported the presence of pica sdr. in children with toxocariasis with Larva Migrans Visceralis syndrome [11-17] most often in the age group of 1 to 6 years, with a slight prevalence of boys over girls [10]. Two contradictory studies have shown, on the one hand, a relationship between the habit of chewing nails and toxocariasis [18], while the other showed the absence of this relation [7].

The presence of a dog in the house has also been classified

as a risk factor for toxocariasis according to some studies [8,10,19,12,13,20,21]. However, some authors have pointed out that if hygiene measures are kept, this correlation is not maintained [8]. Several studies have provided information on the relationship between seropositivity at *T. canis* in puppy owners, who had their pets for at least 3 months [7,20]. Iddawela et al. have demonstrated that socio-economic status is not an increased risk for toxocariasis [20]. Other authors have shown the relation between this parasitosis and the socio-economic status with such indicators as low income and lack of education [5,18,22]. They have found a connection between the high prevalence of toxocariasis and the low level of urbanization or the lack of access to sanitary conditions [8,18,23]. Thus, the many studies performed in this field had contradictory results, but all of them have a common side – toxocariasis presents a very varied seroprevalence: from 9.7% to 43% in children in various areas of the world [20-22, 24-27]. In most cases of invasion with *T. canis*, infection occurs asymptotically (approximately 44.4% of cases) [28], the systemic manifestations reaching only 15.5% of diagnosed cases [29].

Because of the variability of clinical signs, a new classification of toxocariasis was proposed in the 1992-1993, according to which the disease was divided into 3 clinical forms: LMV (Larva Migrans Visceralis), OT (Ocular Toxocariasis) and occult form of toxocariasis [30, 31].

The proposed classification was presented as a compromise between clinical observations of patients, the presence of immunopathogenic mechanisms including the degree of immunological response and the location of the toxocara larvae. In fact, this classification divides toxocarosis into the classical, systemic, occult form, and compartmentalized (ocular and neurological) forms. The last two forms are likely to be classified separately, being the last penetration sites of the *Toxocara* larvae [32].

LMV has been described as a syndrome with marked manifestations of hypereosinophilia, hepatosplenomegaly, fever, hypergammaglobulinemia [1], leukocytosis, manifestations that occur in children from 1 to 5 years, with an average duration of 2 years [33].

Various authors have found a correlation between the presence of anemia and toxocariasis [1,14, 25, 35, 36, 37, 38]. Others, (Glickman et al.) found a correlation between a leukocytosis of 10×10^9 and a positive ELISA for *T. canis* [34].

Ocular toxocariasis is a clinical form that affects with the same frequency women and men and occurs at an early age. In literature OT is described as having a frequency from 0 to 10% [21, 28, 39] with an average age at the time of occurrence from 3 to 11 years [11, 40]. The disease is unilateral in most cases with a minimal or moderate degree of inflammation [41, 42]. Clinical manifestations are presented through peripheral granuloma of the retina in 50% cases, macula in 25%, and in 25% cases occurs endophthalmitis. Granuloma can also appear in the optic nerve [43]. Magnaval et al.

[44], and Sabrosa and Souza [15] in 2001. reported that eosinophilia is usually absent in occult toxocariasis.

Throughout the history of the study of toxocariasis, have been described various types of systemic damage. It all began in 1952 when Beaver et al. [1] have described several clinical cases of toxocarosis with skin damage. In the same year Beaver described 3 cases of hepatomegaly in children with toxocariasis, one child also presented splenomegaly. These children endure liver biopsy, with an extensive area of liver necrosis and inflammation. The authors also found eosinophilic leukocytes as well as giant and epithelial cells around the areas of necrosis [1].

Other authors, studying the same pathology, did not find a direct correlation between splenomegaly [7] and hepatomegaly [34] in patients with toxocariasis, but demonstrated the presence of isolated hepatomegaly in patients with this parasitosis [7,45]. Studying the incidence of splenomegaly and hepatomegaly in patients with toxocariasis, in various studies the authors presented a rate of hepatomegaly between 11 and 85% [14,17,28] and splenomegaly between 20 and 45%. Despite of such diverse rates of hepatomegaly, a slightly elevated level of the liver occurred in nearly 90% of children with toxocariasis according to a study in Brazil [46].

Taylor et al. described abdominal pain as one of the most common symptoms, especially in children with high antibody titres of *T. canis* [40]. Iddawela et al. have assumed that the major cause of abdominal pain is mesenteric lymphadenopathy as a response of the intermediate host to the migration of the toxocara larvae [20].

Also, in several studies conducted in children with toxocariasis, there were found hypoeogenic lymph nodes with a diameter of up to 8 mm [47]. Two children with pancreatic lymph node were also described. In literature there are reports of liver abscesses in toxocariasis [48-50]. Between 1996 and 2002 three cases of pleuritis with positive ELISA were described for *T. canis* [51-53].

Some authors have demonstrated the connection between bronchial asthma and toxocariasis [45], others have insisted that this was possible in patients with atopic and / or allergic antecedents [54]. The literature includes multiple descriptions of bronchospasm-associated with toxocariasis in children [14, 21, 55, 33]. Alderets et al. describe the association of wheezing with positive serology for *T. canis* [18]. Other authors reported that such respiratory signs as cough are common in children with positive serology for toxocariasis [20, 45, 56, 57].

Material and methods

The study included 167 children aged from 3 to 18 years who were divided into two research groups: the first included 94 children diagnosed with toxocariasis monoinvasion, and the second group included 73 children, with toxocariasis associated with other parasitoses (ascaridosis, oxyuriasis, giardiasis). Patients were examined clinically, showing the most common clinical and paraclinical signs, the general

blood count, biochemical test (ALT and AST), total IgE, antibody titer against *T. canis*.

Results and discussion

The study involved 167 children with chronic visceral toxocariasis, 94 of them with toxocara monoinvasion and 73 in combination with various other parasitoses. The duration of the toxocara invasion ranged from 1 to 9 years, the majority of 117 (70.1%) with a duration of 2-7 years.

The age of children with toxocara monoinvasion was presented by next values: age category 4-7 years constituted 22.3%, 8-12 years 38.3% and 13-18 years 39.4%. In these patients the bronchopulmonary form prevailed in 32 children (34.0%) followed by the neurological form in 30 children (31.9%), cutaneous form in 16 children (17.0%), digestive form in 10 children (10.5%) and other clinical variants in 6 children (7.3%).

The spreading of the process demonstrated the involvement of a single organ system in the pathological process in 33 cases (35.1%), two systems in 39 cases (41.5%) and three and more systems in 22 cases (23.4%).

Among the children with toxocariasis associated with other parasitoses (ascariidiasis – 25 cases, oxyuria – 18, lambliaisis 16, ascariidiasis with oxyuria – 5, ascariidiasis with lambliaisis – 9), the age category 3-7 years constituted 16,4%, 8-12 years – 37.0%, and 13-18 years – 46.6%. The most common clinical form was neurological with involvement of 25 children (34.2%), followed by bronchopulmonary clinical form in 19 children (26.02%), digestive form in 14 children (19.2%), cutaneous form in 8 children (11%), and other

manifestations in 7 children (9.6%). Clinical manifestations involving only one system were recorded in 26 children (35.6%), two systems – 32 children (43.8%), three and more affected systems were determined in 15 children (20.5%).

The most frequent clinical manifestations in the group with toxocara monoinvasion were headache and long-standing cough, both in 33% of cases, followed with a decrease in percentage value (from 25.5% to 20.3%) by hepatomegaly, vertigo, abdominal pain, diffuse echographic changes in liver, skin pruritus, sleep disturbances. The other 6 clinical signs with a percentage decrease from 20% to 10% were: maculo-papular rash, splenomegaly, neuropsychiatric disorders (impulsivity, inability to concentrate, poor memory, chronic apathy, etc.), physical asthenia and weight loss (fig. 1).

In the group with toxocariasis associated with other parasitoses the most common symptom was headache with 42.5% followed by abdominal pain in 32.9% of cases, vertigo in 31.5%, sleep disturbance, physical asthenia and long-standing cough in 27.4%. Thus, within 6 more frequent symptoms, 4 were with the involvement of central nervous system. These signs of CNS involvement were functional, with a gradual decrease to complete disappearance at different time intervals. In toxocariasis associated with other parasitoses, asthenia, weight loss, anorexia, pain and weight in the right hipocondrium were significantly more common compared to toxocara monoinvasion. Long-term cough (32.4% versus 24.7%) was reported more frequently in toxocara monoinvasion, whereas in toxocariasis associated with other parasitoses were found more frequent headache

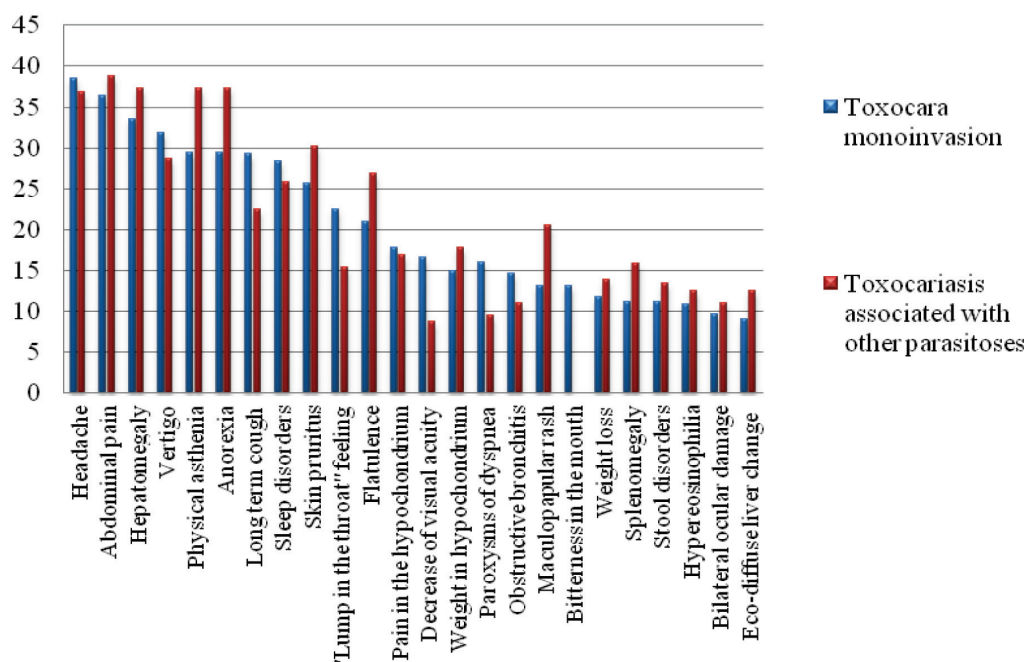


Fig. 1. Percentage distribution of the most common signs in children with chronic visceral toxocariasis in monoinvasion and in combination with other parasitoses.

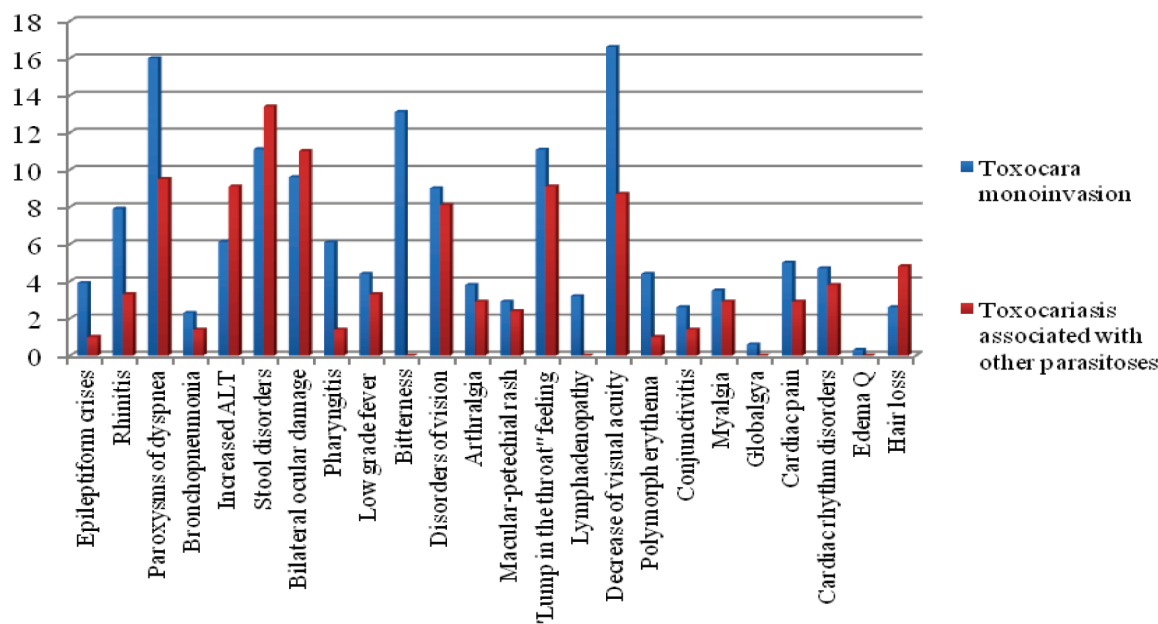


Fig. 2. Percentage distribution of rare signs in children with chronic visceral toxocariasis in monoinvasion and in combination with other parasitoses.

(42.5% vs. 32.4%), abdominal pain (32.9% vs. 21.6%) and vertigo (31.5% vs 24.3%) (fig. 2).

Clinical manifestations with an incidence of less than 10% during chronic toxocariasis in children are shown in figure 2. In 8.1% of cases of toxocara monoinvasions were recorded epileptiform seizures, signs of rhinitis and dyspnoea, in 6.8% of cases – bronchopneumonia, in 5.4% of cases elevated ALT level. In associated forms more frequently was observed an increased level of ALT (8.2%).

In the group of patients with associated diseases, non-specific treatment included antiparasitic therapy (for ascariasis, lamblia, enterobiosis) with a single dose of benzimidazole derivatives, the dose being repeated after 14 days only in oxyuria, a three days therapy being given in ascariasis and five days in lamblia, in all cases being administered in only one administration per day. The specific anti-toxocara treatment included in most cases benzimidazoles derivatives, being given twice per day with a dose of 10 mg / kg / body with a 10-14 days therapy.

The leukocyte count did not show significant deviations from the value of the norm in both groups, but during the surveillance it decreased significantly in the group of patients with specific treatment in the toxocara monoinvasion from 6.8 ± 0.47 to 5.5 ± 0.47 .

Also, the number of erythrocytes increased compared to the values before treatment, being significant in the case of toxocara monoinvasion despite of the specific treatment applied. The percentage values of the lymphocytes had minor decrease compared to the baseline in the group with toxocara monoinvasion regardless to the applied therapy, but nevertheless remained above the mean values compared to the healthy individuals, and in the toxocariasis associated

with other parasites this index increased from the initial values. The percentage of eosinophils, which was initially above normal values in healthy subjects (6.3 ± 0.61), decreased despite of the treatment applied: in the group with toxocara monoinvasion with anti-larval therapy up to 3.7 ± 1.0 .

In the groups of children without specific treatment, both in the toxocara monoinvasion and toxocariasis associated with other parasitoses, the levels of ALT activity increased significantly compared to baseline values in healthy individuals. In mono-invasion they increased from 23.8 ± 2.4 to 62.8 ± 14.2 in the associated forms from 29.8 ± 4.24 to 45.5 ± 5.23 . These liver enzyme behavioral findings demonstrate the direct involvement of toxocara larvae and their toxins in the development of hepatic cytolysis syndrome. At the same time, in both groups with specific treatment, ALT activity remained close to baseline mean values, not different from those seen in healthy individuals, demonstrating the safety of antilarvaric treatment in children.

Paradoxically, however, in both groups, regardless of treatment, antibody levels to *T. canis* increased, recording higher levels than those found up to treatment.

The total IgE level was much higher in the case of toxocara monoinvasion – 302.2 ± 41.0 , compared to toxocariasis associated with other parasitoses – 187.6 ± 31.9 . Specific treatment had a benefic effect on the evolution of total IgE, especially in the group of toxocariasis without comorbidities, recording significantly lower values compared to the baseline (145.4 ± 29.2 versus 302.2 ± 41.0). In the case of toxocariasis associated with other parasitoses, the total IgE level on a background of specific treatment decreased insignificantly, whereas in the group with toxocariasis without therapy, on the contrary, increased to 220.7 ± 43.2 , compared to 187.6 ± 31.9 .

The separate group analysis based on the specificity of the administered therapy revealed different behavior in the percentage distribution of clinical efficacy. A total of 56 (59.6%) children with toxocara monoinvasion were treated with anti-larvicidal drugs, while 38 children (40.4%) did not receive this treatment. In the course of chronic toxocariasis without comorbidities, a very pronounced clinical efficacy in children with anti-larvicidal treatment was recorded in 16.1% of cases, whereas in the non-treated group only in 5.3% of cases. Clinical efficacy was also pronounced in a much higher proportion in the group of patients with anti-toxocara therapy – 48.2% of the 56 treated versus 23.7% of the 38 without treatment.

Of the 73 children with toxocariasis associated with other parasitoses, 52 received anti-toxocara therapy, while the other 21 followed only the anti-parasitic therapy of comorbidities. Very pronounced efficacy was found only in 7.7% of the 52 patients with treatment and in none of the children without anti-toxocara treatment. A clinical efficiency with a decrease in the proportion of 50-75% of the previous intensity of clinical signs was found in most patients with anti-toxocara treatment – 51.9% compared to 0.0% in those without the treatment. Also, partial clinical improvement was more frequent in the group of children with toxocariasis with anti-larvicidal treatment with 19.2% of cases, compared with 4.8% of cases in children with therapy only against other parasitoses. The clinical ineffectiveness of anti-toxocara specific therapy was established in 21.2% of cases and in 95.2% in children who only followed treatment against parasitoses identified as comorbidities.

The level of antibodies to *T. canis* in children with toxocara monoinvasion who received specific treatment decreased to 31 (55.4%) compared to 18 (47.4%) found in those without specific therapy. In toxocariasis associated with comorbidities, the decrease in the level of the antibodies was 34 (65.4%) in the group with specific treatment and only in 2 children in the absence of this therapy. However, in both groups after anti-toxocara treatment it was noted the increase in antibody levels in approximately 1/3 of patients: 39.2% of cases from toxocara monoinvasion group and 30.8% from the group of toxocariasis associated with other parasitoses, although most of these children were with clinical improvement.

Conclusions

1. Clinical manifestations during chronic toxocariasis in children are very numerous (over 40 clinical signs), varying in intensity and incidence, the most common of them being headache, dry cough, abdominal pain.

2. In toxocariasis associated with other parasitoses, asthenia, weight loss, anorexia, pain and weight in the right hipochondrium were significantly more common compared to toxocara monoinvasion.

3. Blood hypereosinophilia is recorded in every 6th, 7th

of the studied children, with a rate of 13.5% in the group with toxocara monoinvasion and 15.1% in the group with toxocariasis associated with other parasitoses.

4. Specific therapy in chronic visceral toxocariasis in children, both in cases of isolated toxocariasis and in combination with other parasitoses, had far superior clinical performance compared to other medications, including concomitant therapy for the eradication of parasites.

5. Specific treatment significantly reduced the percentage of eosinophils in both groups of patients, the IgE level in the toxocara monoinvasion group, whereas in the group of toxocariasis associated with other parasitoses in the absence of anti-larvicidal treatment both IgE total and the percentage of eosinophils increased.

References

1. Beaver PC, Snyder CH, Carrera GM, Dent JH, Lafferty JW. Chronic eosinophilia due to visceral larva migrans: report of three cases. *Pediatrics*. 1952;9:7-19.
2. Beaver PC. The nature of visceral larva migrans. *J Parasitol*. 1969;55:3-12.
3. Despommier D. Toxocariasis: clinical aspects, epidemiology, medical ecology, and molecular aspects. *Clin Microbiol Rev*. 2003;16:265-72.
4. Abe-Jacob CM, Oselka GW. Toxocaríase na infância [Toxocariasis in childhood]. *Pediatrics*. 1991;13:48-55. Portuguese.
5. Glickman LT, Schantz PM. Epidemiology and pathogenesis of zoonotic toxocariasis. *Epidemiol Rev*. 1981;3:230-50.
6. Bourke GM, Yeates FM. Blindness due to household pets. *Med J Aust*. 1961;48:12-4.
7. Figueiredo SD, Taddei JA, Menezes JJ, Novo NE, Silva EO, Cristóvão HL, et al. Estudo clínico-epidemiológico da toxocaríase em população infantil [Clinical-epidemiological study of toxocariasis in children]. *J Pediatr (Rio J)*. 2005;81:126-32. Portuguese.
8. Anaruma Filho F, Chieffi PP, Correa CR, Camargo ED, Silveira EP, Aranha JJ, et al. Human toxocariasis: a seroepidemiological survey in the municipality of Campinas (SP), Brazil. *Rev Inst Med Trop São Paulo*. 2002;44:303-7.
9. Mizgajská H. The role of some environmental factors in the contamination of soil with *Toxocara* spp. and other geohelminth eggs. *Parasit Int*. 1997;46:67-72.
10. Glickman LT, Chaudry IU, Costantino J, Clack FB, Cypess RH, Winslow L. Pica patterns, Toxocariasis, and elevated blood lead in children. *Am J Trop Med Hyg*. 1981;30:77-80.
11. Zinkham WH. Visceral larva migrans. A review and reassessment indicating two forms of clinical expression: visceral and ocular. *Am J Dis Child*. 1978;132:627-33.
12. Marmor M, Glickman L, Shofar F, Faich LA, Rosenberg C, Cornblatt B, et al. *Toxocara canis* infection of children: epidemiologic and neuropsychologic findings. *Am J Public Health*. 1987;77:554-9.
13. Ellis GS Jr, Pakalnis VA, Worley G, Green JA, Frothingham TE, Sturmer RA, et al. *Toxocara canis* infestation. Clinical and epidemiological associations with seropositivity in kindergarten children. *Ophthalmology*. 1986;93:1032-7.
14. Snyder CH. Visceral larva migrans: ten years experience. *Pediatrics*. 1961;28:85-91.
15. Sabrosa NA, de Souza EC. Nematode infections of the eye: toxocariasis an diffuse unilateral subacute neuroretinitis. *Curr Opin Ophthalmol*. 2001;12:450-4.
16. Trabelsi S, Belhadj S, Kallel K, Zouiten F, Ben Becheur S, Ben Ayed N, et al. La toxocarose: une pathologie sous-estimée. A propos de 9 cas. *Tunis Med*. 2004;82:684-9.
17. Abe-Jacob CM. Contribuição para o estudo da toxocaríase na infância: aspectos clínico-laboratoriais de 40 casos [Contribution to the study of toxocariasis in childhood: clinical and laboratory aspects of 40 cases] [dissertation]. São Paulo: Universidade de São Paulo; 1990. Portuguese.
18. Alderete JM, Jacob CM, Pastorino AC, Rubinsky-Elefant G, Castro AP, Fomin AB, et al. Prevalence of *Toxocara* infection in schoolchildren

- from the Butantã region, São Paulo, Brazil. *Mem Inst Oswaldo Cruz.* 2003;98:593-7.
19. Coelho LM, Silva MV, Dini CY, Giacon Neto AA, Novo NF, Silveira EP. Human toxocariasis: a seroepidemiological survey in schoolchildren of Sorocaba, Brazil. *Mem Inst Oswaldo Cruz.* 2004;99:533-7.
 20. Iddawela DR, Kumarasiri PV, Wijesundera MS. A seroepidemiological study of toxocariasis and risk factors for infection in children in Sri Lanka. *Southeast Asian J Trop Med Public Health.* 2003;34:7-15.
 21. Souza FA. Parâmetros clínicos laboratoriais na evolução de 104 crianças portadoras de larva migrans visceral por *Toxocara canis* [Clinical laboratory parameters in the evolution of 104 children with visceral larva migrans by *Toxocara canis*] [dissertation]. São Paulo: UFESP; 1992. Portuguese.
 22. Kanafani ZA, Skoury A, Araj GF, El-Khoury M, Sawaya RA, Atweh SE, et al. Seroprevalence of toxocariasis in Lebanon: a pilot study. *Parasitology.* 2006;132:635-9.
 23. Caseiro MM. Síndrome de Larva Migrans Visceral causada por Larvas de *Toxocara canis*, no município de Santos [Visceral larva syndrome caused by larvae of *Toxocara canis*, in the municipality of Santos] [dissertation]. São Paulo: Universidade de São Paulo, Faculdade de Medicina; 1996. Portuguese.
 24. García-Pedrique ME, Días-Suárez O, Esteves J, Cheng-Ng R, Araujo-Fernández M, Castellano J, et al. Prevalencia de infección por *Toxocara* em pré-escolares de una comunidad educativa de El Moján, Estado Zulia, Venezuela. Resultados preliminares [Prevalence of *Toxocara* infection in preschool children from an educational community in El Moján, Zulia State, Venezuela. Preliminary results]. *Invest Clin.* 2004;45:347-54. Portuguese.
 25. Malla N, Aggarwal AK, Mahajan RC. A serological study of human toxocariasis in north India. *Natl Med J India.* 2002;15:145-7.
 26. Huerca Aramburu H, López-Vélez R. Estudio comparativo de la patología infecciosa em niños inmigrantes de distintas procedências [Comparative study of the infectious pathology in immigrant children of different origins]. *An Pediatr (Barc).* 2004;60:16-21. Portuguese.
 27. Taranto NJ, Passamonte L, Marinconz R, de Marzi MC, Cajal SP, Malchiodi EL. Parasitosis zoonóticas transmitidas por perros en el Chaco salteño [Zoonotic parasitosis transmitted by dogs in Chaco Salteño]. *Medicina (B Aires).* 2000;60:217-20. Spanish.
 28. Altcheh J, Nallar M, Conca M, Biancardi M, Freilij H. Toxocariasis: clinical and laboratory features in 54 patients. *An Pediatr (Barc).* 2003;58:425-31.
 29. Loez Mde L, Martin G, Chamorro Mdel C, Mario Alonso J. Toxocariasis en niños de una region subtropical. *Medicina [Toxocariasis in children of a subtropical region].* *Medicine (B Aires).* 2005;65:226-230. Spanish.
 30. Nathwani D, Laing RB, Currie PF. Covert toxocariasis - a cause of recurrent abdominal pain in childhood. *Br J Clin Pract.* 1992;46:271.
 31. Rasmussen LN, Dirdal M, Birkebaek NH. „Covert toxocariasis“ in a child treated with low-dose diethylcarbamazine. *Acta Paediatr.* 1993;82:116-8.
 32. Pawlowski Z. Toxocariasis in humans: clinical expression and treatment dilemma. *J Helminthol.* 2001;75:299-305.
 33. Schantz PM. *Toxocara larva migrans* now. *Am J Trop Med Hyg.* 1989;41:21-34.
 34. Glickman LT, Schantz PM, Cypess RH. Epidemiological characteristics and clinical findings in patients with serologically proven toxocariasis. *Trans R Soc Trop Med Hyg.* 1979;73:254-8.
 35. González MT, Ibañez O, Balcarce N, Nanfíto G, KoZubsky L, Radman N, et al. Toxocariasis with liver involvement. *Acta Gastroenterol Latinoam.* 2000;30:187-90.
 36. Amir J, Harel L, Eidlitz-Markus T, Varzano I. Lymphedema as a presenting sign of Toxocariasis. *Infection.* 1995;23:389-90.
 37. Ishibashi H, Shimamura R, Hirata Y, Kudo J, Onizuka H. Hepatic granuloma in toxocaral infection: role of ultrasonography in hypereosinophilia. *J Clin Ultrasound.* 1992;20:204-10.
 38. Almeida MT, Ribeiro RC, Kauffman WM, Maluf Júnior PT, Brito JL, Cristofani LM, et al. Toxocariasis simulating hepatic recurrence in a patient with Wilms' tumor. *Med Pediatr Oncol.* 1994;22:211-5.
 39. Good B, Holland CV, Taylor MR, Larragy J, Moriarty P, O'Regan M. Ocular toxocariasis in schoolchildren. *Clin Infect Dis.* 2004;39:173-8.
 40. Taylor MR, Keane CT, O Connor P, Mulvihill E, Holland C. The expanded spectrum of toxocaral disease. *Lancet.* 1988;1:692-5.
 41. Oréfica F, Boratto LM, Silva HF. Presumível toxocaríase ocular: revisão de 30 casos (1978-1989); relato de dois casos atípicos [Ocular toxocariasis: review of 30 cases (1978-1989); report of two atypical cases]. *Rev Bras Oftalmol.* 1991;50:31-7. Portuguese.
 42. Cochereau I. Infections oculaires [Eye infections]. *Encycl Méd Chir - Maladies infectieuses (Elsevier, Paris)* 2000;8-003-L-10. French.
 43. Stewart JM, Cubillan LD, Cunningham ET Jr. Prevalence, clinical feature, and causes of vision loss among patients with ocular toxocariasis. *Retina.* 2005;25:1005-13.
 44. Magnaval JF, Glickman LT, Dorchie P, Morassin B. Highlights of human toxocariasis. *Korean J Parasitol.* 2001;39:1-11.
 45. Taylor MR, Keane CT, O'Connor P, Girdwood RW, Smith H. Clinical features of covert toxocariasis. *Scand J Infect Dis.* 1987;19:693-6.
 46. Hassan MM, Farghaly AM, Gaber NS, Nageeb HF, Hegab MH, Galal N. Parasitic causes of hepatomegaly in children. *J Egypt Soc Parasitol.* 1996;26:177-89.
 47. Baldisserotto M, Conchin CF, Soares Mda G, Araujo MA, Kramer B. Ultrasound findings in children with toxocariasis: report on 18 cases. *Pediatr Radiol.* 1999;29:316-9.
 48. Pereira FE, Musso C, Castelo JS. Pathology of pyogenic liver abscess in children. *Pediatr Dev Pathol.* 1999;2:537-43.
 49. Moreira-Silva SF, Pereira FE. Intestinal nematodes, *Toxocara* infection, and pyogenic liver abscess in children: a possible association. *J Trop Pediatr.* 2000;46:167-72.
 50. Rayes AA, Teixeira D, Serufo JC, Nobre V, Antunes CM, Lambertucci JR. Human toxocariasis and pyogenic liver abscess: a possible association. *Am J Gastroenterol.* 2001;96:563-6.
 51. Jeanfaivre T, Cimon B, Tolstuchow N, de Gentile L, Chabasse D, Tuchais E. Pleural effusion and toxocariasis. *Thorax.* 1996;51:106-7.
 52. Sakai K, Hirasawa Y, Hashimoto A. A case of toxocariasis with eosinophil-rich pleural effusion. *Nihon Kokyuki Gakkai Zasshi.* 2002;40:494-8.
 53. Ashwath ML, Robinson DR, Katner HP. A presumptive case of toxocariasis associated with eosinophilic pleural effusion: case report and literature review. *Am J Trop Med Hyg.* 2004;71:764.
 54. Buijs J, Egbers MW, Nijkamp FP. *Toxocara canis* induced airway hyperactivity in mice. *Agent Actions Suppl.* 1990;31:75-80.
 55. Paolillo F, Migliori C, Fornari M, Belloni C. Toxocariasi: descrizione di un caso [Toxocariasis: a case report]. *Pediatr Med Chir.* 1997;19:141-2. Italian.
 56. Buijs J, Borsboom G, van Gemund JJ, Hazebroek A, van Dongen PA, van Knapen F, et al. *Toxocara* seroprevalence in 5-year-old elementary schoolchildren: relation with allergic asthma. *Am J Epidemiol.* 1994;140:839-47.
 57. Radman NE, Archelli SM, Fonrouge RD, del V Guardis M, Linzitto OR. Human toxocarosis. Its seroprevalence in the city of La Plata. *Mem Inst Oswaldo Cruz.* 2000;95(3):281-5.