

Mono-invasion with *Toxocara canis* in children

*Placinta Gheorghe^{1,2}, MD, PhD, Associate Professor

¹Department of Infectious Diseases, Nicolae Testemitsanu State University of Medicine and Pharmacy

²Consultation and Diagnostic Center of Medical Parasitology and Tropical Diseases

Toma Ciorba Republican Hospital of Infectious Diseases, Chisinau, the Republic of Moldova

*Corresponding author: gheorghe.placinta@usmf.md. Received April 23, 2018; accepted June 22, 2018

Abstract

Background: Toxocariasis is a clinical notion that reflects human involvement with the *Toxocara* larvae in the second stage of development. Its typical syndromes are Larvae Migrans Visceralis, ocular toxocarosis, neurological form and occult form. The most common toxocariasis is asymptomatic, only eosinophilia and the positive serological result being the only manifestations of this helminth. The epidemiological examination and a detailed anamnesis of the patient can be helpful in establishing this diagnosis. Children are part of the risk group, especially because of the childhood habits, their undoubted attraction to puppies, and because of their low immune system.

Material and methods: The elaborated prospective-descriptive study presents the evolution features in a group of 94 children with *T. canis* mono-invasion in which were examined the clinical signs, important laboratory indices, the applied treatment and its influence.

Results: The study revealed the most common clinical signs and paraclinical changes in a group of 94 children with *T. canis* mono-invasion. Was examined the specific treatment by highlighting its influence on laboratory indices representative for this parasitosis.

Conclusions: The most common clinical signs were headache, dry cough and abdominal pain. The specific therapy for visceral chronic toxocariasis in children was far superior in clinical outcomes, this being reflected by maintaining ALT levels within the normal values demonstrating the direct involvement of larvae and toxocara toxins in the establishment and maintenance of hepatic cytolytic syndrome in children.

Key words: Toxocariasis in children, larva migrans visceralis.

Introduction

Lately, parasitic diseases have returned in force in medical practice putting major problems of diagnosis, treatment and evolution [1,2]. The geographical study of parasitosis as well as the high number of human diseases justify the involvement of substantial resources to prevent and exert effective control of these infections [3,4].

Toxocariasis is a term representing human infection caused by larvae of helminths of the genus *Toxocara* that parasites in dogs (*Toxocara canis*), cats (*Toxocara cati*) [5], and possible in horned animals (*Toxocara vitulorum*) and swine [6]. Definitive host is shown by the above-mentioned animals, but once they enter the human body it can lead to bad consequences.

Toxocara canis and *cati*, being the most common intestinal parasites have a variety of random hosts including humans, birds, pigs, rodents, monkeys and rabbits. The man is infected by the ingestion of *T. canis* or *T. cati* embryonic eggs. Larvae hatch in the intestine of the intermediate host without the ability to fully mature and remain throughout the infected period at the second stage of development. The degree of the intermediate host damage depends on the amount of larvae circulating through the bloodstream and the affected organs, as well as on the immune response of the host [7]. Of course, it is much more difficult to establish the diagnosis of Toxocariasis in those with whom the disease is asymptomatic or discrete, even if it can evolve for a long time, sometimes up to several decades [8].

Transmission to humans most often occurs through the ingestion of toxocara eggs. *Toxocara canis* has an ability to

produce about 200,000 eggs per day, and one gram of puppy feces can contain around 100,000 eggs per gram. However, eggs need a few weeks to stay out of the host to mature and become invasive, so recently eliminated eggs are not dangerous [9].

The basic classification of toxocarosis divides this pathology depending on the affected organ. Thus, there are two basic syndromes: Larvae Migrans Visceralis (LMV) where pathology occurs with major organs damage and Migrans Larvae Ocular (OLM) [10] where the disease is limited to damage of the eye and the optic nerve [11]. The asymptomatic and occult form has also been described [12].

Clinical syndrome of LMV may be acute or subacute with splenomegaly, hepatomegaly, gastrointestinal symptoms, skin manifestations, pulmonary involvement, and CNS involvement (this particular form was called Neurological Toxocariasis) [13] and eosinophilia [14].

The occult form occurs as a result of the development of non-specific symptoms due to the action of the parasite antigen in the host's immune system. Asymptomatic form is established when accidentally in patient without signs of typical damage are detected antibodies to *Toxocara* and eosinophilia [15].

Multiple studies in this area, although most of the time having contradictory results, had a common element: the distribution of *T. canis* and *T. cati* is global, with cases identified in very limited populations. The seroprevalence rate ranges from less than 10% [16,17] to more than 80% [18,19,20], increased seroprevalence being more common in economically underdeveloped countries or countries in

developing course[14,21]. Besides these well-known types, have also been discovered new varieties of *Toxocara* as *Toxocara malayasiensis* affecting domestic cats [22] and *T. lynx* infecting lynx [23]. However, there is no data on the involvement of these new types discovered in human damage.

Children, due to childhood habits (especially geophagia), poor personal hygiene, even if the children are part of families with a high income and good living standard, the tendency to contact with the animals, especially with puppies without parental supervision, leads to an increased risk of receiving toxocarosis[15].

Material and methods

A prospective descriptive study was developed with the inclusion of 94 children aged 4 to 18 years with no other associated parasitosis (ascaridiasis, oxyuriasis, giardiasis, etc.). The patients were examined both clinically, with developing the most common clinical and paraclinical signs, revealing the general blood counts, biochemical examination (ALT and AST), total IgE level, antibody titre to *T. canis*.

Results and discussion

The study involved 94 children with *Toxocara canis* monoinvasion. Duration of toxocara invasion ranged from 1 year to 9 years, in most children (70.1%) with a duration of 2 to 7 years.

Among the studied group the average age was 11.4 ± 0.47 years. Children aged 4-7 were 21 (22.3%), 8-12 years – 36 (38.3%) and 13-18 years – 37 (39.4%).

The bronchopulmonary form prevailed with the involvement of 32 children (34.0%) followed by the neurological form with 30 children (31.9%), the cutaneous form was discovered in 16 children (17.0%), the digestive form – in 10 children (10.5%), and in 6 cases (7.3%) other clinical forms were described.

The frequency of major signs encountered during the course of the disease in children in the studied group is shown in fig. 1. Clinical manifestations behaved with a variety of different intensity and frequency. The most frequent clinical manifestations in the studied group were headache and long-term cough, both in 33% of cases, followed with a decrease in percentage (from 25.5% to 20.3%) with hepatomegaly, vertigo, abdominal pain, diffuse liver changes on ultrasound exam, skin pruritus, sleep disturbances. The other 6 clinical signs with a decrease in percentage from 20% to 10%: maculo-papular rash, splenomegaly, neuropsychiatric disorders (impulsivity, inability to concentrate, poor memory, chronic apathy, etc.), physical asthenia and weight loss (fig. 1).

Clinical manifestations with an incidence of less than 10% in the course of chronic toxocarosis in children are shown in fig. 2. In 8.1% of cases of monoinvasion with *T. canis* were noted epileptiform seizures, signs of rhinitis and dyspnoea, in 6.8% of cases is described bronchopneumonia, in 5.4 cases – high level of ALT.

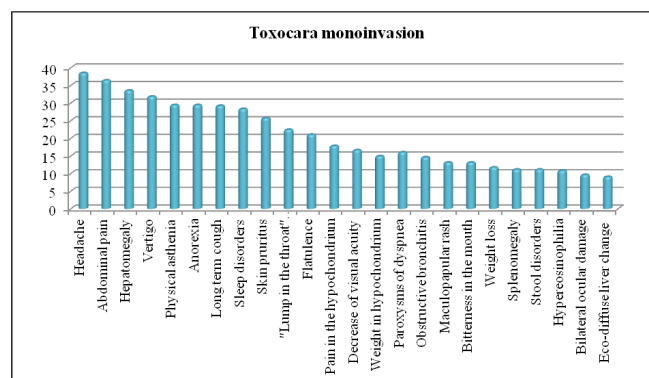


Fig. 1. Percentage distribution of the most common signs in children with chronic visceral toxocarosis, monoinvasion.

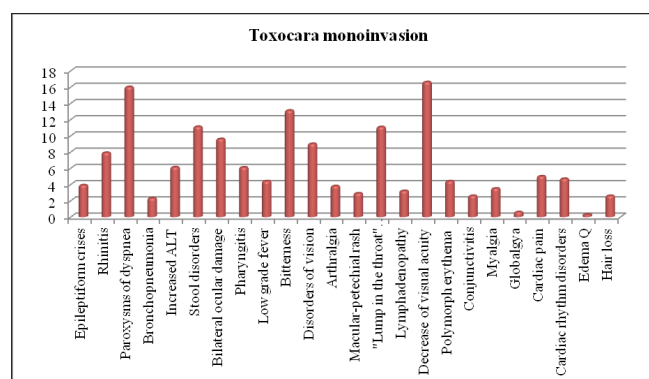


Fig. 2. Percentage distribution of the less common signs in children with chronic visceral toxocarosis, monoinvasion.

The specific treatment indicated in toxocarosis has been shown in most cases with benzimidazole derivatives with a 2-times daily intake of 10 mg / kg / body with duration of 10-14 days.

The number of leukocytes was not deviating from normal mean values, but significantly declined in patients with specific treatment from 6.8 ± 0.47 to 5.5 ± 0.47 ($P < 0.05$). Also, the number of erythrocytes increased compared to the values before the treatment, with statistical significance regardless of the specific treatment applied ($P < 0.001$). The percentages of the lymphocytes had minor decreases compared to the baseline in the patients regardless of the therapy applied; however, they remained above the mean values compared to the healthy ones. The percentage of eosinophils, starting from over-normal values compared to healthy subjects (6.3 ± 0.61 versus 1.8 ± 0.10 , $P < 0.001$), decreased regardless of the treatment applied to 3.7 ± 1.0 ; in the absence of this treatment – 3.1 ± 0.76 ($P < 0.05$).

In the group of children without specific treatment, ALT levels have increased significantly from baseline values and those seen in healthy individuals. In monoinvasion with *T. canis*, they increased from 23.8 ± 2.4 to 62.8 ± 14.2 ($P < 0.01$). These liver enzyme behavioral findings demonstrate the direct involvement of larvae and toxocara toxins in the hepatic cytolytic syndrome. At the same time, the ALT activity in the group with specific treatment remained close to the mean baseline values, no different from those seen in

healthy individuals, which prove the safety of antilarvaric treatment in children. Activity levels of the AST enzyme did not change during the different treatment regimens, and remained constant within the normal mean values.

Paradoxically, however, regardless of treatment, levels of antibodies to *T. canis* increased, averaging higher than those found up to treatment.

The total IgE level was in the medium of 302.2 ± 41.0 . Specific treatment had a beneficial effect on the evolution of total IgE, registering significantly lower values than baseline (145.4 ± 29.2 vs. 302.2 ± 41.0 , $P < 0.01$).

In order to identify the capacity of these children to form and maintain the postvaccinal response, randomly in every third child, with an average age of 9.18 ± 0.64 years, timely vaccinated according to the national vaccination schedule with three doses of the vaccine HepB, we tested the presence of anti-HBsAg in the serum. In these patients, the result was the titre of the protection antibodies below the detection limit, 1/3 of who were under the age of 7 years.

Because, as we mentioned, clinical manifestations were varied in intensity and frequency, the changes in the clinical picture during chronic toxocariasis in children were analyzed according to the percentage decrease of each symptom, shown as a percentage of the intensity expressed before the onset of treatment applied. The average percentage reduction in symptoms determined clinical effectiveness. Thus, clinical efficacy was noted in terms of diminishing or negating clinical signs: very pronounced – efficacy noted with a reduction of 75%-100% of the intensity of previous manifestations, pronounced – 50-75%, poorly pronounced – less than 50% and absence. As observed in the study group, more pronounced and poorly pronounced clinical efficacy was found, and the lack of clinical efficacy was found only in 17.0% of the 94 tested children ($P < 0.01$).

Out of the 94 children studied, antilarvaric specific treatment received 56 (59.6%) children and 38 (40.4%) did not receive this treatment. The very pronounced clinical efficacy in children with antilarvaric treatment was recorded in 16.1% of cases, whereas in the non-treated group only in 5.3% ($P < 0.05$). Significant clinical efficacy was found in 48.2% of the 56 treated versus 23.7% of the 38 without treatment ($P < 0.05$). And the percentage of those with specific treatment with poor clinical efficacy was higher – 23.2% versus 15.8%.

Lack of clinical efficacy was seen in 55.2% of children without specific therapy and only in 12.5% in those who received this therapy ($P < 0.001$).

The level of antibodies to *T. canis* in children in the investigated group receiving specific treatment decreased to 31 (55.4%) compared to 18 (47.4%) found in those without specific therapy. However, after the anti-toxocara treatment, it was noted that in approximately one third of the patients the antibody levels increased (39.2%), although most of these children had expressed clinical improvement.

The percentage of eosinophils also had a greater decrease in children with specific treatment – 66.9%. Among the children with specific treatment, the cumulative per-

centage in increase or maintenance at the same eosinophil values was 30.4%, compared to 71.1% in the non-specific anti-toxocara treated group ($P < 0.001$).

Total IgE concentration also declined more frequently among patients with anti-toxocara therapy – 33.9% of cases, compared with 26.3% in children without anti-toxocara treatment ($P < 0.001$). The percentage of patients who did not experience essential changes was quite high, ranging from 42.3% to 48.2% ($P < 0.05$).

Therefore, clinical manifestations of chronic toxocariasis in children are very numerous (more than 40 clinical signs), varying in intensity and incidence, and the most common of these are headache and dry cough, both of which are recorded in 33.0% of cases. In the investigated group hyper-eosinophilia is recorded in every 6-7th child, with a percentage of 13.5%. Summarizing the correlation of the laboratory indices in chronic toxocariasis in children, there is a decrease in the number of leukocytes, especially with applied specific antilarvar therapy ($P < 0.05$). Parasitic offensive action on laboratory indices was evident, demonstrating high levels of total IgE (302.2 ± 41.0 $P < 0.05$) and eosinophils (6.27 ± 0.61 , $P > 0, 05$). Prolonged invasive parasitic action in children keeps the immune system permanently alert, contributing to the depletion of postvaccinal response formation and maintenance capacity.

Specific treatment significantly reduced the percentage of eosinophils and total IgE ($P < 0.01$). The increase in ALT from 23.8 ± 2.4 to 62.8 ± 14.2 ($P < 0.01$) in the absence of specific treatment, and maintenance of this enzyme within the normal range throughout the duration of the specific therapy demonstrates the direct involvement of the larvae and toxocara toxins in the development of hepatic cytolysis syndrome in children. The antibody levels to *T. canis*, regardless of the treatment applied, tended to increase. The main laboratory indices that directly reflect parasitic activity (the level of antibodies, total IgE and percentage of eosinophils) had a higher positive change frequency in the specific treated group ($P < 0.05$). However, in approximately 1/3 of the children with anti-toxocara treatment the antibody titres increased (to 39.2%) and total IgE remained unchanged in 48.2% of cases, although most of them had apparent clinical improvement.

Conclusions

1. Clinical manifestations during chronic toxocariasis in children are very numerous (over 40 clinical signs); varying in intensity and incidence, the most common of them being headache, dry cough and abdominal pain. Blood hyper-eosinophilia is recorded in every 6-7th child at a rate of 13.5%.

2. The specific therapy in chronic visceral toxocariasis in children had a much higher clinical rate, being reflected by maintaining the ALT level within the limits of normal values demonstrating the direct involvement of larvae and toxocara toxins in the occurrence and maintenance of hepatic cytolysis syndrome in children.

3. Specific treatment significantly reduced the intensity of clinical manifestations, the percentage of eosinophils and

total IgE ($P < 0.01$), much less acting on the level of antibodies against *Toxocara canis*.

4. Toxocariasis in children takes the form of a complex evolutionary chronic process with periods of remissions, relapses and exacerbations, which implies the need for further surveillance of these children, if necessary with the involvement of other specialists (neurologist, ophthalmologist, etc.).

References

- Balta Madalina, et al. Toxocaroză pulmonară [Pulmonary toxocariasis]. Revista Medicală Română. 2010;57(4):280-3. Romanian.
- Despommier D. Toxocariasis: clinical aspects, epidemiology, medical ecology, and molecular aspects. Clin Microbiol Rev. 2003 April;16(2):265-72.
- Cretu Carmen-Michaela. Toxocara Spp și toxocaroză umană [Toxocara Spp and human toxocariasis]. București: Carol Davila; 2002. 230 p. Romanian.
- Gherghina I, et al. Parazitoze în pediatrie [Parasitosis in pediatrics]. Medicina Modernă. 2006;13(8):416-26. Romanian.
- Espinoza YA, Huapaya PH, Roldani WH, Jimenez S, Arce Z, Lopez E. Clinical and serological evidence of Toxocara infection in school children from Morrope district, Lambayeque, Peru. Rev Inst Med Trop S Paulo. 2008;50:101-5.
- Despommier D. Toxocariasis: clinical aspects, epidemiology, medical ecology, and molecular aspects. Clin Microbiol Rev. 2003;16:265-72.
- Won KY, Kruszon-Moran D, Schantz PM, et al. National seroprevalence and risk factors for zoonotic Toxocara spp. infection. Am J Trop Med Hyg. 2008;79(4):552-7.
- Glickman LT, Magnaval JF, Domanski LM, Shofer FS, Lauria SS, Gottstein B, Brochier B. Visceral larva migrans in French adults: a new disease syndrome? Am J Epidemiol. 1987;125(6):1019-34.
- Fillaux J, Magnaval JF. Laboratory diagnosis of human toxocariasis. Vet Parasitol. 2013;193(4):327-36. doi: 10.1016/j.vetpar.2012.12.028.
- Zibaei M, Sadjjadi SM, Karamian M, Uga S, Oryan A, Jahadi-Hosseini SH. A comparative histopathology, serology and molecular study, on experimental ocular toxocariasis by Toxocara cati in Mongolian gerbils and Wistar rats. Biomed Res Int. 2013;2013:109580. doi: 10.1155/2013/109580.
- Woodhall D, Starr MC, Montgomery SP, et al. Ocular toxocariasis: epidemiologic, anatomic, and therapeutic variations based on survey of ophthalmic subspecialists. Ophthalmology. 2012;119(6):1211-7.
- Woodhall DM, Fiore AE. Toxocariasis: a review for pediatricians. J Pediatric Infect Dis Soc. 2014;3(2):154-9. doi: 10.1093/jpids/pit066.
- Kazek B, Jamroz E, Mander M, Bierzyńska-Macyszyn G, Kluczevska E, Marszał E. The cerebral form of toxocarosis in a seven-year-old patient. Fol Neuropathol. 2006;44:72-76.
- Roldán WH, Espinoza YA, Atúnchar A, Ortega E, Martínez A, Saravia M. Frequency of eosinophilia and risk factors and their association with Toxocara infection in schoolchildren during a health survey in the North of Lima, Peru. Rev Inst Med Trop São Paulo. 2008;50(5):273-8. doi: 10.1590/S0036-46652008000500005.
- Kroten A, Toczyłowski K, Oldak E, Sulik A. Toxocarosis in children: poor hygiene habits and contact with dogs is related to longer treatment. Parasitol Res. 2018;117(5):1513-9. doi: 10.1007/s00436-018-5833-7. Epub 2018 Mar 20.
- Iddawela D, Ehambaram K, Atapattu D, Pethiyagoda K, Bandara L. Frequency of toxocariasis among patients clinically suspected to have visceral toxocariasis: a retrospective descriptive study in Sri Lanka. J Parasitol Res. 2017;2017:4368659. doi: 10.1155/2017/4368659.
- Hosseini-Safa A, Mousavi SM, Bahadoran Bagh Badorani M, Ghatreh Samani M, Mostafaei S, Yousofi Darani H. Seroepidemiology of toxocariasis in children (5-15yr Old) referred to the Pediatric Clinic of Imam Hossein Hospital, Isfahan, Iran. Iran J Parasitol. 2015;10(4):632-7.
- Placinta G, Stirbu T, Tovba L. Evolution of the toxocariasis monoinvasion in comparison with the toxocariasis associated with other parasites in children. The Moldovan Medical Journal. 2018;61(1):36-41. doi: 10.5281/zenodo.1186196.
- Tania OR, Camilo R, Rafael H, Linda GB, Galia Sh. Identification of Toxocara spp. eggs in dog hair and associated risk factors. Vet World. 2017 Jul;10(7):798-802. doi: 10.14202/vetworld.2017.798-802.
- Hotez PJ, Wilkins PP. Toxocariasis: America's most common neglected infection of poverty and helminthiasis of global importance? Plos Negl Trop Dis. 2009;3(3):e400. doi: 10.1371/journal.pntd.0000400.
- Rai SK, Uga S, Ono K, Nakanishi M, Shrestha HG, Matsumura T. Seroepidemiological study of Toxocara infection in Nepal. Southeast Asian J Trop Med Public Health. 1996;27(2):286-90.
- Gibbons LM, Jacobs DE, Sani RA. Toxocara malaysiensis n. sp. (Nematoda: Ascaridoidea) from domestic cat (Felis catus Linnaeus, 1758). J. Parasitol. 2001;87(3):660-5.
- Macchioni G. A new species. Toxocara lyncis, in the caracal (Lynx caracal). Parasitology. 1999;41(4):529-32.

