

## Typical and variant anatomy of the palmar arteries during perinatal period of ontogenesis

\*Oleksandr Slobodian, Volodymyr Guzak

Department of Anatomy, Clinical Anatomy and Operative Surgery  
Bukovinian State Medical University, Chernivtsi, Ukraine

Authors' ORCID iDs, academic degrees and contribution are available at the end of the article

\*Corresponding author: slobodjanaleksandr@ukr.net

Manuscript received April 21, 2020; revised manuscript May 29, 2020; published online 10, 2020

### Abstract

**Background:** The value of the study is finding typical and variant anatomy of the palmar arteries during fetal and early neonatal periods of ontogenesis, which is important while performing amputations, osteosynthesis, resection of bones followed by further prosthetics, as well as during catheterization of the arterial branches in order to deliver diagnostic and therapeutic substances in fetuses, neonates and infants.

**Material and methods:** The study was performed on 51 specimens of dead fetuses (from 4 to 10 months) and 10 neonates of both sexes died due to the causes not related to diseases of the muscular-skeletal system and without external signs of anatomical defects, without visual macroscopic deviations or anomalies from the normal structure of the upper limbs.

**Results:** During the perinatal period of ontogenesis the typical anatomy of the palmar arteries (formation of the superficial palm arch) is found in 62% of cases, the variant one – in 38%. The variant structure of the palmar artery during the perinatal period of ontogenesis is divided into closed and open-ended (continuous superficial palmar arch is absent) arteries. In their turn, closed palmar arteries include anastomosis formation in the form of an arch and without arch formation. In case of open-ended arteries the palm is supplied with blood through the branches from two or three arteries. The older the fetus is, the greater percentage ratio of the typical structure of the palmar artery becomes (9% of cases more) in comparison with other forms. Moreover, the open-ended artery system increases when the palmar surface is supplied with blood from the three arteries (28% of observations more) in comparison with those cases when the palmar surface is supplied through the two arteries. During the perinatal period of ontogenesis the amount of the variant arterial structure is more found on the left palm (25%) compared to the right one (17.5%).

**Conclusions:** Detection of the typical and variant anatomy of the palmar arteries is a morphological precondition to introduce new methods of performing radical and reconstructive-restorative surgeries on the hand.

**Key words:** arteries, palm, anatomy, fetus, neonate.

### Cite this article

Slobodian O, Guzak V. Typical and variant anatomy of the palmar arteries during perinatal period of ontogenesis. *Mold Med. J.* 2020;63(2):44-48. doi: 10.5281/zenodo.3866021.

### Introduction

Both external and internal factors influencing the processes of growth, development and formation of the body, its parts and organs, stipulate certain human development produce certain effect on the formation of the circulatory system. Disorders during morphogenesis in general and angiogenesis in particular, can be caused by heredity, hormonal changes, xenobiotic effect etc. [1-5]. Modification of the structure and location of the arterial system on the upper limb demonstrates a great amount of variants. Complicated and numerous processes of the embryonic development transformations make up their etiological basis [6-9]. Different variants of arterial origin in the upper limb, relocation of the point of its beginning, variants of location, size, branching in the number of abductor branches or complete lack of vessels are found concerning certain arteries [6].

Considering the fact that arteries and veins are different vessels in their morphology and physiology, they have been

recently believed to be formed from the primitive blood vessels according to the changes of hemodynamics and physiological factors. Though, original studies indicate that arterial-venous identity is stipulated genetically [10, 11].

Anatomical evidences concerning blood supply of the hand are numerous and do not differ one from another substantially. General recent clinical studies deal with the issues of the variant anatomy of the arterial bed of the hand mainly, and less – of its veins [12-17].

More comprehensive investigation of the blood vessels of the upper limbs will help to avoid errors in surgical and traumatological practice essentially during amputations, osteosynthesis, resection of the bones on the limbs followed by their prosthetics, and during catheterization of the arterial branches in order to deliver diagnostic and therapeutic substances etc. [14, 18, 19]. All the above stipulates the necessity to specify the current data and to find new ones concerning anatomical structure of the vascular network of the human hand during the perinatal period of ontogenesis

[20-22]. Our objective was to find anatomical peculiarities of the typical and variant structure of the palmar arteries during fetal and early neonatal periods of ontogenesis.

### Material and methods

The study was performed on 51 specimens of dead fetuses (from 4 to 10 months) and 10 neonates of both sexes died due to the causes not related to diseases of the muscular-skeletal system and without external signs of anatomical defects, without visual macroscopic deviations or anomalies from the normal structure of the upper limbs. The adequate anatomical methods were applied during research: macrodissection, injection of the blood vessels, radiography, making topographic-anatomical sections, morphometry, and statistical analysis. The vessels were injected with a special mixture on the basis of red lead. After the specimens of dead fetuses and neonates were preserved, macro- and microdissection of the palmar arteries was performed by means of a forceps and scissors. By means of the pen «AIHFIO ZENTEL» red gel was applied on the arteries in order to examine syntopy of the arterial and adjacent structures better. It enabled to get accurate differentiation of the major arteries and their branches from other palm structures.

The study is performed keeping to the main regulations of the Declaration of Helsinki as a statement of ethical principles for medical research involving human subjects (1964-2000) and the Order of the Ministry of Health of Ukraine No 690, dated 23.09.2009. It is a fragment of a comprehensively planned initiated scientific-research study conducted by *M. G. Turkevych* Department of Human Anatomy, and Department of Anatomy, Clinical Anatomy and Operative Surgery, Bukovinian State Medical University: "Regularities of the Genital-Age Structure and Topographic-Anatomical Transformations of the Body Organs and Structures during the Ante- and Postnatal Periods of Ontogenesis".

### Results and discussion

During the perinatal period of ontogenesis the final portion of the ulnar artery accompanied by two veins is found to pass along the ulnar sulcus moving to the wrist channel of the elbow side. The ulnar artery passing to the palm of the hand joins the lateral side of the pisiform bone, is located on the short palmar muscle and covered with the fascial thickening of the flexor retinaculum. It goes directly along the lateral side of the short flexor muscle of the little finger included into the tenor muscles of the little finger. The ulnar artery on the hand is located in the loose cellular tissue of the hand middle receptacle on the tendons of the long flexors, and it is covered by the palmar aponeurosis superiorly. When the fourth palmar digital artery emerges from the final portion of the ulnar artery, the latter becomes of a radial direction joining the final part of the tenor muscles of the thumb forming the arch, that is, superficial palmar arch. The latter one forms anastomosis with the superficial palmar branch of the radial artery. Three general palmar digital arteries pass from the convex part of the arch. The

final portion of the superficial palmar branch of the radial artery extends the major artery of the thumb and the radial artery of the forefinger. Such kind of structure assuming the formation of the superficial palmar arch is called typical one (fig. 1). The typical structure of the palmar arteries with the formation of the superficial palmar arch is found in 62% of cases during the perinatal period [4, 9, 12, 13]. At the same time, the arch is found to be closed in all the observations (anastomosis formation). It is significant that with the term of fetuses the number of cases of the superficial palmar arch formation increases. Thus, it is found in 61% of observations during the second trimester of the intrauterine development, but in the third trimester and during the neonatal period it is found in 70%.

The variant structure of the palmar arteries is found in 38% of cases during the perinatal period of ontogenesis. The structural variants include both closed and open-ended arches, and blood supply of the palm through the ulnar and additional arteries.

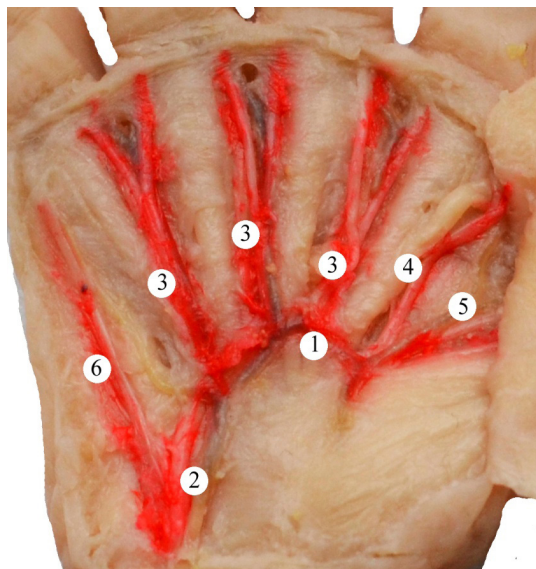
Table 1

Variant structure of the palmar arteries during the perinatal period of ontogenesis

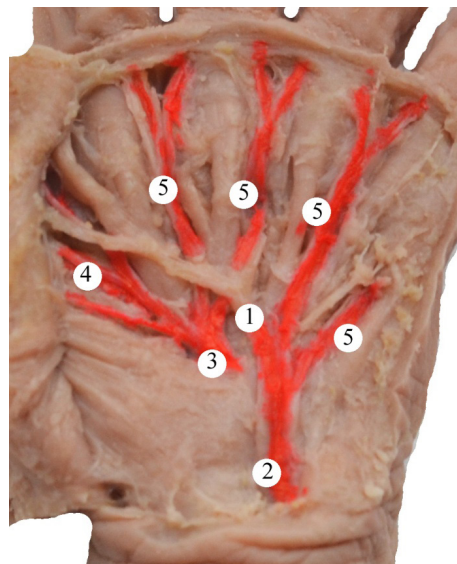
Variant structure of the palmar arteries (38%)			
Formation of the closed palmar arteries (13%)		Formation of the open-ended palmar arteries (25%)	
Anastomosis in the form of arch (5%)	Anastomosis without arch formation (8%)	Blood supply of the palm from the two sources (17%)	Blood supply of the palm from the three sources (8%)

In 3% of cases the palmar arteries form anastomosis in the form of an arch between the ulnar artery and the major artery of the thumb or the radial artery of the forefinger (fig. 2). At the same time, on the level of the final tenor part the ulnar artery divides into two general palmar arteries, one of which passes in the direction to the elbow edge of the palmar portion of the little finger, and another one – in the fourth interdigital space and to the anastomosis arch. The superficial palmar branch of the radial artery divided into the three final branches on the level of the final tenor portion: two general palmar digital arteries passing in the direction to the second and third interdigital spaces, and the major artery of the thumb, from which a branch emerges to the radial edge of the palmar surface of the forefinger.

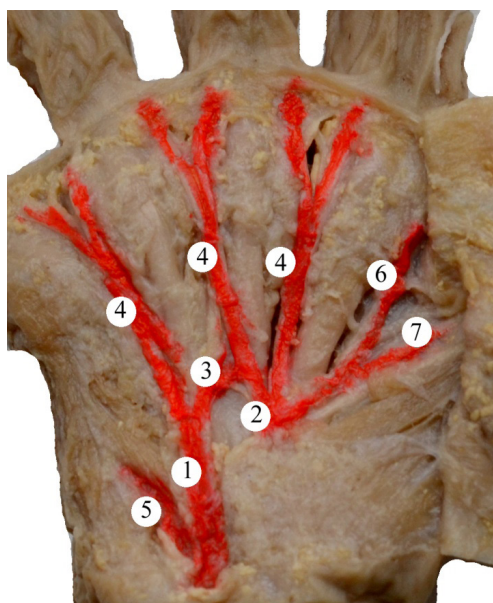
In 8% of cases during the perinatal period of ontogenesis the palm is supplied with blood by means of the two arteries forming anastomosis without arch formation (fig. 3). The ulnar artery close to the final edge of the holder of the flexor muscles divides into three branches: two general palmar digital arteries and anastomosing branch. One general palmar digital artery passes along the palmar surface of the hypotenor to the elbow edge of the palmar surface of the little finger, and another one – into the fourth interdigital space. Anastomosing branch forms anastomosis between the third and fourth general palmar digital arteries. The radial part of the palm is supplied with blood from the system of the radial artery. The superficial palmar branch of the ra-



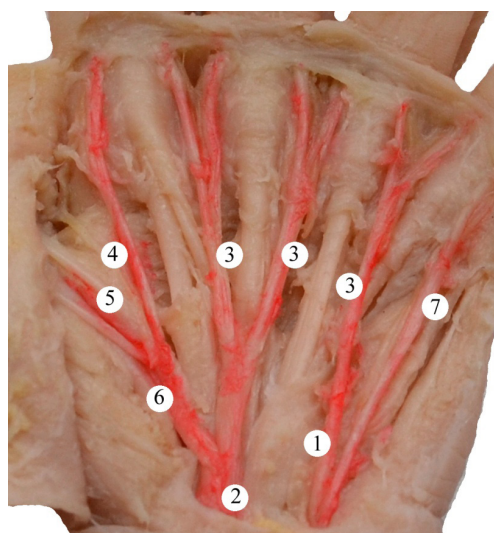
**Fig. 1.** Palmar surface of the right hand of a neonate (skin, subcutaneous tissue, palmar aponeurosis are removed). Macrospecimen. Magnified by 3.5<sup>x</sup>:  
 1 – superficial palmar arch, 2 – ulnar artery, – general palmar digital arteries, 4 – radial artery of the forefinger, 5 – major artery of the thumb, – fourth general palmar digital artery.



**Fig. 2.** Palmar surface of the left hand of a fetus, 310.0 mm of the parietal-calcaneal length (skin, subcutaneous tissue, palmar aponeurosis are removed). Macrospecimen. Magnified by 3.8<sup>x</sup>:  
 1 – arch-anastomosis between the ulnar artery and the major artery of the thumb, 2 – ulnar artery, 3 – superficial palmar branch of the radial artery, 4 – major artery of the thumb, 5 – general palmar digital arteries.



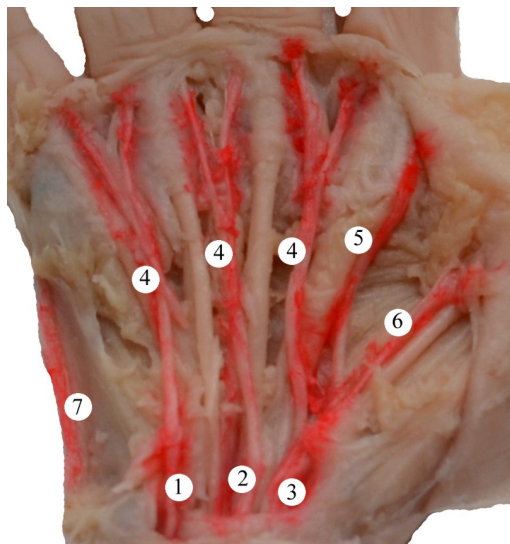
**Fig. 3.** Palmar surface of the right hand of a neonate (skin, subcutaneous tissue, palmar aponeurosis are removed). Macrospecimen. Magnified by 2.8<sup>x</sup>:  
 1 – ulnar artery, 2 – superficial palmar branch of the radial artery, 3 – branch-anastomosis between the second and third general palmar digital arteries, 4 – general palmar digital arteries, 5 – fourth general palmar digital artery, 6 – radial artery of the forefinger, 7 – major artery of the thumb.



**Fig. 4.** Palmar surface of the left hand of a fetus, 320.0 mm of the parietal-calcaneal length (skin, subcutaneous tissue, palmar aponeurosis are removed). Macrospecimen. Magnified by 3.8<sup>x</sup>:  
 1 – ulnar artery, 2 – superficial palmar branch of the radial artery, 3 – general palmar digital arteries, 4 – radial artery of the forefinger, 5 and 6 – major artery of the thumb, 7 – fourth general palmar digital artery.

dial artery close to the final end of the tenor divides into two general palmar digital arteries passing in the direction to the second and third interdigital spaces and the major artery of the thumb.

During the perinatal period the system of open-ended arteries (continuous superficial palmar arch is absent) is found in 25% of cases. The palm is supplied with blood through the two or three arteries. In 17% of cases the pal-



**Fig. 5. Palmar surface of the right hand of a fetus, 250.0 mm of the parietal-calcaneal length (skin, subcutaneous tissue, palmar aponeurosis are removed). Macrospecimen. Magnified by 4.5<sup>x</sup>:**  
 1 – ulnar artery, 2 – accompanying artery of the median nerve, 3 – superficial palmar branch of the radial artery, 4 – general palmar digital arteries, 5 – radial artery of the forefinger, 6 – major artery of the thumb, 7 – fourth general palmar digital artery.

mar surface of the hand is supplied with blood through the branches of the ulnar artery and superficial palmar branch of the radial artery (fig. 4). In these cases the final portion of the ulnar artery divides into two general palmar digital arteries. One of them passes in the direction to the elbow edge of the palmar surface of the little finger, and the other one – to the fourth interdigital space. The superficial palmar branch of the radial artery gives two general palmar digital arteries and the major artery of the thumb. General palmar digital arteries pass in the direction to the second and third interdigital spaces. The major artery of the thumb branches to the radial edge of the palmar surface of the forefinger.

In 8% of cases the palm is supplied with blood through the branches from the three arteries: ulnar, accompanying artery of the median nerve, superficial palmar branch of the radial artery (fig. 5) [15, 16]. The final portion of the ulnar artery divides into two general palmar digital arteries. One of them passes in the direction to the elbow edge of the palmar surface of the little finger, and the other one – to the fourth interdigital space. The accompanying artery of the median nerve is located on the palm between the final portion of the ulnar artery and superficial palmar branch of the radial artery. It extends under the holder of the flexor muscles together with the median nerve. It passes into the general palmar digital artery on the palmar surface of the hand in the direction to the third interdigital space. The superficial palmar branch of the radial artery close to the final portion of the tenor muscles of the thumb divides into the general palmar digital artery passing in the direction to the second interdigital space, and the major artery of the thumb from which the branch to the radial edge of the palmar surface of the forefinger emerges.

With the term of fetuses the percentage ratio of the typical structure of the closed superficial palmar arches increases (9% of cases more) in comparison with the variant forms. In the third trimester of the intrauterine development and during the neonatal period the cases of formation of the superficial palmar arches in the form of arcades convex in the direction of fingers increase (6% of cases more) compared to the second trimester. Though, the number of cases when there is anastomosing branch between the third and fourth general palmar digital arteries decreases with the term from 10.5% of cases (the second trimester of the intrauterine development) to 4% (the third trimester of the intrauterine development and during the neonatal period). The number of cases when the palm is supplied with blood from the system of the open-ended arteries (continuous superficial palmar arch is absent) during the perinatal period of ontogenesis is practically similar.

In the second trimester of the intrauterine development the variant structure of the open-ended arteries when the palmar surface of the hand is supplied with blood from the system of two arteries is found in 78% of cases, in the third trimester and during the neonatal period – 50%. That is, the percentage decreases contrary to the open-ended arteries when the palmar surface is supplied with blood from the system of the three arteries – it increases from 22% of cases to 50% respectively [17].

During the perinatal period of ontogenesis the greater amount of variant structure of the arteries is found on the left palm than on the right one – 25% and 17.5% respectively. Although during the perinatal period of ontogenesis this peculiarity changes: the greater number of structural variants of the arteries on the left palm is found in the second trimester, but in the third trimester and during the neonatal period – on the right one.

### Conclusions

1. During the perinatal period of ontogenesis the typical anatomy of the palmar arteries (formation of the superficial palm arch) is found in 62% of cases, the variant one – in 38%.

2. The variant structure of the palmar artery during the perinatal period of ontogenesis is divided into closed and open-ended (continuous superficial palmar arch is absent) arteries. In their turn, closed palmar arteries include anastomosis formation in the form of an arch and without arch formation. In case of open-ended arteries the palm is supplied with blood through the branches from two or three arteries.

3. With the term of fetuses the percentage ratio of the typical structure of the palmar artery increases (9% of cases more) in comparison with other forms. Moreover, the open-ended artery system increases when the palmar surface is supplied with blood from the three arteries (28% of observations more) in comparison with those cases when the palmar surface is supplied through the two arteries.

4. During the perinatal period of ontogenesis the amount of the variant arterial structure is more found on the left palm (25%) compared to the right one (17.5%).

## References

- Bianconi SE, Conley SK, Keil MF, et al. Adrenal function in Smith-Lemli-Opitz syndrome. *Am J Med Genet A*. 2011;155-A(11):2732-8. doi: 10.1002/ajmg.a.34271.
- Crépeaux G, Grova N, Bouillaud-Kremarik P, Sikhayeva N, Salquière G, Rychen G, et al. Short-term effects of a perinatal exposure to a 16 polycyclic aromatic hydrocarbon mixture in rats: assessment of early motor and sensorial development and cerebral cytochrome oxidase activity in pups. *Neurotoxicology*. 2014 Jul;43:90-101. doi: 10.1016/j.neuro.2014.03.012.
- Kovalenko-Klychkova NA, Kenis VM, Klychkova IYU. Poroki razvitiia kistei i stop pri sindrome Smita-Lemli-Opittsa [Congenital malformations of hands and feet in Smith-Lemli-Opitz syndrome]. *Travmatologiya i ortopediya Rossii [Traumatol Orthop Russia]*. 2013;3(69):143-7. Russian.
- Haladaj R, Wysiadecki G, Dudkiewicz Z, Polguy M, Topol M. Persistent median artery as an unusual finding in the carpal tunnel: its contribution to the blood supply of the hand and clinical significance. *Med Sci Monit*. 2019;25:32-9. doi: 10.12659/MSM.912269.
- Sultanov DD, Karimov TN. Revaskularizatsiya pri distal'nykh porazheniyakh arterii verkhnikh konechnostei [Revascularization in distal lesions of the arteries of the upper limbs]. *Vestnik Avitsenny [Avicenna Bull]*. 2012;2(51):167-73. Russian.
- Bidarkotimath S, Avadhani R, Kumar A. An anatomical study of primary pattern of arteries of upper limb with relevance to their variations. *NUJHS*. 2012;2(1):8-14.
- Bidarkotimath S, Avadhani R, Kumar A. Primary pattern of arteries of upper limb with relevance to their variations. *Int J Morphol*. 2011;29(4):1422-8. doi: 10.1055/s-0040-1703547.
- Shubha R, Sudarshan Babu KG, Mekala D, Jeyanthi K, Lalitha C. An anatomical study of variations in termination of brachialartery: embryological basis and clinical implication. *J Dent Med Sci (IOSR)*. 2013;9(1):68-77.
- Singla RK, Sharma R, Sharma R, Sharma T. Superficial brachial artery with its high division. *JNMA J Nepal Med Assoc*. 2012 Jul-Sep;52(187):138-41.
- Aitsebaomo J, Portbury AL, Schisler JC, Patterson C. Brothers and sisters: molecular insights into arterial-venous heterogeneity. *Circ Res*. 2008;103:929-39. doi: 10.1161/CIRCRESAHA.108.184937.
- Tsutom Kume. Specification of arterial, venous, and lymphatic endothelial cells during embryonic development. *Histol Histopathol*. 2010 May;25(5):637-46. doi: 10.14670/hh-25.637.
- Baytinger VF, Golubev IO, Shmatov SV. Klinicheskaia anatomii kisti. Chast' 1 [Clinical anatomy of a hand. Part 1]. *Voprosy rekonstruktivnoi i plasticheskoi khirurgii [Issues Reconstr Plast Surg]*. 2010;4(35):29-40. Russian.
- Baytinger VF, Golubev IO. Klinicheskaya anatomiya kisti. Chast' 2) [Clinical anatomy of a hand. Part 2]. *Voprosy rekonstruktivnoi i plasticheskoi khirurgii [Issues Reconstr Plast Surg]*. 2011;1(36):44-56. Russian.
- Deykalo VP, Tolstik AN, Boloboshko KB. Klinicheskaia anatomii kisti i khirurgicheskie dostupy: posobie [Clinical anatomy of the hand and surgical access: textbook]. Vitebsk: VGMU; 2013. 123 p. Russian.
- Menshawi K, Mohr JP, Gutierrez J. A functional perspective on the embryology and anatomy of the cerebral blood supply. *J Stroke*. 2015;17(2):144-58. doi: 10.5853/jos.2015.17.2.144.
- Gubochkin NG, Shapovalov VM, Zhigalo AV, Umnikov AS. Osobennosti krovosnabzheniya ladonnoi poverkhnosti kisti [Features of blood supply to the palmar surface of the hand]. *Travmatologiya i ortopediya Rossii [Traumatol Orthop Russia]*. 2008;2(48):26-7. Russian.
- Ritterband-Rosenbaum A, Herskind A, Li X, Willerslev-Olsen M, Olsen MD, Farmer SF, et al. A critical period of corticomuscular and EMG-EMG coherence detection in healthy infants aged 9-25 weeks. *J Physiol*. 2017 Apr 15;595(8):2699-713. doi: 10.1113/JP273090.
- Gurkov A, Lobov G, Gurevich K. Krovotok v krupnykh sosudakh predplech'ia i mikrososudakh kisti u patsientov na programmnom gemodialize [Blood flow in large vessels of the forearm and microvessels of the hand in patients on program hemodialysis]. *Vrach [Doctor]*. 2012;(6):64-7. Russian.
- Karimov TN, Sultanov DD, Khodzhayev FM. Priamye i nepriamye metody revaskularizatsii pri distal'nykh porazhenii arterii verkhnikh konechnostei [Direct and indirect methods of revascularization in distal lesions of the arteries of the upper limbs]. *Vestnik Tadzhičskogo natsional'nogo universiteta. Seriya estestvennykh nauk [Bulletin of the Tajik National University. Series of natural sciences.]*. 2014;1-2(130):231-8. Russian.
- Guéro S. Developmental biology of the upper limb. *Hand Surg Rehabil*. 2018 Oct;37(5):265-74. doi: 10.1016/j.hansur.2018.03.007.
- Huzak VD, Slobodian OM. The method of anatomical study of the fetal palmar structures. In: *Natural Science Readings*; 2017 May 18-21; Bratislava, Slovakia. Bratislava; 2018. p. 32-33.
- Mohammadi-Nejad AR, Mahmoudzadeh M, Hassanpour MS, Wallois F, Muzik O, Papadelis C, et al. Neonatal brain resting-state functional connectivity imaging modalities. *Photoacoustics*. 2018 Feb 2;10:1-19. doi: 10.1016/j.pacs.2018.01.003.

## Authors' ORCID iDs and academic degrees

Oleksandr Slobodian, MD, PhD, Professor – <https://orcid.org/0000-0002-4402-8457>.

Volodymyr Guzak, MD, PhD Applicant – <https://orcid.org/0000-0002-4102-1727>.

## Authors' contribution

OS designed the trial and revised the manuscript critically; VG collected the data, drafted the first manuscript. Both authors revised and approved the final version of the manuscript.

## Funding

The study was supported by Bukovinian State Medical University, Chernivtsi, Ukraine. The authors are independent and take responsibility for the integrity of the data and accuracy of the data analysis.

## Ethics approval and consent to participate

The research protocol No 02 of February 20, 2020 was approved by the Research Ethic Board of Bukovinian State Medical University, Chernivtsi, Ukraine.

## Conflict of Interests

The authors have no conflicts of interests to declare.