

UDC 616.314.18-002-089.873-74-076.5-092.9

<https://doi.org/10.26641/2307-0404.2019.4.189606>

**Yu. Khotimska<sup>1</sup>,**  
**I. Kovach<sup>1</sup>,**  
**Kh. Buniatian<sup>1</sup>,**  
**L. Kravchenko<sup>1</sup>,**  
**S. Varzhapetian<sup>2</sup>**

## COMPARATIVE ANALYSIS OF THE EFFECT OF TRICALCIUM SILICATE CEMENT AND MINERAL TRIOXIDE AGGREGATE ON THE CELLULAR COMPOSITION OF THE PULP AFTER THE VITAL AMPUTATION IN EXPERIMENTAL ANIMALS

SE «Dnipropetrovsk medical academy of Health Ministry of Ukraine»<sup>1</sup>

Department of pediatric dentistry

V. Vernadsky str., 9, Dnipro, 49044, Ukraine

SE «Zaporizhzhia medical academy of postgraduate education of the Ministry of Health of Ukraine»<sup>2</sup>

Department of surgical and preventive dentistry

Vintera bul., 20, Zaporizhzhia, 69000, Ukraine

ДЗ «Дніпропетровська медична академія МОЗ України»<sup>1</sup>

кафедра дитячої стоматології

(зав. – д. мед. н., проф. І.В. Ковач)

вул. В. Вернадського, 9, Дніпро, 49044, Україна

ДЗ «Запорізька медична академія післядипломної освіти МОЗ України»<sup>2</sup>

кафедра хірургічної профілактичної стоматології

бул. Вінтера, 20, Запоріжжя, 69000, Україна

e-mail: khotimskaya@ukr.net

**Цитування:** Медичні перспективи. 2019. Т. 24, № 4. С. 145-153

**Cited:** Medicni perspektivi. 2019;24(4):145-153

**Key words:** pulpitis, tricalcium silicate, mineral trioxide aggregate, histology, experiment

**Ключові слова:** пульпіт, трикальцій силікат, мінерал триоксид агрегат, гістологія, експеримент

**Ключевые слова:** пульпит, трикальция силикат, минерал триоксид агрегат, гистология, эксперимент

**Abstract.** Comparative analysis of the effect of tricalcium silicate cement and mineral trioxide aggregate on the cellular composition of the pulp after the vital amputation in experimental animals. Khotimska Yu., Kovach I., Buniatian Kh., Kravchenko L., Varzhapetian S. The purpose of the study was to determine the effect of tricalcium silicate cement on the protective process of pulp in the treatment of reversible pulpitis. There was carried out an experiment on 3-month-old male rabbits to study morphofunctional changes in the pulp tissue with modeling of reversible pulpitis followed by vital amputation with coating of the pulp with tricalcium silicate (8 animals, study group) and mineral trioxide aggregate (MTA) (8 animals, comparison group). In 2 and 6 weeks dental tissues were fixed by 10% formalin solution and after decalcification and done routine procedures, histological sections were made, stained with hematoxylin and eosin. After the application of tricalcium silicate cement in 2 weeks, the odontoblast density changed to  $3.92 \pm 1.03 \times 10^3 / \text{mm}^2$  from  $8.3 \pm 1.02 \times 10^3 / \text{mm}^2$  of cell density in the intact group. The number of neutrophils also plays a big role in the regeneration of inflamed pulp. Thus, in 2 weeks the number of neutrophils made up  $6.39 \pm 2.61 \times 10^2$  per  $1 \text{ mm}^2$ , which is 3 times less than after mineral trioxide aggregate usage –  $19.49 \pm 2.85 \times 10^2$  per  $1 \text{ mm}^2$ . It was established that the processes of rheological disorders with impaired lymph circulation are replaced by the restoration of the cellular component. In such a way the proposed vital amputation was examined for reversible pulpitis and it revealed similar clinical and pathological effectiveness with a positive regenerative process with formation of a sufficient number of odontoblasts ( $7.98 \pm 1.51 \times 10^3 / \text{mm}^2$ ) for the subsequent formation of a hard tissue bridge, which consists of collagen fibers in the form of a frame. The main goal of vital amputation procedure is regeneration (proliferation) of the pulp with a short-term signs of alteration and exudation, which is provided by the choice of material for the pulp covering. Thus, after the vital amputation of the pulp, followed by the use of tricalcium silicate cement 6 weeks after, the number of neutrophils was  $1.39 \pm 0.72 \times 10^2$  per  $1 \text{ mm}^2$ , which is 5 times less than after using mineral trioxide aggregate.

**Реферат.** Порівняльний аналіз дії трикальцій силікатного цементу та мінерал триоксид агрегату на клітинний склад пульпи після проведення вітальної пульпотомії в експериментальних тварин. Хотімська Ю., Ковач І., Бунятян Х., Кравченко Л., Варжапетян С. Метою дослідження було визначити вплив трикальцій силікатного цементу на захисний процес пульпи при лікуванні зворотнього пульпіту. Був проведений експеримент на 3-місячних кроликах-самцях для вивчення морфофункціональних змін тканини пульпи з моделюванням зворотнього пульпіту та подальшою вітальною ампутацією й покриттям трикальцію

силікатом (8 тварин, досліджувана група) та мінерал триоксид агрегатом (8 тварин, група порівняння). Через 2 та 6 тижнів тканини зуба фіксували 10% формаліном, після декальцинації та рутинних процедур проводили гістологічні зрізи, які фарбувались гематоксиліном та еозином. Після застосування трикальцієвого силікатного цементу через 2 тижні щільність одонтобластів змінилася до  $3,92 \pm 1,03 \times 10^3 / \text{мм}^2$  з  $8,3 \pm 1,02 \times 10^3 / \text{мм}^2$  щільності клітин у цілій групі. Кількість нейтрофілів також відіграє велику роль у регенерації запаленої пульпи. Кількість нейтрофілів через 2 тижні становила  $6,39 \pm 2,61 \times 10^2$  на  $1 \text{ мм}^2$ , що в 3 рази менше, ніж після використання мінерал триоксид агрегату –  $19,49 \pm 2,85 \times 10^2$  на  $1 \text{ мм}^2$ . Встановлено, що процеси реологічних порушень з порушенням циркуляції лімфи замінюються відновленням клітинного компонента. Таким чином, запропонована вітальна ампутація була обстежена на наявність зворотнього пульпіту та виявила схожу клінічну та патологічну ефективність із позитивним регенеративним процесом із утворенням достатньої кількості одонтобластів ( $7,98 \pm 1,51 \times 10^3 / \text{мм}^2$ ) для подальшого утворення твердого тканинного мосту, який складається з колагенових волокон у вигляді каркаса. Основною метою методики вітальної ампутації є регенерація (проліферація) пульпи, з короточасними ознаками альтерації й ексудації, що, звичайно ж, забезпечується вибором матеріалу для покриття пульпи. Таким чином, після вітальної ампутації пульпи з подальшим застосуванням трикальцій силікатного цементу через 6 тижнів кількість нейтрофілів становила  $1,39 \pm 0,72 \times 10^2$  на  $1 \text{ мм}^2$ , що в 5 разів менше, ніж після використання мінерал триоксид агрегату.

Mature pulp as connective tissue formations is a component of the whole organism. Any change in exogenous and endogenous factors directly affects its histological structure. To date, the most common drug for its treatment is calcium-containing compounds.

However, long-term observations after treatment with calcium hydroxide-based drugs have shown that its effectiveness decreases with the increase of the observation period. All this has become a prerequisite for replacing calcium hydroxide with more modern materials, which are based on mineral trioxide aggregate. It is a biocompatible material that provides high impermeability and regeneration of the soft dental tissue on contact with the cells and periapical tissues [4, 6]. The drug stimulates the formation of dentinal bridges, protecting the exposed pulp much more efficiently than calcium hydroxide. Despite a rather positive effect, it has a number of features that render dentist's work difficult, limiting it to a two-stage treatment modality. To date, of particular interest is the material represented by the compound of tricalcium silicate (TCS), which demonstrates physical and chemical properties similar to the characteristics of some derivatives of Portland cement [8]. From a biological point of view it has excellent compatibility [10] and is capable of causing reactive dentin deposits by stimulating the activity of odontoblasts [9, 11, 12], as well as reparative dentin - due to cell differentiation [3, 5]. The described property may be useful for various treatment options for the vital pulp [7].

The aim of this study was to determine the effects of tricalcium silicate and mineral trioxide aggregate on the course of reversible pulpitis by detection of morpho-functional peculiarities of changes in the pulp tissue.

#### MATERIALS AND METHODS OF RESEARCH

An experimental investigation on 3-month-old male rabbits in order to study the morphofunctional

changes of the pulp tissue with modeling of reversible pulpitis was performed.

After a general anesthesia (0.4 ml of 5% ketamine per 1 kg of body weight intramuscularly) we performed preparation of hard dental tissues with a micromotor tip with opening of the pulp horn. Half of the pulp was amputated with the following capping with tricalcium silicate (8 animals, study group) and mineral trioxide aggregate (8 animals, comparison group), tooth filling was performed with glass ionomer cement.

After withdrawal of animals from the experiment in 2 and 6 weeks, dental tissues were fixed in 10% formalin, after decalcification in acetic acid and routine proceeding, histological sections were stained with hematoxylin and eosin (H&E), according to van Gieson, Mallory; PAS-reaction was performed. The sections were studied under the microscope "Olympus BX-41" and following interpretation by "Olympus DP – soft version 3.2", which was used for morphometric study. Number of vessel cross-sections per  $1 \text{ мм}^2$ , odontoblasts,  $\times 10^3$  per  $1 \text{ мм}^2$ , neutrophils,  $\times 10^2$  per  $1 \text{ мм}^2$ , was detected. All values are expressed as means and standard error of the mean for statistical analysis. Statistical comparison was performed using Mann-Whitney test for statistical analysis. The accepted level of significance was  $p < 0.05$ .

The procedure was done strictly in compliance with the Helsinki Declaration, European Convention for the protection of vertebrate animals (18.03.1986), European Economic Society Council Directive on the Protection of Vertebrate Animals (24.11.1986) after approval of the Regional Ethical Review Board at State Establishment "Dnipropetrovsk Medical Academy" protocol N 2 (01.04.2016).

## RESULTS AND DISCUSSION

Clinical trials have shown that MTA and TCS reduce the frequency and severity of serious complications [1]. However, despite a significant amount of research performed by domestic and foreign scientists, the mechanism and degree of action on stimulating activity of odontoblasts after the application of MTA and TCS cement on the tooth pulp after its amputation remains understudied. The search for new methods and materials is extremely important for the treatment of dental pathology [3, 12], especially with an understanding of the pathogenetic background [1, 10].

Thus, calcium silicate material was widely used, and one of the proposed methods for pulp amputation began to be discussed in restorative dentistry. However, the methodology is especially useful and preferable when the tissue of the coronal pulp is inflamed, and the direct coating of the pulp is not suitable in accordance with some works.

Thus, it was found that pulp tissue has high reactive abilities, and direct pulp coating is insufficient to stimulate active regeneration processes with the active formation of a capillary network and new connective tissue elements [8]. Thus, after amputation of a vital pulp, protective mechanisms in the form of an inflammatory process with its resorption, encapsulation of dentin fragments and foci of necrosis against the background of intensive angiogenesis appear two weeks after.

In histological examination of the pulp of the comparison group two weeks after there was revealed reversible pulpitis. Vascular disorders, inflammatory infiltration, changes in the cellular reaction were manifested by infiltration of the affected zone by inflammatory cells with neutrophils  $\times 10^2$  per  $1 \text{ mm}^2$   $19.49 \pm 2.85$  (fig. 1). Morphometric data are presented in table for this and other groups.

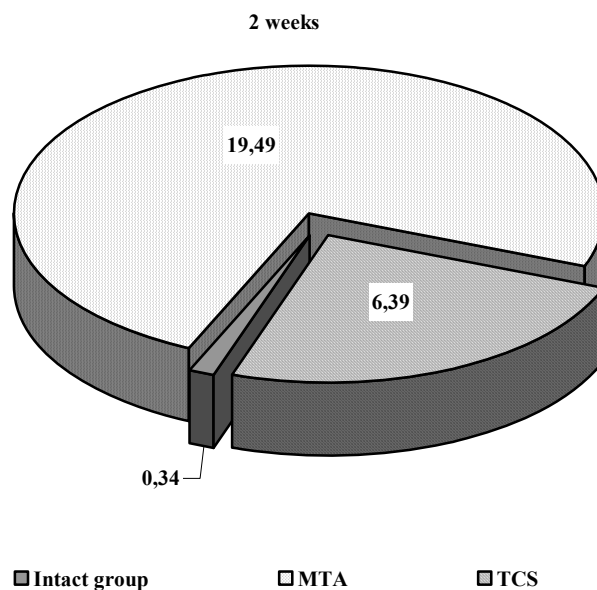


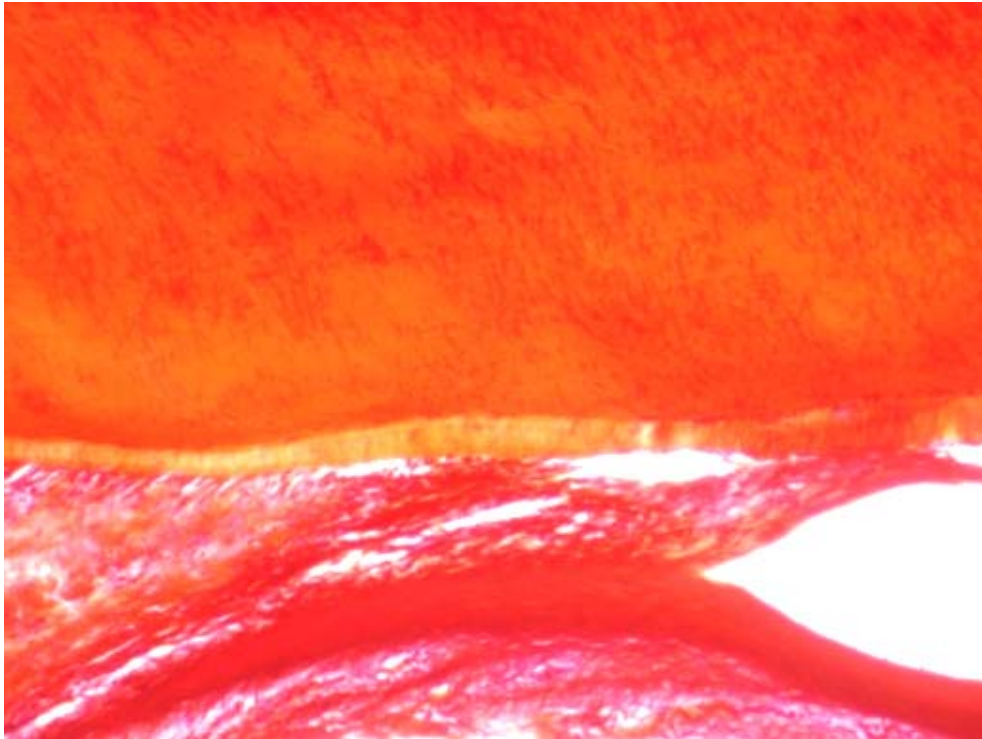
Fig. 1. Neutrophils,  $\times 10^2$  per  $1 \text{ mm}^2$

Layers of epithelial cells are intact, in cells of the basal layer moderately expressed signs of proliferation are found. The radial structure of the dentinal tubules is preserved on the peripheral part of the crown. Small areas with large interglobular spaces and the process of ectasia of the dentinal tubules are noted (fig. 2).


In the central part, in the place of direct contact with the defect, homogenization and mosaicism of

the intertubular dentin and disappearance of the dentinal tubules in it are noted. In rare places, residues of the tubules with the formation of zones of transparent dentin are defined (fig. 3).

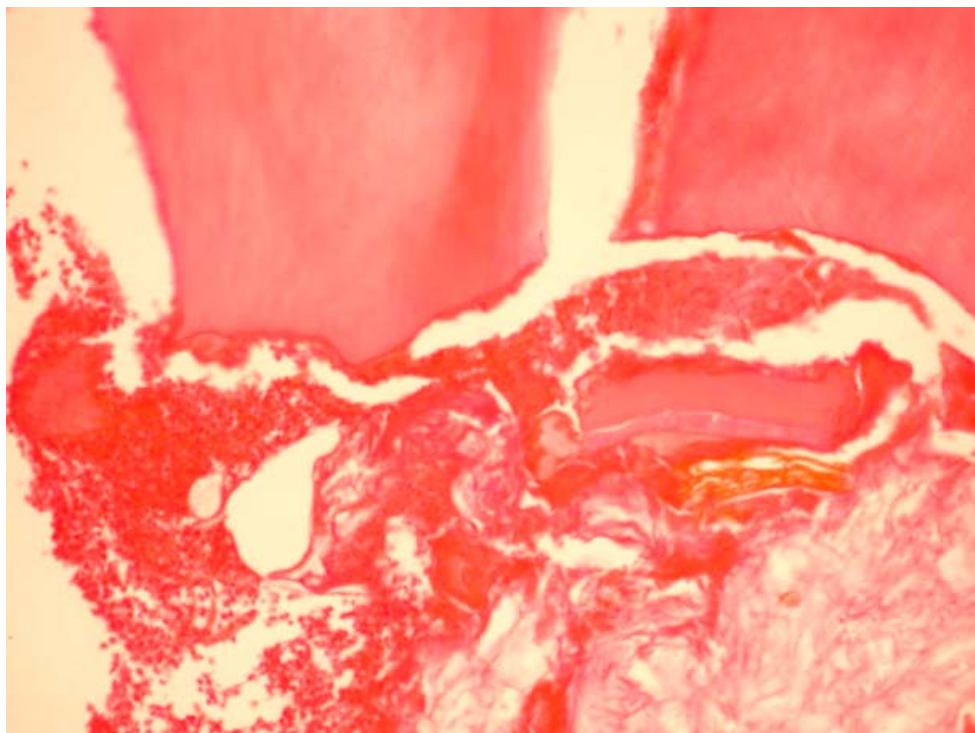
In the area of penetration of the defect into the pulp cavity, the area of necrosis with cellular detritus, as well as the foci of neutrophilic infiltrations is determined (fig. 4).



**Fig. 2.** Small areas with large interglobular spaces and the process of ectasia of the dentinal tubules are noted. Staining by Mallory x200



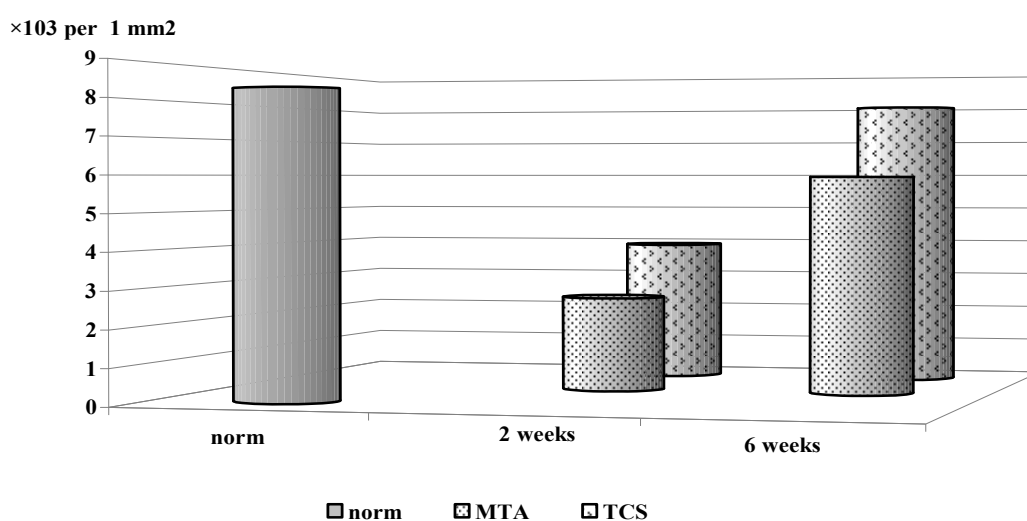
**Fig. 3.** Residues of the tubules.  
Electron-diffraction photograph, magnification x3510



**Fig. 4. Foci of neutrophilic infiltrations.  
Homogenized vascular walls. Staining with hematoxylin and eosin x200**

Odontoblasts of  $2.58 \pm 1.11 \times 10^3$  per  $1 \text{ mm}^2$  are also determined (fig. 5). The processes of odontoblasts are swollen, of various thicknesses with signs of vacuolar hydropic dystrophy. In the area of the neck and root, reactive changes of the pulp predominate, and are characterized by blood- and

lymph flow disorders, including vascular hyperemia before the sludge-phenomenon of red blood cells. In the microvascular bed, erythrocyte aggregation and stasis are observed. Single pre-dentin sites with diapedetic hemorrhages of erythrocytes in the layer of odontoblasts are visualized.



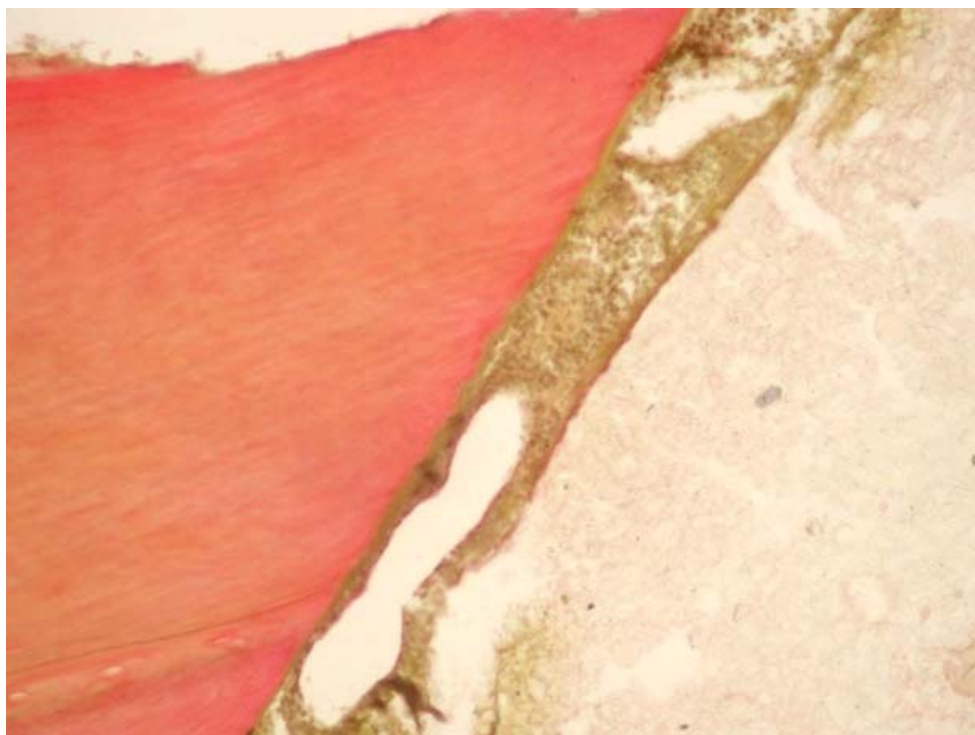
**Fig. 5. Number of odontoblasts after odontotropic materials usage,  $\times 10^3$  per  $1 \text{ mm}^2$**

Histological examination of the obtained micro-objects after pulp amputation with the following

tricalcium silicate preparation shows the other picture of pulp tissue condition 2 weeks after.

In general, signs of proliferation are identified. The edges of the traumatic defect are even, linear without dentin protrusions. The radial structure of

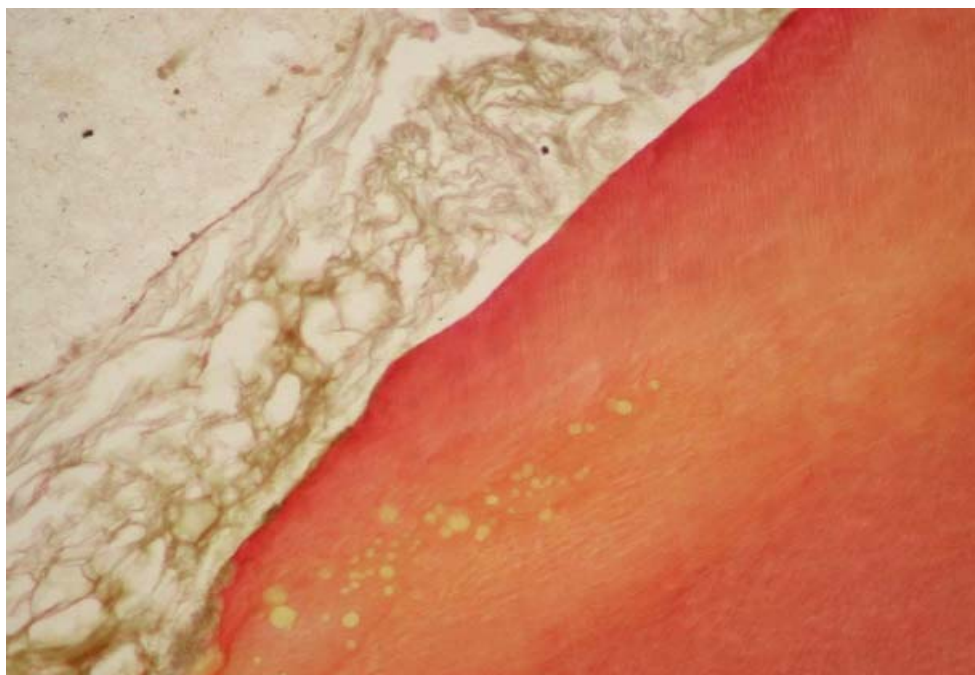
the dentinal tubules around the area of drug application is saved. Small zones with large interglobular spaces are noted (fig. 6).



**Fig. 6. Small zones with large interglobular spaces. Staining by Van Gieson ×200**

The enamel-dentin junction is represented by a linear formation, the enamel has the appearance of a granular mass. In the zone of the enamel-dentin junction (staining by Mallory), enamel beams having

the form of small tape-like formations are visualized. In the area of the dentin-enamel junction, a slight loosening of enamel beams is observed (fig. 7).



**Fig. 7. Loosening of enamel beams is observed. Staining by Van Gieson. ×200.**

In the central part, in the place of a direct contact with the defect, homogenization and mosaicism of the intertubular dentin and the disappearance of the dentinal tubules in it is noted. Peritubular dentin is impacted, which is characterized by a clear picture of the borders of the tubules. Circum-pulpal dentin is without signs of pathological transformation, only in isolated areas the penetration of reactive pathological changes into the healthy tissue of circum-pulpal dentin is noted.

Cellular composition of the pulp is represented mainly by undifferentiated cells of the fibroblastic lines, fibroblasts, odontoblasts  $3.92 \pm 1.03 \times 10^3$  per  $1 \text{ mm}^2$ , macrophages; neutrophils  $6.39 \pm 2.61 \times 10^2$  per  $1 \text{ mm}^2$  are isolate (fig. 8).

Histological examination of the obtained micro-objects of pulp amputation with the following MTA coating shows signs of a proliferative inflammatory process six weeks after.

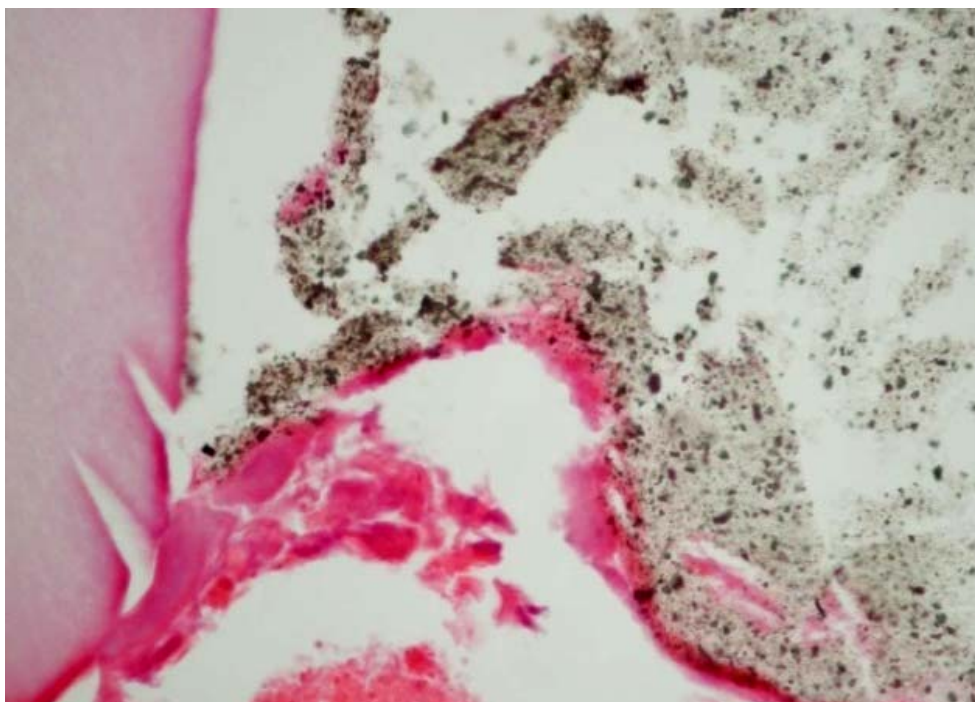


Fig. 8. Insignificant number of inflammatory elements.

Moderately pronounced vascular congestion of the microcirculatory bed in the root area with a slight swelling in the perivascular space is noted.

Small clumps of neutrophils  $7.12 \pm 0.96 \times 10^2$  per  $1 \text{ mm}^2$  are noted (fig. 9).

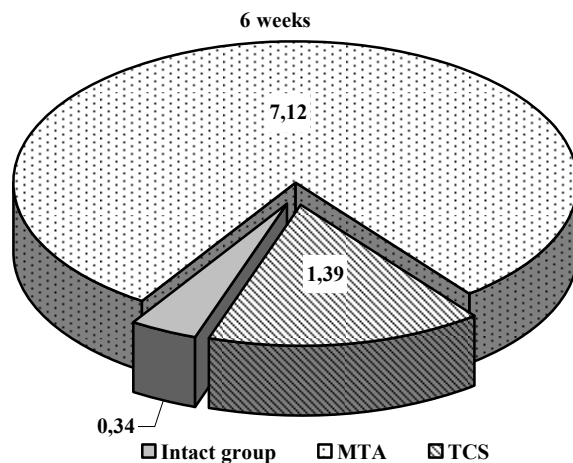


Fig. 9. Neutrophils,  $\times 10^2$  per  $1 \text{ mm}^2$

Odontoblasts ( $5.95 \pm 1.53 \times 10^3$  per  $1 \text{ mm}^2$ ) of root pulp adjacent directly to the damage zone with pronounced signs of dystrophic changes. In the underlying connective tissue a moderately pronounced edema is found. The cytoplasm of macrophages, plasma cells, fibroblasts and endotheliocytes is pale, odontoblasts with signs of vacuolization.

The histological examination of the obtained micro-objects after pulp amputation with tricalcium

silicate six weeks after shows that cellular elements of the pulp are presented by odontoblasts ( $7.98 \pm 1.51 \times 10^3$  per  $1 \text{ mm}^2$ ) in the peripheral layer and in the subodontoblastic and central layers; fibroblasts and sessile macrophages are also revealed in the subodontoblastic and central layers. Hyperemia is less pronounced without hemorrhages; no necrobiotic changes have been revealed. PAS-reaction is evenly positive in connective tissue fibers and vascular membrane of the pulp.

### Results of morphometric investigation of dental pulp tissue (M±m)

	Intact animals	MTA		TCS	
		2 weeks	6 weeks	2 weeks	6 weeks
Odontoblasts, $\times 10^3$ per $1 \text{ mm}^2$	8.3±1.02	2.58±1.11*	5.95±1.53#	3.92±1.03*	7.98±1.51#
Neutrophils, $\times 10^2$ per $1 \text{ mm}^2$	0.34±0.03	19.49±2.85*	7.12±0.96#	6.39±2.61*	1.39±0.72#

Notes: \* –  $p < 0.05$  – index of significance of differences as compared with intact animals; # –  $p < 0.05$  – index of significance of differences as compared with data in 2 weeks

The tissue is abundantly vascularized with numerous newly formed microcirculatory beds and with pronounced convoluted and anastomotic lymphatic vessels. Cellular composition of the pulp is represented mainly by undifferentiated cells of the fibroblastic lines, fibroblasts, odontoblasts, macrophages; neutrophils ( $1.39 \pm 0.72 \times 10^2$  per  $1 \text{ mm}^2$ ) are isolate.

#### CONCLUSION

1. Two weeks after the modeling of the reversible pulpitis in the pulp tissue there were found manifestations of protective-adaptive mechanisms in the form of the inflammatory process with its resolution, with necrosis zone being replaced by connective tissue.

2. It was established that after TCS using in 6 weeks the number of neutrophils is 5 times less than

after applying MTA and revealed similar clinical and pathological efficacy with a positive regenerative process with the formation of a bridge of hard tissues, which consists of collagen fibers in the form of a frame.

3. It was established that the number of odontoblasts after the application of TCS is 1.5 times higher in comparison with MTA. Therefore, our results can be useful for TCS in comparison with MTA.

4. Thus, it should be assumed that the use of tricalcium silicate as a material for pulp coating contributes to more active regeneration processes.

Conflict of interests. The author declares that there is no conflict of interest.

### REFERENCES

1. Varzhapetian S, et al. Aerobic microflora in the pathogenesis of maxillary sinusitis after the treatment of caries complications. Georgian medical news. 2019;289:42-46.
2. Avwioro G. Histochemical Uses of Haematoxylin. A Review. JPCS. 2011;1:24-34.
3. Tomás-Catalá CJ, Collado-González M, García-Bernal D, Oñate-Sánchez RE, et al. Biocompatibility of New Pulp-capping Materials NeoMTA Plus, MTA Repair HP, and Biodentine on Human Dental Pulp Stem Cells. J Endod. 2018;44(1):126-32. doi: <https://doi.org/10.1016/j.joen.2017.07.017>
4. Pinheiro LS, Iglesias JE, Boijink D, Mestieri LB, et al. Cell Viability and Tissue Reaction of

- NeoMTA Plus: An In Vitro and In Vivo Study. Grecca FS4. J Endod. 2018 Jun 1;pii S0099-2399:30169-9. doi: <https://doi.org/10.1016/j.joen.2018.03.007>
5. Tomás-Catalá CJ, Collado-González M, García-Bernal D, Oñate-Sánchez RE, et al. Comparative analysis of the biological effects of the endodontic bioactive cements MTA-Angelus, MTA Repair HP and NeoMTA Plus on human dental pulp stem cells. Int. Endod J. 2017;50(Suppl. 2):e63-e72. doi: <https://doi.org/10.1111/iej.12859>
6. Guerreiro-Tanomaru MJ, Bosso-Martelo R, Chavez-Andrade GM, Tanomaru Filho MJ. Solubility, porosity and fluid uptake of calcium silicate-based cements.





Torres FFE. *Appl Oral Sci.* 2018;26:e20170465. doi: <https://doi.org/10.1590/1678-7757-2017-0465>

7. Kovach I, Buniatian K, Makarevych A, et al. Influence of Tricalcium silicate on course of traumatic pulpitis. *Georgian medical news.* 2018;276(3):130-5.

8. Nagas E, Kucukkaya S, Eymirli A, Uyanik M. Effect of Laser-Activated Irrigation on the Push-Out Bond Strength of ProRoot Mineral Trioxide Aggregate and Biodentine in Furcal Perforations. *Cehreli ZC2 Photomed Laser Surg.* 2017;35(4):231-5. doi: <https://doi.org/10.1089/pho.2016.4171>

9. Tanomaru-Filho MA, Torres FE, Bosso-Martelo R, Chávez-Andrade GM, et al. Novel Model for Evaluating the Flow of Endodontic Materials Using Micro-computed Tomography. *J Endod.* 2017;43(5):796-800. doi: <https://doi.org/10.1016/j.joen.2016.12.002>

10. Övsay E, Kaptan RF, Şahin F. The Repair of Furcal Perforations in Different Diameters with Biodentine, MTA, and IRM Repair Materials: A Laboratory Study Using an E. Faecalis Leakage Model. *Biomed Res Int.* 2018 Jan 15;5478796.

doi: <https://doi.org/10.1155/2018/5478796>

11. Tanomaru-Filho M, Torres FE, Chávez-Andrade GM, de Almeida M, et al. Physicochemical Properties and Volumetric Change of Silicone Bioactive Glass and Calcium Silicate-based Endodontic Sealers. *J Endod.* 2017;43(12):2097-101.

doi: <https://doi.org/10.1016/j.joen.2017.07.005>

12. Rahimi S, Shahi S, Torabi Z, Rezaie Y, et al. The Effect of a Mineralized Bone Graft on the Surface Microhardness of Mineral Trioxide Aggregate and Biodentine. *Iran Endod J.* 2018;13(1):83-87.

## СПИСОК ЛІТЕРАТУРИ

1. Aerobic microflora in the pathogenesis of maxillary sinusitis after the treatment of caries complications / S. Varzhapetian et al. *Georgian medical news.* 2019. Vol. 289. P. 42-46.

2. Avwioro G. Histochemical Uses of Haematoxylin. A Review. *JPCS.* 2011. N 1. P. 24-34.

3. Biocompatibility of New Pulp-capping Materials NeomTA Plus, MTA Repair HP, and Biodentine on Human Dental Pulp Stem Cells / C. J. Tomás-Catalá et al. *J. Endod.* 2018. Vol. 44, No. 1. P. 126-132. DOI: <https://doi.org/10.1016/j.joen.2017.07.017>

4. Cell Viability and Tissue Reaction of NeomTA Plus: An In Vitro and In Vivo Study / L. S. Pinheiro et al. Grecca FS4. *J. Endod.* 2018. 1 Jun. pii S0099-2399. P. 30169-9. DOI: <https://doi.org/10.1016/j.joen.2018.03.007>

5. Comparative analysis of the biological effects of the endodontic bioactive cements MTA-Angelus, MTA Repair HP and NeomTA Plus on human dental pulp stem cells / C. J. Tomás-Catalá et al. *Int. J. Endod.* 2017. Vol. 50. Suppl. 2. P. e63-e72. DOI: <https://doi.org/10.1111/iej.12859>

6. Guerreiro-Tanomaru M. J., Bosso-Martelo R., Chavez-Andrade G. M., Filho Tanomaru M. J. Solubility, porosity and fluid uptake of calcium silicate-based cements. *Torres FFE. Appl Oral Sci.* 2018. No. 26. P. e20170465. DOI: <https://doi.org/10.1590/1678-7757-2017-0465>

7. Influence of Tricalcium silicate on course of traumatic pulpitis / I. Kovach, et al. *Georgian medical news.* 2018. Vol. 276, No. 3. P. 130-135.

8. Nagas E., Kucukkaya S., Eymirli A., Uyanik M. Effect of Laser-Activated Irrigation on the Push-Out Bond Strength of ProRoot Mineral Trioxide Aggregate and Biodentine in Furcal Perforations. *Cehreli ZC2. Photomed Laser Surg.* 2017. Vol. 35, No. 4. P. 231-235. DOI: <https://doi.org/10.1089/pho.2016.4171>

9. Novel Model for Evaluating the Flow of Endodontic Materials Using Micro-computed Tomography / M. A. Tanomaru-Filho et al. *J. Endod.* 2017. Vol. 43, No. 5. P. 796-800.

DOI: <https://doi.org/10.1016/j.joen.2016.12.002>

10. Övsay E., Kaptan R. F., Şahin F. The Repair of Furcal Perforations in Different Diameters with Biodentine, MTA, and IRM Repair Materials: A Laboratory Study Using an E. Faecalis Leakage Model. *Biomed Res Int.* 2018. 15 Jan. P. 5478796.

DOI: <https://doi.org/10.1155/2018/5478796>

11. Physicochemical Properties and Volumetric Change of Silicone Bioactive Glass and Calcium Silicate-based Endodontic Sealers / M. Tanomaru-Filho et al. *J. Endod.* 2017. Vol. 43, No. 12. P. 2097-2101. DOI: <https://doi.org/10.1016/j.joen.2017.07.005>

12. The Effect of a Mineralized Bone Graft on the Surface Microhardness of Mineral Trioxide Aggregate and Biodentine / S. Rahimi et al. *Iran Endod J.* 2018. Vol. 13, No. 1. P. 83-87.

The article was received  
2019.09.12

