

CASE REPORT

EXAGGERATED PLACENTAL SITE REACTION MIMICKING A TROPHOBLASTIC TUMOR: A CASE REPORT

Angel YORDANOV¹✉, Margarita NIKOLOVA², Stanislav SLAVCHEV³, Stoyan KOSTOV³, Strahil STRASHILOV⁴

¹ Department of Gynecologic Oncology, Medical University Pleven, Pleven, Bulgaria

² Saint Marina University Hospital – Pleven, Medical University Pleven, Pleven, Bulgaria

³ Department of Gynecology, Medical University Varna, Bulgaria

⁴ Department of Plastic Restorative, Reconstructive and Aesthetic Surgery, Medical University Pleven, Bulgaria

Received 24 Oct 2019, Accepted 05 Febr 2020

<https://doi.org/10.31688/ABMU.2020.55.1.21>

ABSTRACT

Introduction. Exaggerated placental site reaction is a rare benign non-neoplastic lesion and presents with infiltration of the endometrium and myometrium by intermediate trophoblastic cells at the implantation site. This reaction may occur following healthy or ectopic pregnancy, abortions, or molar pregnancy. The diagnosis is only histopathological.

Case report. We present a 44-year-old woman with prolonged menstrual bleeding, high levels of beta-hCG and ultrasound finding mimicking submucosal fibroid. Hysterectomy was performed because of the tumoral mass in the uterine cavity. The diagnosis made was exaggerated placental site reaction.

Conclusions. Exaggerated placental site reaction is a benign condition, but this lesion has to be differentiated from placental site nodule, placental site trophoblastic tumor and choriocarcinoma because the latter require aggressive treatment.

Keywords: exaggerated placental site reaction, intermediate trophoblast, submucosal fibroid.

RÉSUMÉ

Réaction de site placentaire exagérée imitant la tumeur trophoblastique : rapport du cas

Introduction. La réaction exagérée du site placentaire est une lésion bénigne non néoplasique rare et présente une infiltration de l'endomètre et du myomètre par des cellules trophoblastiques intermédiaires au site d'implantation. Cette réaction peut survenir après une grossesse en santé ou extra-utérine, un avortement ou une grossesse molaire. Le diagnostic est seul histopathologique.

Rapport du cas. Nous présentons le cas d'une femme de 44 ans avec des saignements menstruels prolongés, des taux élevés de bêta-hCG et une échographie simulant un fibrome sous-muqueux. L'hystérectomie a été réalisée en raison de la masse tumorale dans la cavité utérine. Le diagnostic posé était une réaction exagérée du site placentaire

Conclusions. La réaction exagérée du site placentaire est une affection bénigne, mais cette lésion doit être différenciée du nodule du site placentaire, de la

✉ Address for correspondence:

Angel D. YORDANOV
Clinic of Gynecologic Oncology, University Hospital "Dr. Georgi Stranski",
Pleven, Bulgaria
Address: Georgi Kochev 8A, Pleven, Bulgaria
Email: angel.jordanov@gmail.com; Phone +35 988 767 1520

Abbreviations:

EPSR – Exaggerated placental site reaction
IIT – intermediate trophoblasts
beta-hCG – human chorionic gonadotropin
hPL – human placental lactogen
PSN – placental site nodules
PSTT – placental site trophoblastic tumor
ETT – epithelioid trophoblastic tumor
IHM – invasive hydatidiform mole
ChCa – choriocarcinoma

INTRODUCTION

Exaggerated placental site reaction (EPSR) is a benign non-neoplastic lesion, defined as exuberant infiltration of extra villous implantation site, intermediate implantation trophoblasts (IIT) in the endometrium, myometrium and blood vessel walls at the implantation site¹⁻³. In the past, this finding was called syncytial endometritis, but now the World Health Organization uses the term exaggerated placental site because the lesion is non-inflammatory, not limited to the endometrium and the constituent cells are not syncytial⁴. This reaction may occur following healthy or ectopic pregnancy, abortion, or molar pregnancy⁵, and its frequency is 1.6% in spontaneous and elective first-trimester abortions⁶. It is essential to differentiate this lesion from other trophoblastic lesions, because some of them necessitate aggressive treatment and follow up⁵.

CASE REPORT

We present a 44-year-old patient with a history of one pregnancy, one cesarean section in 2002, and no concomitant conditions. She sought medical attention for menstrual bleeding that lasted 10 days. After an examination in another clinic, she was diagnosed with a cyst in the left ovary, and cystectomy was suggested. The patient presented to our clinic for a second opinion.

During the last few months, the intervals between menstruation cycles were longer, and the last was 20 days late, after which heavy bleeding occurred that continued for 12 days on the day of examination. The gynecological findings were normal except for a slightly enlarged uterus. Ultrasound examination visualized a single echo-homogenous follicular cyst in the left ovary, sized 35/42 mm, without papilliform growths. The endometrium was echo-heterogeneous, 15 mm thick, and a round heterogeneous formation, measuring 32/24mm. The laboratory value from the investigation of human chorionic gonadotropin

tumeur trophoblastique du site placentaire et du choriocarcinome, ces derniers nécessitant un traitement agressif.

Mots-clés: réaction exagérée du site placentaire, trophoblaste intermédiaire, fibrome sous-muqueux.

(beta-hCG) for suspected trophoblast disorder was 3326 mIU/ml, and an explorative curettage was performed. The histological analysis revealed a spontaneous miscarriage (hypersecretory endometrium, spongy decidua, and scattering, swollen fibrotic chorionic villi. The diagnosis made was of incomplete abortion. On the 10th day following the intervention, beta-hCG was 3114 mIU/mL. Two months later, it was 1130 mIU/mL, and after another month dropped to 429 mIU/mL. Another ultrasound was carried out, which revealed normal adnexa. A tumor was found, as described above (Fig. 1).

Based on the ultrasound findings, the diagnosis was submucosal fibroid formation. The patient reported two missed periods. After blood analysis, chest X-ray and abdominal ultrasound, laparoscopic hysterectomy was performed, sparing the adnexa. The tumor found in the uterus was round, soft, and submucosal, sized 3x3.5 cm (Fig. 2).

The histological examination of the specimen revealed that the uterine cavity was lined with secretory endometrium with involute changes. Amongst the myometrium, there was a well-defined nodule composed of blood clot, cellular debris, and necrotic chorionic villi (Fig. 3). The adjacent myometrium was perivascular infiltrated with intermediate implantation trophoblasts (IIT) (Fig. 4). Immunohistochemical examination proved that the Ki67 labeling index was 0, and the human placental lactogen (hPL) was positive in the perivascular infiltrates that confirmed their nature: intermediate implantation trophoblasts (Fig. 5). The clinical data, surgical finding, and the histological and immunohistochemical investigations all led to the diagnosis we made, of persistent exaggerated placental site after abortion.

Recovery was uneventful, and the patient was discharged on the third postoperative day. Two weeks after the operation, the beta-hCG was 0.21 mIU/mL. Three months after the operation, the patient had no complaints.

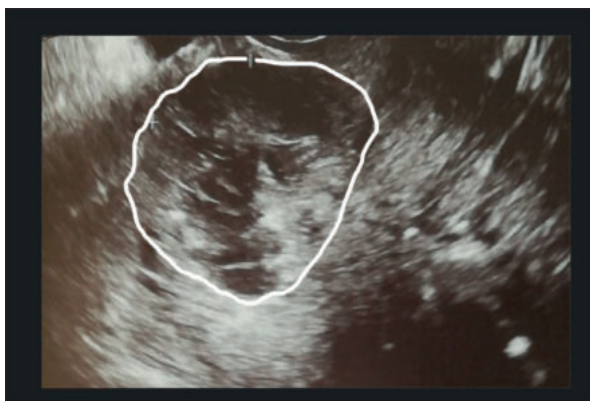


Fig. 1. Ultrasound finding in the uterine cavity.

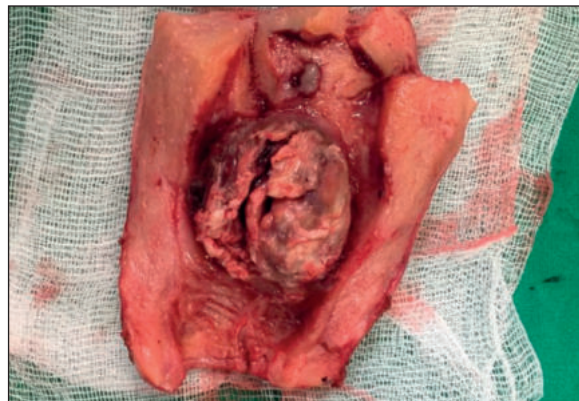


Fig. 2. The intraoperative finding after dissection of the uterus – submucosal, round, and soft formation, sized 3/3.5 cm.

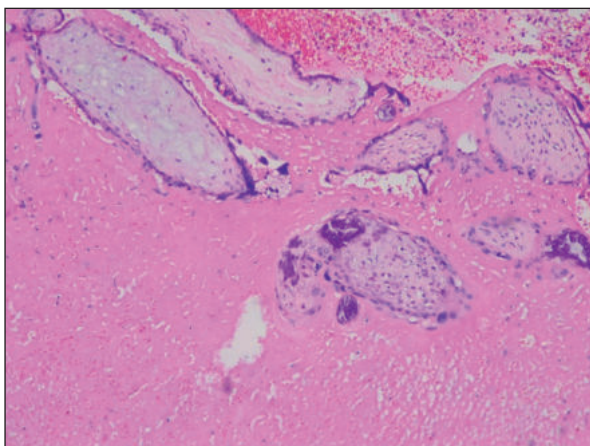


Fig. 3. Blood clot and necrotic chorionic villi. HE x10

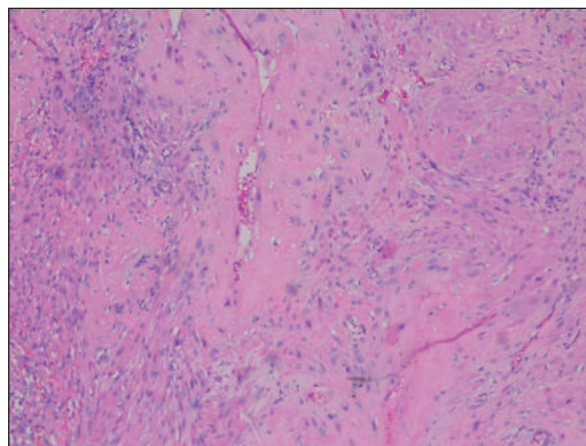


Fig. 4. Myometrium and vascular wall infiltrated by implantation of intermediate trophoblast that is hPL-positive (insertion x40). HEx10

DISCUSSION

EPSR is a rare benign condition presented by infiltration of intermediate trophoblastic cells into the endometrium and myometrium at the implantation site. In the past, this condition was known as syncytial endometritis or benign chorionic invasion. Both terms are inaccurate, because there is neither inflammatory condition nor limitation to the endometrium³. Intermediate trophoblasts (IT) show differentiation between cytotrophoblasts and syncytiotrophoblasts. Intermediate trophoblasts play a crucial role in the maintenance of pregnancy: they infiltrate the decidua, invade the myometrium and spiral arteries and obtain the maternal-fetal circulation⁷. When the IIT expands into the myometrium, without consequent regression or involution, the condition is called EPSR⁸. The diagnosis is only histopathological.

EPSR may occur after a normal pregnancy or ectopic pregnancy, abortion, or molar pregnancy^{4,9}.

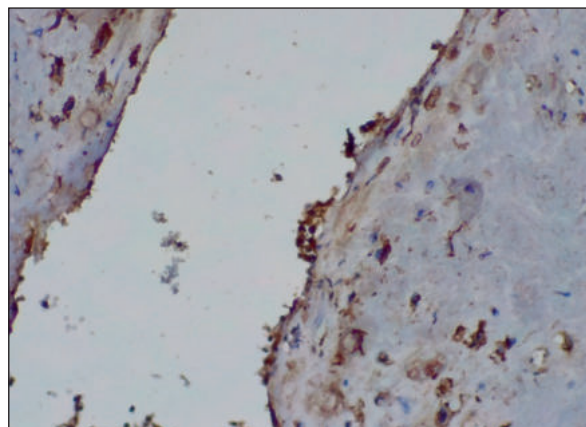


Fig. 5. hPL-positive IIT

EPSR is not the only lesion which can arise from the IT. The others are placental site nodules (PSN), placental site trophoblastic tumor (PSTT), and epithelioid trophoblastic tumor (ETT). EPSR and PSN are benign proliferation, while PSTT and ETT have

metastatic potential and can lead to a local invasion. PSN and ETT arise from intermediate trophoblasts of chorionic leave, whereas EPSR and PSTT occur from intermediate trophoblasts at the implantation site³. The accurate diagnosis is vital because each of these lesions has different clinical behavior and a specific treatment¹⁰. EPSR can be diagnosed when the lesion does not demonstrate a high mitotic rate. The lesion is interspersed with the trophoblasts is hyaline material, and villi can be present^{6,11}. The trophoblasts of EPSR are cytologically similar to the intermediate trophoblasts of the normal implantation site¹⁰.

EPSR can present with excessive uterine bleeding, elevated beta-hCG, or, rarely, with a uterine mass. Kase et al have reported a case of EPSR in cervical pregnancy with uterine bleeding and intrauterine mass¹². Menczer et al described a case of EPSR in association with a molar pregnancy, in which increased beta-hCG levels after curettage with an intrauterine nodule were noticed¹³. Kadian et al considered that the level of beta-hCG has to be followed up in all patients with EPSR, and this was an essential criterion for differentiation from PSTT¹⁴. There are several cases reported in the literature, in which EPSR presented with postpartum hemorrhage after caesarian section or vaginal delivery without a formation in the uterus^{15,16}. EPSR can also present with delayed irregular uterine bleeding, starting 7 months to 15 years after normal delivery^{17,18}.

Takebayashi et al assume that postpartum uterine atony results from vascular dilation in the decidua and myometrium caused by excessive proliferation of IIT or is due to unknown substances secreted by IIT, and preventing myometrial contraction¹⁵. EPSR should be suspected in cases of postpartum hemorrhage, which does not respond to medical management. The diagnosis has to be confirmed by histological examination, and serum beta-hCG levels have to be monitored¹⁰.

Clinically, our case is closest to a case reported by Harada et al⁶. They described a 43-year-old woman with massive genital bleeding 41 days after induced abortion in the first trimester. On ultrasound examination, they found a placental polyp, and hysterectomy was performed. The histological diagnosis was an exaggerated placental site with a placental polyp.

In our case, the presence of myometrial mass combined with elevated serum levels of hCG and clinical data of an abortion a few months before raised the possibility of a trophoblastic tumor – including a PSTT, ETT, an invasive hydatidiform mole (IHM), and even a choriocarcinoma (ChCa). The histological finding of chorionic villi was not consistent with PSTT and ETT, and the total absence of proliferative activity (Ki67=0) ruled out all of the neoplasms

mentioned above. Finally, the histological appearance of chorionic villi in the curetting material and the surgical specimen was not the same as that of molar villi. Hence, IHM was also ruled out. So, all the clinical, surgical, histological, and Immunohistochemical findings were compatible with a non-neoplastic trophoblastic disease, that is EPS. We did not think about it initially because it was not evident¹⁹. Our first clinical suspicion was about a submucosal leiomyoma, not consistent with the elevated serum levels of hCG.

CONCLUSIONS

Exaggerated placental site reaction is a benign condition that should enter into the differential diagnosis with trophoblastic tumors, including choriocarcinoma. Recognition of these tumors is still a challenge because of their rarity and morphological overlapping with some benign conditions. The adequate diagnosis is crucial for patient management, because neoplastic trophoblastic disease necessitates an aggressive treatment.

Author contributions

S. K. and S. S. were responsible for the diagnostic procedures, clinical diagnosis, and treatment decisions. M. N. made the histopathological diagnosis, A.Y. and S. S. performed the surgery. A. Y. and M. N. wrote the manuscript. All authors have read and agreed to the published version of the manuscript.

Compliance with Ethics Requirements:

„The authors declare no conflict of interest regarding this article“

„The authors declare that all the procedures and experiments of this study respect the ethical standards in the Helsinki Declaration of 1975, as revised in 2008(5), as well as the national law. Informed consent was obtained from the patient included in the study“

„No funding for this study“

Acknowledgments: none

REFERENCES

1. Silverberg SG, Kurman RJ. Tumors of the uterine corpus and gestational trophoblastic disease. In: Rosai J, Sobin LH (eds) Atlas of Tumor Pathology, 3rd series, fascicle 3. Washington DC: Armed Forces Institute of Pathology, 1999: 274-5.
2. Erdogan NY, Kara M. Exaggerated placental site with term pregnancy. *Pak J Med Sci.* 2012; 28: 977-8.
3. Shihle M, Mazur MT, Kurman RJ. Gestational trophoblastic disease and related lesions. In: Kurman RJ. Blaustein's

- Pathology of the Female Genital Tract. 5th ed. Baltimore: Springer, 2004; 1193-247.
4. Ozdemir O, Sari ME, Selimova V, Ilgin BU, Atalay CR. A case report of complete mole with co-existent exaggerated placental site reaction and review of the literature. *Niger Med J*. 2014;55(2):180-2.
 5. Jayakrishnan N, Jayakrishnan K. *Int J Reprod Contracept Obstet Gynecol*. 2016;5(7):2425-2427
 6. Harada N, Nobuhara I, Haruta N, Kajimoto, M. A placental polyp arising from an exaggerated placental site. *J Obstet Gynaecol Res*. 2011; 34: 609-12
 7. Fisher SJ, Damsky CH. Human cytotrophoblast invasion. *Semin Cell Biol*. 1993; 4: 183-8.
 8. Shetty A, Narasimha A, Jyalakshmi V. J. Exaggerated placental site reaction: case report of a rare benign trophoblastic lesion. *Int J Reprod Contracept Obstet Gynecol*. 2015;4(5):1647-1649.
 9. Choi JJ, Emmadi R. Incidental placental site nodule in a fallopian tube. *Int J Surg Pathol*. 2014;22(1):90-2.
 10. Sidhu S, Ashima, Isaacs R, Dhar T. Exaggerated placental site reaction: a rare cause of massive postpartum hemorrhage. *EJPMR*. 2018;5(4):472-474.
 11. Yeasmin S, Nakayama K, Katagiri A, et al. Exaggerated placental site mimicking placental site trophoblastic tumor: case report and literature review. *Eur J Gynaecol Oncol*. 2010; 31: 586-9.
 12. Kase H, Kodama S, Yahata T, Aoki Y, Tanaka K. Case report: an exaggerated placental site with a cervical pregnancy. *J Obstet Gynaecol Res*. 1996; 22: 379-83.
 13. Menczer J, Livoff A, Malinger G, Girtler O, Zakut H. Exaggerated placental site erroneously diagnosed as non-metastatic trophoblastic disease. A case report. *Eur J Gynaecol Oncol*. 1999; 20: 15-6.
 14. Kadian ND, Singh S, Rajotia N, Dahiya K, Jain S, Malik R. Exaggerated placental site: a cause of post-partum collapse? *J South Asian Feder Obst Gynae*. 2015;7: 148-51.
 15. Takebayashi A, Kimura F, Yamanaka A, et al. Exaggerated placental site, consisting of implantation site intermediate trophoblasts, causes massive postpartum uterine hemorrhage: case report and literature review. *Tohoku J Exp Med*. 2014; 234: 77-82.
 16. Liu G, Yuan B, Wang Y. Exaggerated placental site leading to postpartum hemorrhage: a case report. *J Reprod Med*. 2013;58: 448-50.
 17. Stolnicu S, Radulescu D, Gonzalez-Rocha T, Timar I, Puscasiu L, Nogales FF. Exaggerated placental site lesion with unusual presentation in the cervix of a perimenopausal patient. *APMIS*. 2008;116: 160-2.
 18. Hui P, Baergen R, Cheung ANY, et al. Gestational trophoblastic neoplasms. In: Kurman RJ, Carcangiu ML, Herrington CS, Young RH (Eds.), WHO Classification of Tumors of Female Reproductive Organs, 4th ed., IARC, Lyon, France, 2014, pp. 155-7.
 19. Heller DS. Update on the pathology of gestational trophoblastic disease. *APMIS*. 2018;126(7):647-654.