



ISSN: 2467-9283

INTERNATIONAL JOURNAL OF GRADUATE RESEARCH AND REVIEW

website: www.ijgrr.org

INDEXING & ABSTRACTING



OPEN

ACADEMIC JOURNALS INDEX (OAJI), INFOBASE
INDEX, COSMOS, RESEARCHGATE,
CITEFACTOR, SCHOLAR STEAR, JOURINFO, ISRA:
JOURNAL-IMPACT-FACTOR (JIF), ROOT INDEXING
ETC.

Impact Factors*

IBI factor: 3

Impact factor (OAJI): 0.101.





Mini Review

Extrauterine Pregnancy in Bitch: A Mini Review

Bhuwan Raj Bhatta^{1*}, Krishna Kaphle², Saroj Shrestha¹, Ashok Kafle¹

¹Institute of Agriculture and Animal Science, Tribhuvan University, Nepal

²Department of Theriogenology, Institute of Agriculture and Animal Science, Tribhuvan University, Nepal

Article Information

Received: 15 January 2020

Revised version received: 20 February 2020

Accepted: 23 February 2020

Published: 28 February 2020

Cite this article as:

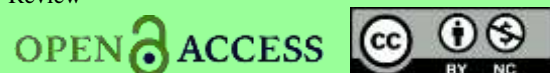
B.R. Bhatta *et al.* (2020) Int. J. Grad. Res. Rev. Vol 6(1): 1-4.

*Corresponding author

Bhuwan Raj Bhatta,
Institute of Agriculture and Animal Science, Tribhuvan
University, Nepal
Email: bhattabhuwan33@gmail.com

Peer reviewed under authority of IJGRR

© 2020 International Journal of Graduate Research and Review



Abstract

Extrauterine pregnancy or ectopic pregnancy means a pregnancy occur elsewhere than uterus. It is a rare condition in animals than humans. Nevertheless, the causes are not well defined in animals and humans. Two types of ectopic pregnancy are well recognized: Tubal and Abdominal. Tubal pregnancy is occurred when the fertilized embryo fails to travel in uterus and remains in the oviduct. Abdominal pregnancy occurs when embryo develops into abdominal cavity. Abdominal pregnancy is further divided into two forms: primary and secondary. Primary forms occur due to rearward migration of oocyte and embryo from fimbriae and oviduct and secondary form due to rupture of uterus and oviduct. Clinical findings are not the trademark for the diagnosis of extrauterine pregnancy in animals. Diagnosed by radiography, ultrasonography, computed tomography and treatment is done by surgically in animals.

Keywords: Abdominal; Bitch; Extrauterine pregnancy; Tubal

This is an open access article & it is licensed under a [Creative Commons Attribution Non-Commercial 4.0 International](https://creativecommons.org/licenses/by-nc/4.0/) (<https://creativecommons.org/licenses/by-nc/4.0/>)

Introduction

Extrauterine or ectopic pregnancy denotes the pregnancy occur elsewhere than the uterus (Corpa, 2006) or embedding and subsequent development of fertilized ovum outside the uterus (Laube, 1986). Ectopic pregnancy is abnormal, unusual and rare condition in Humans (Buckley and Caine, 1979), Baboon (Jerome & Hendrickx, 1982), Monkey (Lapin & Yakovleva, 1963), Guinea pigs (Araujo, 1964), Dog and Cat (Bunte & Hildebrandt, 1975), Rabbit (Smith *et al.*, 1989), Hamsters (Buckley and Caine, 1979), Rats (Gosden & Russel, 1981), Mice (Bloch, 1962), Mouse (King *et al.*, 1978), Mare (Freitag, 1972), Cow (Botcherby, 1980), Pigs (Hong & Armstrong, 1978) and Sheep (Davies 1982). Two main ectopic pregnancy is recognized; they are described below.

Types of Extrauterine Pregnancy

A. Tubal Pregnancy

Once mature oocyte is fertilized and then trapped in the oviduct cause tubal pregnancy in animals (Corpa, 2006). A tubal pregnancy is more common in human but it is a rare bitch due to different physiological structure of uterus (Hunter, 1994). An experiment in rabbit, rat, sheep, and pig shows tubal ligation cause degeneration of embryo rather than implant in obstructed tubes (Heap *et al.*, 1979b & Moore *et al.*, 1992). Implantation of embryo in tube may not able to recognize maternal recognition, not able to get uterine secretions, unfavorable environment for implant and luteolysis may arise (Heap *et al.*, 1979a, 1979b).

B. Abdominal Pregnancy

It occurs when the pregnancy is established in the peritoneal cavity. Abdominal pregnancy is two types; primary and secondary form. due to its way to be an occurrence.

i. Primary Form

A mature oocyte or a rearward oocyte is lost from the fimbriae or from the oviduct part, and lost embryo is fertilized into the abdominal cavity and develops there (Corpa, 2006). Another form of primary form is fertilized ova rearward and enters the peritoneal cavity. In primary form of abdominal pregnancy, placentation must occur on peritoneal or omental surface (Corpa, 2006).

ii. Secondary Form

Secondary abdominal pregnancies is due to rupture of an oviduct or the uterus after the implantation of the fetus (Smith *et al.*, 1989), this is due to trauma or by internal pressure (Owensby *et al.*, 2001). Rupture of uterus and oviduct cause the fetus expelled into the abdominal cavity (Corpa, 2006). External trauma, dead fetus, uterine torsion, excessive use of oxytocin, malpresentation of fetus, faulty obstetrical technique causes uterine rupture and may cause abdominal pregnancy in animals (Ofir *et al.*, 2003 & Hajurka *et al.*, 2005).

It is quite the difficult to difference between the primary and secondary forms of ectopic pregnancy but there is a little scar in repaired tissue of endometrium (Bunte & Hildebrandt, 1975). In primary form of abdominal pregnancy placental attachment may in mesentery, omentum, liver, spleen and large and small intestine (Kalof *et al.*, 2004). In secondary form of abdominal pregnancy, the placental attachments in endometrium and fetus can only escape in peritoneal region (Leaderer & Fisher, 1960). In both primary and secondary form of abdominal pregnancy, the fetus may die due to inadequate nutrition and blood supply (Buckley and Caine, 1979).

Aetiology

Uterine trauma, rupture (Lederer & fisher, 1960) and rearward of either fertilized or unfertilized ovum (Corpa, 2006) cause abdominal pregnancy. There is no known cause of tubal pregnancy. Abnormal uterine anatomy such as one uterine horn and urachal remnant (Hansen, 1974). These anomalous structures permit the sperm to reach and fertilize an ovum but does not allow to receive the fertilized ovum (Nack, 2000).

Clinical Findings

Clinical findings of ectopic pregnancy may vary in animals, and occasionally include gastrointestinal syndromes such as anorexia, vomiting, abdominal distension and diarrhoea (Peck and Badame 1967; Corpa 2006; Eddey 2012). In most of the cases, dogs with extrauterine fetuses are seemingly healthy and diagnosis is usually an incidental finding (Myung *et al.*, 2016).

Diagnosis

It is difficult to diagnosed extrauterine pregnant in the bitch or other animals because in this case animals seems healthy or doesn't show any symptoms. In some cases, animals may show mild symptoms which are not exact for diagnosis. If we are fully unfamiliar about history of breeding, then the extrauterine pregnancy in animals gone unnoticed. Sometimes some cases are diagnosed incidentally. Diagnosis is done by the following equipment's: Radiography, Ultrasonography, and Computed Tomography (Myung *et al.*, 2016).

Treatment

Surgical Treatment

There is various treatment for ectopic pregnancy for humans: surgical removal, medicinal treatment and expectant management. Once a tubal ectopic pregnancy in bitches is diagnosed, only treatment documented is surgical removal of uterus with or without ovary (Johnson, 1986). Rupture of uterus due to ectopic pregnancy the only treatment is laparotomy for its correction.

Conclusion

Extrauterine pregnancies is not a new case in animals. It can be found incidentally due to an irregular necropsy in animals. Different treatment method is described in human's models (surgical, medicinal and expected management) but not in animal models. Medicinal methods of treatment in humans could be implicated in animals. However, the etiological condition of extrauterine pregnancy is necessary to clarify.

Conflict of Interest

The authors declare that there is no conflict of interest with present publication.

Acknowledgement

Authors would like to thank teachers, seniors, friends and juniors of Institute Agriculture and Animal Science (IAAS) who helped directly or indirectly during this work for their help and support.

References

- Araujo P (1964) A case of ectopic abdominal pregnancy in guinea pig. *Laboratory Animal Care*. **14**: 1–5.
- Bloch S (1962) An atypical pregnancy in a laboratory mouse. *Acta Anatomica*. **51**: 148–152.
- Botcherby WC (1980) Ectopic pregnancy in a cow. *Veterinary Record*. **106**: 565–566.
- Buckley P and Caine A (1979) A high incidence of abdominal pregnancy in the Djungarian hamster (*Phodopus sungorus*). *Journal of Reproduction and Fertility*. **56**: 679–682.
- Bunte RM & Hildebrandt PK (1975) Abdominal mummified fetus in an owl monkey. *Journal of the American Veterinary Medical Association*. **167**: 667–668.



- Corpa JM (2006) Ectopic pregnancy in animals and humans. *Reproduction*. **131**: 631–640.
- Davies PT (1982) Extrauterine pregnancy in a ewe. *Veterinary Record*. **110**: 475.
- Eddey PD (2012) Ectopic pregnancy in an apparently healthy bitch. *Journal of the American Animal Hospital Association*. **48**: 194–197.
- Freytag K (1972) Secondary abdominal pregnancy in a mare. *Deutsch Tierärztliche Wochenschrift*. **79**: 522–524.
- Gosden RG and Russell JA (1981) Spontaneous abdominal implantation in the rat with development to full term. *Laboratory Animal*. **15**: 379–380.
- Hajurka J, Macak V, Hura V, Stavova L and Hajurka R (2005) Spontaneous rupture of uterus in the bitch at parturition with evisceration of puppy intestine-a case report. *Vet Med-Czech*. **50**(1): 85-88.
- Hansen JS (1974) Ectopic pregnancy in a queen with one uterine horn and a urachal remnant. *Veterinary Medicine Small Animal Clinician*. **69**: 1135–1137.
- Heap RB, Flint AP and Gadsby JE (1979a). Role of embryonic signals in the establishment of pregnancy. *British Medical Bulletin*. **35**: 129–135.
- Heap RB, Flint AP, Gadsby JE and Rice C (1979b) Hormones the early embryo and the uterine environment. *Journal of Reproduction and Fertility*. **55**: 267–275.
- Hong CC and Armstrong ML (1978) Ectopic pregnancy in 2 guinea-pigs. *Laboratory Animal*: **12**: 243–244.
- Hunter RH (1998) Have the Fallopian tubes a vital role in promoting fertility? *Acta Obstetrica et Gynecologica Scandinavica*. **77**: 475–486.
- Jerome CP and Hendrickx AG (1982) A tubal pregnancy in a rhesus monkey (*Macaca mulatta*). *Veterinary Pathology*. **19**: 239–245.
- Johnson CA (1986) Disorders of pregnancy. *Veterinary Clinics of North America Small Animal Practise*. **16**: 477–482.
- Kalof AN, Fuller B and Harmon M (2004) Splenic pregnancy: a case report and review of the literature. *Archives of Pathology & Laboratory Medicine*. **128**: e146–e148.
- King IR, Myers JD and Semmer JR (1978) Diagnosis of unruptured ectopic pregnancy by the use of the laparoscope. *Journal of the Tennessee Medical Association*. **71**: 19–21.
- Lapin BA and Yakovleva LA (1963) In Comparative Pathology in Monkey spp. 215–216. Eds B.A. Lapin & LA Yakovleva. Illinois: Charles C. Thomas Springfield.
- Laube T (1986) Primary and secondary extrauterine pregnancy in a cat. *Tierärztliche Praxis*. **14**(4): 509–513.
- Lederer HA and Fisher LE (1960) Ectopic pregnancy in a dog. *Journal of the American Veterinary Medical Association*. **137**: 61.
- Moore GD, Eddy CA and Pauerstein CJ (1992) Rabbit endosalpinx inhibits implantation in vitro. *Fertility and Sterility* **57**: 902–907.
- Myung HW, Lee AJ, Kim JY, Kim JH, Eom KD, Kim HJ and Chung DJ (2016) Secondary abdominal pregnancy with foetal mummification diagnosed using computed tomography in a dog: a case report, *Veterinari Medicina*. **61**: 51–55. Doi: 10.17221/8682-VETMED.
- Nack RA (2000) Theriogenology question of the month. An ectopic fetus. *Journal of the American Veterinary Medical Association*. **217**: 182–184.
- Ofir K, Sheiner E, Levy A, Katz M and Mazor M (2003) Uterine rupture: Risk factors and pregnancy outcome. *American Journal of Obstetrics and Gynecology*. **189**: 1042–1046.
- Owensby T, Jackson K and Scharf B (2001) Failure to deliver in a rabbit with intra-abdominal masses. *Laboratory Animal*. **30**: 23–25.
- Peck GK and Badame FG (1967) Extra-uterine pregnancy with fetal mummification and pyometra in a pomeranian. *The Canadian Veterinary Journal*. **8**: 136–137.
- Smith CA, Stone DM and Prieur DJ (1989) Spontaneous profuse superovulation in association with ectopic fetuses in a rabbit. *Laboratory Animal Science*. **39**: 74–77.