

## Original Article

## Asian Pacific Journal of Reproduction

Journal homepage: www.apjr.net



doi: 10.4103/2305–0500.288587

## Genistein improves the vaginal epithelium thickness in a rat model of vaginal atrophy through modulation of hormone and heat shock protein 70 levels

Pribakti Budinurdjaja<sup>1,2✉</sup>, I Wayan Arsana Wiyasa<sup>3</sup>, Ika Kustiyah Oktaviyanti<sup>2</sup>, Djanggan Sargowo<sup>4</sup><sup>1</sup>Doctoral Program in Medicine, Faculty of Medicine, Universitas Brawijaya, Malang, East Java, Indonesia<sup>2</sup>Department of Obstetric and Gynecology, Faculty of Medicine Universitas Lambung Mangkurat/Ulin General Hospital, Banjarmasin, South Kalimantan, Indonesia<sup>3</sup>Department of Obstetric and Gynecology, Faculty of Medicine Universitas Brawijaya/dr. Saiful Anwar General Hospital, Malang, East Java, Indonesia<sup>4</sup>Department of Cardiology and Vascular Medicine, Faculty of Medicine Universitas Brawijaya/dr. Saiful Anwar General Hospital, Malang, East Java, Indonesia

## ABSTRACT

**Objective:** To investigate whether administration of genistein can improve hormonal changes (estradiol and follicle stimulating hormone (FSH)), heat shock protein 70 (Hsp70) expression, and thickness of vaginal epithelial cells in a rat model of vaginal atrophy.

**Methods:** Twenty-five multiparous female rats were divided into five groups, namely the control group (without ovariectomy), the ovariectomy only group, and the ovariectomy groups 1, 2 and 3 receiving genistein at the doses of 0.045, 0.090 and 0.180 mg/kg body weight/day, respectively. Estradiol, FSH, and Hsp70 expression were analyzed by using the immunoassay technique. Analysis of the thickness of the vaginal epithelium was performed by histology.

**Results:** Ovariectomy significantly decreased estradiol levels compared to the control group ( $P < 0.05$ ). All doses of genistein significantly increased levels of estradiol in rats with vaginal atrophy compared to the ovariectomy only group ( $P < 0.05$ ). Ovariectomy significantly increased FSH levels compared to the control group ( $P < 0.05$ ). All three doses of genistein restored FSH levels comparable to those in the control group ( $P > 0.05$ ). Ovariectomy significantly increased parabasal cell Hsp70 expression compared to the control group ( $P < 0.05$ ). Of all the genistein doses, only the dose at 0.045 mg/kg body weight/day restored the expression of Hsp70 to levels in the control group ( $P > 0.05$ ).

**Conclusions:** Genistein is able to increase the thickness of the vaginal epithelium through hormone modulation and cellular stress suppression. Genistein is beneficial in the form of a herbal or alternative food for improvement of vaginal atrophy due to menopause.

**KEYWORDS:** Vagina; Cellular stress; Hypoestrogen; Pelvic organ prolapse

## 1. Introduction

Pelvic organ prolapse is an anatomical change characterized by a drop in the pelvic organs and other vaginal compartments[1]. The

incidence of pelvic organ prolapse is 40% in all menopausal women. Fifty percent of women who have given birth will suffer from pelvic organ prolapse. The etiology of this disorder is multifactorial, and includes age, hypoestrogenism, genetics, race, various conditions that trigger an increase in intra-abdominal pressure, parity, and connective tissue disease[2,3]. Pelvic organ prolapse treatments include pelvic wall exercises, vaginal pessarium, lifestyle modification, smoking cessation, constipation treatment, avoidance of impactful exercise, and operative correction[4,5].

Pregnancy and vaginal delivery cause the weakening of the vaginal structure[6]. Furthermore, menopausal women are at the highest risk of pelvic physical changes due to loss of estrogen. Estrogen depletion causes vaginal dryness and atrophy[7]. Vaginal atrophy is a symptom that is often overlooked in menopausal women. These structural and vaginal molecular changes have been identified in women with pelvic organ prolapse and are involved in the pathogenesis of pelvic organ prolapse[8,9]. The standard treatment for vaginal atrophy is estrogen therapy, but many women do not use it due to complications associated with the therapy[10].

Various approaches in the form of stem cell therapy and phytoestrogens have been used to treat vaginal atrophy. Stem cell therapy includes the use of adipose-derived mesenchymal stem cells[11]. Phytoestrogens are plant-derived active compounds with structural and functional similarity to estradiol[12]. Phytoestrogen containing licorice vaginal creams can improve the vaginal

✉To whom correspondence may be addressed. E-mail: budinurdjaja@yahoo.com

This is an open access article distributed under the terms of the Creative Commons Attribution-Non Commercial-Share Alike 4.0 License, which allows others to remix, tweak and build upon the work non-commercially, as long as the author is credited and the new creations are licensed under the identical terms.

**For reprints contact:** reprints@medknow.com

©2020 Asian Pacific Journal of Reproduction Produced by Wolters Kluwer- Medknow. All rights reserved.

**How to cite this article:** Budinurdjaja P, Wiyasa IWA, Oktaviyanti IK, Sargowo D. Genistein improves the vaginal epithelium thickness in a rat model of vaginal atrophy through modulation of hormone and heat shock protein 70 levels. *Asian Pac J Reprod* 2020; 9(4): 192-196.

**Article history:** Received: 10 September 2019; Revision: 22 March 2020; Accepted: 8 April 2020; Available online: 4 July 2020

maturation index, vaginal mucus cell changes, and vaginal acidity[13]. Treatment with isoflavone isolates cannot improve vaginal dryness. Phytoestrogens cannot improve the vaginal epithelium, although these results are inconsistent[14].

Genistein is the main flavonoid in leguminous plant. It is a phytoestrogen that is both an agonist and antagonist. Genistein targets the estrogen receptors  $\alpha$  and  $\beta$  but has a higher affinity for estrogen receptor  $\beta$ . Various studies have proven the potential of genistein in prevention and treatment, but its use in the treatment of vaginal atrophy is rare[15,16]. The efficacy of isoflavone products is also unclear[17]. Therefore, this study aimed to investigate whether administration of genistein can improve hormonal changes [estradiol and follicle stimulating hormone (FSH)], heat shock protein 70 (Hsp70) expression, and thickness of vaginal epithelial cells in rat models of vaginal atrophy.

## 2. Materials and methods

### 2.1. Animal

This study used female rats (*Rattus norvegicus*) with a history of giving birth three times and hypoestrogenism due to ovariectomy. The age of rats was 11 months, with average weight was 300-350 g. All animals were maintained in individual cage, received feed and drink *ad libitum*. Standard laboratory setting was adjusted at 12/12h light/dark cycle (light on at 7:00 a.m.) at an average temperature of (25±1) °C.

A total of twenty-five rats were randomly divided into five study groups, namely the control group (without ovariectomy), the ovariectomy only group, the ovariectomy group 1 treated with genistein at a dose of 0.045 mg/kg body weight/day, the ovariectomy group 2 that received genistein at a dose of 0.090 mg/kg body weight/day, and the ovariectomy group 3 given genistein at a dose of 0.180 mg/kg body weight/day. All genistein was administered to the rats *via* subcutaneous injection. These dose was adopted from previous study[18].

### 2.2. Genistein

Genistein from *Glycine max* (soya bean) was purchased from Sigma Aldrich, Singapore, with catalog number 06776. Genistein was dissolved in 1% aqueous carboxymethyl cellulose as vehicle[19]. Genistein was administered *via* subcutaneous injection. Genistein treatment began 28 days after ovariectomy and for a duration of 28 days.

### 2.3. Ovariectomy

Bilateral ovariectomy was performed seven days postpartum. Bilateral ovariectomy was performed under ketamine anesthesia at a dose of 35 mg/kg of body weight and xylazine at 5 mg/kg of body weight, delivered intraperitoneally. Before surgery, we cleaned the hair at the incision site by disinfecting the area. After that, a 1 cm incision was made over the ovary. The ovary was then removed and

ligated to the oviduct. Finally, the incision site was closed. In the control group, the procedure was carried out, without removal of the ovaries[20].

### 2.4. Analysis of estradiol levels

Analysis of estradiol levels was performed by using the enzyme-linked immunosorbent assay technique. The analysis procedure was carried out according to the manufacturer's instructions (Bioassay Technology Laboratory, Shanghai, China; Catalog No E0174Ra).

### 2.5. Analysis of FSH levels

Analysis of FSH levels was carried out by using an enzyme-linked immunosorbent assay. The analysis procedure was carried out according to the manufacturer's instructions (Bioassay Technology Laboratory, Shanghai, China; Catalog No E0182Ra).

### 2.6. Analysis of Hsp70 expression

Immunohistochemistry was used to analyze the expression level of Hsp70. The Hsp70 antibodies used were purchased from Genetex (GeneTex Inc, Taiwan, China; catalog number GTX25442).

### 2.7. Tissue isolation and analysis of vaginal epithelial thickness

After genistein treatment was completed, euthanasia was carried out for the removal of organs and blood. The vagina was removed and then rinsed in physiological saline to remove blood and a dissection of the surrounding tissue was performed. The vagina was then weighed and fixed for 48 h in a 10% neutral formalin buffer and stored in 70% ethanol at 4 °C. After dehydration and embedding in paraffin wax, tissue slices were carried out at a thickness of 5  $\mu$ m and then stained with hematoxylin eosin for histological analysis[21]. Measurement of the thickness was performed by using a light microscope (Olympus BX51, Japan) at magnification  $\times$ 400 and expressed in micrometer. Measurements were made with dot slide software (Olympus Soft Imaging Solutions GmbH, Germany) starting from the basement membrane of the superficial epithelium in 10 fields of view.

### 2.8. Statistical analysis

Data were analyzed by using analysis of variance and least significant difference-*post hoc* tests. Data were presented as mean $\pm$ standard deviations (mean $\pm$ SD).  $P < 0.05$  was considered to be statistically significant.

### 2.9. Ethics statement

This research was conducted through a research ethics study and was approved by the Research Ethics Committee, Faculty of Medicine, Universitas Lambung Mangkurat, Banjarmasin, South

Kalimantan, Indonesia (ethics approval No. 590/KEPK-FK UNLAM/EC/2018).

### 3. Results

#### 3.1. Levels of estradiol

Estradiol levels were significantly lower in the ovariectomy only group than in the control group ( $P < 0.05$ ). The various doses of genistein increased estradiol levels as compared with the ovariectomy only group ( $P < 0.05$ ), achieving a value comparable to the control group for lowest dose (0.045 mg/kg) of genistein ( $P > 0.05$ ). Genistein at dose of 0.090 or 0.180 mg/kg body weight/day significantly increased estradiol level compared with the control group or the ovariectomy only group ( $P < 0.05$ ). There was no significant difference of estradiol level between these two highest doses ( $P > 0.05$ ) (Figure 1).

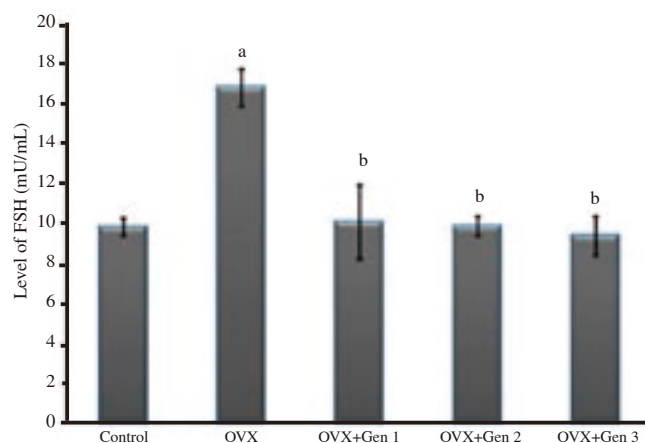
#### 3.2. Levels of FSH

There was a significant increase in FSH levels in the ovariectomy only group as compared with the control group ( $P < 0.05$ ). Various doses of genistein reduced FSH levels as compared with the ovariectomy only group ( $P < 0.05$ ), even reaching a value comparable to the control group ( $P > 0.05$ ). There were no significant differences in FSH level between groups of genistein treatment (Figure 2).

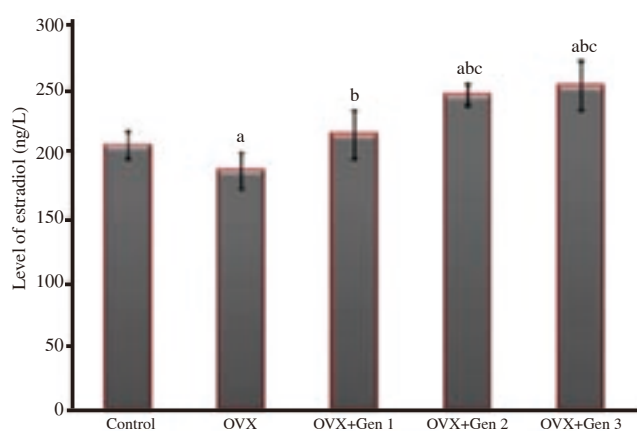
#### 3.3. Expression of Hsp70

The expression of Hsp70 was significantly higher in the ovariectomy only group than in the control group ( $P < 0.05$ ). All

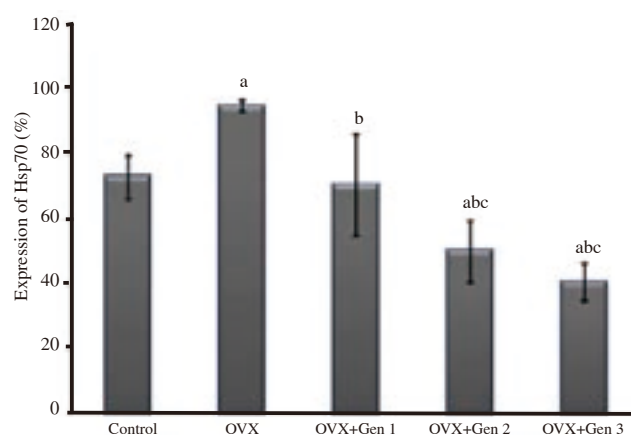
three doses of genistein administration significantly reduced Hsp70 expression as compared with the ovariectomy only group ( $P < 0.05$ ), achieving expression levels comparable to the control group for the lowest dose (0.045 mg/kg) ( $P > 0.05$ ). The expression of Hsp70 was significantly lower in genistein group at dose of 0.090 or 0.180 mg/kg body weight/day compared with the control group or the ovariectomy only group ( $P < 0.05$ ). There was no significant difference of Hsp70 level between these two highest doses ( $P > 0.05$ ) (Figure 3).



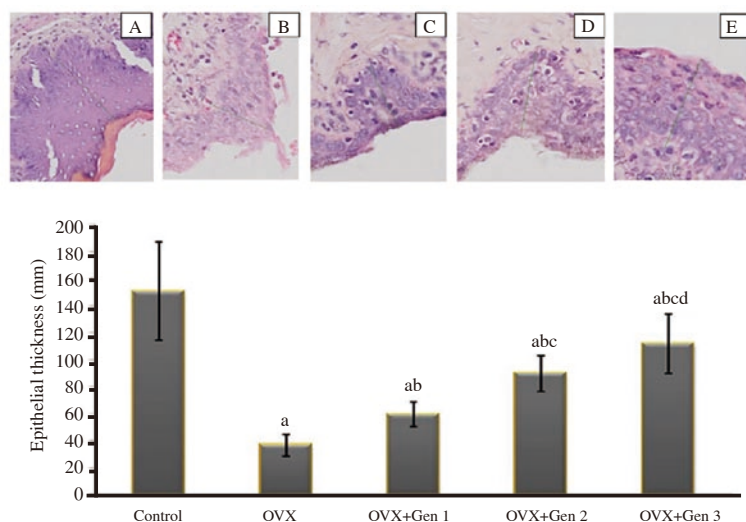
**Figure 2.** FSH levels in different treatment groups. a: There are significant differences compared with the control group ( $P < 0.05$ ); b: there are significant differences compared with the ovariectomized only group ( $P < 0.05$ ). Note: OVX: ovariectomy; OVX+Gen 1: Rats are ovariectomized and receive a genistein dose of 0.045 mg/kg body weight/day; OVX+Gen 2: Rats are ovariectomized and receive a genistein dose of 0.090 mg/kg body weight/day; OVX+Gen 3: Rats are ovariectomized and receive a genistein dose of 0.180 mg/kg body weight/day.



**Figure 1.** Levels of estradiol in different treatment groups. a: There are significant differences compared with the control group ( $P < 0.05$ ); b: there are significant differences compared with the ovariectomized only group ( $P < 0.05$ ); c: there are significant differences compared with the ovariectomized group that received genistein at the 0.045 mg/kg body weight/day dosage level (OVX+Gen 1) ( $P < 0.05$ ).



**Figure 3.** Expression of Hsp70 in different treatment groups. a: There are significant differences compared with the control group ( $P < 0.05$ ); b: there are significant differences compared with the ovariectomized only group ( $P < 0.05$ ); c: there are significant differences compared with the ovariectomized group received to genistein at the 0.045 mg/kg body weight/day (OVX+Gen 1) ( $P < 0.05$ ).



**Figure 4.** Histology of epithelial vaginal tissue in the control and treatment groups (hematoxylin eosin; magnification  $\times 400$ ) (upper panel). A: the control group; B: the ovariectomized only group; C: the ovariectomized group receiving genistein at the 0.045 mg/kg body weight/day dosage level (OVX+Gen 1); D: the ovariectomized group receiving genistein at 0.090 mg/kg body weight/day dosage level (OVX+Gen 2); E: the ovariectomized group receiving genistein at 0.180 mg/kg body weight/day dosage level (OVX+Gen 3).

Vaginal epithelial thickness in different treatment groups (lower panel). a: There are significant differences compared with the control group ( $P < 0.05$ ); b: there are significant differences compared with the ovariectomized only group ( $P < 0.05$ ); c: there are significant differences compared with the ovariectomized group received to genistein at the 0.045 mg/kg body weight/day dosage level ( $P < 0.05$ ) (OVX+Gen 1); d: there are significant differences compared with the ovariectomized group received to genistein at the 0.090 mg/kg body weight/day dosage level ( $P < 0.05$ ) (OVX+Gen 2).

### 3.4. Vaginal thickness

The thickness of the vaginal epithelium in ovariectomized rats was significantly lower than in the control group ( $P < 0.05$ ). There was a significant increase in vaginal epithelial thickness in all three ovariectomy groups treated with genistein as compared with the ovariectomy only group ( $P < 0.05$ ), but was unable to reach a thickness in the control group ( $P < 0.05$ ). The vaginal thickness was significantly higher in the 0.090 mg/kg body weight/day group compared with the 0.045 mg/kg body weight/day group ( $P < 0.05$ ). The vaginal thickness was significantly higher in the 0.180 mg/kg body weight/day group compared with the 0.090 mg/kg body weight/day group ( $P < 0.05$ ) (Figure 4).

## 4. Discussion

In this study, ovariectomy suppressed the production of estradiol and significantly increased the FSH levels as compared with the control group. This finding suggests that ovarian loss causes suppression of estradiol release accompanied by an increase in FSH levels. This study is consistent with previous studies that ovariectomy triggers a significant decrease in serum estrogen levels compared to the control group[22,23]. This increase in FSH levels was also confirmed in a previous study[24], which aimed to support the change of cholesterol into estrogen in ovariectomy rats[25]. The lowest dose of genistein can increase the levels of estradiol to levels observed in the control group. In the case of FSH, all doses of genistein suppressed the increase in FSH, reaching levels similar to that in the control group. This finding indicates that genistein can normalize the hormones, estradiol, and FSH in vaginal atrophy. This study extends previous findings that genistein can control FSH levels depending on estrogen receptor activity[26]. For hormone modulation, the normalization of estradiol levels is played by the lowest dose

genistein. Meanwhile, for FSH modulation, all genistein doses can return to normal values. These findings indicate that genistein works in the biosynthesis of estradiol and FSH. Under these pathological conditions, the optimal dose is different for modulation of estradiol or FSH.

In this study, the thickness of the vaginal epithelium decreased significantly in the ovariectomy only group as compared with the control group. This finding shows the existence of thinning or atrophy of the vaginal wall in ovariectomy rats, which is consistent with previous studies[27,28]. This depletion is thought to be caused by changes in the population of vaginal epithelial cells owing to decrease of cells proliferation, as proven in previous studies[29]. We suspect that this atrophy mechanism occurs owing to an increase in stress due to estrogen deficiency, which is characterized by estradiol deletions and significantly increased expression of Hsp70 as compared with that in the control group. This result is consistent with previous findings that Hsp70 upregulation occurs under conditions of cellular stress[30]. The mechanism of Hsp 70 changes due to ovariectomy and the effect of genistein in repairing the changes are thought to be played by heat shock factor[31].

In this study, administration of genistein increased vaginal thickness, but had not yet reached thickness in the control group. This finding indicates that genistein induces cell proliferation of vaginal epithelial cells. The mechanism of increased thickness of the epithelium is in part related to the mechanism of hormonal modulation and decreased cellular stress. Previous studies have shown that herbal contains genistein or vaginal genistein is able to improve vaginal atrophy *via* epithelial cells proliferation[16,32].

In conclusion, genistein is able to increase the thickness of the vaginal epithelium through hormone modulation and cellular stress suppression. Thus, genistein can be consumed as a herbal or alternative food for the improvement of vaginal atrophy due to menopause.

## Conflict of interest statement

The authors declare there is no conflict of interest.

## Authors' contributions

Pribakti Budinurdjaja conceived and designed the experiments, performed the experiments; analyzed and interpreted the data, contributed reagents, materials, analysis tools or data, also wrote the paper. I Wayan Arsana Wiyasa conceived and designed the experiments, analyzed and interpreted the data, and wrote the paper. Ika Kustiyah Oktaviyanti was involved in conceived and designed the experiments, performed the experiments and wrote the paper. Djanggan Sargowo conceived and designed the experiments, analyzed and interpreted the data, and wrote the paper.

## References

- [1] Hayden BT, Maher CF, Barber MD, Camargo S, Dandolu V, Digesu A, et al. An International Urogynecological Association (IUGA)/International Continence Society (ICS) joint report on the terminology for female pelvic organ prolapse (POP). *Int Urogynecol J* 2016; **27**(2): 165-194.
- [2] Ward RM, Edwards DRV, Edwards T, Giri MA, Jerome RN, Wu JM. Genetic epidemiology of pelvic organ prolapse: A systematic review. *Am J Obstet Gynecol* 2014; **211**(4): 326-335.
- [3] Smith FJ, Holman CD, Moorin RE, Tsokos N. Lifetime risk of undergoing surgery for pelvic organ prolapse. *Obstet Gynecol* 2010; **116**(5): 1096-1100.
- [4] Rantell A. Vaginal pessaries for pelvic organ prolapse and their impact on sexual function. *Sex Med Rev* 2019; **7**(4): 597-603.
- [5] Sioutis D, Reid F. Pelvic organ prolapse: Anatomical and functional assessment. *Obstet Gynecol Reprod Med* 2019; **27**(2): 57-64.
- [6] Culligan PJ. Nonsurgical management of pelvic organ prolapse. *Obstet Gynecol* 2012; **119**(4): 852-860.
- [7] Tso C, Lee W, Austin-Ketch T, Winkler H, Zitkus B. Nonsurgical treatment options for women with pelvic organ prolapse. *Nurs Women's Health* 2018; **22**(3): 228-239.
- [8] Mao M, Li Y, Zhang Y, Kang J, Zhu L. Tissue composition and biomechanical property changes in the vaginal wall of ovariectomized young rats. *Biomed Res Int* 2019; **2019**: Article ID 8921284. doi: 10.1155/2019/8921284.
- [9] Weber MA, Kleijn MH, Langendam M, Limpens J, Heineman MJ, Roovers JP. Local oestrogen for pelvic floor disorders: A systematic review. *PLoS One* 2015; **10**(9): e0136265.
- [10] Thacker HL. Assessing risks and benefits of nonhormonal treatments for vasomotor symptoms in perimenopausal and postmenopausal women. *J Women's Health* 2011; **20**(7): 1007-1016.
- [11] Kasap B, Kasap S, Vatanserver S, Kendirci R, Yilmaz O, Calisir M, et al. Effects of adipose and bone marrow-derived mesenchymal stem cells on vaginal atrophy in a rat menopause model. *Gene* 2019; **711**: 143937.
- [12] Rietjens IMCM, Lousse J, Beekmann K. The potential health effects of dietary phytoestrogens. *Br J Pharmacol* 2017; **174**(11): 1263-1280.
- [13] Sadeghi M, Namjouyan F, Cheraghian B, Abbaspoor Z. Impact of *Glycyrrhiza glabra* (licorice) vaginal cream on vaginal signs and symptoms of vaginal atrophy in postmenopausal women: A randomized double blind controlled trial. *J Trad Complement Med* 2020; **10**(2): 110-115.
- [14] Cardenas-Trowers O, Meyer I, Markland A, Richter HE, Addis I. A review of phytoestrogens and their association with pelvic floor condition. *Female Pelvic Med Reconstr Surg* 2019; **24**(3): 193-202.
- [15] Sureda A, Sanches Silva A, Isabel D, Sanchez-Machado DI, Lopez-Cervantes J, Daglia M, et al. Hypotensive effects of genistein: From chemistry to medicine. *Chem-Biol Interact* 2017; **268**: 37-46.
- [16] Le Donne M, Caruso C, Mancuso A, Costa G, Iemmo R, Pizzimenti G, et al. The effect of vaginally administered genistein in comparison with hyaluronic acid on atrophic epithelium in post-menopause. *Arch Gynecol Obstet* 2011; **283**(6): 1319-1323.
- [17] Woods NF. An overview of chronic vaginal atrophy and options for symptom management. *Nurs Women's Health* 2012; **16**(6): 482-494.
- [18] Rodríguez-Landa JF, Cueto-Escobedo J, Puga-Olguín A, Rivadeneyra-Domínguez E, Bernal-Morales B, Herrera-Huerta EV, et al. The phytoestrogen genistein produces similar effects as 17 $\beta$ -estradiol on anxiety-like behavior in rats at 12 weeks after ovariectomy. *Biomed Res Int* 2017; **2017**: Article ID 9073816. doi: 10.1155/2017/9073816.
- [19] Wu D, Meng B, Chen Y, Gan L, Huang P, Cao Y. The effect of risedronate on orthodontic tooth movement in ovariectomized rats. *Arch Oral Biol* 2019; **105**: 59-64.
- [20] Vailati S, Melloni E, Riscassi E, Roussel DB, Sardina M. Evaluation of the effects of a new intravaginal gel, containing purified bovine colostrum, on vaginal blood flow and vaginal atrophy in ovariectomized rat. *Sex Med* 2013; **1**: 35-43.
- [21] Zhu J, Xia J, Jiang J, Jiang R, He Y, Lin H. Effects of estrogen deprivation on expression of aquaporins in rat vagina. *Menopause* 2015; **22**(8): 893-898.
- [22] Kridawati A, Rahardjo TBW, Hardinsyah H, Damanik R, Hogervors E. Comparing the effect of tempe flour and tofu flour consumption on estrogen serum in ovariectomized rats. *Heliyon* 2019; **5**: e01787.
- [23] Wang H, Wang C, Sun L, Zhou S, Wang F. Research on the influence of bilateral oophorectomy on the BMD, body components, and sex hormone of women during the perimenopause. *Pak J Pharm Sci* 2017; **30**(4): 1497-1500.
- [24] Cui H, Zhao G, Wen J, Tong W. Follicle-stimulating hormone promotes the transformation of cholesterol to estrogen in mouse adipose tissue. *Biochem Biophys Res Comm* 2018; **495**(3): 2331-2337.
- [25] Arispe SA, Adams B, Adams TE. Effect of phytoestrogens on basal and GnRH-induced gonadotropin secretion. *J Endocrinol* 2013; **219**(3): 243-250.
- [26] Zin SR, Omar SZ, Khan NL, Musameh NI, Das S, Kassim NM. Effects of the phytoestrogen genistein on the development of the reproductive system of Sprague Dawley rats. *Clinics (Sao Paulo)* 2013; **68**(2): 253-262.
- [27] Basha ME, Chang S, Burrows LJ, Lassmann J, Wein AJ, Moreland RS, et al. Effect of estrogen on molecular and functional characteristics of the rodent vaginal muscularis. *J Sex Med* 2013; **10**(5): 1219-1230.
- [28] Ishii A, Ogawa B, Koyama T, Nakanishi Y, Sasaki M. Influence of the estrus cycle on the evaluation of a vaginal irritation study in intact and ovariectomized rats. *J Toxicol Pathol* 2017; **30**(2): 161-168.
- [29] Ceccarelli S, D'Amici S, Vescarelli E, Coluccio P, Matricardi P, di Gioia C, et al. Topical KGF treatment as a therapeutic strategy for vaginal atrophy in a model of ovariectomized mice. *J Cell Mol Med* 2014; **18**(9): 1895-1907.
- [30] Sisti G, Kanninen T, Ramer I, Witkin SS. Interaction between the inducible 70-kDa heat shock protein and autophagy: Effects on fertility and pregnancy. *Cell Stress Chaperon* 2015; **20**(5): 753-758.
- [31] Muhammad SI, Maznah I, Mahmud RB, Saeed MI, Imam MU, Ishaka A. Estrogen receptor modulatory effects of germinated brown rice bioactives in the uterus of rats through the regulation of estrogen-induced genes. *Drug Des Devel Ther* 2013; **7**: 1409-1420.
- [32] Jaroenporn S, Urasopon N, Watanabe G, Malaivijitnond S. Improvements of vaginal atrophy without systemic side effects after topical application of *Pueraria mirifica*, a phytoestrogen-rich herb, in postmenopausal cynomolgus macaques. *J Reprod Dev* 2014; **60**(3): 238-245.