

Original Article

Asian Pacific Journal of Reproduction

Journal homepage: www.apjr.net



doi: 10.4103/2305-0500.275635

Seasonal changes in testicular ultrasonogram pixel–intensity and their association with semen characteristics in rams

Mohamed Gamal Hedia^{1✉}, Mohamed Shehata El–Belely¹, Sayed Taha Ismail¹, Amal Mahmoud Abo El–Maaty²¹Department of Theriogenology, Faculty of Veterinary Medicine, Cairo University, Giza, Egypt²Department of Animal Reproduction and AI, Veterinary Division, National Research Center, Dokki, Giza, Egypt

ABSTRACT

Objective: To establish reference values for pixel intensity of testicular ultrasonogram of rams in breeding and non-breeding seasons, and to investigate if the seasonal changes in testicular echogenicity and heterogeneity are associated with semen characteristics.

Methods: Five Awassi rams aged 3-5 years old and weighing 45-60 kg were subjected to ultrasonographic scanning of the testes twice monthly for one year (from January 2018 to December 2018), together with semen collection and evaluation of ejaculate volume, sperm motility, sperm concentration, sperm morphology and viability. The ejaculate volume was determined in a graduated collection tube (scale of 0.1 mL). Mass and individual sperm motility was expressed in percentage of motile spermatozoa under optical microscope equipped with a warm stage. Sperm concentration was determined by using a Neubauer chamber. Semen smears stained with eosin-nigrosin were used to determine the percentage of live spermatozoa and sperm cell morphology by using a light microscope.

Results: The mean testicular pixel intensity was the lowest in winter and increased gradually from breeding season to non-breeding season, reaching its maximum value in summer ($P<0.05$). Pixel intensity was found to have a significant negative correlation with progressive motility ($r=-0.605$, $P<0.05$), and sperm concentration ($r=-0.619$, $P<0.05$). It is also positively correlated with the percentage of sperm morphological abnormalities ($r=0.666$, $P<0.05$).

Conclusions: Pixel intensity values of testicular ultrasonogram in rams undergo marked seasonal changes that are associated with fluctuations in photoperiod and ambient temperature. The resulting values of testicular echogenicity (pixel intensity) throughout the year provide useful reference values for predicting the testicular function in Awassi rams.

KEYWORDS: Testes; Echotexture; Pixel intensity; Semen; Season; Rams

1. Introduction

Reproductive performance in rams is widely dependent on the seasonal changes in average ambient temperature and photoperiod length in tropical and subtropical localities[1–4], where rams show a superior reproductive capacity during the breeding seasons (autumn and winter).

For maximal animal production, producers tend to rear a limited number of rams with high merit of reproductive efficiency, which permit them to impregnate a large number of ewes in the same flock[5]. Breeding soundness examination is used for ram selection based on a series of sequential steps, which are conducted to indirectly ensure the reproductive performance of rams through evaluation of certain physical, reproductive and ultrasonographical parameters in accordance with semen quality and plasma hormonal profile[3,6].

Ultrasound imaging is a valuable, non invasive technique, which is used to safely evaluate the external and internal reproductive organs in males[7]. Recently, the use of grey-scale ultrasound has widely been conducted in different species to assess the testicular functionality[8–10]. Interestingly, there are various methodologies available based on ultrasonographic evaluation of the testicular parenchyma and epididymis in rams[11–13]. In the first reports, ultrasound has been exclusively used for scanning of testicular parenchyma and differentiating normal testes from those with pathologies[14,15], which is followed by the application of pulsed-

✉To whom correspondence may be addressed. E-mail: mohammedhedia@cu.edu.eg

This is an open access article distributed under the terms of the Creative Commons Attribution-Non Commercial-Share Alike 4.0 License, which allows others to remix, tweak and build upon the work non-commercially, as long as the author is credited and the new creations are licensed under the identical terms.

For reprints contact: reprints@medknow.com

©2020 Asian Pacific Journal of Reproduction Produced by Wolters Kluwer- Medknow. All rights reserved.

How to cite this article: Hedia MG, El-Belely MS, Ismail ST, Abo El-Maaty AM. Seasonal changes in testicular ultrasonogram pixel-intensity and their association with semen characteristics in rams. *Asian Pac J Reprod* 2020; 9(1): 49-54.

Article history: Received: 10 July 2019; Revision: 26 October 2019; Accepted: 5 November 2019; Available online: 17 January 2020

wave Doppler analysis of testicular artery[6]. Currently, the testicular ultrasound imaging is performed by using computer-assisted software in rams, which provides visual image analysis system of previously saved B-mode ultrasound images of testicular parenchyma, and this is known as testicular ultrasonogram[11,13,16].

Ultrasonogram is composed of an array of pixels, where the variation in pixel intensities displayed in a range of shades of gray is used to determine tissue density[13,17]. Several authors have demonstrated that the changes in pixel intensity are correlated with changes that occur during the development of the reproductive organs in rams[18], bucks[10] and bulls[16]. In addition to this clear association, the changes in pixel intensity values appear to be also correlated with semen quality parameters[12,19]. Estimation of the numerical “pixel intensity” values of testicular echogenicity using computer-assisted image analysis, is expressed on a scale of 0 to 255; where 0 represents absolute black and 255 represents absolute white. Testicular heterogeneity is estimated by calculating the pixel standard deviation[10,16,17,19,20].

To the best of our knowledge, the available data to date concerning the seasonal changes in testicular echogenicity and heterogeneity are not widely investigated in rams. The rationale that seasonal variations in testicular ultrasonogram values may be associated with other seasonal changes in semen quality was checked for further functional validation. Thus, the current study aimed to determine seasonal reference values for testicular echogenicity and heterogeneity during the breeding and non-breeding seasons in fat-tailed Awassi rams, and to investigate the possible correlation between seasonal changes of these values and semen characteristics.

2. Materials and methods

2.1. Animals and management

Five adult fat-tailed Awassi rams (a native breed), weighing 45-60 kg and aged 3-5 years, were kept under natural environmental conditions. Animals received a maintenance ration and had a free access to fresh drinking water. They were previously vaccinated and received treatments for both external and internal parasites. Animals were selected after thorough clinical and andrological examination and proved to be free from any reproductive problems. Means of seasonal temperature, temperature-humidity index and sunny hours for the study period (from January 2018 to December 2018) were obtained from the Egyptian Meteorological Authority, Kobry El-Kobba, Cairo, Egypt. Seasonal average temperature, temperature-humidity index and sunny hours, respectively, were (20.5 °C, 20, 11 h) during winter, (31.5 °C, 29, 14 h) during spring, (33.0 °C, 31, 13 h) during summer and (25.0 °C, 23, 11 h) during autumn. The studied seasons were defined as the following: winter: January, February, and March; spring: April, May, and June; summer: July, August, and September; and autumn: October, November, and December. The breeding season was the period from early autumn to late winter.

2.2. Study design

All rams were subjected to semen collection followed by ultrasonographical examination of the testes twice monthly (every two weeks) for one year (January to December 2018) (*i.e.* 24 measures for each parameter/animal). Examinations were always performed between 8 and 9 am.

2.3. Semen collection and evaluation

Semen was collected by using an artificial vagina of ram (40 °C-42 °C). Fresh semen samples were directly transferred to the Seminalysis Laboratory, Faculty of Veterinary Medicine, Cairo University for immediate evaluation. Semen was evaluated according to Evans and Maxwell[21] for the following characteristics: ejaculate volume, sperm motility (mass and individual sperm motility), sperm concentration, sperm viability and sperm morphology. The ejaculate volume was determined in a graduated collection tube (scale of 0.1 mL). Mass and individual sperm motility was expressed in percentage of motile spermatozoa under optical microscope (Olympus BH-2, Olympus Optical Co. Ltd., Japan) equipped with a warm stage (100× and 400×, respectively). Sperm concentration was determined by using a Neubauer chamber. Semen smears stained with eosin-nigrosin were used to determine the percentage of live spermatozoa (400×) and sperm cell morphology by using a light microscope (under oil immersion lens, 1 000×).

2.4. Testicular ultrasonogram

All examinations were carried out by using ultrasound scanner (EXAGO, Echo Control Medical, France) equipped with a linear array transducer (7.5 MHz). The ultrasound settings (focus, gain, and brightness) were standardized and kept constant for the whole study period. All ultrasonographic examinations were performed by the same operator. The rams were restrained without sedation. To eliminate the presence of air spaces, the fine wool on both sides of the scrotum were shaved, and the transducer was covered with a copious amount of gel as a coupling material to facilitate ultrasonographic imaging. With a minimum pressure, each testis was imaged by placing the transducer vertically on the caudal aspect of the scrotum and parallel to the long axis of the testis.

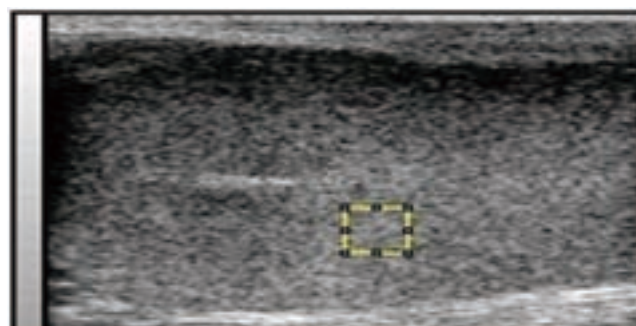


Figure 1. Ultrasonogram of the testis of Awassi rams. The figure shows placement of rectangle 0.5 to 1.0 cm deep into the parenchyma.

Table 1. Testicular ultrasonogram (pixel intensity and pixel standard deviation) as well as semen characteristics in breeding and non-breeding seasons of Awassi rams.

Parameters	Breeding season			Non-breeding season		
	Autumn	Winter	Overall	Spring	Summer	Overall
Testicular pixel intensity	83.13±7.77	83.06±6.89	83.10±7.33*	87.80±6.75	91.33±7.69	89.57±7.22#
Testicular pixel standard deviation	21.26±1.63	21.52±2.13	21.72±1.88	20.95±2.15	21.20±1.98	21.16±2.06
Semen volume (mL)	0.56±0.14	0.74±0.18	0.65±0.16 ^a	0.64±0.12	0.57±0.17	0.60±0.14#
Mass motility (%)	87.67±2.84	81.00±3.77	84.33±3.30*	86.00±3.37	87.33±2.19	86.67±2.78#
Individual motility (%)	84.33±4.66	69.67±5.46	77.00±5.06*	76.33±5.23	77.33±3.76	76.83±4.50#
Sperm viability (%)	82.67±4.63	79.33±3.15	81.00±3.89*	89.67±2.68	92.34±3.47	91.00±3.09#
Abnormality (%)	12.67±5.76	14.00±4.17	13.33±4.97*	13.33±2.89	13.33±4.72	13.30±3.80#
Sperm concentration (10 ⁹ /mL)	3.13±0.72	3.53±0.60	3.31±0.66*	3.28±0.38	1.89±0.47	2.58±0.42#

Data are represented as mean±SD. *, # within rows are significantly different at $P<0.05$.

The image was aligned until the mediastinum of the testis was clearly visible. All ultrasonograms were captured and downloaded to a computer for further analysis. Computer analysis of each image was performed by using image analysis software (ImageJ, U. S. National Institutes of Health, Maryland, USA) [22]. Testicular echogenicity (pixel intensity) and heterogeneity (pixels standard deviation) were computed on one selected area of 1 cm² per testis by drawing a rectangle 0.5 to 1.0 cm deep into the parenchyma (Figure 1) where it appeared homogenous[16]. Testicular pixel intensity represented the average value attributed to each pixel within the selected area according to the shade of gray[13].

2.5. Statistical analysis

Seasonal results of fresh semen characteristics were presented as mean±standard deviation (mean±SD). Data were analyzed by analysis of variance using general linear model procedures for repeated measurements (SPSS, version 16.0)[23]. Dependent variables in the mathematical model were pixel intensity, pixel standard deviation and semen traits. Pearson's correlation coefficients among ultrasonogram parameters and semen parameters were calculated (SPSS, version 16.0)[23]. Differences were considered significant at $\alpha = 0.05$.

2.6. Ethical approval

The present experiment was carried out at the Department of Theriogenology, Faculty of Veterinary Medicine, Cairo University, Egypt. All the experimental protocols were approved by the Ethics Committee of Cairo University (IACUC, Institutional Animal Care and Use Committee, CU || S 5 18).

3. Results

3.1. Impact of testicular laterality on echotexture assessment

There were no significant differences in testicular echogenicity

and heterogeneity measurements between the right and left testis of the same ram at each time point. Thus, the means values of the right and left testis were used for further analysis.

3.2. Semen characteristics and testicular ultrasonogram

As depicted in Table 1, semen quality parameters showed a higher values during the breeding season as compared to the non-breeding season ($P<0.05$). The overall averages of the ejaculate volume, sperm progressive motility and sperm cell concentration were significantly ($P<0.05$) higher in the breeding season. Testicular ultrasonogram showed marked changes in the measures of pixel intensity in breeding season compared with those recorded in the non-breeding season ($P<0.05$), whereas the values of pixel standard deviation (testicular heterogeneity) were not different between breeding season and non-breeding season ($P>0.05$).

3.3. Correlation coefficients

As shown in Table 2, testicular pixel intensity exhibited a moderate significant negative correlation with the percentage of progressively motile sperm ($r=-0.605$, $P<0.05$) as well as sperm cell concentration ($r=-0.619$, $P<0.05$), while it showed a positive association with the percentage of total sperm abnormalities ($r=0.666$, $P<0.05$) (Figure 2, 3).

Table 2. Correlation coefficients between testicular echotextural characteristics and parameters analyzed in fat-tailed rams.

Parameters	Testicular pixel intensity	Testicular pixel standard deviation
Sperm progressive motility	-0.605*	0.146
Sperm concentration	-0.619*	0.175
Sperm viability	-0.408	0.190
Abnormal sperm percentage	0.666*	-0.274

* Correlation is significant at $P<0.05$ level.

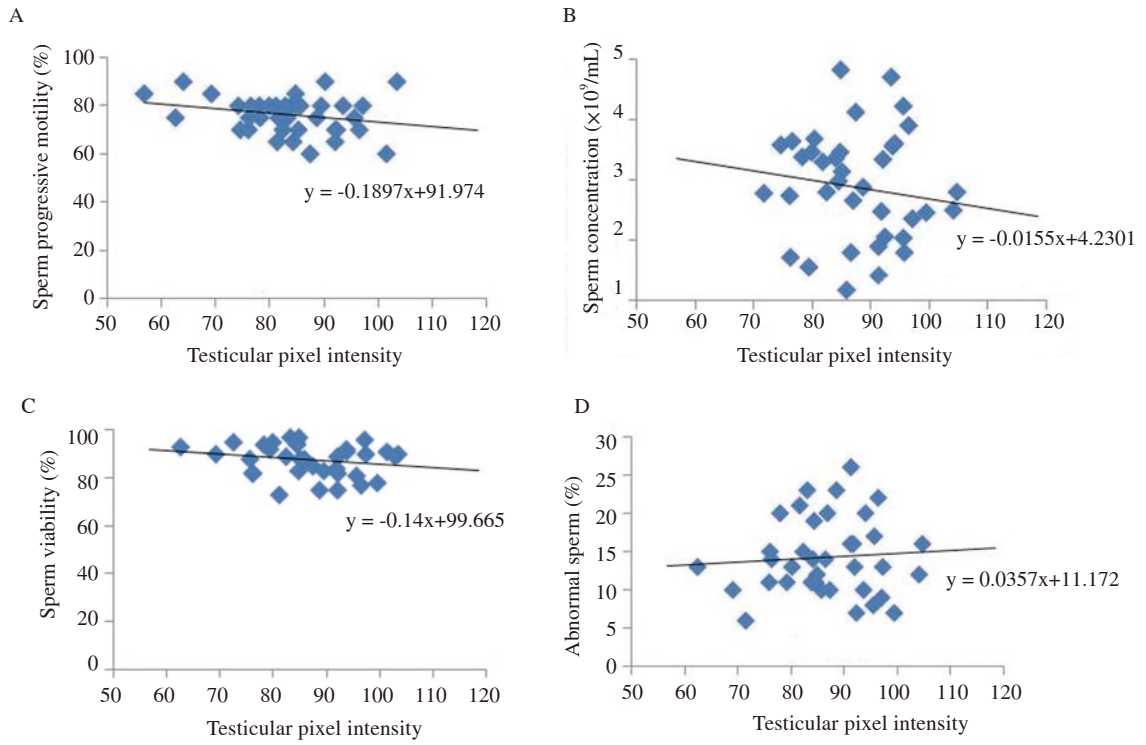


Figure 2. Correlation between testicular pixel intensity and sperm parameters.

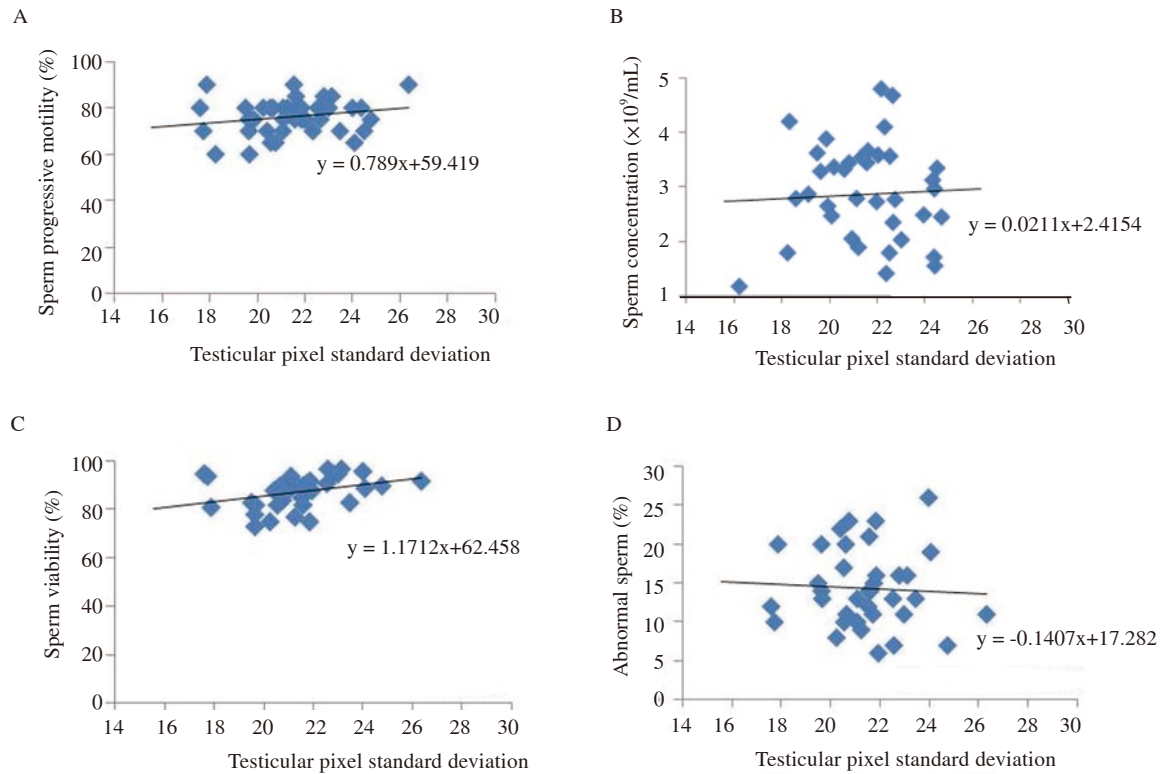


Figure 3. Correlation between testicular pixel standard deviation and sperm parameters.

4. Discussion

In the current study, significant seasonal changes in semen characteristics were noticed in Awassi fat-tailed rams. These changes were previously described in several reports concerning the Egyptian native breeds of fat-tailed rams[24,25]. These studies showed a better semen quality in autumn and winter (breeding season) compared with the spring and summer (non-breeding season).

Our results showed that the overall semen volume was similar to the value that was previously reported for the same native Egyptian breeds of fat-tailed ram[26,27], Pampinta rams[1] and Algerian rams[28]. Considering that autumn and winter are seasons with decreasing daylight, it is obvious that the present fat-tailed rams are sensitive to photoperiodism.

In the current study, semen mass activity scores (mass motility) and individual motility percentages were higher in autumn and summer compared to the other seasons. This finding was in agreement with previous several studies conducted on fat-tailed rams in different localities[25,29,30]. However, our results contradict the observation of Salem *et al*[26] and Belkhir *et al*[28] who found that sperm motility parameters were higher in breeding season (autumn and winter) than in the non-breeding season (spring and summer).

In our study, the percentage of live sperm cells was higher in non-breeding season compared with the breeding season. These results are in line with the findings of Aller *et al*[1], Kafi *et al*[29] and Pourseif *et al*[31]. However, other reports demonstrated a higher value of live sperm cells in breeding season as compared to the non-breeding season[30,32]. These different trends may be, at least in part, due to breed differences and geographical location.

In the present study, sperm concentration exhibited higher values during the breeding season as compared with the non-breeding season, which is in agreement with several previous reports[25,31]. However, these results are different from those obtained by Aller *et al*[1] and Sárlos *et al*[2], who recorded a higher range than those found in the present study. This may be due to the frequency of semen collection and the local average seasonal temperature.

As far as we know, there is very limited number of reports that describe testicular ultrasonogram and its value as a predictor of reproductive capacity in rams. One study has suggested a possible correlation between semen characteristics as well as scrotal circumference on one hand, and testicular echotexture on the other hand[11] with emphasis on season effects in mature rams.

In the present study, testicular pixel intensity showed marked higher values during the non-breeding season compared with values recorded in the breeding season. Our results were in agreement with values obtained by Ahmadi *et al*[11] in mature, healthy rams. Interestingly, several studies showed that the testicular echotexture measures had a considerable association with testicular histopathological changes in adult rams, where Ahmadi *et al*[11] and Giffin *et al*[33] recorded a positive correlation between testicular pixel intensity with seminiferous tubules and epithelium area. In addition, testicular pixel intensity measurement revealed the mean value depicted to each pixel in the selected area of assessment within the testicular parenchyma, and exhibited as shade of gray on a range of

1 to 255, where 1 recorded as black and 255 recorded as white[16]. In a previous study, Al-Ghetaa[34] demonstrated that the seminiferous tubules showed degenerative changes during the non-breeding season owing to the higher air temperature and photoperiod, which ultrasonographically[35] exhibited as white spots within the homogenous testicular parenchyma of rams.

In the present study, testicular pixel intensity showed a negative correlation with sperm cells concentration and sperm progressive motility, and a positive association with the percentage of abnormal sperm cells.

However, testicular heterogeneity (pixel standard deviation) showed no differences between the breeding and non-breeding seasons. In their report, Ahmadi *et al*[11] recorded higher significant measures of testicular heterogeneity in the non-breeding season (August), but these measures did not change in the breeding season (December and February). This discrepancy might be, at least in part, due to the native ambient temperature.

Several results of other studies, such as Ntemka *et al*[12], reported that the percentages of sperm cells viability were positively associated with testicular echotexture in rams ($r=0.6$). In addition, Ahmadi *et al*[11] investigated a linear relationship between testicular heterogeneity and future semen quality. In contrast, Tomlinson *et al*[36] recorded no significant association between the testicular echotexture and the sperm quality parameters.

In conclusion, seasonal assessment of testicular echogenicity and heterogeneity measures combined with semen characteristics in the present study show evidence that testicular echogenicity and heterogeneity is a potential indicator of reproductive performance in rams. Therefore, image analysis of testicular parenchyma can be used as prognostic tool to determine ram fertility as a step during breeding soundness examination practices in rams.

Conflict of interest statement

The authors declare that they don't have any conflict of interest.

Authors' contributions

Mohamed Hedia was the main participant during conducting the experimental protocol, Mohamed El-Belely and Sayed Ismail are the main contributors in designing the protocol and monitoring, while Amal Abo-El-Maaty was the main person during ultrasound examinations and data analysis.

References

- [1] Aller JF, Aguilar D, Vera T, Almeida GP, Alberio RH. Seasonal variation in sexual behavior, plasma testosterone and semen characteristics of Argentine Pampinta and Corriedale rams. *Spanish J Agric Res* 2012; **10**: 345-352.

- [2] Sarlós P, Egerszegi I, Balogh O, Molnár A, Cseh S, Rátky J. Seasonal changes of scrotal circumference, blood plasma testosterone concentration and semen characteristics in Racka rams. *Small Rum Res* 2013; **11**: 90-95.
- [3] Palacios C, Alvarez S, Martín-Gil J, Abecia JA. Plasma hormonal levels of rams are affected by sexual activity and confinement in a semen collection centre. *ARC J Anim Vet Sci* 2016; **2**: 15-21.
- [4] Hedia MG, El-Belely MS, Ismail ST, AboEl-Maaty AM. Monthly changes in testicular blood flow dynamics and their association with testicular volume, plasma steroid hormones profile and semen characteristics in rams. *Theriogenology* 2019; **123**: 68-73.
- [5] Fitzgerald JIM, Morgan G. Reproductive physiology of the ram. In: Youngquist RS, Threlfall WR. (eds.) *Current therapy in large animal theriogenology*. St Louis: Elsevier Inc; 2007, p. 617-619.
- [6] Batissaco L, Celeghini ECC, Pinafei FLV, Oliveria BMM, Andrade AFC, Recalde ECS, et al. Correlations between testicular hemodynamic and sperm characteristics in rams. *Braz J Vet Res Anim Sci* 2013; **50**: 384-395.
- [7] Gnemmi G, Lefebvre RC. Ultrasound imaging of the bull reproductive tract: An important field of expertise for veterinarians. *Vet Clin North Food Anim Pract* 2009; **25**(3): 767-779.
- [8] Bollwein H, Schulze JJ, Miyamoto A, Sieme H. Testicular blood flow and plasma concentrations of testosterone and total estrogen in the stallion after the administration of human chorionic gonadotropin. *J Reprod Dev* 2008; **54**: 335-339.
- [9] Zelli R, Troisi A, Elad-Ngonput A, Cardinali L, Polisca A. Evaluation of testicular artery blood flow by Doppler ultrasonography as a predictor of spermatogenesis in the dog. *Res Vet Sci* 2013; **95**: 632-637.
- [10] Kumari S, Luthra RA, Chandolia RK, Pandey AK, Swami DS, Kumar K. Ultrasonographic study of testicular development in Beetal bucks. *J Anim Res* 2015; **5**: 237-242.
- [11] Ahmadi B, Lau CP, Giffin J, Santos N, Hahnel A, Raeside J, et al. Suitability of epididymal and testicular ultrasonography and computerized image analysis for assessment of current and future semen quality in the ram. *Exp Biol Med* 2012; **237**: 186-193.
- [12] Ntemka A, Kioussis E, Boscoc C, Theodoridis A, Kourousekos G, Tsakmakidis I. Effects of testicular hemodynamic and echogenicity changes on ram semen characteristics. *Reprod Domest Anim* 2018; **53**: 50-55.
- [13] Camela SC, Nociti RP, Santos VJC, Macente BI, Murawski M, Vicente WRR, et al. Changes in testicular size, echotexture, and arterial blood flow associated with the attainment of puberty in Dorper rams raised in a subtropical climate. *Reprod Domest Anim* 2019; **54**: 131-137.
- [14] Júnior CC, Moustacas VS, Xavier MN, Costa EA, Costa LF, Silva TMA, et al. Andrological, pathologic, morphometric, and ultrasonographic findings in rams experimentally infected with *Brucella ovis*. *Small Rum Res* 2012; **102**(2-3): 213-222.
- [15] Dascanio J, Roberson J, Pfent C, Nahar VK, Arauz M, Alexander K, et al. The prevalence of ultrasonographic abnormalities and histopathologic lesions is high in testes of yearling tropical hair rams. *Vet Radiol Ultrasound* 2019; **60**(3): 338-345.
- [16] Brito LFC, Barth AD, Wilde RE, Kastelic JP. Testicular ultrasonogram pixel intensity during sexual development and its relationship with semen quality, sperm production, and quantitative testicular histology in beef bulls. *Theriogenology* 2012; **78**: 69-76.
- [17] Giffin JL, Franks SE, Rodriguez-Sosa JR, Hahnel A, Bartlewski PM. A study of morphological and haemodynamic determinants of testicular echotexture characteristics in the ram. *Exp Biol Med* 2009; **234**: 794-801.
- [18] Ribeiro MS, Quirino CR, Junior AB, Pacheco A. Biometry and ultrasound evaluation of testicles and accessory glands in Santa Ines rams. *R Bras Zootec* 2017; **46**(4): 317-323.
- [19] Arteaga AA, Barth AD, Brito LFC. Relationship between semen quality and pixel intensity of testicular ultrasonograms after scrotal insulation in beef bulls. *Theriogenology* 2005; **64**: 408-415.
- [20] Moxon R, Bright L, Pritchard B, Bowen IM, Souza MB, Silva LDM, et al. Digital image analysis of testicular and prostatic ultrasonographic echogenicity and heterogeneity in dogs and the relation to semen quality. *Anim Reprod Sci* 2015; **160**: 112-119.
- [21] Evans G, Maxwell WMC. Collection of semen. In: Maxwell WMC. (ed.) *Salamon's artificial insemination of sheep and goats*. Sydney: Butterworths; 1987, p. 85-91.
- [22] Rasband WS. Image J. U. S. National Institutes of Health, Bethesda, Maryland, USA. [Online] Available from: <http://imagej.nih.gov/ij/>; 2014.
- [23] SPSS. *Statistical package for social sciences, version 16.0*. Chicago: SPSS Inc.; 2007.
- [24] Hashem ALS. Semen physical traits and thyroid activity of Barki rams as affected by season and feeding non-edible date palm at Siwa oasis, Egypt. *World App Sci J* 2014; **30**(5): 556-566.
- [25] Taha TA, Abdel-Gawad E, Ayoub MA. Monthly variations in some reproductive parameters of Barki and Awassi rams throughout 1 year under subtropical conditions. Semen characteristics and hormonal levels. *Anim Sci* 2000; **71**: 317-324.
- [26] Salem AA, Salem IA, Aboulwaffa G. Relationship of puberty and semen characteristics to seasonal and nutritional variations in Saidi ram lambs. *Egyptian J Anim Prod* 2005; **42**: 145-156.
- [27] Hassanin SH, Hussein AF, Khattab YA, Abdalla MA. Reproductive performance of rams under arid conditions. *Life Sci J* 2013; **10**: 2596-2605.
- [28] Belkhiry Y, Bouzebda F, Bouzebda Z, Mouffok C. Age and season effects on sexual parameters in mature rams used in artificial insemination centre. *Global Vet* 2017; **18**: 31-40.
- [29] Kafi M, Safdarian M, Hashemi M. Seasonal variation in semen characteristics, scrotal circumference and libido of Persian Karakul rams. *Small Rum Res* 2004; **53**: 133-139.
- [30] Budai C, Oláh J, Egerszegi I, Jávora A, Kovács A. Seasonal variations in some reproductive parameters of Dorper rams in Hungary. *Agra Kozl* 2013; **53**: 17-20.
- [31] Pourseif MM, Moghaddam GH, Rafat SA, Daghighkia H, Pourseif A. Photoperiod as a factor for studying fluctuations of seminal traits during breeding and non-breeding season. *Iran J App Anim Sci* 2013; **3**: 313-321.
- [32] Moghaddam GH, Pourseif MM, Rafat SA. Seasonal variation in semen quantity and quality traits of Iranian crossbred rams. *Slovak J Anim Sci* 2012; **45**: 67-75.
- [33] Giffin JL. *Determinants of testicular echotexture in the sexually immature ram lamb*. PhD thesis. University of Guelph; 2014.
- [34] Al-Ghetaa HFK. Effect of environmental high temperature on the reproductive activity of Awassi ram lambs. *Iraqi J Vet Med* 2012; **36**: 244-253.
- [35] Elbaz HT, Abdel Razek EM. Ultrasonographic monitoring of reproductive organs of Barki rams during early non-breeding season. *H Adv Vet Res* 2019; **9**(2): 56-63.
- [36] Tomlinson M, Jennings A, Macrae A, Truysers I. The value of trans-scrotal ultrasonography at bull breeding soundness evaluation (BBSE): The relationship between testicular parenchymal pixel intensity and semen quality. *Theriogenology* 2017; **89**: 169-177.