



## Cystic partially differentiated nephroblastoma: A rare case of kidney tumor in an infant

Padmapriya Balakrishnan<sup>1</sup>, Thirunavukkarasu Arun Babu<sup>2</sup>, Vijayan Sharmila<sup>3</sup>

<sup>1</sup>MBBS Graduate, Indira Gandhi Medical College & Research Institute (IGMC&RI), Puducherry, India

<sup>2</sup>Department of Pediatrics, All India Institute of Medical Sciences (AIIMS), Mangalagiri, Andhra Pradesh, India

<sup>3</sup>Department of Obstetrics & Gynecology, All India Institute of Medical Sciences (AIIMS), Mangalagiri, Andhra Pradesh, India

### ABSTRACT

Cystic partially differentiated nephroblastoma (CPDN) is among the rare kidney tumors of childhood. Here, a case of CPDN in a baby who was operated with the diagnosis of multicystic kidney is reported. Clinical and imaging studies have a limited role in the differential diagnosis and diagnosis of this entity. A careful histopathological study is required to distinguish between CPDN and other types of multicystic kidneys. Because of the rare potential for aggressive behavior of this tumor, nephrectomy is the treatment of choice alone.

**Key Words:** Infancy, multicystic kidney, cystic partially differentiated nephroblastoma.

© 2020 [pediatricurologycasereports.com](http://www.pediatricurologycasereports.com)

✉ Dr. Thirunavukkarasu Arun Babu  
Department of Pediatrics, All India Institute of Medical  
Sciences (AIIMS), Mangalagiri, Andhra Pradesh,  
India

E-mail: [babuarun@yahoo.com](mailto:babuarun@yahoo.com)

Received: 2020-09-01 / Revisions: 2020-09-20

Accepted: 2020-09-22 / Publication Date: 2020-11-01

### Introduction

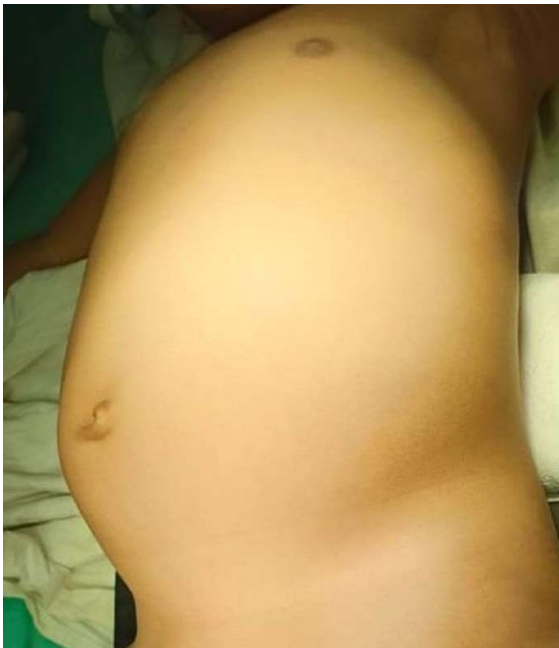Cystic kidney diseases in infancy include various diseases such as polycystic kidney disease, hydatid cyst of the kidney, multicystic kidney dysplasia, cystic variant of Wilms' tumor, and cystic variant of mesoblastic nephroma, cystic clear cell sarcoma and multilocular cystic kidney tumors [1,2,3]. The most common cause of multicystic kidney in early infancy is mesoblastic nephroma. Multilocular cystic renal tumors of infancy are classified into cystic nephroma (CN) and

cystic partially differentiated nephroblastoma (CPDN) [2]. CPDN is a relatively rare tumor of the kidney usually affecting infants [4]. It is part of a spectrum of multicystic renal tumors that also includes CN and cystic Wilms' tumor (CWT) [5]. Therefore, they must be distinguished from CPDN. Additionally, a careful histopathological study is required to distinguish between CPDN and other types of multicystic kidneys. CPDN is characterized by multicystic lesions containing blastemal cells with variably differentiated epithelial and stromal elements in the septa [3]. In general, nephrectomy alone appears to be sufficient to treat CPDN, but regular monitoring with non-invasive techniques is recommended [3].

We are reporting a case of CPDN in an infant with multicystic kidney disease owing to its rarity.

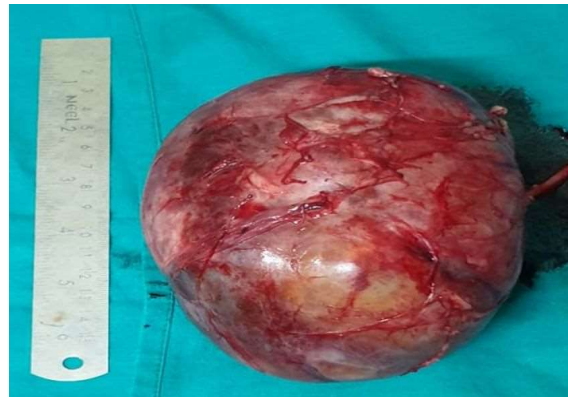### Case report

A 1 year old male child born to non-consanguineous parents was brought with complaints of painless palpable abdominal mass for 3 months. The lump was initially smaller in size and gradually progressed to the present size. There was no history of hematuria, fever and difficulty in passing urine. There was no family history of renal disease or renal mass. There was no history of anomalies in antenatal ultrasonogram and postnatal period was uneventful with no neonatal intensive care unit (NICU) admission. The child was active, playful and alert during examination. Head to toe examination was normal with no evidence of dysmorphism or associated congenital anomalies. Vitals were within normal limits. There was no pallor, fever, lymphadenopathy or pedal edema. On abdominal examination, a well circumscribed mass of size 9x9 cm was palpable in left lumbar region bimanually which was mobile, firm, nontender and ballotable (Fig. 1).

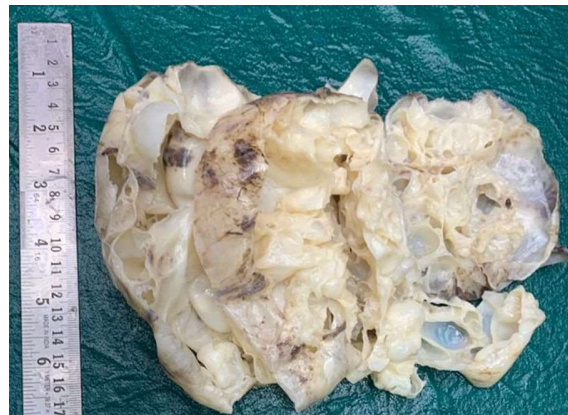

**Fig. 1.** Preoperative photograph of infant with left lumbar region mass.

Normal bowel sounds were heard. There was no hepatosplenomegaly and ascites. His complete blood picture and renal function tests were within normal limits. Ultrasound showed unilateral multilocular cystic mass of left kidney of 10x9x10 cm and normal right kidney which was confirmed by CT abdomen. Child underwent left sided nephrectomy under general anesthesia (Fig. 2). Grossly, cut section of kidney showed multilocular cysts filled with clear fluid (Fig. 3).



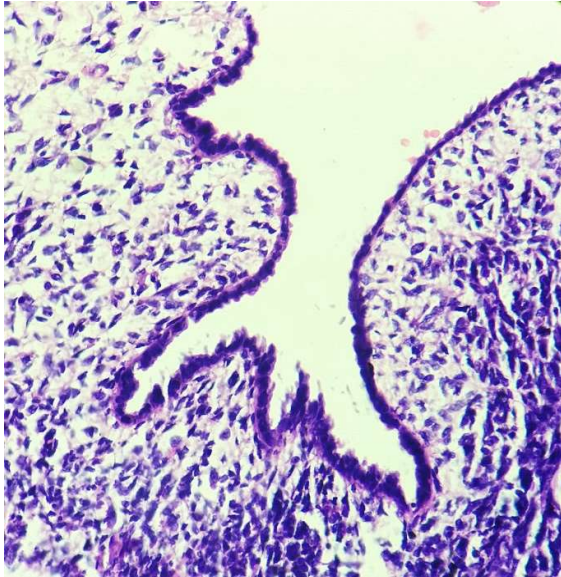
**Fig. 2.** Gross photograph of total the left nephrectomy specimen.



**Fig. 3.** Cut section of specimen showed multilocular cystic kidney filled with clear fluid and no solid nodular area.

Histopathological examination showed multiloculated cysts lined by flattened

epithelium with more than 50% of septal wall showing immature blastemal cells. There were no epithelial, stromal and heterologous elements (Fig. 4). The diagnosis of cystic partially differentiated nephroblastoma was made.



**Fig. 4.** Photomicrograph showing cysts wall lined by flattened epithelium with septal wall showing immature blastemal cells (H&E stain 40 x).

The child was advised to follow up regularly with abdominal ultrasound every 6 months, and his condition was good and there were no signs of recurrence.

### Discussion

Unilateral painless abdominal mass in an infant is mostly of renal origin. The common cystic tumors of kidney in infancy are cystic variant of Wilms' tumor, cystic variant of mesoblastic nephroma and multilocular cystic renal tumours such as cystic nephroma and CPDN [1,2, 3]. Mesoblastic nephroma can be diagnosed mostly by antenatal ultrasound examination within 3 months of postnatal period. Cystic variant of Wilms' tumor is

associated with family history of renal mass and congenital anomalies in child which were absent in our case. Cystic change in Wilms' tumor is due to degeneration and necrosis of solid part of tumor and is a risk factor for tumor rupture. The Wilms' tumor also presents with hematuria, anemia and hypertension in child.

The most common presentation of CPDN is abdominal mass as in our case. To diagnose multilocular cystic renal tumor, grossly, kidney should contain multiple septations with non-communicating locules which are filled with clear fluid without any solid area as in our case [1]. Multiloculated cystic renal tumor comprises of cystic nephroma and CPDN which can be distinguished only by histopathology. CN has differentiated elements such as tubules, glomeruli in septal wall whereas CPDN shows immature blastemal cells in septal wall [1,3]. As per literature, our case was categorized as grade 2 CPDN where more than 50% of septal wall showed immature blastemal cells [1]. CN, CPDN and Wilms' tumor are spectrum of renal tumors where CN is benign, CPDN has intermediate behavior and Wilms' tumor has malignant behavior [2,6,7]. CPDN is considered to have low malignant potential because of immature blastemal cells [2,7]. The preferred treatment option is total nephrectomy and regular follow up visits with postoperative surveillance by imaging [1,3,6]. CPDN is a rare cause of cystic renal disease and awareness about its low malignant potential and need for regular follow up following surgery is required [5]. However, 2 pediatric cases with intra-abdominal recurrence without metastasis due to incomplete resection and cyst rupture have been reported [3,8].

### Conclusion

We report a rare case of CPDN in an infant with right multicystic kidney. CPDN is a rare

condition which requires knowledge and high index of suspicion for timely diagnosis. Awareness about its low malignant potential is needed to plan appropriate management and regular follow up of patients.

### **Compliance with ethical statements**

*Conflicts of Interest:* None.

*Financial disclosure:* None.

*Consent:* Patient confidentiality is maintained and written consent for the publication of patient details and clinical pictures in this journal has been obtained from the patient's parents or closest relative and can be given as required.

### **ORCID iD of the author (s)**

Padmapriya B / 0000-0002-0129-4616

Thirunavukkarasu AB / 0000-0003-1123-5270

Vijayan S / 0000-0003-4821-561X

### **References**

- [1]Agrons GA, Wagner BJ, Davidson AJ, et al. Multilocular cystic renal tumor in children: radiologic-pathologic correlation. *Radiographics.* 1995;15(3):653-69.
- [2]Singh S, Gupta R, Khurana N. Cystic partially differentiated nephroblastoma: a rare differentiated variant of Wilm's tumour. *J Postgrad Med.* 2006;52(1):45-46.
- [3]Joshi VV, Beckwith JB. Multilocular cyst of the kidney (cystic nephroma) and cystic, partially differentiated nephroblastoma. Terminology and criteria for diagnosis. *Cancer.* 1989;64(29):466-79.
- [4]Puvaneswary M, Macintosh J, Cassey J. Cystic partially differentiated nephroblastoma. *Australas Radiol.* 2006;50(3):255-57.
- [5]Cordeiro LPV, Carvalho ACM, Silva IM, et al. Cystic partially differentiated nephroblastoma: a rare pediatric renal tumor-case report. *Radiol Case Rep.* 2020;15(8):1133-37.
- [6]van den Hoek J, de Krijger R, van de Ven K, et al. Cystic nephroma, cystic partially differentiated nephroblastoma and cystic Wilms' tumor in children: a spectrum with therapeutic dilemmas. *Urol Int.* 2009;82(1):65-70.
- [7]Joshi VV, Beckwith JB. Pathologic delineation of the papillonodular type of cystic partially differentiated nephroblastoma. A review of 11 cases. *Cancer* 1990;66(7):1568-577.
- [8]Baker JM, Viero S, Kim PC, et al. Stage III cystic partially differentiated nephroblastoma recurring after nephrectomy and chemotherapy. *Pediatr Blood Cancer.* 2008;50(1):129-31.