



Benign fibroepithelial polyps causing ureteropelvic junction obstruction in a child: A case report

SeyyedMohammad Ghahestani¹,  Elaheh Shahab²

¹Division of Pediatric Urology, Pediatric Center of Excellence, Tehran University of Medical Sciences, Tehran, Iran.

²Department of Surgery, Kosar General Hospital, Semnan University of Medical Sciences, Semnan, Iran.

ABSTRACT

The fibroepithelial polyps of the ureter are benign tumors derived from mesenchymal tissue, which can rarely cause obstruction of the ureteropelvic junction in children. Because the fibroepithelial ureteral polyps are difficult to accurately diagnose preoperatively, multiple diagnostic procedures are required for diagnosis. We report the case of a 5-year-old boy with intermittent gross hematuria, left flank pain and hydronephrosis diagnosed with fibroepithelial polyp by ultrasonography. We performed ureteroscopy to confirm the diagnosis and localize the polyp, which led us to surgical exploration and dismembered pyeloplasty due to the multiplicity and large size of the polyps. At the 18-month follow-up, the patient is recurrence-free.

Key Words: Ureteropelvic junction obstruction, fibroepithelial polyps, hydronephrosis, renal ultrasound, children.

© 2020 [pediatricurologycasereports.com](http://www.pediatricurologycasereports.com)

✉ Dr. SeyyedMohammad Ghahestani

Division of Pediatric Urology, Pediatric Center of Excellence, Tehran University of Medical Sciences, Tehran, Iran.

E-mail: mgrosva@gmail.com

Received: 2020-05-01 / Revisions 2020-05-08

Accepted: 2020-05-10 / Publication Date: 2020-07-01

Introduction

Fibroepithelial polyps (FEPs) are rare benign mesodermal tumors of the urinary tract. The exact etiology of FEPs is unknown; however, it has been suggested that the development of pathology can be caused by chronic inflammation, allergic factors, trauma, developmental disorders and congenital causes [1]. Initially, they were thought to cause only 0.5% of ureteropelvic junction (UPJ)

obstructions, but recent publications report around 5% higher incidence in the pediatric population [1,2]. Hematuria and / or flank pain caused by obstructive hydronephrosis are the most common symptoms of pyeloureteral polyps [1,2]. The pre-operative diagnosis of FEPs, due to failure of conventional imaging methods to visualize ureter and UPJ area, is challenging [3,4].

In this report, we describe a case of a 5-year old boy with occasional hematuria and recently left flank pain, found to have FEPs on ultrasonography (US).

Case report

A 5-year old boy, without medical or surgical history, presented with intermittent gross

hematuria from 6 months ago and left renal colic pain from the day before.

He was normal on physical examination and had negative urine culture. The renal function test and hemogram were also normal.

Renal Doppler ultrasound showed left severe hydronephrosis and an intra-luminal protruding lesion of 21×6 millimeters located at the proximal ureter with minimal vascularization (Fig. 1).

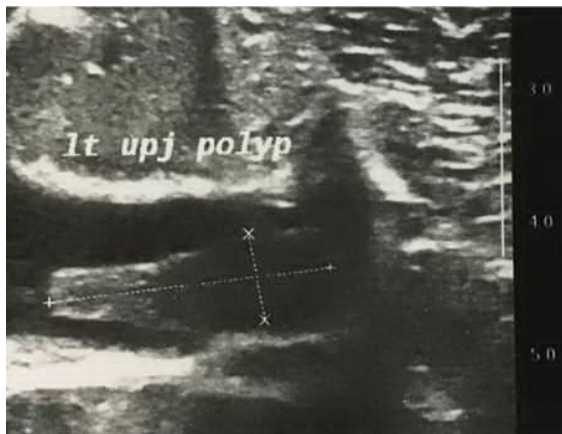


Fig. 1. Sonographic image demonstrating the fibroepithelial polyp.

No vesicoureteral reflux was detected on voiding cystourethrogram. Diuretic diethylenetriaminepentaacetic acid (DTPA) renal scan showed obstructive drainage pattern for left kidney and a 57% of total renal function.

On ureteroscopic vision, multiple UPJ polyps with the largest size of 20 millimeters were observed fluttering back and forth into the ureteropelvic junction area with ureteroscope water stream. The intertwined polyp stalks evoked an image of mythological Medusa hair. We proceeded to a cold cup biopsy through the ureteroscope which did not prove to be successful due to the relatively weak jaws of cold cup biopsy instrument, to pick off a bite of the polypoid lesion. Moreover, we did not

expect a real change of treatment protocol regarding the quite specific endoscopic appearance of a polypoid diffuse benign lesion. There upon we decided in fact to proceed to open exploration and resection of the whole involved segment. Hence, we supposed surgical UPJ exploration would be more practical than endoscopic ablation. Typical smooth lined, finger like appearance of the polyps obviated the need to perform biopsies or abandon the certain surgery.

Operative report

By left flank incision, enlarged left renal pelvis and ureter were exposed. A transverse incision of UPJ revealed multiple finger like polyps emanating from the upper ureter and UPJ (Fig. 2). These segments along with the polyps were resected and dismembered pyeloplasty with stent placement proceeded. Regarding the segment of diseased ureter needing complete excision was 4 cm long, renal descent with nephropexy was required to address undue tension.

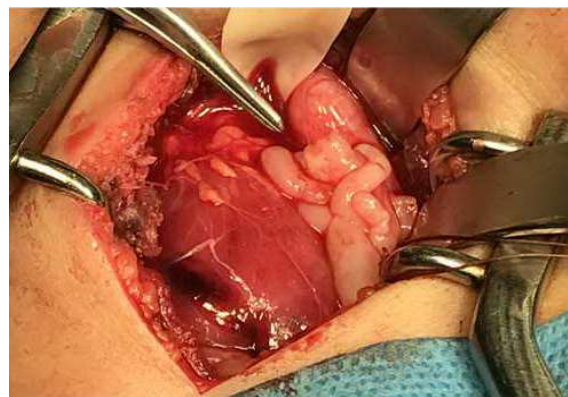


Fig. 2. Intraoperative photograph of several finger-like polyps in the left ureteropelvic region.

Post-operative course

The patient was discharged 2 days after surgery with no complication during post-

operative period. Double J stent was removed 1 month later while performing ureteroscopy to rule out any residual polyps or obstructions. Microscopic examination revealed multiple polypoid projections covering each mucosal layer with low vascularity loose fibrous tissue (Fig. 3). Obvious stromal edema was noted on most specimens. Mast cells and scattered eosinophils indicating moderate inflammation were observed (Fig. 4). The epithelial layer was transitional without any ulceration or malignant changes.

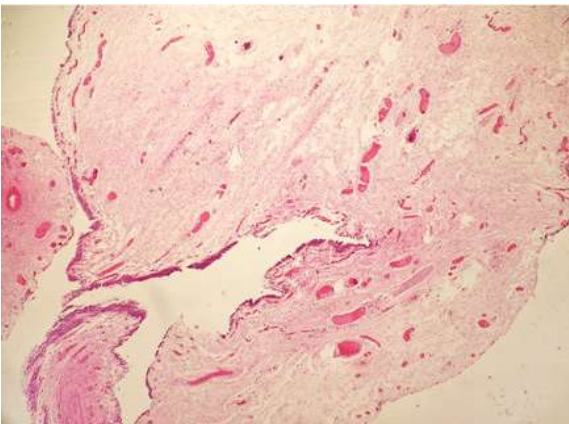


Fig. 3. Microscopic section of the polyps showing fibrous projections lined by transitional epithelium (H& E, original magnification $\times 40$).

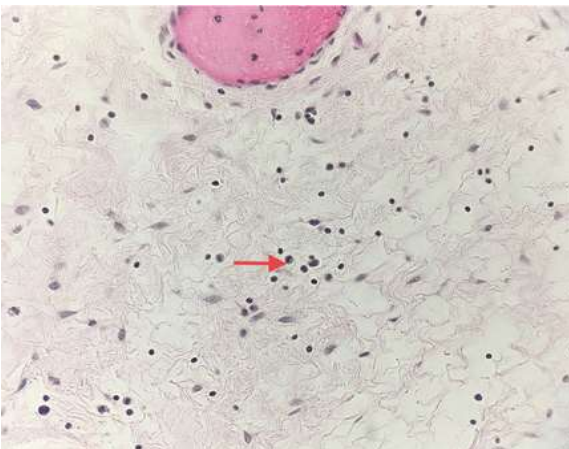


Fig. 4. Fibrous core showing low vascularity, scattered eosinophils (red arrow) (H&E, original magnification $\times 100$).

Concerning pathology report, the patient was started on 5mg Prednisolone for 3 months and Monteleukast 5mg a day for one year after which tapering was done under closer follow up. This medical protocol was presumptive and empirical based on reports of eosinophilic cystitis treatments [5,6].

Follow up was not clearly defined in the literature but three monthly sonograms showed no recurrence of echogenic polyps or increase of hydronephrosis. On 3-month post-operation DTPA scan with Lasix, no obstruction was visible.

Discussion

FEPs are most frequently arise from UPJ area and proximal ureter. They are more common in adults and, male gender left side is more affected [7]. Imaging studies such as ultrasonography, CT scans, nuclear medicine kidney scans and retrograde urograms can be performed to diagnose FEPs. Additionally, an often underutilized modality in children is the less invasive, non-radiating, magnetic resonance urography (MRU) [8]. Contrast studies are more favored in diagnosis of upper urinary tract polyps, but they are rarely conducted in children population [3,4]. Since the inadequacy of sonography in visualization of UPJ area, detection of FEPs by sonography is seldom reported in literature [3]. In our case, multiplicity and large size of ureteral polyps may have made diagnosis by sonography more comfortable.

Currently, endoscopic evaluation of the urinary tract has become the mainstay of diagnosis and treatment of FEPs [9,10]. It permits complete visualization of the ureter to rule out synchronous polyps along with localizing and defining polyps' appearances, in order to proceed with endoscopic resection if possible. Multiple, broad-based or large polyps

of the UPJ are better treated by dismembered pyeloplasty to prevent incomplete treatment and recurrence of UPJ obstruction [10].

We performed ureteroscopy directly after detection of UPJ polyps on sonography and confirming obstruction on diuretic renogram, in order to reduce undue expenses of further diagnostic modalities and trial of endoscopic treatment.

Conclusion

Pre-operative diagnosis of UPJ polyps is difficult. Although different diagnostic modalities have been proposed for better diagnosis, there is consensus on sonography being the appropriate first step in management of renal colic and hematuria. In case of intraluminal echogenic lesions of the ureter suggesting FEPs, ureteroscopy is favored for polyp mapping. Multiple or large, broad-based UPJ polyps are better treated by dismembered pyeloplasty, which seems curative with lasting results.

Compliance with ethical statements

Conflicts of Interest: None.

Financial disclosure: None.

Consent: Informed and written consent were taken from patient and her parents to publish this case report.

ORCID iD of the author (s)

SeyyedM Ghahestani / 0000-0002-9056-8892

Elaheh Shahab / 0000-0002-9144-5720

References

- [1] Delia EC, Sherwood W, Joseph VT. Fibroepithelial polyps causing ureteropelvic junction obstruction in children—a case report and review article. *Eur J Pediatric Surg.* 2007; 17(2): 142-46.
- [2] Horebeek IV, Wyndaele M, Verlindeet P, et al. Fibroepithelial ureteral polyps as a cause of ureteropelvic junction obstruction in children: A case report. *Pediatr Urol Case Rep.* 2016;3(5):147-52.
- [3] Adey GS, Vargas SO, Retik AB, et al. Fibroepithelial polyps causing ureteropelvic junction obstruction in children. *J Urol.* 2003; 169(5): 1834-36.
- [4] Patheyar V, Venkatesh SK, Siew EPY, et al. MR imaging features of fibroepithelial ureteral polyp in a patient with duplicated upper urinary tract. *Singapore Med J.* 2011; 52(3): 45-47.
- [5] van den Ouden D, van Kaam N, Eland D. Eosinophilic Cystitis presenting as urinary retention. *Urol Int.* 2001; 66(1): 22-26.
- [6] Sterrett S, Morton J, Perry D, et al. Eosinophilic cystitis: successful long-term treatment with montelukast sodium. *Urology.* 2006; 67(2): 423e19-423e21.
- [7] Ezekiel A, Agrawal V, Romero E, et al. Benign fibroepithelial polyps: A rare cause of ureteropelvic junction obstruction in children. *Urol Case Rep.* 2015;3(4):111-13.
- [8] Chang HH, Ray P, Ockuly E, et al. Benign fibrous ureteral polyp. *Urology.* 1987; 30(2): 114-18.
- [9] Chaker K, Rhouma SB, Daly KM, et al. Benign fibroepithelial polyp of the ureter: a case report. *Urology Case Reports.* 2018; 22: 52-33.
- [10] Li R, Lightfoot M, Alsyof M, et al. Diagnosis and management of ureteral fibroepithelial polyps in children: a new treatment algorithm. *J Pediatr Urol.* 2015; 11(1): 22e1-22e6.