

Intestinal Metaplasia of the Bladder: A Rare Case Report

Nadir Bir Olgu Sunumu: Mesanenin İntestinal Metaplazisi

Ekrem Akdeniz¹, Kemal Öztürk¹, Metin Gür¹, Mahmut Ulubay², Mustafa Bakırtaş³, Süleyman Tümer Çalışkan¹

¹ Samsun Gazi Devlet Hastanesi, Üroloji Kliniği, Samsun

² Sağlık Bilimleri Üniversitesi, Samsun Eğitim ve Araştırma Hastanesi, Üroloji Kliniği, Samsun

³ Sağlık Bilimleri Üniversitesi, Samsun Eğitim ve Araştırma Hastanesi, Patoloji Kliniği, Samsun



Geliş tarihi (Submitted): 16.08.2019

Kabul tarihi (Accepted): 11.12.2019

Yazışma / Correspondence

Ekrem Akdeniz

Baris Bulvari, Kadikoy Mahallesi,
No:199, İlkadim, 55090, Samsun /
Turkey

Tel: +90 362 311 30 30

E-mail: ekrem.akdeniz@saglik.gov.tr

ORCID

E.A. 0000-0002-0666-9579

K.Ö. 0000-0001-7555-4209

M.G. 0000-0002-4130-1630

M.U. 0000-0001-6049-6448

M.B. 0000-0003-3185-6947

ST.Ç. 0000-0001-8940-2476



Bu eser [Creative Commons Atf-
GayriTicari 4.0](https://creativecommons.org/licenses/by-nc/4.0/) Uluslararası Lisansı
ile lisanslanmıştır.

Özet

Mesanenin intestinal metaplazisi ürotelyumda intestinal epitelin varlığı ile karakterize oldukça nadir görülen benign bir lezyondur. Patogenezi belli değildir ve adenokarsinom prekürsörü olduğu tartışmalıdır. Bu çalışmada hematurü ve mukozürü ile tarafımıza başvuran, yapılan ultrasonografide mesanede düzgün sınırlı 32x25x6 mm kitle izlenen, transüretal rezeksiyon yapılan ve patolojisi sistitis glandularis arka planında intestinal metaplazi çıkan hastanın klinik bulguları sunulmuştur.

Anahtar Kelimeler: Mesane tümörü, İntestinal metaplazi, Transüretal rezeksiyon

Abstract

Intestinal metaplasia of the bladder, characterized by the presence of an intestinal-type epithelium in the urothelium, is a glandular proliferation and extremely rare benign lesion. The pathogenesis of this uncommon entity is unclear, and its role as a precursor of adenocarcinoma is controversial. We present a case of a 45-year-old man admitted with macroscopic hematuria and mucosuria. Ultrasound showed a 32x25x6 mm hypoechoic nodule with regular contours on the posterior wall. Histopathological examination following transurethral resection revealed an intestinal metaplasia against a background of cystitis glandularis.

Keywords: Bladder neoplasm, Intestinal metaplasia, Transurethral resection

INTRODUCTION

Intestinal metaplasia (IM) of the bladder, characterized by the presence of intestinal-type epithelium in the urothelium, is a glandular proliferation and extremely rare benign lesion. IM is generally seen in the fifth and sixth decades, and affects men much more frequently than women (1). The incidence is 0.1-0.9%, and the condition is associated with chronic irritation of the urothelium (2). Hematuria is the most common finding, and clinical features are similar to those of other bladder tumors without mucosuria (1). The pathogenesis of this uncommon lesion is unclear, and its role as a precursor of adenocarcinoma is controversial (3). It generally occurs on the trigone in the bladder, and transurethral resection (TUR) represents the principal treatment (1). We present a case of IM of the bladder.

CASE REPORT

A 45-year-old man was admitted to our clinic with macroscopic hematuria and mucosuria persisting for the previous six months. He had no history of smoking and comorbidities. Physical examination and serum biochemistry values were normal. Ultrasound showed a hypoechoic nodule on the posterior wall, 32 mm × 25 mm × 6 mm in size, with regular contours. Flexible cystoscopy was performed, and the mass was visualized endoscopically (Figure 1).

TUR of the mass was performed, with complete removal of all visible lesions. Macroscopic examination

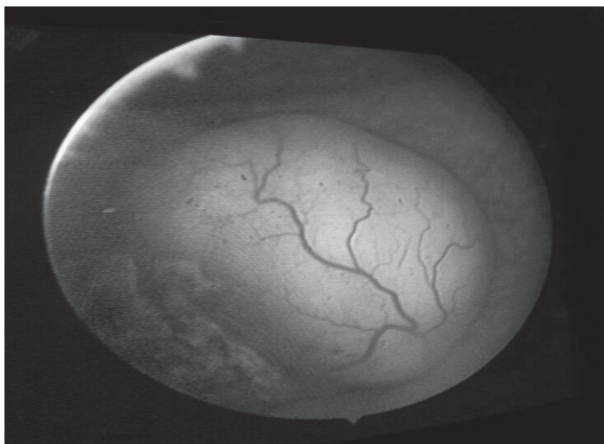


Figure 1. Endoscopic image of the mass

of the resection material revealed a gray-white necrotic lesion. Microscopic examination revealed intestinal metaplasia exhibiting cystic dilations and cystitis glandularis in the form of cystic cavities, the lumen being filled with mucoid material. The material accumulated in the cyst lumen stained positive with PAS, and tissue CDX2 staining was positive at immunohistochemical examination.

The patient was diagnosed with IM against a background of cystitis glandularis. No complication occurred in the early or late postoperative periods. Computed tomography urogram scans revealed no pathology. No adjuvant therapy was administered.

DISCUSSION

IM of the bladder is defined by the presence of intestinal type epithelium in the bladder. It may be focal or diffuse, and is thought to be a reactive process in response to urothelial injury, such as chronic infection or irritation, as seen in patients with a neurogenic bladder, stone disease, persistent infection or long-term catheterization (4). The lesion is rare, and is more common in men. It is most frequently identified at the bladder trigone, but can also be seen in the ureter and renal pelvis. IM of the bladder can be effectively treated with TUR (1).

Mucinous cystadenoma, mucinous adenocarcinoma and IM of the bladder are histologically very similar. The glands being regular, atypia in cells being at a moderate level, and absence of invasion findings are shared characteristics among the three. However, while IM of the bladder stains positive with CDX2, this does not occur with mucinous cystadenoma (5). In intestinal type cystitis glandularis, an intestinal epithelium occurs between the luminal cells and goblet cells, and this may be confused with adenocarcinoma. Adenocarcinomas are characterized by deep invasion of the lamina propria by irregular glands, and greater nuclear atypia and mitosis. Mucin pools due to mucin extravasation may also be seen in intestinal type cystitis glandularis. Similar mucin pools are also a frequent finding in mucinous adenocarcinoma, but this can be differentiated from intestinal type cystitis glandularis

by the presence of floating cells inside the pools and atypia in the epithelium lining the cyst (3).

IM of the bladder is a benign lesion. However, its association with adenocarcinoma of the bladder is controversial (3, 4). Corica et al. followed-up 53 IM patients for 10 years and concluded that IM is not a precancerous risk factor for adenocarcinoma after observing that no adenocarcinoma developed in any cases (6). Xin et al. followed-up 89 patients with IM of the bladder for a mean 105 months, and reported development of adenocarcinoma in only one patient with high-grade dysplasia (1). However, another study on this subject reported that presence of low- or high-grade dysplasia in IM is linked to adenocarcinoma, and described high-grade dysplasia IM as a high precancerous risk factor for adenocarcinoma (2).

CONCLUSION

The recurrence rate in IM of the bladder, which closely resembles other bladder tumors in terms of clinical and macroscopic findings, is 4.5% (1). The natural history of IM is unknown, and close surveillance is therefore not necessary. Subsequent cystoscopy should be repeated every three months, and semianual or annual surveillance with CT studies should be recommended for evaluation of the perivesical tissues. Further epidemiologic and clinical studies are now required to evaluate the association with adenocarcinoma.

Informed Consent

Written informed consent was obtained from the patient for his clinical data to be published in this article.

Endnote: This study appeared as a poster presentation during the 9th Eurasian Uro-oncology Congress, 16– 20 October, 2019, Athens, Greece.

REFERENCES

1. Xin Z, Zhao C, Huang T, Zhang Z, Chu C, Lu C, Wu M, Zhou W. Intestinal metaplasia of the bladder in 89 patients: a study with emphasis on long-term outcome. *BMC Urol* 2016;16:24.
2. Gordetsky J, Epstein JI. Intestinal metaplasia of the bladder

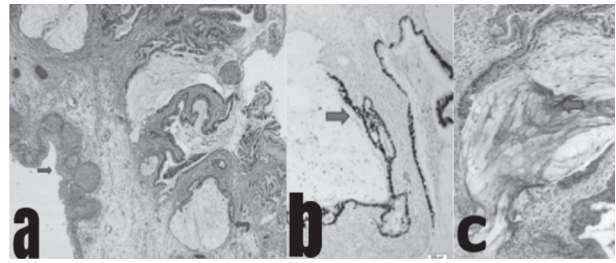


Figure 2. Intestinal metaplasia of the bladder (a) H&E, x 40. Normal bladder surface epithelium (blue arrow), cystitis glandularis (red arrow) with areas of intestinal metaplasia (b) H&E, x 100. PAS-positive cyst lumen (blue arrow) (c) H&E, x 100. Immunohistochemical CDX2 positivity of the epithelium showing intestinal metaplasia (blue arrow)

with dysplasia: a risk factor for carcinoma? *Histopathology* 2015;67:325-30.

3. McKenney JK. Precursor lesions of the urinary bladder. *Histopathology* 2019;74:68-76.
4. Figler BD, Elder JS, MacLennan GT. Intestinal metaplasia of the bladder. *J Urol* 2006;175:1119.
5. Sung MT, Lopez-Beltran A, Eble JN, MacLennan GT, Tan PH, Montironi R, et al. Divergent pathway of intestinal metaplasia and cystitis glandularis of the urinary bladder. *Mod Pathol* 2006;19:1395–401.
6. Corica FA, Husmann DA, Churchill BM, Young RH, Pacelli A, Lopez-Beltran A, et al; Intestinal metaplasia is not a strong risk factor for bladder cancer: study of 53 cases with long-term follow-up. *Urology* 1997;50:427-31.