

Original Article

Asian Pacific Journal of Tropical Medicine

journal homepage: www.apjtm.org

doi:10.4103/1995–7645.291039

Impact Factor: 1.94

Pomegranate peel extract lessens histopathologic changes and restores antioxidant homeostasis in the hippocampus of rats with aluminium chloride–induced Alzheimer’s disease

Steve Harakeh^{1,6}, Wafaa S. Ramadan^{2,3}, Mohammed S. Al Muhayawi^{4,5}, Soad Al Jaouni^{6,7}, Shaker Mousa⁶, Khalid Rehman Hakeem⁸✉

¹Special Infectious Agent Unit, King Fahd Medical Research Center, King Abdulaziz University, Kingdom of Saudi Arabia

²Department of Anatomy, Faculty of Medicine, King Abdulaziz University, Kingdom of Saudi Arabia

³Department of Anatomy, Faculty of Medicine, Ain Shams University, Cairo, Egypt

⁴Department of Medical Microbiology/Parasitology and Molecular Microbiology Laboratory, KAUH, King Abdulaziz University, Kingdom of Saudi Arabia

⁵Department of Hematology/Pediatric Oncology, King Abdulaziz University Hospital (KAUH), Faculty of Medicine, King Abdulaziz University, Kingdom of Saudi Arabia

⁶Yousef Abdul Latif Jameel Scientific Chair of Prophetic Medicine Application, Faculty of Medicine, King Abdulaziz University, Kingdom of Saudi Arabia

⁷Pharmaceutical Research Institute, Albany College of Pharmacy and Health Sciences, Rensselaer, NY, USA

⁸Department of Biological Sciences, Faculty of Sciences, King Abdulaziz University, Jeddah, Saudi Arabia

ABSTRACT

Objective: To investigate the neuroprotective efficacy of pomegranate and ellagic acid on the histopathological changes in the hippocampus of an aluminium chloride (AlCl₃) induced rat model of Alzheimer’s disease.

Methods: Sprague Dawley rats were divided into 4 groups ($n=10$ each): Group I : serving as negative control; Group II , Alzheimer model, induced by administration of 17 mg/kg bw AlCl₃; Group III, administered the same dose of AlCl₃ with 50 mg/kg of pomegranate peel extract and Group IV : administered ellagic acid (50 mg/kg) in addition to the same dose of AlCl₃. The medication given to all groups continued for 28 days. All were given the compounds by gastric gavage. Radial arm maze test, hippocampus antioxidant markers, histopathology of the dentate gyrus, and CA3 of the hippocampus were evaluated.

Results: Rats treated with pomegranate peel extract exposed to radial arm maze test showed less number of errors and reduced time needed to reach the criterion. There was an increase in the levels of glutathione, catalase, and total antioxidant capacity and decreased lipid peroxidation products. Histopathological features in dentate gyrus and CA3 as apoptosis and chromatolysis of pyramidal cells and granular layer, respectively, were decreased. Alzheimer characteristic neurofibrillary tangles and senile plaques were reduced. Treatment with ellagic acid ameliorated the pathological

results but to a statistically lower level.

Conclusions: Pomegranate peel extract alleviates memory deficit and restores antioxidant homeostasis following degenerative changes in the hippocampus induced by aluminium chloride in rats.

KEYWORDS: Pomegranate; Peel extract; Ellagic acid; Antioxidants; Hippocampus; Behavioural test

1. Introduction

Alzheimer’s disease (AD), a neurodegenerative brain disorder, is the most common cause of dementia[1,2]. Cumulative oxidative stress has been attributed to its etiology[3]. Excessive production of

✉To whom correspondence may be addressed. E-mail: khakim@kau.edu.sa; kur.hakeem@gmail.com

This is an open access journal, and articles are distributed under the terms of the Creative Commons Attribution-Non Commercial-ShareAlike 4.0 License, which allows others to remix, tweak, and build upon the work non-commercially, as long as appropriate credit is given and the new creations are licensed under the identical terms.

For reprints contact: reprints@medknow.com

©2020 Asian Pacific Journal of Tropical Medicine Produced by Wolters Kluwer-Medknow. All rights reserved.

How to cite this article: Harakeh S, Ramadan WS, Al Muhayawi MS, Al Jaouni S, Mousa S, Hakeem KR. Pomegranate peel extract lessens histopathologic changes and restores antioxidant homeostasis in the hippocampus of rats with aluminium chloride-induced Alzheimer’s disease. Asian Pac J Trop Med 2020; 13(10): 456-463.

Article history: Received 26 May 2019 Revision 25 May 2020
Accepted 2 June 2020 Available online 14 August 2020

oxidants in the human body can lead to oxidative damage to large biomolecules such as lipids, DNA, and proteins[4]. The hippocampus is extensively susceptible to oxidative stress[5]. Knowing that it plays an important role in spatial cognition, representing the elements of everyday interactions and the relations among them marked the hippocampus as a pivot in-memory processing[6].

Cognitive dysfunction has been found to be among the most sensitive impairments associated with exposure to environmental contaminants in human[7] and experimental animal models[8]. Previous studies have indicated that the presence of aluminium in drinking water and foods lead to AD in humans and animals[9,10]. Aluminium causes microtubule depletion, eventually leading to disconnection of the neuronal afferents and efferents, loss of function and regional atrophy, which is consistent with MRI findings in AD brains[10]. It is well documented that Al-based compounds are widely used in many fields like medicine[11], industries[12], water purification tool[13] and household cookware[14].

Oxidative stress is associated with many pathological conditions affecting the nervous system, many compounds have been demonstrated, based on trials, to decrease the cellular load of reactive oxygen species[15]. Currently prescribed medications for the treatment of AD break the vicious oxidative stress cycles and neurodegeneration. However, they may compromise the signal transduction pathways and prevent free radical production[16]. Meanwhile, the antioxidant products, present in fruits, vegetables and medicinal plants, have become the centre of attention as they proved their defensive role[17,18].

Pomegranate fruit (*Punica granatum* L.) displayed many therapeutic effects on using extracts of all its parts (peel, seeds, juice)[19,20]. This has been attributed to various reasons, especially due to their antioxidant properties and their total polyphenol activity[21]. The peel exhibited a high content of polyphenols[22] of which ellagitannins are the major constituents, and are further hydrolyzed into ellagic acid in the gut[23]. Ellagitannins are also known for their antioxidant effect[23]. The availability of free ellagic acid in food is unusual; it is conjugated with either a glycoside moiety or forms part of the polymeric ellagitannins[24]. The beneficial role of using the whole herb or combination of a group of herbs aims at several objectives; it will mitigate the toxicity and reduce the side effects of one, isolated compound from the plant. Many previous studies addressed the high nutritional and potential role of an extract of *Punica granatum*. Proofs are accumulating that compounds present in a fruit or herb extract augment each other's biological effect[25].

The aim of the present study was to compare the antioxidant effect of the total pomegranate peel extract with its single principle constituent, ellagic acid, on the neurodegenerative effects in the hippocampus rats and decreasing the incidence of subsequent resulting dementia.

2. Material and methods

2.1. Materials

Forty Sprague Dawley rats with an body weight of 200-250 g were purchased from Faculty of Pharmacy, King Abdulaziz University, Jeddah, Saudi Arabia. The rats were housed in wire-meshed cages at a constant temperature (22 ± 2) °C, 55% humidity and light-dark conditions (12/12 hours light/dark). Animals were provided with Purina chow diet (Purina, Ontario) and drinking water *ad libitum* and left to habituate to the laboratory environment for one week. The protocol of the current study followed the guidelines of animal care at Faculty of Pharmacy Animal House, KAU. Ethical approval No. 330-19 was granted by ethical committee at King Abdulaziz University, Jeddah, Saudi Arabia.

Aluminium chloride ($AlCl_3$) and ellagic acid (EA) were purchased from Sigma Aldrich. Standardized pomegranate extract (PE) was POMELLA™ (Verdure Sciences, Noblesville, IN, USA), which has been studied in human subjects for its safety/tolerability and bioavailability[26].

2.2. Experimental design

The rats were randomly divided into four groups ($n=10$ each). Group I (control): was the negative control and received only food and water. Group II (AD) received $AlCl_3$ administered orally at a dose of 17 mg/kg body weight (bw) daily for 28 days[27]. Both group III and IV were also given $AlCl_3$ at a dose of 17 mg/kg body weight (b.w.) daily for 28 days. Then group III (AD+PE) received PE 50 mg/kg for 28 days[27]. Group IV (AD+EA) received EA 50 mg/kg dissolved in DMSO for 28 days[28]. Treatment was given to the latter two groups by intragastric tube daily after $AlCl_3$ administration was stopped.

2.2.1. Behavioural tests: Radial arm maze (RMT)

A 12 arm radial maze was built to be similar to that used by Lai *et al*[28]. Rats were habituated to the maze 10 min daily for 4 days. This was followed by the test phase (14 days) in which the rat searched the maze for food pellets present at the end of each of the 12 arms. The rat was kept in the maze until it entered all 12 arms or 10 min had passed. The maze was cleaned entirely before each test session. An entry was considered when all four paws were inside an arm. Two main variables were recorded: the number of errors and the time to complete the maze. Errors are defined as when a rat chooses an unbaited arm (reference memory error) or when it returns to a baited arm after obtaining the food reward (working memory error). The time it took for each rat to enter the 12 baited arms was measured and considered as time to criterion[29].

2.2.2. Brain tissue sampling

At the end of the experiment, the rats were deprived of food for 12 h then sacrificed by decapitation under humane conditions. The whole brain was rapidly extracted, washed with isotonic saline, dried, and sagittally divided into two halves; the hippocampus of the left side was dissected for homogenate preparation and the right-sided cerebral hemisphere for histopathological examination.

2.2.3. Preparation of hippocampus homogenate

Hippocampus homogenization was done as previously published[30].

2.2.4. Biomarkers for antioxidant activity

Estimation of catalase activity was performed according to Chance and Maehly[31]. The activity of catalase was expressed as % activity. Evaluation of glutathione in the hippocampus was done following the method of Habiget *et al*[32]. The concentration was expressed as μmol per mg protein. The TAC in brain homogenate was determined using Cell Biolabs' OxiSelect™ TAC Assay (Catalog Number STA-360). The reaction was read with a standard 96-well spectrophotometric microplate reader at 490 nm.

2.2.5. Estimation of lipid peroxidation assay: Thiobarbituric acid reactive substance

The assay for lipid peroxidation was carried out by assessing the thiobarbituric acid reactive substance following Ohkawa *et al*[33]. Results were expressed as μM of malondialdehyde (MDA) per mg protein.

2.2.6. Histopathological examination

The second portion of each brain was fixed in phosphate buffer formalin (10%) for 24 h. The brains were processed and embedded in paraffin blocks. Sections (4 μm thick) were stained with

hematoxylin and eosin stains, Cresyl violet, and Silver stains[34]. Sections were examined and photographed using an Olympus light microscope (model: BX51TF-Japan).

2.2.7. Morphometric analysis

Both the thickness of the pyramidal cell layer in the CA3 area and the granular cell layer of the dentate gyrus (DG) were measured using Image ProPlus Software, (Media Cybernetics, Silver Spring, MD). Five non-overlapping fields in each of 10 sections for each rat were assessed and the mean for each of the ten rats was calculated.

2.2.8. Statistical analysis

Statistical analyses were performed using SPSS program version 20 (IBM-USA). The one-way analysis of variance (ANOVA) test was used and when equal variance could be assumed, the LSD *t*-test was applied. Data are presented as mean \pm standard deviation (mean \pm SD). $P<0.05$ was considered statistically significant.

3. Results

3.1. Behavioral test

In the RMT, the number of errors in 14 days' time significantly decreased in the groups treated with PE and EA in comparison to the AD group. Rats treated with PE made fewer errors than those treated with EA (Figure 1A). Through out the phase test (14 days), it was documented on daily bases that the time spent by control rats to reach criterion was significantly shorter than those of the AD group ($P<0.05$). Rats treated with PE and EA significantly decreased the time to reach criterion ($P<0.05$) in comparison to the AD group (Figure 1B).

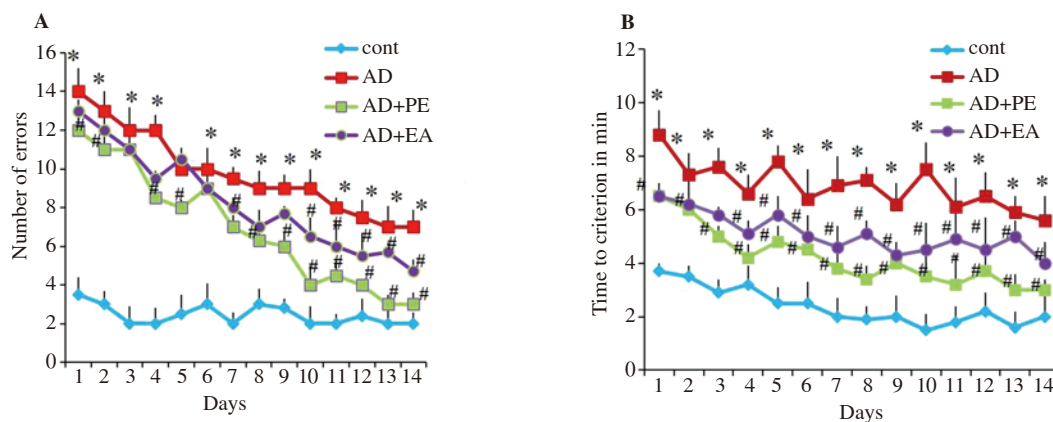


Figure 1. Line graph showing (A) the mean number of errors made by rats in each of the four groups for each daily test trial and the mean time to criterion (12 arms); (B) $n=10$ rats/group. Data were expressed as mean \pm SD. Cont: control, AD: Alzheimer model, AD+PE: treated with pomegranate peel extract, AD+EA: treated with ellagic acid. * $P<0.05$ indicates a significant difference from the control. # $P<0.05$ indicates a significant difference from AD group.

Table 1. Catalase, glutathione activity, total antioxidant capacity (TAC) and lipid peroxidation products (MDA) in all groups .

Parameters	Control	AD	AD+PE	AD+EA
Catalase (ng/mL)	433.70±4.50	110.41±4.80 [*]	415.16±7.78 [#]	395.24±4.90 [#]
Glutathione (μM)	52.63±3.20	23.12±3.30 [*]	76.75±4.43 [#]	49.80±2.30 [#]
TAC (CRE)	830.17±4.01	327.75±4.91 [*]	1172.42±5.21 [#]	896.04±4.31 [#]
MDA (μM)	24.67±1.60	41.50±3.20 [*]	29.70±1.60 [#]	35.10±2.20 [#]

AD: administered AlCl₃; AD+PE: administered AlCl₃+pomegranate extract; AD+EA: administered AlCl₃+ellagic acid. **P*<0.05 significant difference comparing with the control group; [#]*P*<0.05 significant difference comparing with AD group.

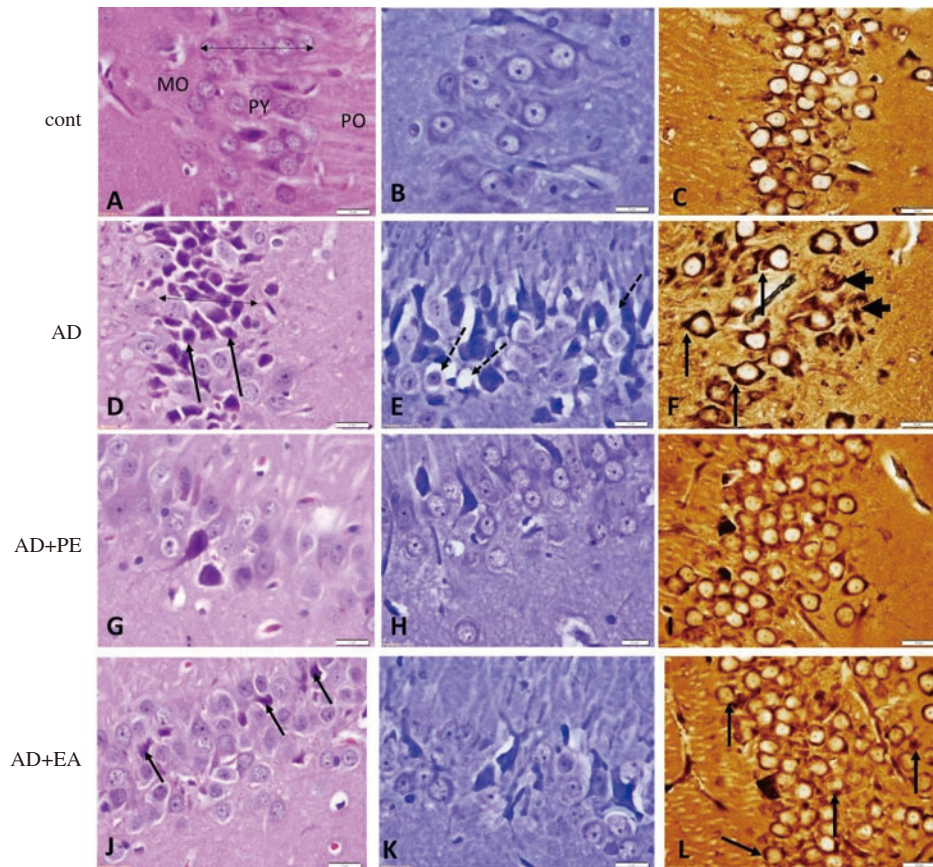


Figure 2. Photomicrographs of sections of hippocampal CA3 region showing normal poly-morphic (PO), pyramidal (PY) and molecular cell layers (MO) in the control group (A) and well defined distribution of nissl granules in (PY) cells (B). Silver stain showing normal pyramidal cells (C). In AD, apparent decreased thickness of the (PY) layer, pyramidal cells are shrunk with pyknotic nuclei (arrows), with vacuolated cytoplasm and areas devoid of cells are also revealed (D). Marked chromatinolysis of PY cells (E), NFT (thin arrows) and (SP) (thick arrows) are prominent (F). In rats treated with PE, most of pyramidal cells of CA3 show normal structure (G), restored nissl granules (H) and less NFT and SP are noted (I). In groups treated with AD+EA, frequent apoptotic cells (arrows) are noted (J), chromatinolysis of pyramidal cells (K) and persistent NFT and SP are still noted (L). AD: Alzheimer, NFT: neurofibrillar tangles, SP, senile plaques, PE: pomegranate peel extract, EA: ellagic acid, (A, D, G, Jx H&E×400), (B, E, H, Kx Cresyl violet ×400), (C, F, I, Lx Silver×400).

3.2. Biomarkers for the antioxidant activity

In comparison with the control group, the concentration of catalase and glutathione in the hippocampus homogenate significantly decreased in the AD rat model to (110.41±4.80) ng/mL and (23.12±3.30) μM, respectively. On the other hand, treatment with PE enhanced the antioxidant activity and resulted in the higher catalase and glutathione levels in comparison to those rats on EA. Moreover, the TAC yielded by PE was significantly higher than those administered EA (Table 1).

3.3. Estimation of lipid peroxidation assay: Thiobarbituric acid reactive substance (TBARS)

In comparison to AD group, the supplementation of EA decreased MDA by 15.4% while PE administration reduced it by 28.4%. PE therapy significantly decreased the level of MDA from (41.50±3.20) μM in the AD group to (29.7±1.60) μM (Table 1).

3.4. Histopathological results

Examination of the CA3 region of the hippocampus of the control group using H&E stain revealed poly-morphic, pyramidal and

molecular cell layers. The pyramidal cells, with large vesicular nuclei and basophilic cytoplasm, were packed in 4-5 layers (Figure 2A). Cresyl violet staining showed the well-defined distribution of Nissl's granules corresponding to rough endoplasmic aggregates, giving characteristic blue hallow surrounding the nucleus (Figure 2B). Silver staining of the control sections showed round polyhedral pyramidal cells (Figure 2C).

In the AD group, some of the pyramidal cells appeared shrunk with pyknotic nuclei, others had vacuolated cytoplasm. Microvacuolation of the neuropil with areas devoid of cells were also revealed (Figure 2D). Cresyl violet stain showed marked chromatolysis, which explains the vacuolated appearance of pyramidal cells in H&E stain (Figure 2E).

The pathological hallmarks of AD were revealed in silver stain; (Neurofibrillary tangles) NFT and senile plaques (SP) (Figure 2F). Rats treated with PE decreased the degenerative changes; NFT and SP. The Nissl's granules and the mean thickness of the pyramidal layer were restored (Figure 2G-I). Frequent NFT, SP, and other degenerative changes persisted in sections of rats treated with EA. (Figure 2J-L). Decreased mean thickness of the pyramidal layer (Figure 3) reflected the degenerative changes in this layer.

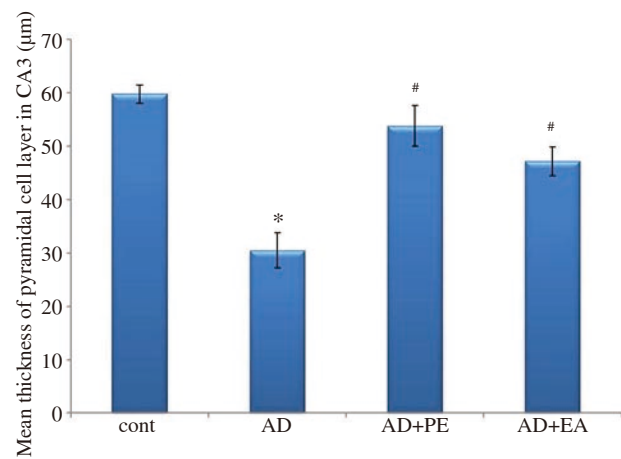


Figure 3. The mean thickness of the pyramidal layer in groups treated with AD+PE in comparison to AD and groups treated with AD+EA. The one-way analysis of variance (ANOVA) test was used. The Fisher's least significant difference (LSD) *t*-test was applied when equal variance could be assumed. Data are presented as means±SD. *significantly different from the control, AD+PE, AD+EA at $P \leq 0.05$. #significantly different from AD group at $P \leq 0.05$.

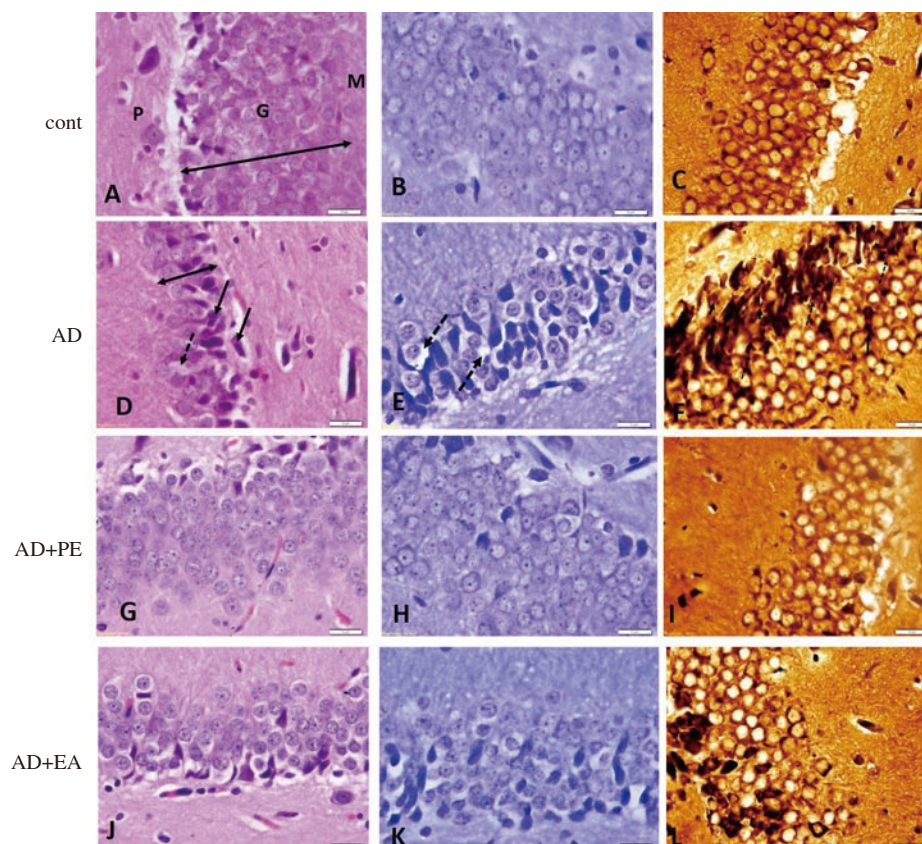


Figure 4. Photomicrographs of sections of hippocampal DG region showing normal molecular (M), granular cell (G) and pleomorphic layers (P) in the control group (A) and prominent nissl granules in (B), and large polyhydal cells (C). In AD model, reduced thickness of granular cell layer, marked vacuolation of disorganized cells (dashed arrows), and multiple shrunken cells with pyknotic nuclei (arrows) are noted (D). Chromatolysis of (G) cells (dashed arrows) (E) and multiple SP (arrows) and NFT (dashed arrows) are dispersed (F). Signs of degenerative changes decreased with PE administration (G-I) more than with EA treatment (J, K, L). DG: dentate gyrus; AD: Alzheimer; NFT: neurofibrillar tangles; SP: senile plaques; PE: pomegranate peel extract; EA: ellagic acid (A, D, G, Ix H&E $\times 400$), (B, E, H, Kx cresyl violet $\times 400$), (C, F, I, Lx Silver $\times 400$).

The DG consisted of the molecular, granular cell, and pleomorphic layers. The granular cell layer of the control group contained polyhedral cells with vesicular nuclei, with well-dispersed Nissl's granules manifested in cresyl violet stain and large polyhedral cells by silver stain (Figure 4A, B & C). In the AD model, reduced thickness of granular cell layer, marked vacuolation of disorganized granular cells, with multiple shrunk cells and pyknotic nuclei were all revealed in H&E stain (Figure 4D). Marked chromatolysis with a peripheral displacement of the nucleus (Figure 4E) and multiple SP and NFT were dispersed in the granular layer (Figure 4F) manifested in cresyl stain and silver stain, respectively. These degenerative changes were ameliorated on treatment with PE (Figures 4G, H & I) but persisted on treatment with EA (Figure 4J, K & L). A significant decrease in the mean thickness of the granular layer corresponded with degenerative changes [(55.0±3.40) μm] in comparison to the control [(79.0±1.50) μm] (Figure 5).

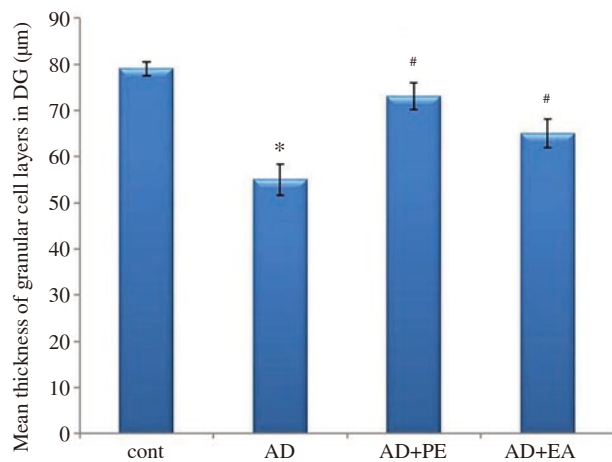


Figure 5. The mean thickness of the granular layer on treatment with PE. The one-way analysis of variance (ANOVA) test was used. The Fisher's least significant difference (LSD) *t*-test was applied when equal variance could be assumed. Data are presented as means±SD. *significantly different from the control, AD+PE, AD+EA at $P \leq 0.05$. #significantly different from AD group at $P \leq 0.05$.

4. Discussion

Several studies agree that body cells exposed to oxidative stress at the physiological state and subjected to factors like stress, ageing, and environmental degenerative contaminants reinforce the damage caused by oxidative stress[35]. This work aims to compare the antioxidant effect of whole peel PE with its single active component, EA, in relation to neurodegenerative histopathological changes in the hippocampus of rat brains in an AD model. The hippocampus plays an exclusive role in learning and memory and is subjected to early affection in AD. The hippocampus is formed of DG and the hippocampus proper, which is further composed of CA1, CA2, and

CA3 fields and the subiculum[28].

Neurodegenerative changes in hippocampus exposed to $AlCl_3$ revealed reduced thickness of granular cells in DG and pyramidal cell in CA3 in addition to vacuolation of cells and pyknosis of their nuclei. Chromatolysis and loss of Nissl's granules were evident in cresyl violet stained sections. Similar results were described by Damjanov[36] as signs of neuronal injury. The darkly stained fibrillary tangles NFT involving the neurons and focal interneuronal spherical neuritic plaques SP were also described as pathological hallmarks of AD[37]. The aggregation and formation of NFT resulted from hyperphosphorylation of Tau protein, which dis-stabilises neuron microtubules as analyzed by Rodríguez-Martín *et al*[38] and resulted in neurodegeneration and loss of function[42]. It is confirmed that oxidative damage in the brain precipitated neurofibrillary tangle NFT[43]. The SP resulted in the abnormal deposition of the amyloid- β peptide ($A\beta$) with 40 or 42 amino acids ($A\beta_{40}$ and $A\beta_{42}$) outside the cells, which are the metabolism by-products of the amyloid precursor protein (APP).

There is evidence suggesting an interconnection between oxidative stress and tau pathology. It has been reported that neurons with excessive tau protein showed increased susceptibility to oxidative stress, and the consumption of peroxisomes was the reason[39]. Moreover, accumulation of extracellular amyloid plaques led to increased oxidative stress, induced mitochondrial dysfunction[40] and increased the levels of the byproducts of lipid peroxidation[46].

In the present study oxidative stress was proved to be a factor in AD neurodegenerative changes as manifested by decreased catalase, glutathione, TAC, and increased lipid peroxidation products (MDA). This was reflected in rats undergoing the RMT. AD rat model revealed impairment of spatial memory as the number of errors increased while time to reach criterion decreased. This is supported by results from a study by Mohsen *et al*[41].

Previous research generally confirmed that RMT could be used to test for the reference and working memory performance simultaneously[42]. It has been proven that the DG integrates both the visual object and spatial information to create a memory of a 'total' spatial representation[43], while the CA3 region plays a role in pattern completion or the retrieval of memory when only partial input cues are presented[44].

In the present study, the PE mitigated the neurodegenerative pathological changes in the hippocampus more than EA. This was manifested by regaining thickness of the granular layer in DG and pyramidal layer in CA3, the decrease in NFT and SP formation, and restoration of Nissl's granules. This can be attributed to its antioxidant effect revealed in elevation of the lowered levels of catalase, glutathione and lowering of the high levels of lipid peroxidation products.

PE relieved histopathological changes in the AD model better than

EA. These results were supported by the stronger antioxidant effect manifested by a statistically significant TAC in PE more than in EA treated group. It is documented that pomegranate peel ethanolic extract exhibited proton-donating ability, demonstrated the highest free radical scavenging activity, and had the highest inhibitory activity on lipid peroxidation[45].

The peel comprises about 50% of the total fruit weight and is considered an indispensable source of bioactive compounds such as phenolics, flavonoids, ellagitannins, and proanthocyanidin compounds, minerals, and complex polysaccharides[46].

In conclusion, it was found that therapeutic potential of pomegranate peel extract on the neurodegenerative changes induced in the hippocampus of rats and the subsequent resulting dementia was better than the effect of a single principle constituent, ellagic acid.

Conflict of interest statement

The authors declare no conflict of interest among them.

Acknowledgements

This project was funded by Deanship of Scientific Research (DSR), King Abdulaziz University, Jeddah, under grant No. DF-658-248-1441). The authors, therefore, gratefully acknowledge DSR technical and financial support.

Authors' contributions

S.T. supervised the project, W.R. designed the study and carried out the experiment. M.M. contributed in writing the manuscript and literature search, S.J. and S.M. analyzed and interpreted the collected data. S.T. and K.R. supported the study through critical comments and reviewing of the manuscript.

References

- [1] Wimo A, Jonsson L, Winblad B. An estimate of the worldwide prevalence and direct costs of dementia in 2003. *Dement Geriatr Cogn Dis* 2006; **21**(3): 175–181.
- [2] Blennow K, de Leon MJ, Zetterberg H. Alzheimer's disease. *Lancet* 2006; **368**(9533): 387–403.
- [3] Song P, Zou MH. Roles of reactive oxygen species in physiology and pathology. In: Wang H, Patterson C, editors. *Atherosclerosis: Risks, mechanisms, and therapies*. Hoboken, NJ: John Wiley & Sons Inc.; 2015, p. 379–392.
- [4] Poulouse SM, Miller MG, Shukitt-Hale, B. Role of walnuts in maintaining brain health with age. *J Nutr* 2014; **144**(Suppl 4): S561–S566.
- [5] Gottlieb M, Leal-Campanario R, Campos-Esparza MR, Sanchez-Gomez MV, Alberdi E, Arranz A, et al. Neuroprotection by two polyphenols following excitotoxicity and experimental ischemia. *Neurobiol Dis* 2006; **23**(2): 374–386.
- [6] Deacon RM, Rawlins JNP. Hippocampal lesions, species-typical behaviours and anxiety in mice. *Behav Brain Res* 2005; **156**(2): 241–249.
- [7] Eskenazi B, Marks AR, Bradman A, Harley K, Barr DB, Johnson C, et al. Organophosphate pesticide exposure and neurodevelopment in young Mexican-American children. *Environ Health Perspect* 2007; **115**(5): 792–798.
- [8] Levin ED, Addy N, Baruah A, Elias A, Christopher NC, Seidler FJ, et al. Prenatal chlorpyrifos exposure in rats causes persistent behavioral alterations. *Neurotoxicol Teratol* 2002; **24**(6): 733–741.
- [9] Exley C. The aluminium-amyloid cascade hypothesis and Alzheimer's disease. *Alzheimer's disease*. Boston: Springer; 2005, p. 225–234.
- [10] Walton JR. Chronic aluminum intake causes Alzheimer's disease: Applying Sir Austin Bradford Hill's causality criteria. *J Alzheimer's Dis* 2014; **40**: 765–838.
- [11] Lione A. Aluminum toxicology and the aluminum-containing medications. *Pharmacol Therap* 1985; **29**(2): 255–285.
- [12] Abbasali K, Zhila T, Farshad N. Developmental toxicity of aluminum from high doses of AlCl₃ in mice. *J Appl Res* 2005; **5**(4): 575–579.
- [13] Newairy ASA, Salama AF, Hussien HM, Yousef MI. Propolis alleviates aluminium induced lipid peroxidation and biochemical parameters in male rats. *Food Chem Toxicol* 2009; **47**(6): 1093–1098.
- [14] Bilkei-Gorzo A. Neurotoxic effect of enteral aluminium. *Food Chem Toxicol* 1993; **31**(5): 357–361.
- [15] Slemmer JE, Shacka JJ, Sweeney MI, Weber JT. Antioxidants and free radical scavengers for the treatment of stroke, traumatic brain injury and aging. *Curr Med Chem* 2008; **15**(4): 404–414.
- [16] Gella A, Durany N. Oxidative stress in Alzheimer disease. *Cell Adh Migr* 2009; **3**(1): 88–93.
- [17] Fu L, Xu BT, Xu XR, Gan RY, Zhang Y, Xia EQ, et al. Antioxidant capacities and total phenolic contents of 62 fruits. *Food Chem* 2011; **129**(2): 345–350.
- [18] Deng GF, Xu XR, Guo YJ, Xia EQ, Li S, Wu S, et al. Determination of antioxidant property and their lipophilic and hydrophilic phenolic contents in cereal grains. *J Funct Food* 2012; **4**(4): 906–914.
- [19] Newman RA, Lansky EP, Block ML. *Pomegranate: The most medicinal fruit*. Laguna Beach, California: Basic Health Publications; 2007, p. 120.
- [20] Jurenka J. Therapeutic applications of pomegranate (*Punica granatum* L.): A review. *Alter Med Rev* 2008; **13**(2): 128–144.
- [21] Tzulkler R, Glazer I, Bar-Ilan I, Holland D, Aviram M, Amir R. Antioxidant activity, polyphenol content, and related compounds in

- different fruit juices and homogenates prepared from 29 different pomegranate accessions. *J Agric Food Chem* 2007; **55**(23): 9559-9570.
- [22]Faria A, Calhau C. The bioactivity of pomegranate: Impact on health and disease. *Critical Rev Food Sci Nut* 2011; **51**(7): 626–634.
- [23]Gil MI, Tomas-Barberan FA, Hess-Pierce B, Holcroft DM, Kader AA. Antioxidant activity of pomegranate juice and its relationship with phenolic composition and processing. *J Agric Food Chem* 2000; **48**(10): 4581–4589.
- [24]Larrosa M, Tomás-Barberán FA, Espín JC. The dietary hydrolysable tannin punicalagin releases ellagic acid that induces apoptosis in human colon adenocarcinoma Caco-2 cells by using the mitochondrial pathway. *J Nutr Biochem* 2006; **17**: 611–625.
- [25]Jain S, Rai R, Upadhyaya AR, Malhotra G. *Punica granatum*: A natural and recent approach towards dental problem. *Intern J Pharma Sci Res* 2014; **2**(1): 1–6.
- [26]Mertens-Talcott SU, Jilma-Stohlawetz P, Rios J, Hingorani L, Derendorf HJ. Absorption, metabolism, and antioxidant effects of pomegranate (*Punica granatum* L.) polyphenols after ingestion of a standardized extract in healthy human volunteers. *Agric Food Chem* 2006; **54**: 8956–8961.
- [27]Toklu HZ, Dumlu MU, Sehirlı O, Ercan F, Gedik N, Gokmen V, et al. Pomegranate peel extract prevents liver fibrosis in biliary obstructed rats. *J Pharm Pharmacol* 2007; **59**(9): 1287-1295.
- [28]Li Y, Mu Y, Gage FH. Development of neural circuits in the adult hippocampus. *Curr Top Dev Biol* 2009; **87**: 149-174.
- [29]Genovese RF, Benton BJ, Shippee SJ, Jakubowski EM, Bonnell JC. Effects of low level inhalation exposure to cyclosarin on learned behavior in Sprague Dawley rats. *J Toxicol Environ Health* 2006; **69**(24): 2167-2180.
- [30]Kumar P, Kumar A. Neuroprotective effect of cyclosporine and FK506 against 3-nitropropionic acid induced cognitive dysfunction and glutathione redox in rat: Possible role of nitric oxide. *Neurosci Res* 2009; **63**(4): 302–314.
- [31]Chance B, Maehly AC. Assay of catalase and peroxidases. *Met Enzymol* 1955; **11**: 764–775.
- [32]Habig WH, Pabst MJ, Jakoby WB. Glutathione-S-transferases: The first enzymatic step in mercapturic acid formation. *J Biol Chem* 1974; **249**(22): 7130–7139.
- [33]Ohkawa H, Ohishi N, Yagi K. Assay for lipid peroxides in animal tissues by thiobarbituric acid reaction. *Anal Biochem* 1979; **95**(2): 351-358.
- [34]Bancroft JD, Stevens A. The haematoxylin and eosin. In: *Theory and practice of histological techniques*. 4th ed. London, New York & Tokyo: Churchill Livingstone; 1996, p. 99–112.
- [35]Halliwell B, Gutteridge JMC. Cellular responses to oxidative stress: Adaptation, damage, repair, senescence and death. In: *Free radicals in biology and medicine*. 4th ed. Oxford UK: Clarendon Press; 2007, p. 187–267.
- [36]Damjanov I. Central nervous system. In, Paul St. Romain, Damjanov, editors. In: *Atlas of histopathology*. 1st edition. New Delhi: Jaypee Brothers Medical Publishers(P) Ltd.; 2012, p. 367-372.
- [37]Serrano-Pozo A, Frosch MP, Masliah E, Hyman BT. Neuropathological alterations in Alzheimer disease. *Cold Spring Harb Perspect Med* 2011; **1**(1): a006189.
- [38]Rodríguez-Martín T, Cuchillo-Ibáñez I, Noble W, Nyenya F, Anderton BH, Hanger DP. Tau phosphorylation affects its axonal transport and degradation. *Neurobiology of Aging* 2013; **34**(9): 2146–2157.
- [39]Stamer K, Vogel R, Thies E, Mandelkow E, Mandelkow EM. Tau blocks traffic of organelles, neurofilaments, and APP vesicles in neurons and enhances oxidative stress. *J Cell Biol* 2002; **156**(6): 1051–1063.
- [40]Gandhi S, Abramov AY. Mechanism of oxidative stress in neurodegeneration. *Oxid Med Cell Longev* 2012; **42**: 8010.
- [41]Mohsen MMAE, Irvani MM, SPEcer JPE, Rose S, Fahim AT, Motawi TMK, et al. Age associated changes in protein oxidation and proteasome activities in rat brain: Modulation by anti-oxidants. *Biochem Biophys Res Commun* 2005; **336**(2): 386-391.
- [42]Rajagopal L, Massey BW, Huang M, Oyamada Y, Meltzer HY. The novel object recognition test in rodents in relation to cognitive impairment in schizophrenia. *Curr Pharm Des* 2014; **20**(31): 5104-5114.
- [43]Kesner RP, Rolls ET. A computational theory of hippocampal function, and tests of the theory: New developments. *Neurosci Biobehav Rev* 2015; **48**: 92–147.
- [44]Rolls ET. The mechanisms for pattern completion and pattern separation in the hippocampus. *Front Syst Neurosci* 2013; **7**: 74.
- [45]Manasathien J, Indrapichate K, Intarapichet K. Antioxidant activity and bioefficacy of Pomegranate *Punica granatum* Linn. peel and seed extracts. *Global J Pharmacol* 2012; **6**(2): 131-141.
- [46]Viuda-Martos M, Fernández-López J, Pérez-álvarez JA. Pomegranate and its many functional components as related to human health: A review. *Compr Rev Food Sci Food Saf* 2010; **9**(60): 635–654.