



doi: 10.4103/2221-6189.281312

jadweb.org

## Effect of Jintiange capsule on acute bone atrophy resulting from wrist fractures: A randomized controlled trial

Li-You Wei<sup>1</sup>, Hong-Wei Zhang<sup>1✉</sup>, Jin-Zeng Zuo<sup>1</sup>, Su-Miao Xu<sup>2</sup>, Liang Li<sup>1</sup>, Cheng Jiao<sup>1</sup>, Xiu-Yun Dou<sup>3</sup>

<sup>1</sup>Department of Orthopedics, the Second Hospital of Tangshan (Orthopaedic Hospital Affiliated to North China University of Science and Technology), Tangshan 063000, China

<sup>2</sup>Tangjiashuang Hospital of Kailuan (Group) Limited Liability Corporation, Tangshan, 063100, China

<sup>3</sup>Tangshan gongren hospital, Tangshan, 063000, China

### ABSTRACT

**Objective:** To investigate the efficacy of Jintiange capsule in the treatment of acute bone atrophy due to wrist fractures.

**Methods:** Participants were randomly allocated into two groups, *i.e.* the treatment group and the control groups. All patients received functional rehabilitation exercise. Patients in the treatment group received Jintiange capsule orally, while the control group received placebos. At 3 and 6 months after the treatment, Cooney score, hand grip and pinch strength were measured. The visual analogue scale (VAS) was applied, and safety events were recorded.

**Results:** No loss occurred during 6 months of follow-up after treatment. Before the treatment, there was no statistically significant difference between the two groups in Cooney score, hand grip strength, hand pinch strength or VAS score (all  $P > 0.05$ ). At 3 and 6 months after the treatment, the Cooney score, hand grip and pinch strength increased, and the VAS were decreased in all patients. The treatment group showed significantly greater improvement than the control group ( $P < 0.05$ ). In addition, both groups showed few side effects.

**Conclusions:** Jintiange capsule can improve the function of the wrist joint and alleviate the pain of fracture. It is safe and effective for treating acute bone atrophy.

**KEYWORDS:** Jintiange capsule; Acute bone atrophy; Biomimetic medicine

### 1. Introduction

Acute bone atrophy is a severe complication of wrist fracture, which has an incidence from 0.9% to 37%[1-3]. Osteoporosis of acute bone atrophy localized in wrist and fingers is accompanied by

severe pain, joint stiffness, swelling and/or poor skin elasticity[4,5]. Distal radius fracture is a kind of common wrist fracture, accounting for approximately 1/6 of all emergency fractures[6] and usually treated by surgical and conservative therapies. More patients prefer conservative treatment. Whether conservative or surgical treatment of wrist fractures, patients will not move wrist normally for a period of time, and traumatic bone atrophy often occurs. Delayed treatment will result in chronic wrist pain even lifelong wrist joint dysfunction and affect the patient's quality of life.

Acute bone atrophy is a kind of local osteoporosis but is often mistaken as a common symptom of fracture, which leads to delayed diagnosis and treatment. There is little information regarding the treatment and no specific medicine currently. For now, rehabilitation training and analgesic therapy are the main treatments.

Jintiange capsule is a biomimetic medicine and its components are derived from "non-protected" animal bones with the same pharmacological attributes of tiger bone powder, so it is referred to as artificial tiger bone powder. Recent studies indicated that the active ingredients of the Jintiange capsule can improve the metabolism to absorb calcium and phosphorus. It is also effective in treating osteoporosis and promoting fracture healing[7]. In this study, we studied the effect of Jintiange capsule on traumatic bone atrophy.

✉To whom correspondence may be addressed. E-mail: zhanghw200087@163.com

This is an open access journal, and articles are distributed under the terms of the Creative Commons Attribution-NonCommercial-ShareAlike 4.0 License, which allows others to remix, tweak, and build upon the work non-commercially, as long as appropriate credit is given and the new creations are licensed under the identical terms.

**For reprints contact:** reprints@medknow.com

©2020 Journal of Acute Disease Produced by Wolters Kluwer- Medknow. All rights reserved.

**How to cite this article:** Wei LY, Zhang HW, Zuo JZ, Xu SM, Li L, Jiao C, et al. Effect of Jintiange capsule on acute bone atrophy resulting from wrist fractures: A randomized controlled trial. J Acute Dis 2020; 9(2): 51-55.

Article history: Received 12 September 2019; Revision 9 February 2020; Accepted 22 February 2020; Available online 28 March 2020

## 2. Materials and methods

### 2.1. Participants and ethics approval

A total of 64 patients in Tangshan Second Hospital between January 2015 and December 2017 were selected. This study was approved by the Research Ethics Committee of the Second Hospital of Tangshan. Before the study, every participant signed a consent form with an agreement to the treatment.

### 2.2. Inclusion and exclusion criteria

Inclusion criteria: (1)  $\geq 18$  years old; (2) In line with the diagnosis of traumatic acute bone atrophy[8,9]; (3) Non-operative patients with unilaterally closed fracture; (4) No history of injury in the side of the wrist joint.

Exclusion criteria: (1) Diagnosed as pathological fracture due to osteoporosis, osteomyelitis, bone tuberculosis, and bone tumor; (2) Diagnosed as bilateral fractures or open fracture; (3) Severe liver, kidney and other organ dysfunction or relative combination; (4) Neurological disorders.

### 2.3. Trial design

This study is a randomized, controlled, double-blind, and double-dummy trial. The patients, researchers, and data managers were all blinded throughout this study. The patients were randomly divided into two groups with a distribution ratio of 1:1, and the required sample size was calculated as 30 participants per group. Finally, 32 participants were selected for each group in case that some patients might discontinue the study (Figure 1).

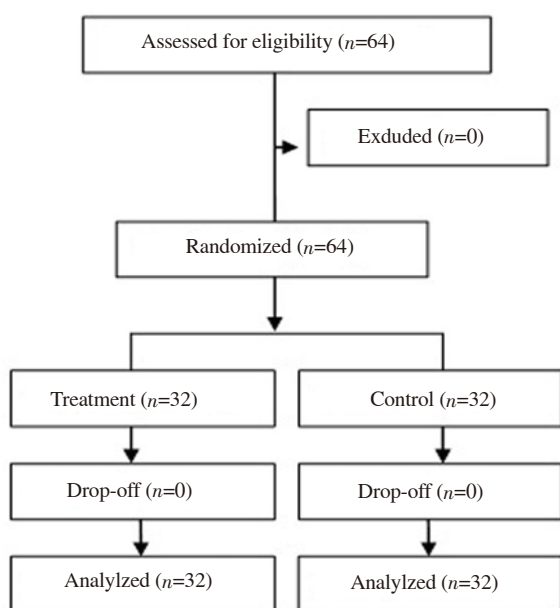


Figure 1. The study flowchart.

All participants had rehabilitation exercise, including flexor and extensor of wrists, elbows and shoulders, as well as some operation exercises and physical therapies of the wrist joint. No other medicine was used during the follow-up treatment. Patients in the treatment group orally took 1.2 g Jintiange capsules (Jinhua Enterprise Limited by Share Ltd Xi'an Jinhua Pharmaceutical Factory, China) 3 times daily following meals, with 3 months as a course. Patients in the control group were given the placebo (starch capsule) in the same way as the treatment group. The placebo capsule was the same as the Jintiange capsule in color, shape, and size.

Before the treatment, 3 and 6 months after the treatment, the Cooney score, grip, and pinch strength of hand (pinch and grip strength expressed as a percentage: the diseased side/the healthy hand) were measured. The visual analogue scale (VAS) and side effects were also recorded.

The Cooney score was one of the standards for assessing wrist function[10], with 25 points for pain, 25 points for function, 25 points for a range of extension and flexion, 25 illness points for control force, and the score ranged from 0 to 100 points. A higher Cooney score means better wrist function.

The VAS is a continuous horizontal line to measure the severity of pain. Participants were instructed to rate their pain severity from 0 "no pain" to 10 "extremely strong pain"[11].

The side effects of the medicine were recorded and the changes in liver function, renal function, electrolyte counts, urine content, and other measures in both groups were recorded.

### 2.4. Statistical analysis

SPSS 17.0 (SPSS Inc., USA) was used. Measurement data were expressed in terms of mean and standard deviation (mean $\pm$ SD) and categorical data were expressed as percentages. A two-independent-sample *t*-test was used to compare normally distributed data, while the Wilcoxon rank-sum test was applied for non-normally distributed data. The *Chi*-square test was performed to analyze categorical data. The significance level of the test was expressed at  $\alpha=0.05$ .

## 3. Results

Gender, age, location, classifications of fracture, and reduction of fracture were similar between the two groups (Table 1) ( $P>0.05$ ). No adverse reactions occurred in the two groups, and there was no significant difference in the safety measures between the two groups ( $P>0.05$ ).

There were no significant difference between the two groups in terms of the Cooney score, strength of hand, and VAS before treatment ( $P>0.05$ ). The Cooney score and the strength of hand were increased while the VAS was decreased in both groups. The improvements in the treatment group were better than those of the control group ( $P<0.05$ ) (Table 2).

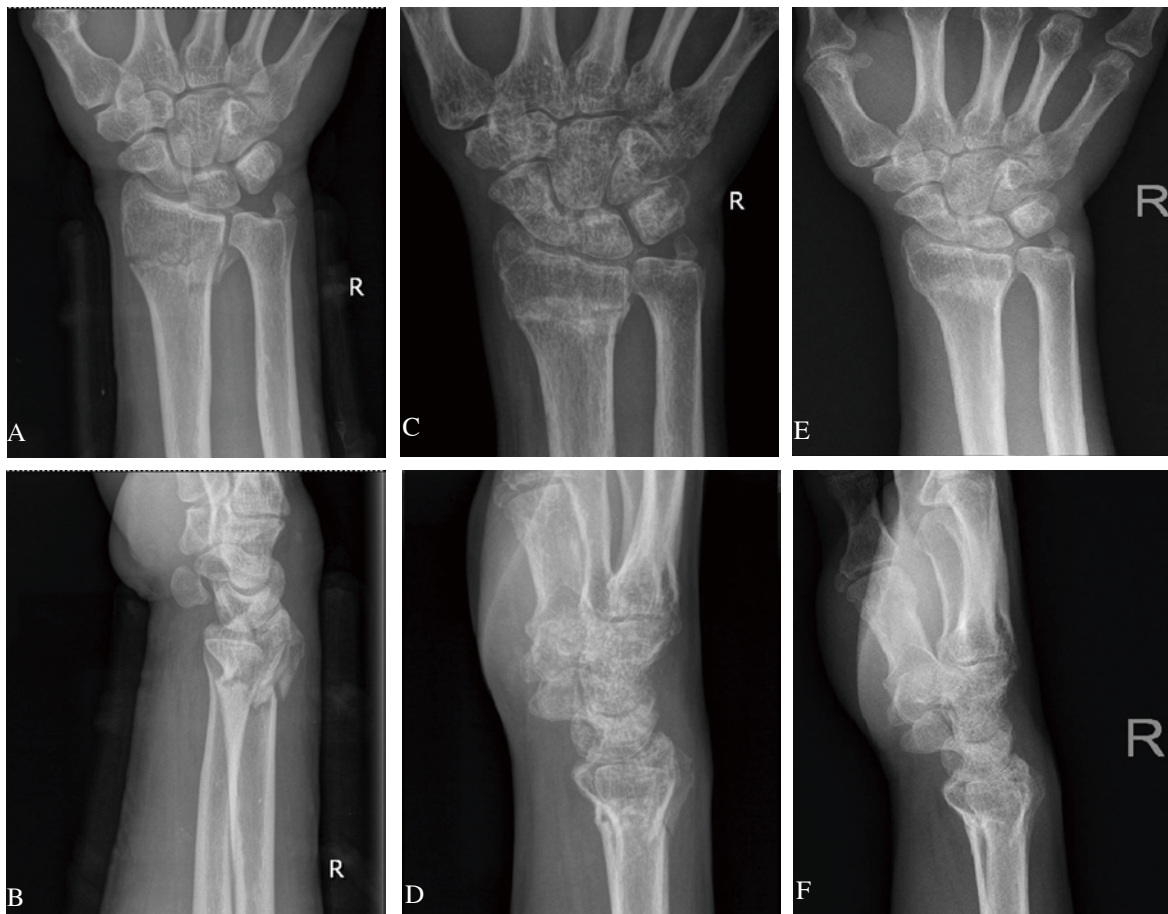
In the treatment group, a 59-year-old male patient was diagnosed as acute bone atrophy after the right distal radius fracture. The patient was treated with Jintiange capsules orally. The imaging changes of the patient were shown in Figure 2.

**Table 1.** Baseline information.

Items	Treatment (n=32)	Control (n=32)	$\chi^2/t/Z$ -value	P-value
Gender (%) (male/female)	52.3% (11/21)	88.2% (15/17)	1.036	0.309
Age (years)	60.41±11.35	61.13±10.09	0.268	0.789
Location (right/left)	13/19	18/14	1.564	0.211
AO classification (A/B/C)	6/12/14	9/13/10	1.134	0.257
Reduction of fracture				
Anteversion angle (°)	8.60±2.26	7.45±2.84	1.792	0.078
Ulnar inclination (°)	19.30±4.15	20.11±4.93	0.711	0.480
Radial length (mm)	9.41±2.52	9.25±2.61	0.249	0.803

**Table 2.** Comparison of efficacy in two groups (mean±SD).

Indicators	Treatment (n=32)	Control (n=32)	t-value	P-value
Cooney score (point)				
Before treatment	64.29±9.61	63.80±10.43	0.195	0.845
3 months	79.63±7.10	75.01±8.12	2.423	0.018
6 months	91.08±6.06	86.29±6.73	2.992	0.003
Grip strength (%)				
Before treatment	70.11±8.22	71.02±9.03	0.422	0.673
3 months	79.93±7.01	74.90±7.22	2.828	0.006
6 months	86.19±6.38	81.07±7.12	3.030	0.003
Pinch strength (%)				
Before treatment	82.13±7.05	81.06±7.17	0.602	0.549
3 months	89.02±6.53	84.37±7.06	2.735	0.008
6 months	92.15±6.01	87.70±6.32	2.886	0.005
Visual analogue scale (point)				
Before treatment	5.63±1.61	5.71±1.74	0.191	0.848
3 months	2.24±1.13	3.09±1.20	2.917	0.004
6 months	1.11±0.54	1.63±0.82	2.996	0.004

**Figure 2.** Imaging changes in the treatment group before and after the treatment. The X-ray images A, B showed distal radius fracture in the right wrist. The X-ray images C, D showed bone atrophy at the beginning of the treatment. The X-ray images E, F showed the wrist bone mass increases 6 months after the treatment.

## 4. Discussion

Acute bone atrophy is known as Sudeck's atrophy, reflex sympathetic dystrophy syndrome or complex regional pain syndrome, and it is a local osteoporosis caused by trauma. The lesions often involve wrists and fingers, and the typical symptoms include pain, vasomotor disorders, swelling of wrists and fingers, poor skin elasticity, and stiffness of joints[12-15], at the same time the X-rays usually show osteoporosis in distal radius, metacarpus, or phalanges. Analyzing probable reason is that a certain period of break following distal radius fractures can lead to bone loss. Both internal and external fixation will lead to poor venous return and sympathetic nerve disorder, and then results in dilatation of blood vessels in skin, muscles, and periosteum. Subsequently, the exudation of water and plasma protein increases, and then local blood stasis leads to pain and swelling in wrist. The increase of acidity in wrist accelerates the dissolution of collagen and hydroxyapatite in bone, activates osteoclasts, causes local osteoporosis[16,17], and ultimately postpones the recovery of wrist joint function. Therefore, effective drugs are important in the treatment of acute bone atrophy following distal radius fracture.

Tiger bone has a long history as a precious natural product in China, but it has been banned as a medicinal material more than 25 years. Jintiange capsule is made from other animals whose bones have the same effect as tiger bones in pharmacology and composition[18-20]. Modern pharmacology has proved that some animals' bones are abundant in collagen protein, trace elements, calcium, and phosphorus. Bone collagen can regulate bone metabolism, inhibit joint degeneration, and increase bone density; Calcium and phosphorus (regardless of their source) can be easily assimilated by human body, and increase of calcium in bloodstream can improve bone strength and toughness, promote bone growth, and provide materials for increasing bone density[21,22]. Several studies have confirmed that Jintiange capsule can effectively increase patients' bone density and inhibit bone mass loss, and it is a safe and effective drug in treatment of primary osteoporosis[23,24].

In this study, the Cooney score and the ability of the hand strength to grip and pinch were increased, while the VAS measure was decreased at 3 and 6-month intervals after the treatment with Jintiange capsules. These changes indicated that Jintiange capsule is effective in relieving pain and improving wrist joint function of patients with acute bone atrophy. The imaging changes in the treatment group showed that Jintiange capsule can enhance bone metabolism, improve local osteoporosis, and increase bone mass. No side effect occurred in either of the two groups and it proved the safety of Jintiange capsule. In addition, this trial was carried out on the basis of rehabilitation training. We believe that rehabilitation exercise is important in the treatment of acute bone atrophy, which is also supported by other studies[25].

Acute bone atrophy following distal radius fracture is common and easily neglected. The pain and dysfunction seriously affect the quality of life. As a kind of bionic medicine, Jintiange capsule can inhibit local osteoporosis, increase bone mass, improve wrist function, and alleviate pain. It is a safe and effective drug for treating acute bone atrophy.

## Conflict of interest statement

The authors report no conflict of interest.

## Founding project

This study was supported by the Science and Technology Support Project of Hebei Traditional Chinese Medicine Administration (No. 2019210).

## Authors' contribution

L.Y.W. proposed the study, analyzed the data, and wrote the first draft. All authors contributed to the design and interpretation of the study and to further drafts.

## References

- [1] Jo YH, Kim K, Lee BG, Kim JH, Lee CH, Lee KH. Incidence of and risk factors for complex regional pain syndrome type 1 after surgery for distal radius fractures: A population-based study. *Sci Rep* 2019; **9**(1): 4871.
- [2] Moseley GL, Herbert RD, Parsons T, Lucas S, Van Hilten JJ, Marinus J. Intense pain soon after wrist fracture strongly predicts who will develop complex regional pain syndrome: prospective cohort study. *J Pain* 2014; **15**(1): 16-23.
- [3] Dijkstra PU, Groothoff JW, ten Duis HJ, Geertzen JH. Incidence of complex regional pain syndrome type I after fractures of the distal radius. *Eur J Pain* 2003; **7**(5): 457-462.
- [4] Ortiz-Romero J, Bermudez-Soto I, Torres-González R, Espinoza-Choque F, Zazueta-Hernandez JA, Perez-Atanasio JM. Factors associated with complex regional pain syndrome in surgically treated distal radius fracture. *Acta Ortop Bras* 2017; **25**(5): 194-196.
- [5] Gradl G, Steinborn M, Wizgall I, Mittlmeier T, Schürmann M. Acute CRPS I (Morbus Sudeck) following distal radial fractures--methods for early diagnosis. *Zentral Chir* 2003; **128**(12): 1020-1026.
- [6] Hanel DP, Jones MD, Trumble TE. Treatment of complex fractures wrist fractures. *Orthop Clin North Am* 2002; **33**(1): 35-38.
- [7] Yu LJ, Wen JX, Song HP, Liu H. Application of Jintian'ge capsule in treatment of vertebral compression fracture in senile osteoporosis patient. *Zhongguo Zhong Yao Za Zhi* 2015; **21**(11): 1366-1368.
- [8] Callmeier EM. Diagnosis and therapy of post-traumatic Sudeck syndrome of the hand. *Z Arztl Fortbild (Jena)* 1990; **84**(12): 609-613.
- [9] Murariu IC, Macovei L. Sudeck's post-traumatic osteodystrophy. *Rev Med Chir Soc Med Nat Iasi* 2012; **116**(4): 1143-1149.
- [10] Cooney WP, Bussey R, Dobyns JH, Linscheid RL. Difficult wrist fractures. Perilunate fracture-dislocations of the wrist. *Clin Orthop Relat Res* 1987; (214): 136-147.
- [11] Wei L, Zhang H, Li X, Yang C, Wang G, Zhang L, et al. Efficacy and safety evaluation of intravenous infusion of *Cervus* and *Cucumis* polypeptides for treatment of avascular necrosis of the femoral head: a

- randomized clinical trial. *J Tradit Chin Med* 2016; **36**(1): 39-44.
- [12]Rogers BA, Ricketts DM. Can vitamin C prevent complex regional pain syndrome in patients with wrist fractures? *J Bone Joint Surg Am* 2007; **90**(2): 1424-1431.
- [13]Jian-Hang W, Tao S. Comparison of effects of seven treatment methods for distal radius fracture on minimizing complex regional pain syndrome. *Arch Med Sci* 2017; **1**: 163-173.
- [14]McGee C, Skye J, Van Heest A. Graded motor imagery for women at risk for developing type I CRPS following closed treatment of distal radius fractures: a randomized comparative effectiveness trial protocol. *BMC Musculoskelet Disord* 2018; **19**(1): 202.
- [15]Crijns TJ, van der Gronde BATD, Ring D, Leung N. Complex regional pain syndrome after distal radius fracture is uncommon and is often associated with fibromyalgia. *Clin Orthop Relat Res* 2018; **476**(4): 744-750.
- [16]Ho JD, Al-Haseni A, Smith S, Bhawan J, Sahni D. Bullous complex regional pain syndrome: A description of the clinical and histopathologic features. *J Cutan Pathol* 2018; **45**(8): 633-635.
- [17]Cowell F, Gillespie S, Cheung G, Brown D. Complex regional pain syndrome in distal radius fractures: How to implement changes to reduce incidence and facilitate early management. *J Hand Ther* 2018; **31**(2): 201-205.
- [18]Wei LY, Zhang HW. Effect of artificial tiger bone powder on low back pain in senile osteoporosis. *Chin J Osteoporosis* 2017; **23**(11): 97-99.
- [19]Wei LY, Zhang HW, Zhao G. Effect of artificial tiger bone powder in the treatment of postmenopausal osteoporosis. *Chin J Primary Med Pharm* 2017; **24**(19): 2982-2984.
- [20]Han N, Wang TB, Kou YH, Zhang DY, Zhang PX, Yin XF, et al. Effect of bionic tiger-bone powder on rat osteoblasts proliferation and type-collagen expression. *Chinese J Tissue Eng Res* 2012; **16**(2): 201-205.
- [21]Ruan HL, Zhou LR, Guo KQ, Ye LX, Yang K. Clinical observation of the efficacy of Jintiange on the treatment of low bone mass. *Chin J Osteoporosis* 2015; **21**(5): 624-626.
- [22]Wei LY, Chen LJ, Li CL, Zhao G, Zhang HW, Liu ZK, et al. Effect of Jintiange capsule on fracture healing and function recovery in patients with osteoporotic distal radius fractures. *Chin J Osteoporosis* 2015; **21**(11): 1366-1368.
- [23]He BY, Teng T, Liu BG, Liu JY, Li XM. The clinical efficacy of Jintiange capsule on the treatment of primary osteoporosis. *Chin J Osteoporosis* 2015; **21**(2): 168-174.
- [24]Wei LY, Zhang HW, Zuo JZ, Xu SM. Artificial tiger bone powder for improving the quality of life in elderly patients with fracture. *Tradit Med Res* 2019; **4**(4): 213-221.
- [25]Oaklander AL, Horowitz SH. The complex regional pain syndrome. *Handb Clin Neurol* 2015; **131**: 481-503.