

Original Research Article

Histological Study on the Protective Effect of Atomoxetine against Olanzapine Induced Weight Gain in Male Albino Rats

Dr. Mohamed Salah Elgendy

Ass. Prof. of Histology, Histology Department, Faculty of Medicine, Fayoum University, Fayoum, Egypt.

ABSTRACT

Olanzapine is an effective atypical antipsychotic carrying the highest risk of weight gain. Atomoxetine is a Norepinephrine reuptake inhibitor that used mainly in attention deficit hyperactivity disorder in children and was reported to augment Olanzapine effect. Clinical observation showed loss of weight in some patients taking it for other indications. So the aim of this research work is to study the role of Atomoxetine in reducing Olanzapine induced obesity in rats through its effect on adipose tissue structure. We used Forty adult male albino rats which were divided into four groups: control group, Atomoxetine treated group (1 mg/kg/day), Olanzapine treated group (1 mg/kg/day), and group treated with both drugs (co-treated group). Immunohistochemical staining for UCP1 was applied on histological sections. The weight gain in Olanzapine group was significantly reduced when co-treated with Atomoxetine. The size of white adipocytes decreased in co-treated group than Olanzapine group with appearance of UCP1 reactive cells in white adipose tissue and increased immunoreactivity in the brown adipose tissue in rats taking Atomoxetine alone or in co-treated groups. We can conclude that Atomoxetine may be beneficial in decreasing the weight gain induced by Olanzapine through its effect on adipose tissue increasing the activity of brown adipose tissue or browning of white adipose tissue by activating UCP1 in it.

Key words: Olanzapine, Atomoxetine, adipose tissue, UCP1

INTRODUCTION

Olanzapine is one of the second generation antipsychotic drugs that became among the first line of schizophrenia treatment due to high efficacy and tolerability. [1] One of the most common side effects of it is the increased risk of obesity in addition to higher risk of diabetes and cardiovascular diseases. [2] Olanzapine acts on multiple neurotransmitter receptors as dopamine D2, serotonin 5-HT2A and 5-HT2C, histamine H1 receptors, and muscarinic M1 and M3 receptors. [3, 4] Acting on D2 and 5-HT2A receptors play the key role in its therapeutic effects, while H1 receptor antagonistic action may be the key factor leading to Olanzapine induced obesity and acting on the 5-HT2C, and M3 receptors may lead to the other

antipsychotic induced metabolic side effects as diabetes and disturbed lipid profile including disturbed cholesterol and triglycerides levels in blood. [3, 5] Previous animal studies showed that Olanzapine may modulate histaminergic neurotransmission responsible for food intake, hyperglycemia and weight gain in rats. [5, 6] In some human studies, there was a remarkable amount of weight gain in some patients within year treatment duration. The weight gain was accompanied by an increase in white fat. [7] In clinical practice, schizophrenic patients may need long or even life-time treatment with antipsychotic drugs. Compliance of patients is decreased because of some adverse side effects of medications as obesity especially in females. [8] Olanzapine-induced weight gain observed in

rat models may be partially related to decreased amount or activity of brown adipose tissue. [9]

Decreased brown adipose tissue (BAT) activity may be associated with obesity and diabetes in humans. The mitochondria of cells in BAT are very rich in uncoupling protein 1 (UCP1). BAT regulates glucose metabolism and improves insulin sensitivity, while brown adipogenesis is suppressed in cases of insulin resistance. So, brown fat stimulation and formation may help in fighting against obesity and diabetes. [10]

Atomoxetine is a norepinephrine reuptake inhibitor (NRI) approved for use mainly in cases of attention deficit hyperactivity disorder (ADHD) in children, adolescents, and adults [11] in addition to decreasing craving in patients recovered from drug abuse of opiates and amphetamines. It has no abuse potential which makes it safer to be used in children unlike methylphenidate (Ritalen) which is more effective but with higher risk of drug abuse. [12] It was noticed in clinical practice that overweight children treated from ADHD taking Atomoxetine showed significant weight loss. [13, 14] The underlying mechanisms of these results are not fully understood. [15] Since Atomoxetine has a high safety profile, we hypothesize that it may be beneficial in decreasing antipsychotic induced obesity in schizophrenic patients.

So the aim of this study is to spot more light on the role of Atomoxetine in decreasing Olanzapine induced obesity in rats through its effect on adipose tissue structure and activity. Histological, immunohistochemical techniques, morphometric measurements and statistical analysis of data were used in this study.

MATERIALS AND METHODS

The original research was approved by the ethics committee in the basic medical science departments union Faculty of Medicine Fayoum University Egypt following international ethics and

regulations for animal research in laboratory animals' applications and all procedures were held under it. [16]

Materials:

Olanzapine (Zyprexa Velotab 10 mg tablet) and Atomoxetine (Strattera 10 mg capsule) were purchased from Eli Lilly pharmaceutical Company Indianapolis, Indiana 46285 USA.

In the present study, we used a dose of 1 mg/kg/day from both drugs by esophageal tube for 4 weeks. The Olanzapine tablet was crushed and dissolved in 10 ml phosphate buffered saline (PBS) and the Atomoxetine capsule was emptied and dissolved also in 10 ml phosphate buffered saline (PBS) to make the stock solution from which the dose calculated for each rat was administered to it. The stock solution should be shaken well before use.

Animals:

The present study included 40 male adult albino rats weighing (200±10 gm). They were obtained from and housed in the animal house of Vacsera - Holding Company for Biological Products and Vaccines (Helwan- Cairo- Egypt)

The animals received equal amount/ cage of standard diet for rodents and allowed free access to water. They were divided into 4 groups 10 animals each. Each group was kept in separate wire cage at room temperature.

The groups are:

Group I (Control group): received 1 ml PBS by esophageal tube.

Group II (Atomoxetine group) received 1 mg Atomoxetine/kg/day dissolved in PBS by esophageal tube.

Group III (Olanzapine group): received 1 mg Olanzapine/kg/day dissolved in PBS by esophageal tube.

Group IV (Olanzapine and Atomoxetine group); received 1 mg Atomoxetine/kg/day and 1 mg Olanzapine/kg/day dissolved in PBS by esophageal tube.

Body weight for each rat was measured weekly.

After 4 weeks treatment, rats were sacrificed after being anaesthetized with

intraperitoneal injection of 50 mg/kg thiopental sodium. The peritoneal and epididymal white adipose tissue, and interscapular brown adipose tissue were collected and fixed in 10% formalin for 24 hours. Paraffin blocks were prepared and 5µm thick sections were stained with Haematoxylin and Eosin stain and immunohistochemical staining technique for UCP1. ^[17] Quantitative morphometric analysis and statistical analysis of the obtained immunohistochemical results were done.

Immunohistochemical staining:

Sections from all animals were processed simultaneously. Tissue samples were fixed in 10% formalin, processed and embedded in paraffin wax blocks. Sections were cut at 5 micron thickness and mounted on poly-L-lysine-coated microscope slides. Sections were labeled with an indirect streptavidin–biotin–peroxidase immunohistochemical staining for the presence of UCP-1 using Anti-UCP-1 (ready-to-use rabbit polyclonal antibody Cat#U6382, RRID:AB_261838 Sigma-Aldrich St. Louis, Missouri, MO 63178USA). The sections were deparaffinized and rehydrated by passing through two changes of xylol, two changes of 100%, then 90% and 70% ethyl alcohol then two changes of distilled sterile water, for 15 min each. Sections were treated with 3% H₂O₂ and methanol for 30 min to block endogenous peroxidase activity then washed in phosphate- buffered saline (PBS 3 changes, 2 minutes each). Excess buffer was drained and non-specific background was eliminated by covering the sections immediately with 2 drops of serum blocking solution and incubated for 10 minutes at room temperature then excess serum was eliminated. Primary antibody was applied to the sections, 2 drops for each section and incubated in humidity chamber for 60 minutes at room temperature. Sections were washed with PBS (3 changes 2 minutes each), then incubated with biotinylated polyvalent secondary antibody Histostain SP kit Cat. #95-9643 (LAB-SA system,

Zymed Laboratories Inc, San Francisco, CA 94080, USA,) for 20 min. Sections were rinsed well with PBS and incubated with "Streptavidin-Horseradish peroxidase" 2 drops for each section) then incubated for 10 minutes in the humidity chamber. Slides were washed well in PBS (3 changes, 2 minutes each) and then dried around the edges of the sections using a piece of gauze. Substrate-chromogen mixture was prepared (Reagents 3A, 3B, 3C) by adding one drop of concentrated substrate buffer, one drop of concentrated DAB chromogen and 1 ml of 0.6% hydrogen peroxide to one ml of distilled water. The mixture was mixed well and protected from light and applied immediately to the sections (2 drops for each section). Slides were incubated at room temperature for 5-10 minutes then Slides were rinsed well with distilled water and they were counterstained with hematoxylin. Slides were washed in tap water until blue. Slides were put in PBS, and then rinsed in distilled water. The slides were dehydrated and mounted.

UCP-1 positive cells showed brown cytoplasmic deposits.

Negative controls for all groups were performed by replacing the primary antisera with PBS.

Positive control was a specimen of interscapular brown adipose tissue.

Quantitative Morphometric Analysis:

The mean white adipocyte area was calculated in H&E stained sections.

The mean UCP-1 immunostained area percent was calculated.

The mean UCP-1 immunostained optical density was calculated.

Using the Leica Qwin 500 Image analysis these parameters were measured in five randomly selected non overlapping fields per slide from five slides of each animal. The magnification used was ×400.

Statistical analysis methods:

Statistical analysis was performed on "EXCELL" Statistical Analysis System Software. Data were presented as the Mean ± SD. Differences among the study groups were detected by one way analysis of

variance (ANOVA) as global test to determine any differences in data prior to comparing pairs of groups then "student-t test" was performed. P values < 0.05 were considered statistically significant. [18]

RESULTS

As regard the effect of Atomoxetine co-treatment in reducing Olanzapine-induced weight gain; in the Olanzapine-only group, there was significant increase in body weight gain compared to the control group at the end of the 4 weeks treatment

period. On the other hand, although the Olanzapine-Atomoxetine co-treatment group had a higher weight gain than the control and Atomoxetine only groups; it appeared to have a significantly lower body weight gain than the Olanzapine-only group after 4 weeks. However, the Atomoxetine - only treatment had no significant difference in weight gain compared to the control group. Therefore, co-treatment of Atomoxetine and Olanzapine can partially reduce weight gain induced by chronic Olanzapine treatment (table: 1).

Table (1): Mean % of body weight changes

	G I (Control)	G II (Atomoxetine)	G III (Olanzapine)	G IV (Olanzapine-Atomoxetine)
initial body weight	202±5	201±7	198±10	199±6
final body weight	212±8	208±7	230±6	216±10
body weight change %	104.717 a	103.8278 a	113.913 b	107.8704 c

*Different superscripts in the same row indicate statistically significant difference (P < 0.05) compared to other groups.

Histological results:

Histopathological observations on white adipose tissues of control rats showed that cells appeared with white adipocyte morphology as the cytoplasm appeared empty vacuolated and nuclei were peripheral eccentric and flattened. In all the sections, cells with white adipocyte morphology were predominant. However, in the sections from animals taking Atomoxetine alone or as co-treatment with Olanzapine, individual cells or islets of cells with multilocular brown adipocyte morphology could be identified. The sections of Olanzapine group showed remarkable large sized adipocytes in many areas more than all other groups. While in the co-treated group the size of cells appeared medium in size between Olanzapine group from one side and Control and Atomoxetine group from the other side (Fig. 1).

Photomicrographs of sections of white adipose tissue showing cells with white adipocyte morphology as the cytoplasm appeared empty vacuolated and nuclei were peripheral eccentric and flattened (thick arrows). In all the sections, cells with white adipocyte morphology were predominant. In the sections from animals taking Atomoxetine alone or as co-treatment

with Olanzapine, individual cells or islets of cells with multilocular brown adipocyte morphology could be identified (thin arrows). The sections of Olanzapine group showed remarkable large sized adipocytes in many areas more than all other groups (L). While in the co-treated group the size of cells appeared medium in size (M) between Olanzapine group from one side and Control and Atomoxetine group from the other side.

[(a) Control; (b) atomoxetine; (c) Olanzapine; (d) co-treatment atomoxetine and Olanzapine] (H&E stain x400; scale bar 20 micrometer).

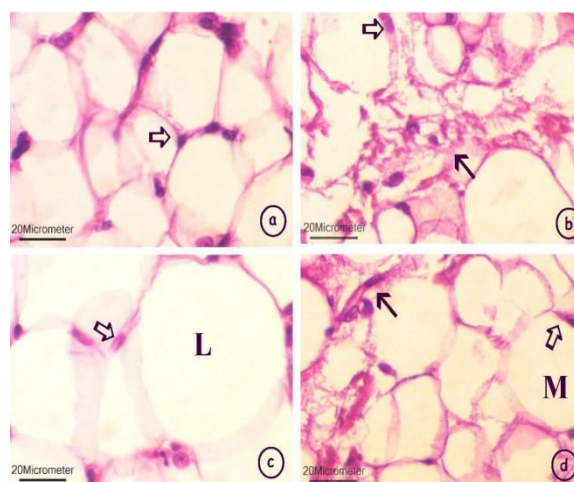


Figure (1): general morphology of white adipose tissue in all groups.

Brown adipose tissue showed cells with multilocular small fat globules with central rounded nuclei. No remarkable differences by H&E stain could be observed between different groups (Fig. 2).

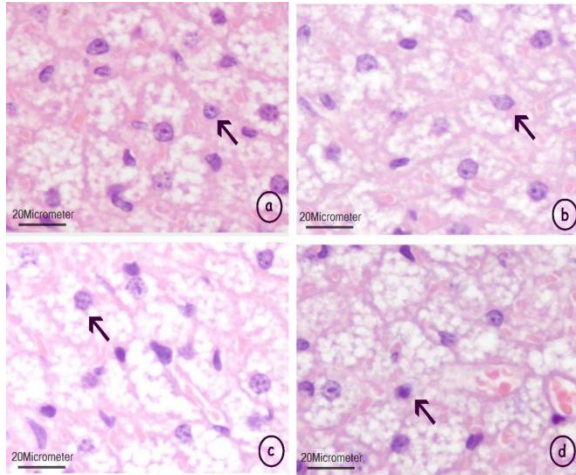


Figure (2): general morphology of brown adipose tissue in all groups.

Photomicrographs of sections of Brown adipose tissue; showing cells with multilocular small fat globules with central rounded nuclei (thin arrows). No remarkable differences could be observed between different groups.

[(a) Control; (b) atomoxetine; (c) Olanzapine; (d) co-treatment atomoxetine and Olanzapine] (H&E stain x400; scale bar 20 micrometer).

As regard immunoreactivity for UCP1 in white adipose tissues; it could be observed in the Atomoxetine and co-treated groups in the form of sporadic immunoreactive cells with either multilocular or unilocular morphology among non reactive white adipocytes in the peritoneal and epididymal adipose tissue with no remarkable differences between the two sites. While in the Control group and Olanzapine group; there was no remarkable immunoreactivity for UCP1 (Fig. 3).

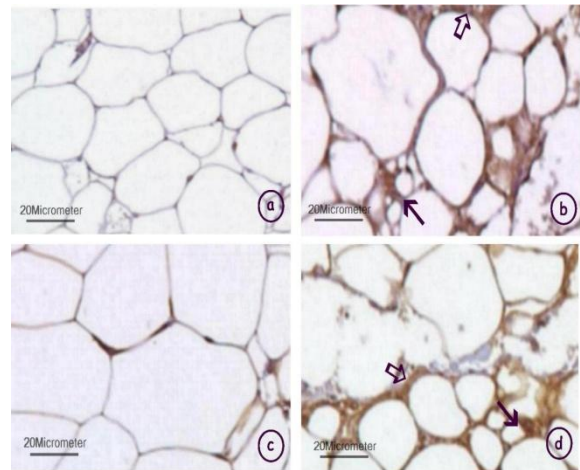


Figure (3): immunohistochemical staining of white adipose tissue in all groups.

White adipose tissues in the Atomoxetine and co-treated groups showed immunoreactivity for UCP1 in the form of sporadic immunoreactive cells with either unilocular (thick arrows) or multilocular morphology (thin arrows) among non reactive white adipocytes. While in the Control group and Olanzapine group; there was no remarkable immunoreactivity for UCP1

[(a) Control; (b) atomoxetine; (c) Olanzapine; (d) co-treatment atomoxetine and Olanzapine] (UCP1 immunostaining x400; scale bar 20 micrometer).

Brown adipose tissue showed positive immunoreactivity in all groups with strong reactivity in the Atomoxetine and the co-treated groups more than Control and Olanzapine groups (Fig. 4).

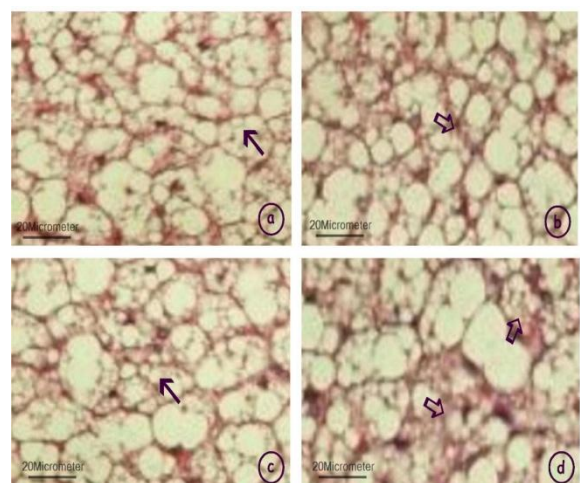


Figure (4): immunohistochemical staining of brown adipose tissue in all groups.

Brown adipose tissue showed positive immunoreactivity in all groups with strong reactivity in the Atomoxetine and the co-treated groups (thick arrows) more than Control and Olanzapine groups (thin arrows). [(a) Control; (b) atomoxetine; (c) Olanzapine; (d) co-treatment atomoxetine and Olanzapine] (UCP1 immunostaining x400; scale bar 20 micrometer).

Morphometric results:

ANOVA among groups as regard the mean size of white adipocyte area and UCP1 mean area % and optical density immunoreactivity showed that in each parameter; there was statistically significant variance among different groups were $P < 0.05$.

ANOVA among groups as regard the mean size of brown adipocyte area and UCP1 mean area % showed that there was statistically non significant variance among different groups were $P > 0.05$. While optical density immunoreactivity showed

statistically significant variance among different groups were $P < 0.05$.

When ANOVA showed significant variance among groups; comparison between each two groups was performed using t-test and the results were summarized in tables (2, 3, 4):

Table (2) summarize the results of measuring mean size of white and brown adipocyte area:

Mean area size of white adipocyte revealed the highest value in the group III (Olanzapine) while the least one was in group II (Atomoxetine) while group I (control) and group IV (co-treatment) showed no remarkable statistical difference.

Comparing each two groups together; it was found to be statistically significant (P value < 0.05) except between the group I and group IV (control and the co-treatment groups) where no statistical significance could be observed. As regard brown adipocyte area; there was no statistically significant difference in adipocyte size among different groups.

Table (2): Mean size of white and brown adipocyte area in μ^2

Group	G I (Control)	G II (Atomoxetine)	G III (Olanzapine)	G IV (Olanzapine-Atomoxetine)
White adipose tissue	383.245±18.56 a	345.158±12.23 b	512.206±7.73 c	369.417 ±9.33 a
Brown adipose tissue	84.37±8.9 a	82.37±5.33 a	86.37±6.19 a	88.37±4.42 a

*Different superscripts in the same row indicate statistically significant difference ($P < 0.05$) compared to other groups.

Table (3) summarize the results of measuring immunohistochemical UCP1 Mean area % in white and brown adipose tissue:

Mean area % of UCP1 immunoreactivity in white adipose tissue revealed the highest value in the group II (Atomoxetine) and group IV (co-treatment) while no immunoreactivity could be detected in group I and group III (Control group and Olanzapine group).

Comparing each two groups together; it was found to be statistically significant (P value < 0.05) except between group I and group III and between group II and group IV where no statistical significance could be observed.

As regard brown adipocyte Mean area % of UCP1 immunoreactivity; there was no statistically significant difference.

Table (3): Mean area % of UCP1 immunohistochemical staining

Group	G I (Control)	G II (Atomoxetine)	G III (Olanzapine)	G IV (Olanzapine-Atomoxetine)
White adipose tissue	0.0 a	2.18±1.33 b	0.0 a	1.83±0.68 b
Brown adipose tissue	7.05±0.09 a	12.38±1.74 b	5.13±0.25 a	11.83±0.81 b

*Different superscripts in the same row indicate statistically significant difference ($P < 0.05$) compared to other groups.

Table (4) summarize the results of measuring immunohistochemical UCP1

Mean optical density in white and brown adipose tissue:

Mean optical density of UCP1 immunoreactivity in white and brown adipose tissue revealed the highest value in the group II (Atomoxetine) and group IV

(co-treatment) while the least one was in group I and group III (Control group and Olanzapine group).

Table (4): The mean UCP-1 immunostained optical density

Group	G I (Control)	G II (Atomoxetine)	G III (Olanzapine)	G IV (Olanzapine-Atomoxetine)
White adipose tissue	0.0 a	37.934±7.4 b	0.0 a	42.45±5.9 b
Brown adipose tissue	102.474±3.4 a	138.274±3.2 b	89.081±8.1 a	121.427±6.3 b

*Different superscripts in the same row indicate statistically significant difference ($P < 0.05$) compared to other groups.

Comparing each two groups together; it was found to be statistically significant (P value < 0.05) except between group I and group III and between Group II and group IV where no statistical significance could be observed.

DISCUSSION

Using long term antipsychotic treatment is very important for schizophrenic patients. Antipsychotic-side effects are important risk factors for cardiovascular disease and metabolic side effects as insulin resistance that increases morbidity and mortality rates and decreasing the patient's compliance to treatment. [19] Many clinical trials showed that antipsychotic administration (particularly Olanzapine and clozapine) may cause many side effects including significant weight gain. [20] Researchers are trying to find methods that can prevent antipsychotics induced weight gain. Few clinical trials used Atomoxetine as an augmentation for Olanzapine to alleviate the depressive and agitation symptoms associated with schizophrenia, some of them reported an effect of Atomoxetine treatment on Olanzapine-induced weight gain, with an unidentified mechanism of action. [21]

Adipose tissue is divided mainly into white adipose tissue (WAT) with unilocular fat cells distributed all over the body and acting as energy storing cells and brown adipose tissue (BAT) with multilocular fat cells found in few areas as periaortic and interscapular areas which is characterized by the presence of UCP1 in the mitochondria leading to energy dissipation as heat (thermogenesis) so decreasing the

amount of (WAT) and energy storage in the body. [22] This type of brown adipocytes is stimulated mainly through adrenergic stimulation. [23] Some drugs and natural products were found to have the ability of activating brown adipocytes activity and even activating white adipocytes to have UCP1 (browning of white adipose tissue) so performing a (BAT) like effect. [24] These drugs and natural products may be effective in reducing weight which can be a great way in fighting obesity.

Atomoxetine was found to have controversial effects as regard its effect on body weight in different studies. It is a drug acting as a Norepinephrine reuptake inhibitor (NRI) so it can stimulate the UCP1. In addition to that; it can be used as an augmentation therapy with Olanzapine and clozapine to enhance their therapeutic effects. [25-27] So it may be a great combination to increase the effect of Olanzapine and at the same time decrease one of its great side effects if it is proved to be effective.

This work aimed at investigating the role of Atomoxetine in reducing Olanzapine-induced weight gain through its effect on the adipose tissue in rats. Histological and immunohistochemical techniques in addition to morphometric measurements and statistical analysis of the data were applied in this study.

In the present study; according to dosage translation between species based on body surface area following the FDA guideline; [28] Olanzapine was administered to rats in a dose of 1 mg/kg orally for 4 weeks. This dose is equivalent to 10 mg/day for human average body weight 60 kg

which is the average common safe recommended dose used in different indications. This dose of Olanzapine was sufficient to promote adipocyte accumulation of fat droplets with decreased level of thermogenesis which was implicated as one important causative factor of adipose tissue accumulation with Olanzapine treatment. [29, 30]

Using Atomoxetine to counteract weight gain may be adventitious to other drugs as it is already could be used as an augmentation therapy to increase the Olanzapine antipsychotic action especially in agitated patients or even used in treating some co-morbid disorders. [31] The recommended dose for human in ADHD range from 0.5 to 1.2 mg/kg/day which is equivalent to 3 to 7.5 mg/kg/day for rats while as an augmentation therapy it can be used in lower doses, [32] so we used a dose of 1 mg/kg/day in our experiment.

In our study, we observed beneficial effect of Atomoxetine treatment in reducing Olanzapine-induced weight gain in rats. This finding in rats also enabled us to further investigate the mechanism of Atomoxetine's action. Olanzapine treatment was reported to increase fat accumulation in rats and in humans. [33-35] In our study, the results demonstrated that Olanzapine treatment, in addition to increasing the body weight compared to other groups, there was increase in adipocyte average size in different sample places compared to similar sites in other groups. These changes were reduced markedly with the concomitant use of Atomoxetine with Olanzapine in the co-treated group in addition to appearance of few cells with brown adipocyte morphology or cells with UCP1 reactivity. In this research work; we demonstrated the Atomoxetine effect on browning of white adipose tissue in Olanzapine treated rats that may be an important mechanism in preventing Olanzapine-induced weight gain, which might imply a potential effectiveness on human patients taking Olanzapine treatment.

We tried to investigate the role of Atomoxetine on the white adipose tissue deposition occurred during Olanzapine treatment. The increased energy storage induced by Olanzapine was extensively considered a result of both increased energy intake (such as hyperphagia) [36] and reduced energy expenditure (such as decreased thermogenesis). [9] In this work we minimized the effect of increased intake by fixing the amount of food available for rats in each cage and adjusting it to be similar to that consumed by the control group. So in our study; we can say that no remarkable effect of food intake and appetite could be a contributing factor in weight gain in Olanzapine treated rats or in proportional lesser weight gain in co-treated rats as we fixed the amount of food intake to all groups as much as possible. Some studies reported a varying degree of Atomoxetine effect on food intake as reduced food intake, while other studies showed that Atomoxetine treatment did not affect food intake. [37, 38] In our study we found no remarkable effect of atomoxetine in reducing appetite in rats as the same amount of food was nearly consumed in all groups. Histological and morphometric study of the brown adipose tissue in the interscapular area showed more reactivity to UCP1 in rats of Atomoxetine group and co-treatment group with no remarkable differences among other groups. This may be due to the stimulatory effect of Atomoxetine as an NRI that elevate the level of Norepinephrine in the brain and circulating Norepinephrine that increase the activity of UCP1 present in brown adipose tissue, [39] in addition to that the white adipose tissue that is normally negative for UCP1 showed mild reactivity in rats taking Atomoxetine either alone or as a co-treatment with Olanzapine. Our results strongly suggest the mechanism of action for Atomoxetine occurs by increasing energy expenditure or by reducing energy storage through its effect on the UCP1 in brown adipose tissue or even browning of white adipose tissue, rather than inhibition

of energy intake through decreasing the amount of food intake.

Atomoxetine is a drug used mainly for the treatment of ADHD in children and can be useful in treating co-morbid diseases with a high efficacy and safety profile. [40-42] The treatment with Atomoxetine did not moderate Olanzapine-induced food intake, so the drug treatment only partially prevented Olanzapine-induced weight gain. With the aim of elucidating the mechanism of Atomoxetine efficacy, we performed immunohistochemical study for UCP1 expression in brown adipose tissue (BAT), and white adipose tissue (WAT); we found that Olanzapine treatment resulted in significantly reduced expression of UCP1 suggesting that thermogenesis would be decreased, which is consistent with Olanzapine-reduced BAT temperature reported by another research group. [43]

Up till now, there is no specific agent being used to control Olanzapine induced weight gain. So the new finding in this study is that Atomoxetine can activate brown adipose tissue and stimulate browning of white adipose tissue which is more prominent at the time of need with high fat deposition after Olanzapine treatment suggesting the presence of feedback mechanism that increase the reactivity of adipose tissue to Atomoxetine after certain period of higher degree of fat deposition due to Olanzapine treatment. Further investigation about this effect may help in decreasing the Olanzapine induced weight gain that lead to non compliance of this treatment in many patients taking that medication.

CONCLUSIONS

This study provides evidence that significant Olanzapine induced weight gain could be controlled to some extent with concomitant use of Atomoxetine in small doses. Since schizophrenic patients usually need long term and repeated antipsychotic treatment, it is very important to control weight gain caused by chronic antipsychotic treatment. In this study, we found that co-

treatment with Atomoxetine is effective in significantly reducing weight gain induced by Olanzapine through the chronic treatment course. This study further demonstrated that the mechanisms of Atomoxetine in reducing Olanzapine-induced body weight gain may be in part to its effect on the adipose tissue through activation of UCP1 in brown and even in white adipose tissue. This study provides further evidence to support a clinical trial to test the effectiveness of co-treatment of Olanzapine and Atomoxetine for controlling the weight gain in schizophrenic patients with chronic and repeated Olanzapine treatment.

REFERENCES

1. Birur B, Thirthalli J, Janakiramaiah N, Shelton RC, Gangadhar BN. Dimensions of schizophrenia and their time course of response to a second generation antipsychotic Olanzapine-A clinical study. *Asian J Psychiatr.* 2016; 24:17-22.
2. Barak N, Beck Y, Albeck JH. Betahistine decreases Olanzapine-induced weight gain and somnolence in humans. *J Psychopharmacol.* 2016; 30(3):237-41.
3. Ikegami M, Ikeda H, Ohashi T, Kai M, Osada M, Kamei A, Kamei J. Olanzapine-induced hyperglycemia: possible involvement of histaminergic, dopaminergic and adrenergic functions in the central nervous system. *Neuroendocrinology.* 2013; 98(3):224-32.
4. Lian J, Huang XF, Pai N, Deng C. Effects of Olanzapine and betahistine co-treatment on serotonin transporter, 5-HT_{2A} and dopamine D₂ receptor binding density. *Prog Neuropsychopharmacol Biol Psychiatry.* 2013; 47:62-8.
5. Hu Y, Young AJ, Ehli EA, Nowotny D, Davies PS, Droke EA, Soundy TJ, Davies GE. Metformin and berberine prevent Olanzapine-induced weight gain in rats. *PLoS One.* 2014; 9(3):e93310.
6. Nagata M, Nakajima M, Ishiwata Y, Takahashi Y, Takahashi H, Negishi K, Yasuhara M. Mechanism Underlying

- Induction of Hyperglycemia in Rats by Single Administration of Olanzapine. *Biol Pharm Bull.* 2016; 39(5):754-61.
7. Salviato Balbão M, Cecílio Hallak JE, Arcoverde Nunes E, Homem de Mello M, Triffoni-Melo Ade T, Ferreira FI, Chaves C, Durão AM, Ramos AP, de Souza Crippa JA, Queiroz RH. Olanzapine, weight change and metabolic effects: a naturalistic 12-month follow up. *Ther Adv Psychopharmacol.* 2014; 4(1):30-6.
 8. Staring AB, Mulder CL, Duivenvoorden HJ, De Haan L, Van der Gaag M. Fewer symptoms vs. more side-effects in schizophrenia? Opposing pathways between antipsychotic medication compliance and quality of life. *Schizophr Res.* 2009; 113(1):27-33.
 9. Zhang Q, Lian J, He M, Deng C, Wang H, Huang XF. Olanzapine reduced brown adipose tissue thermogenesis and locomotor activity in female rats. *Prog Neuropsychopharmacol Biol Psychiatry.* 2014; 51:172-80.
 10. Hibi M, Oishi S, Matsushita M, Yoneshiro T, Yamaguchi T, Usui C, Yasunaga K, Katsuragi Y, Kubota K, Tanaka S, Saito M. Brown adipose tissue is involved in diet-induced thermogenesis and whole-body fat utilization in healthy humans. *Int J Obes (Lond).* 2016; 40(11):1655-1661.
 11. Fredriksen M, Halmøy A, Faraone SV, Haavik J. Long-term efficacy and safety of treatment with stimulants and Atomoxetine in adult ADHD: a review of controlled and naturalistic studies. *Eur Neuropsychopharmacol.* 2013; 23(6):508-27.
 12. Bjarnadottir GD, Haraldsson HM, Rafnar BO, Sigurdsson E, Steingrímsson S, Johannsson M, Bragadottir H, Magnússon A. Prevalent intravenous abuse of methylphenidate among treatment-seeking patients with substance abuse disorders: a descriptive population-based study. *J Addict Med.* 2015; 9(3):188-94.
 13. McElroy SL, Guerdjikova A, Kotwal R, Welge JA, Nelson EB, Lake KA, Keck PE Jr, Hudson JI. Atomoxetine in the treatment of binge-eating disorder: a randomized placebo-controlled trial. *J Clin Psychiatry.* 2007; 68(3):390-8.
 14. Pott W, Albayrak O, Hinney A, Hebebrand J, Pauli-Pott U. Successful treatment with Atomoxetine of an adolescent boy with attention deficit/hyperactivity disorder, extreme obesity, and reduced melanocortin 4 receptor function. *Obes Facts.* 2013; 6(1):109-15.
 15. Ravishankar V, Chowdappa SV, Benegal V, Muralidharan K. The efficacy of Atomoxetine in treating adult attention deficit hyperactivity disorder (ADHD): A meta-analysis of controlled trials. *Asian J Psychiatr.* 2016; 24:53-58.
 16. John P. Gluck, Tony Di Pasquale, and Barbara Orlans. *Applied Ethics in Animal Research (Philosophy, Regulation, and Laboratory Applications)*. Purdue University Press. West Lafayette, Indiana. USA; 2002. pp 131-148.
 17. Peter Jackson, David Blythe. Immunohistochemical techniques. In: *Bancroft's Theory and practice of histological techniques*. Kim Suvarna, Christopher Layton and John D. Bancroft. 7th ed. Churchill Livingstone. New York. USA; 2013. pp. 381-426.
 18. Jennifer Peat and Belinda Barton. *Medical Statistics: A Guide to Data Analysis and Critical Appraisal*. 1st ed. Blackwell Publishing Ltd, Oxford. UK; 2005. pp 108-156.
 19. Tschoner A, Engl J, Laimer M, Kaser S, Rettenbacher M, Fleischhacker WW, Patsch JR, Ebenbichler CF. Metabolic side effects of antipsychotic medication. *Int J Clin Pract.* 2007; 61(8):1356-70.
 20. Buoli M, Kahn RS, Serati M, Altamura AC, Cahn W. Haloperidol versus second-generation antipsychotics in the long-term treatment of schizophrenia. *Hum Psychopharmacol.* 2016; 31(4):325-31.
 21. Fleurence R, Williamson R, Jing Y, Kim E, Tran QV, Pikalov AS, Thase ME. A systematic review of augmentation strategies for patients with major depressive disorder. *Psychopharmacol Bull.* 2009; 42(3):57-90.

22. Kim EK, Lee SH, Jhun JY, Byun JK, Jeong JH, Lee SY, Kim JK, Choi JY, Cho ML. Metformin Prevents Fatty Liver and Improves Balance of White/Brown Adipose in an Obesity Mouse Model by Inducing FGF21. *Mediators Inflamm.* 2016; 2016:5813030.
23. Fukano K, Okamatsu-Ogura Y, Tsubota A, Nio-Kobayashi J, Kimura K. Cold Exposure Induces Proliferation of Mature Brown Adipocyte in a β 3-Adrenergic Receptor-Mediated Pathway. *PLoS One.* 2016; 11(11):e0166579.
24. Kim SH, Plutzky J. Brown Fat and Browning for the Treatment of Obesity and Related Metabolic Disorders. *Diabetes Metab J.* 2016; 40(1):12-21.
25. Ball MP, Warren KR, Feldman S, McMahon RP, Kelly DL, Buchanan RW. Placebo-controlled trial of Atomoxetine for weight reduction in people with schizophrenia treated with clozapine or Olanzapine. *Clin Schizophr Relat Psychoses.* 2011; 5(1):17-25.
26. McElroy SL, Guerdjikova AI, Mori N, O'Melia AM. Current pharmacotherapy options for bulimia nervosa and binge eating disorder. *Expert Opin Pharmacother.* 2012; 13(14):2015-26.
27. Zimbron J, Khandaker GM, Toschi C, Jones PB, Fernandez-Egea E. A systematic review and meta-analysis of randomised controlled trials of treatments for clozapine-induced obesity and metabolic syndrome. *Eur Neuropsychopharmacol.* 2016; 26(9):1353-65.
28. Reagan-Shaw S, Nihal M, Ahmad N. Dose translation from animal to human studies revisited. *FASEB J.* 2008; 22(3):659-61.
29. Nimura S, Yamaguchi T, Ueda K, Kadokura K, Aiuchi T, Kato R, Obama T, Itabe H. Olanzapine promotes the accumulation of lipid droplets and the expression of multiple perilipins in human adipocytes. *Biochem Biophys Res Commun.* 2015; 467(4):906-12.
30. Li Y, Zhao X, Feng X, Liu X, Deng C, Hu CH. Berberine Alleviates Olanzapine-Induced Adipogenesis via the AMPK α -SREBP Pathway in 3T3-L1 Cells. *Int J Mol Sci.* 2016; 17(11).
31. Sikirica V, Pliszka SR, Betts KA, Hodgkins P, Samuelson T, Xie J, Erder H, Dammerman R, Robertson B, Wu EQ. Comparative treatment patterns, resource utilization, and costs in stimulant-treated children with ADHD who require subsequent pharmacotherapy with atypical antipsychotics versus non-antipsychotics. *J Manag Care Pharm.* 2012; 18(9):676-89.
32. Todor I, Popa A, Neag M, Muntean D, Bocsan C, Buzoianu A, Vlase L, Gheldiu AM, Briciu C. Evaluation of the Potential Pharmacokinetic Interaction between Atomoxetine and Fluvoxamine in Healthy Volunteers. *Pharmacology.* 2017; 99(1-2):84-88.
33. Smith GC, Vickers MH, Shepherd PR. Olanzapine effects on body composition, food preference, glucose metabolism and insulin sensitivity in the rat. *Arch Physiol Biochem.* 2011; 117(4):241-9.
34. Mann S, Chintoh A, Giacca A, Fletcher P, Nobrega J, Hahn M, Remington G. Chronic Olanzapine administration in rats: effect of route of administration on weight, food intake and body composition. *Pharmacol Biochem Behav.* 2013; 103(4):717-22.
35. Daurignac E, Leonard KE, Dubovsky SL. Increased lean body mass as an early indicator of Olanzapine-induced weight gain in healthy men. *Int Clin Psychopharmacol.* 2015; 30(1):23-8.
36. He M, Zhang Q, Deng C, Wang H, Lian J, Huang XF. Hypothalamic histamine H1 receptor-AMPK signaling time-dependently mediates Olanzapine-induced hyperphagia and weight gain in female rats. *Psychoneuroendocrinology.* 2014; 42:153-64.
37. Rezaei G, Hosseini SA, Akbari Sari A, Olyaeemanesh A, Lotfi MH, Yassini M, Bidaki R, Nouri B. Comparative efficacy of methylphenidate and Atomoxetine in the treatment of attention deficit hyperactivity disorder in children and adolescents: A systematic review and meta-analysis. *Med J Islam Repub Iran.* 2016; 30:325.

38. Yu G, Li GF, Markowitz JS. Atomoxetine: A Review of Its Pharmacokinetics and Pharmacogenomics Relative to Drug Disposition. *J Child Adolesc Psychopharmacol.* 2016; 26(4):314-26.
39. Mirbolooki MR, Constantinescu CC, Pan ML, Mukherjee J. Targeting presynaptic norepinephrine transporter in brown adipose tissue: a novel imaging approach and potential treatment for diabetes and obesity. *Synapse.* 2013; 67(2):79-93.
40. Rizzo R, Gulisano M, Cali PV, Curatolo P. Tourette Syndrome and comorbid ADHD: current pharmacological treatment options. *Eur J Paediatr Neurol.* 2013; 17(5):421-8.
41. Pérez de los Cobos J, Siñol N, Pérez V, Trujols J. Pharmacological and clinical dilemmas of prescribing in co-morbid adult attention-deficit/hyperactivity disorder and addiction. *Br J Clin Pharmacol.* 2014; 77(2):337-56.
42. Hutchison SL, Ghuman JK, Ghuman HS, Karpov I, Schuster JM. Efficacy of Atomoxetine in the treatment of attention-deficit hyperactivity disorder in patients with common comorbidities in children, adolescents and adults: a review. *Ther Adv Psychopharmacol.* 2016; 6(5):317-334.
43. Stefanidis A, Verty AN, Allen AM, Owens NC, Cowley MA, Oldfield BJ. The role of thermogenesis in antipsychotic drug-induced weight gain. *Obesity (Silver Spring).* 2009; 17(1):16-24.

How to cite this article: Mohamed Salah E. Histological study on the protective effect of Atomoxetine against olanzapine induced weight gain in male albino rats. *International Journal of Research and Review.* 2017; 4(3):42-53.
